



## Mucous Membrane Pemphigoid in a Nonagenarian: A Case Report

Océane Babin de Lignac<sup>1,2</sup>, Priscille Carvalho<sup>1,2</sup>, Marion Carrette<sup>3</sup>, Lucie Cellier<sup>4</sup>, Philippe Courville<sup>4</sup>, Billal Tedbirt<sup>1,2</sup>

<sup>1</sup>Department of Dermatology, CHU Rouen, Rouen, France

<sup>2</sup>French Reference Center for Autoimmune Bullous Diseases, Normandie University, Rouen, France

<sup>3</sup>Department of Immunology, CHU Rouen, Rouen, France

<sup>4</sup>Department of Pathology, CHU Rouen, Rouen, France

Corresponding Author:

Océane Babin de Lignac, MD

Department of Dermatology, CHU

Rouen, 1 rue Germont, 76031 Rouen

Cedex, France

E-mail: O.Babin-De-Lignac@chu-rouen.fr

ORCID:

<https://orcid.org/0000-0003-4807-9152>

Received: March 7, 2023

Revised: June 8, 2023

Accepted: June 20, 2023

Mucous membrane pemphigoid is a rare autoimmune blistering disease characterized by post-bullous erosion of mucous membranes. Herein, we present a case of a nonagenarian man who was referred to our department of dermatology presenting with painful erosion of the buccal mucosa. Physical examination revealed palate erosion associated with erosion of the buccal mucosa. A diagnosis of mucous membrane pemphigoid was confirmed, and the patient was successfully treated with topical corticosteroids.

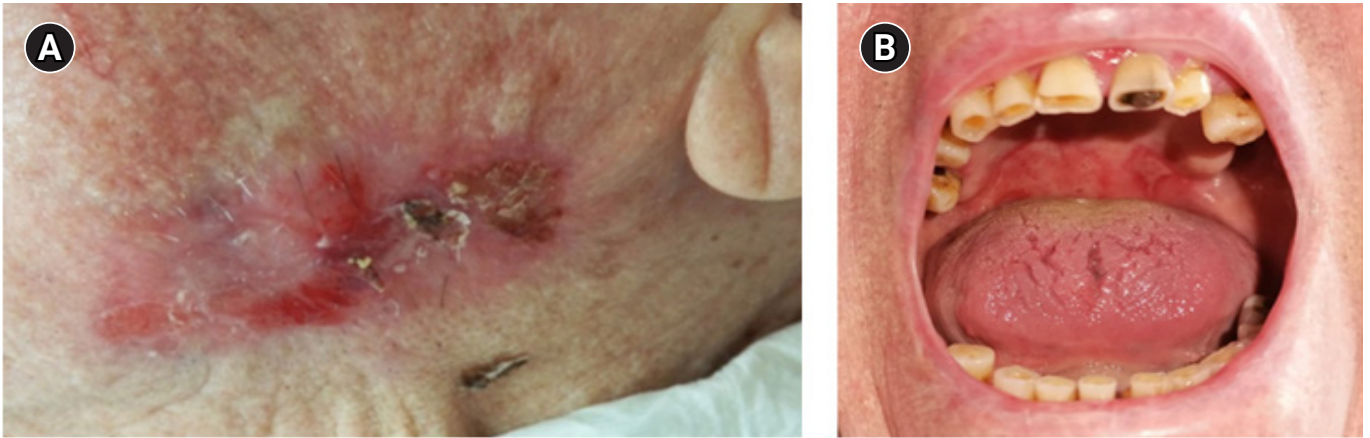**Key Words:** Autoimmune blistering disease, Geriatric, Mucous membrane pemphigoid

### INTRODUCTION

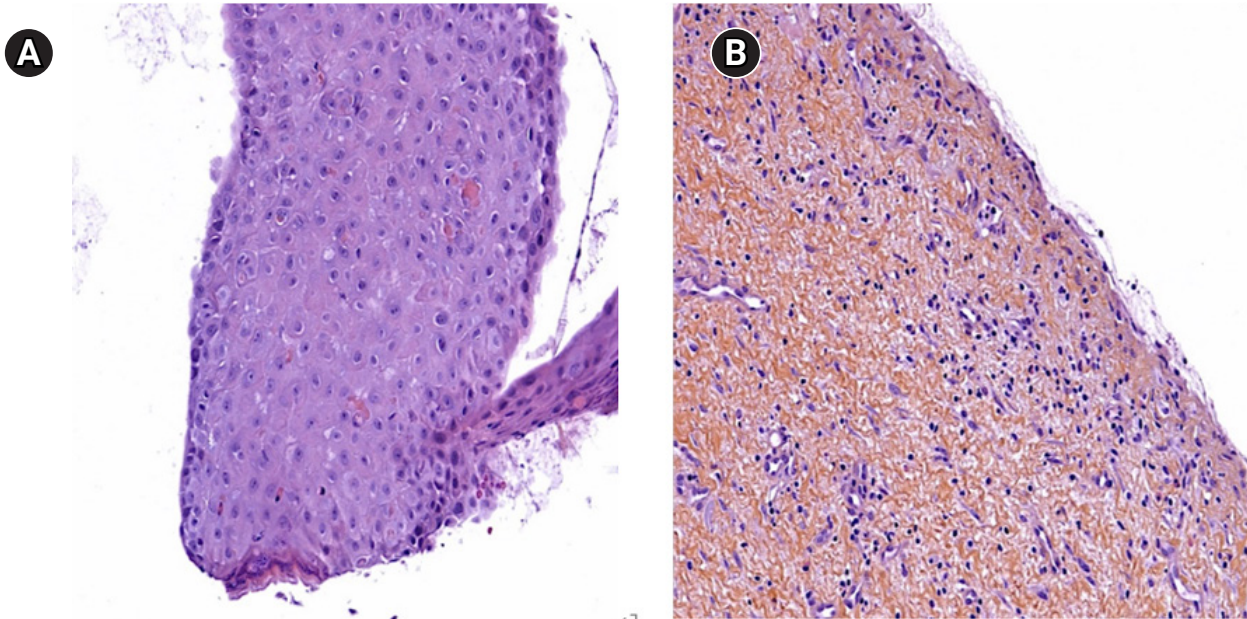
Mucous membrane pemphigoids are a group of chronic autoimmune blistering diseases of the chorioepithelial or dermoepidermal junction, which are characterized by predominant or exclusive mucosal involvement.<sup>1)</sup> Mucous membrane pemphigoids primarily affect older patients, typically those aged 60–80 years.<sup>2)</sup> Mucosal involvement includes the oral, nasopharyngeal, laryngopharyngeal, genital, esophageal, tracheal, anal, and ocular mucosal membranes. Additionally, skin lesions may also be present, although they are typically mild and are observed in approximately 30% of patients.<sup>2)</sup> Mucous membrane pemphigoids are characterized by scarring resulting from initial inflammation, leading to significant morbidity, including pain, malnutrition, and corneal blindness. In nonagenarians, the management of mucous membrane pemphigoid becomes more complex owing to the age-related physiological changes, comorbidities, and potential polypharmacy interactions. Herein, we report a case of an old patient who presented with painful buccal erosions and was diagnosed with mucous membrane pemphigoid that was successfully treated with topical corticosteroids.

### CASE REPORT

A 92-year-old male patient presented with a 6-month history of oral erosion that had resulted in feeding disorders and subsequent weight loss. His medical history included hypertension, atrial fibrillation, and dyslipidemia. Clinical examination revealed post-blistering erosions of the left buccal mucosa associated with palatal erosion (Fig. 1). The patient did not present any other mucosal or skin lesions. A skin biopsy revealed a cleavage between the epidermis and dermis with a few interstitial eosinophils present (Fig. 2). Direct cutaneous immunofluorescence of the biopsy revealed linear immunoglobulin G (IgG) and C3 deposits along the basement membrane. Laboratory test results were negative for antibodies against BP180, BP230, type VII collagen, and laminin 332. Immunoblotting studies of the skin extract and indirect immunofluorescence of salt-split skin yielded negative results. Clinical, histological, and immunological findings were consistent with a diagnosis of mild mucous membrane pemphigoid because the clinical involvement was limited to one site. As the Consensus Conference<sup>1)</sup> indicates that topical treatments can be introduced initially, the patient was prescribed clobetasol propionate cream. The lesions healed completely within 3 months of daily applica-



**Fig. 1.** Clinical presentation: (A) atrophic plaque on the left cheek, with a post-blister erosion in the center associated with painful erosion located on the palate (B).



**Fig. 2.** The skin biopsy revealed a cleavage between the epidermis (A) and dermis with a few interstitial eosinophils (B) (hematoxylin-eosin safran staining, original magnification  $\times 20$ ).

tion, allowing the resolution of pain and recovery of optimal oral feeding. No recurrence was observed after 1 year of follow-up.

## DISCUSSION

The symptoms and complications of mucous membrane pemphigoid can substantially impact the quality of life of patients living with the disease and can cause difficulties in eating, ultimately leading to malnutrition in some cases, as observed in our patient. Scar formation is a characteristic feature of mucous membrane pemphigoid, which can result in major disabilities (e.g., blindness

and esophageal, anal, and vaginal stenosis) and life-threatening situations (e.g., laryngeal stenosis leading to respiratory failure).

Mucous membrane pemphigoid is characterized by autoantibodies directed against various antigens of the dermoepidermal junction (i.e., BP180, laminin 332, type VII collagen,  $\alpha 6\beta 4$  integrin).<sup>2)</sup> Despite the recognition of multiple antigens targeted by autoantibodies and the use of various detection techniques (e.g., enzyme-linked immunosorbent assay [ELISA], immunoblot studies of skin extract, salt-split skin indirect immunofluorescence, and biochip technology), approximately one-third of the patients with mucous membrane pemphigoid do not have detectable autoanti-

bodies, as in our patient.<sup>3,4)</sup> According to the Consensus Conference,<sup>1)</sup> a diagnosis of mucous membrane pemphigoid is established based on the clinical presentation along with the detection of anti-dermoepidermal junction autoantibodies on direct immunofluorescence, direct immunoelectron microscopy, or serological tests (e.g., ELISA, immunoblotting).<sup>2,5)</sup> Direct immunofluorescence is the major diagnostic test, which has the highest sensitivity for the diagnosis of mucous membrane pemphigoid.<sup>5)</sup>

For mild/moderate mucous membrane pemphigoid, dapson, methotrexate, tetracyclines, and/or topical corticosteroids are recommended as the first-line treatment.<sup>5)</sup> Considering the advanced age and potential frailty of our patient, we opted for a topical treatment. High-potency topical corticosteroids led to complete remission in our patient within 3 months, indicating that less invasive treatments can be more beneficial in geriatric patients with mild/moderate mucous membrane pemphigoid. Such a strategy limits the risk of potentially life-threatening adverse events associated with systemic therapies in patients of advanced age.

In conclusion, mucous membrane pemphigoid is a rare autoimmune disease that predominantly affects the mucous membrane and frequently affects the oral mucosa. Recognizing this condition is crucial due to its potential to reduce the quality of life (e.g., oral pain), especially among older patients.

## ACKNOWLEDGMENTS

The authors are grateful to Nikki Sabourin-Gibbs, CHU Rouen, for her help in editing the manuscript.

## CONFLICT OF INTEREST

The researchers claim no conflicts of interest.

## FUNDING

None.

## AUTHOR CONTRIBUTIONS

Conceptualization, OBDL, BT; Data curation, OBDL, PC, MC, LC, PC, BT; Investigation, OBDL, PC, MC, LC, PC, BT; Methodology, OBDL, PC, MC, LC, PC, BT; Supervision, PC, BT; Writing-original draft, OBDL, PC, BT; Writing-review & editing, OBDL, BT.

## REFERENCES

1. Chan LS, Ahmed AR, Anhalt GJ, Bernauer W, Cooper KD, Elder MJ, et al. The first international consensus on mucous membrane pemphigoid: definition, diagnostic criteria, pathogenic factors, medical treatment, and prognostic indicators. *Arch Dermatol* 2002;138:370-9.
2. Rashid H, Lamberts A, Borradori L, Alberti-Violetti S, Barry RJ, Caproni M, et al. European guidelines (S3) on diagnosis and management of mucous membrane pemphigoid, initiated by the European Academy of Dermatology and Venereology: Part I. *J Eur Acad Dermatol Venereol* 2021;35:1750-64.
3. Hayakawa T, Furumura M, Fukano H, Li X, Ishii N, Hamada T, et al. Diagnosis of oral mucous membrane pemphigoid by means of combined serologic testing. *Oral Surg Oral Med Oral Pathol Oral Radiol* 2014;117:483-96.
4. Bernard P, Antonicelli F, Bedane C, Joly P, Le Roux-Villet C, Duvert-Lehembre S, et al. Prevalence and clinical significance of anti-laminin 332 autoantibodies detected by a novel enzyme-linked immunosorbent assay in mucous membrane pemphigoid. *JAMA Dermatol* 2013;149:533-40.
5. Schmidt E, Rashid H, Marzano AV, Lamberts A, Di Zenzo G, Diercks GF, et al. European Guidelines (S3) on diagnosis and management of mucous membrane pemphigoid, initiated by the European Academy of Dermatology and Venereology: Part II. *J Eur Acad Dermatol Venereol* 2021;35:1926-48.