



Title	Surgical Treatment of dialysis-associated spondylosis
Author(s)	Baba, Hideo; Tagami, Atsushi; Adachi, Shinji; Hiura, Takeshi; Shindou, Hiroyuki
Citation	Acta Medica Nagasakiensia, 56(1), pp.5-11; 2011
Issue Date	2011-06
URL	http://hdl.handle.net/10069/25386
Right	

This document is downloaded at: 2020-09-18T04:01:27Z

Surgical Treatment of dialysis-associated spondylosis

Hideo BABA, Atsushi TAGAMI, Shinji ADACHI, Takeshi HIURA, Hiroyuki SHINDOU

Department of orthopaedic Surgery, Graduate School of Medicine, Nagasaki University, Nagasaki, Japan

【Objective】 The purposes of this study were to classify the lesions of dialysis-associated spondylosis and evaluate the results of surgical treatment.

【Subjects and methods】 The subjects were 87 patients (43 men and 44 women) who underwent surgery. These patients were studied in terms of lesion classification, surgical method, duration of dialysis, duration of surgery, intraoperative blood loss, and postoperative complications.

【Results】 Among patients with cervical spine involvement, 13 had destructive spondyloarthropathy (DSA), 29 had amyloid deposition, and 8 had a dens axis lesion. Among patients with lumbar spine involvement, 20 had DSA, and 17 had amyloid deposition.

With regard to 6 patients with a dens axis lesion involving atlantoaxial subluxation, each had posterior fusion (PF) of the occiput to the upper cervical spine. With regard to the patients with lumbar DSA, 10 patients had posterolateral fusion (PLF), 8 patients had posterior lumbar interbody fusion (PLIF) and 2 patients had laminectomy. The duration of dialysis in cases of a dens axis lesion varied between 25 and 35 years, with the mean duration being 28.9 years.

【Conclusions】 All patients who underwent surgery for dens axis lesions were long-term dialysis patients who had been on dialysis for ≥ 25 years. Lumbar spine DSA was treated with PLIF in patients with lateral slipping and marked instability, with laminectomy in patients with a narrowed intervertebral disk space and no instability.

ACTA MEDICA NAGASAKIENSIA 56: 5 - 11, 2011

Keywords: destructive spondyloarthropathy, amyloid deposition, dens axis lesion, spinal surgery, re-operation, infection

Introduction

Recent advances in hemodialysis have prolonged patient lifespan and increased the number of hemodialysis patients. However, the incidence of complications has increased. Destructive spondyloarthropathy (DSA) complicating chronic hemodialysis was defined by Kuntz et al.¹ for the first time in 1984. The cervical spine and lumbar spine are affected by long-term hemodialysis, which can cause dialysis-associated spondylosis.^{2,3} However, there are difficulties associated with spinal surgery because of such patients' poor general condition and poor bone quality.^{4,5,6} Dialysis-associated spondylosis can be divided into DSA, amyloid deposition,^{7,8}

and dens axis lesions.^{9,10} The purposes of this study were to classify the lesions of dialysis-associated spondylosis and evaluate the results of surgical treatment.

Subjects and methods

The subjects were 87 patients (43 men and 44 women) who underwent surgery in this hospital from 1981 onward and who could be observed for at least 6 months (including 4 patients who died within 6 months following surgery). The patients' ages at the time of surgery varied between 37 and 81 years (mean age, 61.1 years). The duration of dialysis

Address correspondence: Hideo Baba, M.D., Ph.D., Department of orthopaedic Surgery, Graduate School of Medicine, Nagasaki University, 1-7-1 Sakamoto, Nagasaki 852-8501, JAPAN

Tel: +81-(0)95-819-7321, Fax: +81-(0)95-849-7325, E-mail: hidbaba@nagasaki-u.ac.jp

Received December 14, 2010; Accepted March 7, 2011

varied between 1 and 32 years (mean duration, 17.1 years), and the duration of postoperative observation varied between 6 months and 12 years (mean duration, 3 years 5 months). Overall, 50 patients had cervical spine involvement, and 37 patients had lumbar spine involvement.

Four orthopedic surgeons (with over 5 years' experience as spine surgeons) classified the lesions as DSA, amyloid deposition, and dens axis lesions. These surgeons evaluated the radiographs and considered the presence of erosions and destruction of vertebrae, intervertebral disk space narrowing, and spondylolisthesis without apparent osteophyte formation as DSA.¹ Amyloid deposition was categorized as the absence of DSA findings, with thickening of the ligamentum flavum, intervertebral disk, and posterior longitudinal ligament visible on MRI, resulting in stenosis of the spinal canal and the appearance of symptoms, with amyloid deposition on tissue harvested during surgery. Dens axis lesion was categorized as pseudotumor due to amyloid deposition visible on MRI, sometimes involving atlantoaxial subluxation.

Patients with more than one of DSA, amyloid deposition or dens axis lesion simultaneously were categorized according to the most important cause of clinical symptoms at the time of onset.

Surgery was performed if spinal cord, cauda equina, or nerve root symptoms were present and no improvement occurred with conservative treatment. Anterior fusion (AF) was the first-choice treatment for cervical DSA. Patients with marked instability who had lost anteroposterior support underwent anteroposterior fusion (APF), whereas those with lesions extending across multiple spine for which long fusion was required underwent posterior fusion (PF). Patients with cervical amyloid deposition underwent decompression by means of laminoplasty, whereas those suffering from anterior pressure due to bulging of the intervertebral disk underwent AF. Patients with a dens axis lesion involving atlantoaxial subluxation underwent posterior decompression and fusion from the occipital bone to the upper cervical spine, whereas patients with only odontoid pseudotumor and no atlantoaxial subluxation underwent only surgical resection of the posterior arch of the atlas. Lumbar spine DSA was treated with posterior lumbar interbody fusion (PLIF) in patients with lateral slipping and marked instability, with laminectomy in patients with narrowed intervertebral disk space and no instability, and with posterolateral fusion (PLF) in the remaining patients. Laminectomy was performed in patients with lumbar amyloid deposition.

Spinal instability was defined as intervertebral instability with anteroposterior slipping over 4 mm or over 10° in the

dynamic image, or lateral slipping over 5 mm in the anteroposterior image.

These patients were studied in terms of lesion classification, surgical method, duration of dialysis, duration of surgery, intraoperative blood loss, and postoperative complications.

Results were statistically compared between lesion classification by t-test. Differences at P values of less than 0.05 were considered to be statistically significant.

Results

Among patients with cervical spine involvement, 13 had DSA, 29 had amyloid deposition, and 8 had a dens axis lesion. Among patients with lumbar spine involvement, 20 had DSA, and 17 had amyloid deposition.

With regard to the surgical method for patients with cervical DSA, 3 patients had APF, 3 patients had PF, and the other patients had AF. All patients with cervical amyloid deposition had laminoplasty, with the exception of a patient who had AF. With regard to 6 patients with a dens axis lesion involving atlantoaxial subluxation, each had PF of the occiput to the upper cervical spine, which was combined with laminoplasty of the middle to lower cervical spine in 4. Two patients with odontoid pseudotumor without atlantoaxial subluxation underwent only surgical resection of the posterior arch of the atlas. With regard to the patients with lumbar DSA, 10 patients had PLF, 8 patients had PLIF, and 2 patients had laminectomy. All patients with lumbar amyloid deposition underwent laminectomy. (Table 1)

With regard to the duration of dialysis, 12 patients had been on dialysis for 1-5 years, 12 patients for 6-10 years, 14 patients for 11-15 years, 16 patients for 16-20 years, 14 patients for 21-25 years, 13 patients for 26-30 years, and 6 patients for 31 years or more. With respect to the correlation between the lesion and the duration of dialysis, the means were as follows: 13.8 years for cervical DSA, 16.0 years for cervical amyloid deposition, 16.7 years for lumbar DSA, and 16.6 years for lumbar amyloid deposition, with no difference between DSA and amyloid deposition. However, the duration of dialysis in cases of a dens axis lesion varied between 25 and 35 years, with the mean duration being 28.9 years; all were long-term dialysis patients who had dedicated themselves to the treatment for 25 years or more. (Table 1) The duration of dialysis in cases of a dens axis lesion was significantly longer than the other lesions ($p < 0.05$). Six cases (75%) had a bone cyst of the odontoid process of the axis and 7 cases (88%) had a bone cyst of the

Table 1. Surgical results of dialysis-associated spondylosis AF: Anterior fusion, PF: posterior fusion, APF: anteroposterior fusion, PLF: posterolateral fusion, PLIF: posterior lumbar interbody fusion

Lesion classification	Cervical DSA (n=13)	Cervical amyloid deposition (n=29)	Dens axis lesion (n=8)	Lumbar DSA (n=20)	Lumbar amyloid deposition (n=17)
Surgical method (patients)	AF : 7 APF : 3 PF : 3	Laminoplasty : 28 AF : 1	PF : 6 Resection of the posterior arch : 2	PLF : 10 PLIF : 8 Laminectomy : 2	Laminectomy : 17
Mean duration of dialysis (years)	13.8 ± 5.3	16.0 ± 9.5	28.9 ± 3.0	16.7 ± 8.8	16.6 ± 10.2
Average intraoperative blood loss (g)	253 ± 241.2	320 ± 313.5	646 ± 521.9	639 ± 620.0	314 ± 291.9
Average duration of surgery	4 hours 42 minutes ± 102.2 minutes	2 hours 52 minutes ± 41.1 minutes	3 hours 44 minutes ± 82.0 minutes	4 hours 16 minutes ± 63.3 minutes	2 hours 22 minutes ± 38.9 minutes

atlas in 8 cases of dens axis lesion.

Average intraoperative blood loss was 413 g, and the average duration of surgery was 3 hours 27 minutes. For patients with cervical DSA, average intraoperative blood loss was 253 g, and average duration of surgery was 4 hours 42 minutes. For patients with cervical amyloid deposition, average intraoperative blood loss was 320 g, and average duration of surgery was 2 hours 52 minutes. For patients with a dens axis lesion, average intraoperative blood loss was 646 g, and average duration of surgery was 3 hours 44 minutes. For patients with lumbar DSA, average intraoperative blood loss was 639 g, and average duration of surgery was 4 hours 16 minutes. For patients with lumbar amyloid deposition, average intraoperative blood loss was 314 g, and average duration of surgery was 2 hours 22 minutes. (Table 1) Intraoperative blood loss was ≥ 1000 g in 6 patients: 2 with cervical amyloid deposition, 1 with a dens axis lesion, and 3 with lumbar DSA. Among both the cervical spine patients and the lumbar spine patients, there were cases of extremely severe bleeding, irrespective of duration of surgery and lesion.

There were 4 early deaths within 6 months following surgery: 1 patient with acute liver failure (died 2 days following surgery), 1 patient with heart failure (died 4 months following surgery), and 2 patients with methicillin-resistant *Staphylococcus aureus* (MRSA) infections at surgical site (died 2 months and 3.5 months following surgery). Of these 4 patients, 3 had lumbar DSA and 1 had cervical amyloid deposition. Surgery was of long duration (9 hours 25 minutes and 5 h 2 min) and blood loss was large (2885 g and 1230 g) in 2 of those who died.

Twenty patients (23%) underwent re-operation, including those who underwent instrumentation removal to eradicate deep infection. These included 5 patients with cervical DSA (38%), 4 with cervical amyloid deposition (14%), and

1 with a dens axis lesion (13%), as well as 5 patients with lumbar DSA (25%) and 5 with lumbar amyloid deposition (29%). Re-operation was performed as a result of the following: appearance of new diseases in 8 cases, reappearance of spinal amyloid deposition in 3 cases, adjacent level impairment in 3 cases, nonunion after fusion in 2 cases, epidural hematoma in 1 case, and deep infections in 3 cases. All deep infections occurred in patients with lumbar DSA.

Presentation of cases

Case 1 : A 55-year-old female patient on dialysis for 25 years (Figure 1)

This patient suffered from numbness in her fingers, gait disturbances, and movement disorders, which had gradually progressed to the point where she was unable to walk when she visited the hospital.

Everything was normal in the neutral and extension positions on radiography images of the cervical spine; however, a lateral radiography in the flexion position revealed anterior subluxation of the atlantoaxial joint. Magnetic resonance imaging (MRI) revealed an odontoid pseudotumor with apparent spinal cord compression at the atlas level. Furthermore, computed tomography (CT) myelography detected a bone cyst of the odontoid process¹¹, and the axial CT image also revealed a bone cyst of the atlas. There were no obvious abnormal findings in the middle to lower cervical spine on radiography; however, apparent spinal canal stenosis that resulted from thickening of the ligaments was detected on MRI and CT myelography.

Following a surgical resection of the posterior arch of the atlas, PF from the occipital bone to the axis and laminoplasty from C3-C7 were performed. The duration of surgery was

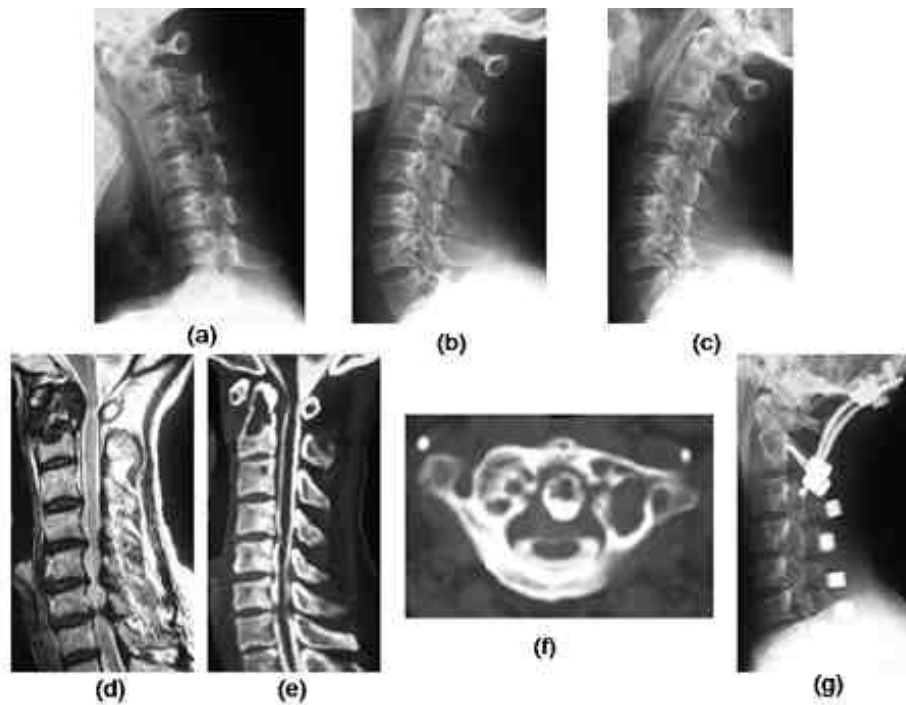


Fig. 1. (Case 1)

A 55-year-old female patient on dialysis for 25 years

Lateral radiography of cervical spine ; a) Flexion position, b) Neutral position, c) Extending position

MRI (T2 weighted images) ; d) Sagittal

CT myelography ; e) Sagittal, f) Axial (C1 level)

Post surgical radiography ; g) Lateral

MRI reveals an odontoid pseudotumor with apparent spinal cord compression at the atlas level. Furthermore, CT myelography detects a bone cyst of the odontoid process and the atlas. Spinal canal stenosis that results from thickening of the ligaments is detected on MRI and CT myelography.

4 hours 50 minutes, and the blood loss was 320 g. The post-operative course was good, with improvement in hand and finger movements, and the patient, who had been unable to walk, regained walking ability as of now, 6 years 7 months following surgery.

Case 2: A 54-year-old male patient on dialysis for 4 years. (Figure 2)

This patient started to suffer back pain 5 years prior to presentation. The back pain gradually worsened, and he started to experience weakness in both legs. When it became difficult for him to walk, he visited the hospital. The anteroposterior lumbar radiography showed apparent scoliosis, and MRI showed stenosis at L3/4. DSA at the site was evident on CT myelography.

PLF was performed on two intervertebral disc spaces, L3/4 and L4/5, combining PLIF using a carbon cage with pedicle screws. The duration of surgery was 4 hours 57 minutes, and the blood loss was 480 g. As of now, 5 years 2 months following surgery, the patient has made a satisfactory recovery.

Case 3: A 60-year-old female patient on dialysis for 13 years (Figure 3)

This patient started to suffer back pain 3 years before presentation. She started to experience pain in her right leg 2 months before presentation. Since it gradually worsened and she became unable to walk, she visited the hospital. While the radiography showed DSA and spondylolisthesis at L4/5, the dynamic image did not show instability.

Laminectomy was performed. The duration of surgery was 1 hour 57 minutes, and the bleeding volume was 60 g. Two years seven months have passed, and the patient has made a satisfactory recovery without showing any spinal instability.

Discussion

It is important to evaluate the lesions of DSA, spinal amyloid deposition, and dens axis lesions that result from dialysis-associated spondylosis in order to determine the optimal surgical method.

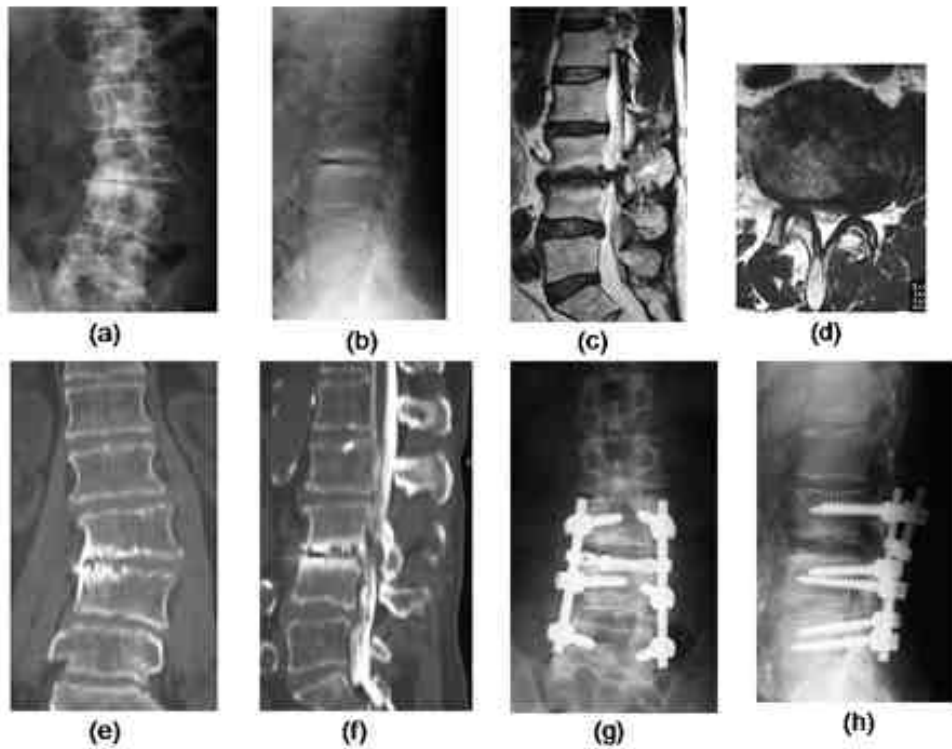


Fig. 2. (Case 2)

A 54-year-old male patient on dialysis for 4 years

Radiography of lumbar spine ; a) Anteroposterior, b) Lateral
MRI (T2 weighted images) ; c) Sagittal, d) Axial (L3/4 level)
CT myelography ; e) Coronal, f) Sagittal

Post surgical radiography ; g) Anteroposterior, h) Lateral

The anteroposterior lumbar radiography shows apparent scoliosis, and MRI shows stenosis at L3/4. DSA at the site is evident on CT myelography.

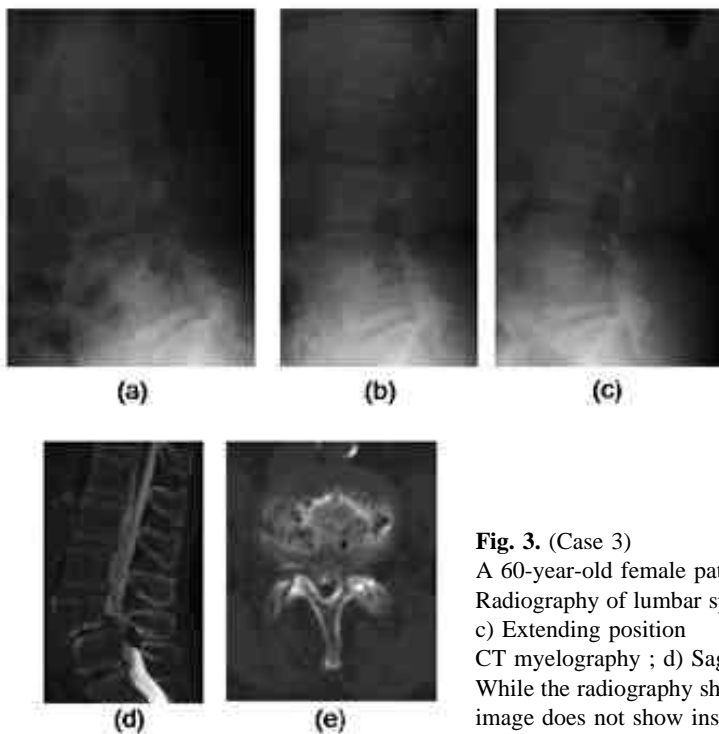


Fig. 3. (Case 3)

A 60-year-old female patient on dialysis for 13 years

Radiography of lumbar spine ; a) Lateral flexion position, b) Neutral position,
c) Extending position

CT myelography ; d) Sagittal, e) Axial (L4/5 level)

While the radiography shows DSA and spondylolisthesis at L4/5, the dynamic image does not show instability.

Case 1 was a patient with a dens axis lesion and middle to lower cervical amyloid deposition. Surgery was performed because of the presence of spinal cord symptoms induced by the dens axis lesion. Because the dens axis lesion involved atlantoaxial subluxation and a bone cyst of the atlas was also present, posterior fusion was performed from the occipital bone to the axis. Spinal canal stenosis due to amyloid deposition in the middle to lower cervical spine was also present, and laminoplasty was therefore performed. Case 2 was a patient who had lumbar DSA with marked instability. Surgery was performed because of the presence of advanced cauda equina neurological symptoms. PLIF was performed on two intervertebral disk spaces, L3/4 and L4/5, because of instability at those levels with lateral slipping. Case 3 was a patient with lumbar DSA with no instability. Surgery was performed because of the presence of advanced nerve root symptoms. DSA and anterior slippage were present at L4/5, but because dynamic imaging did not show instability, only laminectomy was performed.

Kato et al.¹² performed a surgical resection of the posterior arch of the atlas and transarticular screw fixation (Magerl technique)¹³ as the surgical treatment for dens axis lesions in dialysis patients and reported a positive outcome. On the other hand, we performed fusion of the occipital bone on all patients with dens axis lesions involving atlantoaxial subluxation. This is because patients with dens axis lesions are long-term dialysis patients who have dedicated themselves to the treatment for 25 years or more, and also because, in addition to a bone cyst of the odontoid process of the axis,¹¹ similar findings may be observed in the atlas, as was seen in Case 1. Seven cases (88%) had a bone cyst of the atlas in 8 cases of dens axis lesion. Occipitocervical fusion is most frequently selected in such cases in the belief that the transarticular screw fixation (Magerl technique) may not provide sufficient screw fixation of the atlas.

The blood loss in dialysis patients varies widely, irrespective of surgical method and on a case-by-case basis. Causes of the tendency to bleed in dialysis patients include the following: low platelet count, platelet dysfunction, capillary fragility, severe anemia, drug-related, and increased prostaglandin E2 synthesis in the vessel wall.¹⁴ However, no such abnormalities are detected on pre-operative testing. Therefore, a tendency to bleed may be observed only at the time of surgery, and it is therefore necessary to deal with the situation flexibly by, for example, changing the surgical method depending on the bleeding volume.

Because lumbar DSA involves spinal instability (Radiography showed lateral slipping and scoliosis.), as was shown in

Case 2, PLIF or PLF performed. We had 3 lumbar DSA patients who developed MRSA infections following surgery, and 2 of them died. If there is no instability (The dynamic image did not show instability.), performing laminectomy alone causes no problems even in cases of DSA (Figure 3). The spinal instability and general condition should be thoroughly reviewed prior to surgery to identify whether PLIF should also be performed, whether PLF is possible, or whether laminectomy is difficult, and to decide the surgical approach.

The rate of re-operation was high, with 20 patients (23%) undergoing re-operation. The lesion varied, including the following: appearance of new diseases, reappearance of spinal amyloid deposition, and adjacent level impairment. As was seen in Case 2, DSA may not be detected by single radiography. In each case, the lesion should be thoroughly identified, and the surgical approach should be reviewed prior to surgery. In particular, it is necessary to pay attention to two issues: whether DSA exists in cases of spinal amyloid deposition where laminectomy is to be performed; and whether spinal instability between adjacent level impairment is detected when performing spinal fusion for DSA. This is because, in these cases, re-operation could be prevented by selecting fusion as the surgical approach or by extending the extent of fusion.

Conclusion

1. All patients who underwent surgery for dens axis lesions were long-term dialysis patients who had been on dialysis for ≥ 25 years.
2. Lumbar spine DSA was treated with PLIF in patients with lateral slipping and marked instability, with laminectomy in patients with a narrowed intervertebral disk space and no instability, and with PLF in the remaining patients.

References

1. Kuntz D, Naveau B, Bardin T, Drueke T, Treves R, Dryll A. Destructive spondylarthropathy in hemodialyzed patients. A new syndrome. *Arthritis Rheum* 27:369-375,1984.
2. Bind P, Lavaud S, Bermieh B, Toupance O, Chanard J. Early and late occurrences of destructive spondyloarthropathy in haemodialysed patients. *Nephrol Dial Transplant* 5:199-203,1990
3. Davidson GS, Montanera WJ, Fleming JF, Gentili F. Amyloid destructive spondyloarthropathy causing cord compression: related to chronic renal failure and dialysis. *Neurosurgery* 33:519-522,1993
4. Suto H, Ito M, Abumi K et al. Long-term follow up of surgical outcomes in patients with cervical disorders undergoing hemodialysis. *J Neurosurg Spine* 5:313-319,2006

5. Van Driessche S, Goutallier D, Odents T et al. Surgical treatments of destructive cervical spondyloarthropathy with neurologic impairment in hemodialysis patients. *Spine* 31:705-711,2006
6. kumar A, Leventhal MR, Freedman EL, Coburn J, Delamarter R. Destructive spondyloarthropathy of the cervical spine in patients with chronic renal failure. *Spine* 22:573-577,1997
7. Maruyama H, Gejyo F, Arakawa M. Clinical studies of destructive spondyloarthropathy in long-term hemodialysis patients. *Nephron* 61:37-44,1992
8. Sebert JL, Fardellone P, Deramond H et al. Destructive spondyloarthropathy with amyloid deposits in 3 patients on chronic hemodialysis. *Rev Rhum Mal Osteoartic* 53:459-465,1986
9. Maruyama H, Tanizawa T, Uchiyama S et al. Magnetic resonance imaging of pseudotumors of the craniovertebral junction in long-term hemodialysis patients. *Am J Nephrol* 19:541-545,1999
10. Amoroso E, Vitale C, Silvestro A. Spinal-cord compression due to extradural amyloidosis of the cervico-occipital line, in a hemodialysis patient. A case report. *J Neurosurg Sci* 45:120-124,2001
11. Rousselin B, Helenon O, Zingraff J et al. Pseudotumor of the craniocervical junction during long-term hemodialysis. *Arthritis Rheum* 33 (10):1567-1573,1990.
12. Kato Y, Kanayama K, Itoh T. Destructive spondyloarthropathy of the atlantoaxial joint with severe spinal cord compression in long-term hemodialysis patients. *J Orthop Sci* 11:644-650,2006
13. Magerl F, Seeman PS. Stable posterior fusion of the atlas and axis by transarticular screw fixation. Kehr P, Weidner A, editors, *Cervical Spine I*. New York Springer-Verlag.:322-327,1987
14. Kato Y. Present conditions of renal dialysis in Japan and surgical problems for patients with spinal disorders in renal dialysis (in Japanese). *J Japanese spine Res Soc* 16:461-471,2005

