



Title	Spontaneous Closure of a Rectovaginal Fistula that Developed after Double-stapled Anastomosis in Low Anterior Resection
Author(s)	Nakagoe, Tohru; Sawai, Terumitsu; Tsuji, Takashi; Tanaka, Kenji; Hidaka, Shigekazu; Nanashima, Atsushi; Shibasaki, Shin-Ichi; Yamaguchi, Hiroyuki; Yasutake, Tohru
Citation	Acta medica Nagasakiensia. 2003, 48(1-2), p.81-84
Issue Date	2003-06-25
URL	<a href="http://hdl.handle.net/10069/16249">http://hdl.handle.net/10069/16249</a>
Right	

This document is downloaded at: 2020-09-17T19:20:02Z

## Case Report

# Spontaneous Closure of a Rectovaginal Fistula that Developed after Double-stapled Anastomosis in Low Anterior Resection

Tohru NAKAGOE, Terumitsu SAWAI, Takashi TSUJI, Kenji TANAKA, Shigekazu HIDAHA, Atsushi NANASHIMA, Shin-ichi SHIBASAKI, Hiroyuki YAMAGUCHI, Tohru YASUTAKE

First Department of Surgery, Nagasaki University School of Medicine

**Management of a rectovaginal fistula (RVF) following low circular-stapled colorectal anastomosis is difficult and often unsatisfactory. We report herein the case of a 66-year-old woman who developed a RVF following low anterior resection using the double-stapling technique for rectal cancer. The RVF spontaneously closed with nonoperative treatment that included simple observation without dietary restrictions. The spontaneous closure occurred within approximately 25 days. Minimally symptomatic patients may be candidates for nonoperative treatment.**

ACTA MEDICA NAGASAKIENSIA 48 : 81–84, 2003

**Key Words:** rectovaginal fistula, spontaneous closure, rectal cancer, low anterior resection, double-stapling technique

## Introduction

Rectovaginal fistula (RVF) following low circular-stapled colorectal anastomosis has been reported,<sup>1</sup> albeit with incidence rates as low as 2.9%,<sup>2</sup> 2.2%,<sup>3</sup> or 1.0%.<sup>4</sup> The RVF, which leads to vaginal flatus, fecal leakage, and/or vaginal discharge, is an extremely uncomfortable complication. The management of RVF is difficult and often unsatisfactory.<sup>1-7</sup> Many surgeons believe that active operative treatment seems to be the most effective treatment.<sup>2,5-7</sup> There have been few reports on the successful closure of such RVFs with nonoperative treatments.<sup>1,7,8</sup> We report herein a case of patient who developed a RVF following low anterior resection using the double-stapling technique for rectal cancer that was successfully treated with the nonoperative treatment

of simple observation without dietary restrictions.

## Case report

A 66-year-old woman was admitted to our hospital on July 11, 2000 with a chief complaint of hematochezia and constipation that had lasted for approximately 6 months. Her past medical history included an ectopic pregnancy (with emergency laparotomy) and viral hepatitis C at 28 years of age. She had also undergone an emergency laparotomy at age 43 for adhesive intestinal obstruction caused by prior laparotomy.

On admission, physical examination of the abdomen revealed no abnormal findings except for a laparotomy scar. Abnormal findings of laboratory tests included elevated serum levels of CA19-9 (133.8 U/mL; normal range <37 U/mL), whereas serum level of carcinoembryonic antigen (CEA) was within the normal range (4.4 ng/mL; normal range <5.0 ng/mL). Anti-HCV was positive. Laboratory tests also revealed liver dysfunction that included elevated serum levels of AST (317 IU/L; normal range, 13-33 IU/L), ALT (163 IU/L; normal range, 8-42 IU/L), thymol turbidity test (TTT; 10.5 U; normal range, 0-4.0 U), zinc sulfate turbidity test (ZTT; 14.2 U; normal range, 4.0-12.0 U), and low albuminemia (3.8 g/dL, normal range, 4.0-5.0 g/dL). The abnormal findings were compatible with chronic hepatitis C.

Colonoscopy showed an ulcerating tumor of the rectum. The lower edge of the tumor was located 6 cm from the dentate line. The tumor approximately encompassed the entire circumference of the bowel. The colonoscopic biopsy showed an adenocarcinoma. Barium enema revealed the tumor of the rectum, but there was no evidence of multiple tumors in other sites of the colon. Abdominal computed tomography (CT) demonstrated no metastasis to the liver or para-aortic lymph nodes, but there were a couple of small nodules in the mesorectum that were considered lymph node metas-

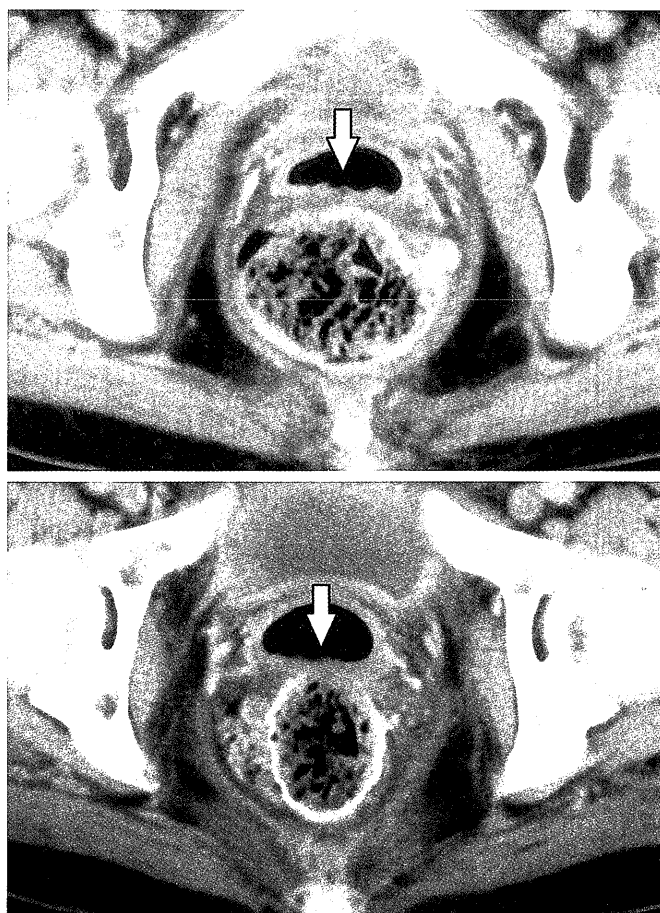
**Address Correspondence:** Tohru Nakagoe, M.D.  
First Department of Surgery, Nagasaki University School of Medicine, 1-7-1 Sakamoto, Nagasaki, 852-8501 Japan  
TEL: +81-95-849-7304 FAX: +81-95-849-7306  
E-mail: nakagoe@net.nagasaki-u.ac.jp

tases.

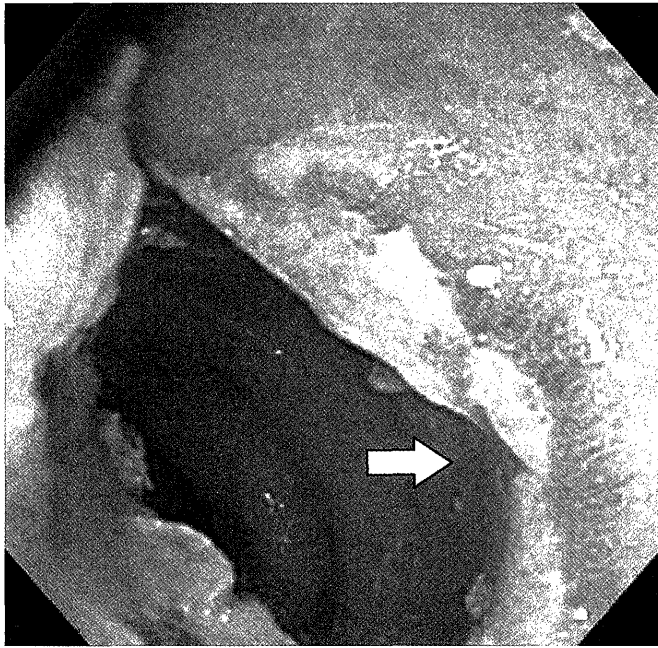
Under the diagnosis of rectal cancer, low anterior resection using the double-stapling technique<sup>9</sup> was performed on August 1, 2000. Lymph nodes at the root of the inferior mesenteric artery were removed and the superior hemorrhoidal artery was divided, preserving the left colic artery. The entire mesorectum was mobilized to the pelvic floor in the avascular plane via sharp dissection. Lateral lymph node dissection with autonomic nerve preservation<sup>10</sup> was performed. The rectum was dissected free of the posterior wall of the vagina. The TA55<sup>®</sup> stapler (US Surgical Corp., Norwalk, CT) was used to divide the distal rectum, which was 4 cm below the cancer. The anastomosis was constructed approximately 2 cm above the dentate line using the premium CEEA<sup>®</sup>31 stapler (US Surgical Corp.). The premium CEEA<sup>®</sup> stapler was closed and fired so that the posterior wall of the vagina was not included in the premium CEEA<sup>®</sup> stapler anastomosis. When the premium CEEA<sup>®</sup> stapler was disengaged from the anastomosis and extracted per anum, the perineal operator felt that the premium CEEA<sup>®</sup> stapler got caught in the anterior wall of the anastomotic portion of the rectum. However, we confirmed completeness of the rectal tissue ring (so-called 'doughnut') by means of inspection. We also checked the integrity of the anastomosis by insufflation of saline solution into the rectum and subsequently confirmed there was no leakage of saline solution within the stapled anastomosis. No diverting colostomy was performed.

The resected specimen revealed an ulcerating tumor of the rectum (maximal diameter, 7.0 cm) with 4.0 cm of distal resection margin. The histological report showed a well-differentiated adenocarcinoma with Dukes C stage (tumor invaded to non-peritonealized, perirectal tissues, presence of lymph node metastasis, presence of lymphatic and venous invasion, no liver metastasis, and no peritoneal dissemination). The patient had an uneventful course until the 11th postoperative day (August 12, 2000) when the patient presented with vaginal flatus and fecal leakage. By vaginoscopy with rectal digital examination, there was a well-circumscribed 7 mm hole through the rectal-vaginal septum 3.5 cm from the level of the introitus vagina. No tumor was present. Staples were palpable just beneath the vaginal mucosa within the fistula. A fistulogram was not conducted because the patient denied consent. Pelvic CT showed a collection of air in the vagina and also showed a deformed, thin posterior wall of the vagina at exactly the same level of the stapled anastomosis portion, which was considered a RVF (Fig. 1). The patient had no fever and laboratory tests also showed no inflammatory changes. The patient felt that the

amount of vaginal flatus and fecal leakage were tolerable. Therefore, under the patient's informed consent, the patient was conservatively treated with nonoperative therapy such as simple observation without dietary restrictions. Fortunately, the amount of the vaginal flatus and fecal leakage gradually decreased after August 17, 2000 (16th postoperative day), and completely disappeared on September 6, 2000 (36th postoperative day). Closure of the rectovaginal fistula was confirmed by vaginoscopy with rectal digital examination and colonoscopy (Fig. 2). During the postoperative period, the patient received no local therapy such as fibrin glue or blood coagulation factor XIII, which accelerates wound healing. Of note, the patient did not receive pre- and/or post-operative radiotherapy. The patient was discharged from the hospital on September 22, 2000 (52nd postoperative day). Upon this writing (April 20, 2002), the patient is and disease-free. In addition, the patient has not had any signs or symptoms of the RVF during the 20.3 months of follow-up.



**Figure 1** Pelvic CT showed a deformed, thin posterior wall of the vagina at exactly the same level of the stapled anastomosis portion, which was considered a rectovaginal fistula (arrow). Collection of air in the vagina was observed. Anastomosis included staples.



**Figure 2** On the 42nd postoperative day, closure of the rectovaginal fistula was confirmed by colonoscopy. Arrow indicates the scar of the rectovaginal fistula within the stapled anastomosis.

## Discussion

Many surgeons believe that the posterior wall of the vagina may be included in the circular stapled anastomosis when describing the etiology of RVF after circular-stapled low anterior resection.<sup>1,5,11</sup> In the current case, we confirmed by visualization during the operation that the posterior wall of the vagina was not included in the circular-stapled anastomosis. However, when the circular stapler was extracted per anum, the perineal operator felt that the circular stapler got caught in the anterior wall of the anastomotic portion of the rectum. Therefore, RVF may have resulted from several factors including minor leakage of the anterior portion of the colorectal anastomosis, consequent abscess formation and spontaneous drainage of the abscess through the devascularized vagina. We believe that that the surgical technique involved in the circular stapled anastomosis may have been an important factor in the etiology of this complication.<sup>5,11</sup>

We previously reported the cases of 4 patients who developed RVF after double-stapled anastomosis in low anterior resection. These were successfully repaired surgically via a transvaginal approach.<sup>2</sup> Although 2 of the 4 patients in that series had been conservatively treated using total parenteral hyperalimentation with bowel rest for over 30 days, spontaneous closure had failed and operative treatment had become necessary.<sup>2</sup>

At that time, we had believed that operative treatment seemed to be the most reliable, effective treatment to cure such RVF. We describe, in the current report, our first experience of a patient with RVF that was successfully treated nonoperatively.

Few studies on successful closure with nonoperative treatment for such RVFs have been reported.<sup>1,7,8,12,13</sup> In order to clarify the incidence and management of RVF following low anterior resection, questionnaires obtained from active members of the American Society of Colon and Rectal Surgeons revealed the following: a total of 57 patients were reported to have postoperative RVF; of these, 53 had circular-stapled anastomosis; 14 were managed nonoperatively (simple observation, parenteral hyperalimentation with bowel rest, or low-residue diets and antibiotics); and 39 were managed operatively; successful closure was obtained in 10 of 14 patients who were treated nonoperatively. In addition, surprisingly, some patients were treated successfully with low-residue diets and antibiotics. Ochiai et al.<sup>8</sup> reported that successful closure of a RVF was obtained with bowel rest and administration of blood coagulation factor XIII, which accelerates wound healing.

In general, bowel rest and nutritional support (total parenteral nutrition) undoubtedly provided a favorable environment for tissue granulation and healing of the intestinal fistula.<sup>14</sup> Also, it has been agreed that healing of the fistula was primarily related to local anatomical conditions.<sup>14</sup> An increase of pressure and amount of stool within the rectum may be an obstacle to spontaneous healing of RVF. The current patient had smooth evacuation because there was not an anastomotic stricture. These conditions might have favored spontaneous closure of the RVF, although its definite mechanism remains unclear.

Once a RVF occurs, management must be individualized.<sup>1</sup> Now, we feel that patient selection for nonoperative treatment may be difficult. Rex and Khubchandani reported that observation with low-residue diets, antibiotics, or bowel rest may be attempted with a high success rate in the minimally symptomatic patient. For the patient in this current report, early decrease in the amount of vaginal flatus and vaginal fecal leakage occurred (on 5th day from onset of RVF). Therefore, such patients may be candidates for nonoperative treatment, although this is inconclusive because of the relative paucity of patients reported.

## References

1. Rex Jr. JC, Khubchandani IT: Rectovaginal fistula: complication of low anterior resection. *Dis Colon Rectum* 35: 354-356, 1992
2. Nakagoe T, Sawai T, Tuji T, et al: Successful transvaginal repair

- of a rectovaginal fistula developing after double-stapled anastomosis in low anterior resection: report of four cases. *Surg Today* 29: 443-445, 1999
3. Antonsen HK, Kronborg O: Early complications after low anterior resection for rectal cancer using the EEA stapling device. A prospective trial. *Dis Colon Rectum* 30: 579-583, 1987
  4. Baran JJ, Goldstein SD, Resnik AM: The double-staple technique in colorectal anastomoses: a critical review. *Am Surg* 58: 270-272, 1992
  5. Sugarbaker PH: Rectovaginal fistula following low circular stapled anastomosis in women with rectal cancer. *J Surg Oncol* 61: 155-158, 1996
  6. Bauer JJ, Sher ME, Jaffin H, Present D, Gelerent I: Transvaginal approach for repair of rectovaginal fistulae complicating Crohn's disease. *Ann Surg* 213: 151-158, 1991
  7. Fleshner PR, Schoetz DJ, Roberts PL, et al: Anastomotic-vaginal fistula after colorectal surgery. *Dis Colon Rectum* 35: 938-943, 1992
  8. Ochiai T, Moriwaki M, Shigematu Y, et al: A case of rectovaginal fistula after low anterior resection by double stapling technique who was cured by conservative treatment. *J Jpn Soc Coloproctol* 46: 368-373, 1993
  9. Cohen Z, Myers E, Langer B, et al: Double stapling technique for low anterior resection. *Dis Colon Rectum* 26: 231-235, 1983
  10. Moriya Y, Sugihara K, Akasu T, Fujita S: Nerve-sparing surgery with lateral node dissection for advanced lower rectal cancer. *Eur J Cancer* 31: 1229-1232, 1995
  11. Nakagoe T, Sawai T, Tsuji T, et al: Avoidance of rectovaginal fistula as a complication after low anterior resection for rectal cancer using a double-stapling technique. *J Surg Oncol* 71: 196-197, 1999
  12. Eden TW: A case of superior recto-vaginal fistula dealt with by the abdominal route after preliminary colostomy. *J Obstet Gynecol Br Commonw* 26: 175-185, 1914
  13. Antonsen HK, Kronborg O: Early complications after low anterior resection for rectal cancer using the EEA stapling device. A prospective trial. *Dis Colon rectum* 30: 579-583, 1987
  14. Levy E, Frileux P, Cugnenc PH, et al: High-output external fistulae of the small bowel: management with continuous enteral nutrition. *Br J Surg* 76: 676-679, 1989