



|            |  |
|------------|--|
| Title      | Two Cases of Multiple Carcinoid Tumors and Gastric Enterochromaffin-like Cell Hyperplasia, Dysplasia and Neoplasia in Type A Gastritis                             |
| Author(s)  | Alipov, Gabit; Nakashima, Masahiro; Nakayama, Toshiyuki; Fukuda, Eiichiro; Niino, Daisuke; Fukuda, Hirotoishi; Yamada, Masafumi; Kishikawa, Hiroki; Sekine, Ichiro |
| Citation   | Acta medica Nagasakiensia. 2002, 47(3-4), p.171-175  |
| Issue Date | 2002-12-17   |
| URL        | <a href="http://hdl.handle.net/10069/16231">http://hdl.handle.net/10069/16231</a>  |
| Right      |  |

This document is downloaded at: 2020-09-17T19:18:10Z

## Case Report

# Two Cases of Multiple Carcinoid Tumors and Gastric Enterochromaffin-like Cell Hyperplasia, Dysplasia and Neoplasia in Type A Gastritis

Gabit ALIPOV<sup>1)</sup>, Masahiro NAKASHIMA<sup>1)</sup>, Toshiyuki NAKAYAMA<sup>2)</sup>, Eiichiro FUKUDA<sup>2)</sup>, Daisuke NIINO<sup>2)</sup>, Hirotooshi FUKUDA<sup>3)</sup>, Masafumi YAMADA<sup>4)</sup>, Hiroki KISHIKAWA<sup>4)</sup>, Ichiro SEKINE<sup>1), 2)</sup>

1) Tissue and Histopathology Section, Division of Scientific Data Registry, Atomic Bomb Disease Institute, Nagasaki University School of Medicine

2) Department of Molecular Pathology, Atomic Bomb Disease Institute, Nagasaki University School of Medicine, Nagasaki, Japan

3) Department of Surgery, Inoue Hospital

4) Department of Surgery, Koseikai Hospital

**We describe two cases of multiple carcinoids and hyperplasia, dysplasia and neoplasia of enterochromaffin-like (ECL) cells associated with atrophic gastritis type A in the stomach. Multiple polypoid lesions measuring 1 cm showed upper gastroendoscopic features. They were all found in the upper body of the stomach. All polypoid lesions with carcinoid foci were observed from the deeper layers of the propria mucosa to the submucosa and were surrounded by ECL cells. In one case, the serum gastrin level which was as high as 1700 pg/ml, returned to normal range (17 pg/ml) after gastrectomy. It is suggested that longstanding hypergastrinemia may have played a causative role in the development of multiple gastric carcinoid tumors. A total gastrectomy was considered essential for treatment of aggressive multiple carcinoid tumors with hypergastrinemia.**

ACTA MEDICA NAGASAKIENSIA 47 : 171–175, 2002

**Key words:** gastric carcinoid, enterochromaffin-like (ECL) cells, type A gastritis

## Introduction

Carcinoid tumors are traditionally divided into endocrine growths originating from foregut, midgut and

hindgut<sup>1)</sup>. Foregut carcinoids, encompassing bronchial, gastric, and duodenal carcinoids, may cause an atypical carcinoid syndrome with severe generalized flush, diarrhea, cutaneous edema, lacrimation, and bronchoconstriction. Three main variants of human gastric carcinoid tumors have been identified: types 1, 2 and 3<sup>2,8)</sup>. Type 1 gastric carcinoids originate from the mucosal ECL cells which can synthesize and store histamine. These tumors are localized to the fundus, are mainly multiple, and are associated with type A gastritis. The pathogenesis of these tumors is claimed to be the trophic effect of the hypergastrinemia on the ECL cells in the fundus<sup>9-11)</sup>. Gastric carcinoid tumors associated with gastritis type A are usually small (less than 1 cm), may be single or multiple, and rarely progress to metastatic disease<sup>12-14)</sup>. We report here on two cases of gastritis type A with multiple carcinoid tumors which were observed post-gastrectomy.

## Case report

### Patient 1

Patient 1 was a 51 year old male who had been diagnosed with diabetes mellitus 11 years ago and had lost 20 kg of weight during the last 2 months. Gastric endoscopy confirmed multiple 1 cm gastric polyps within the body of the stomach. Histological examination of the gastric mucosal biopsies of the corpus and fundus showed atrophic gastritis with focal intestinal metaplasia. Biopsies of the gastric polyps were consistent with the multiple carcinoid lesions in the body of

**Address Correspondence:** Gabit Alipov, M.D.  
Tissue and Histopathology Section, Division of Scientific Data Registry, Atomic Bomb Disease Institute, Nagasaki University School of Medicine  
1-12-4 Sakamoto, Nagasaki 852-8523, Japan  
TEL: +81-95-849-7124 FAX: +81-95-849-7130  
E-mail: a-gabit@net.nagasaki-u.ac.jp

the stomach. Laboratory data are shown in Table 1. Total gastrectomy was performed because gastric carcinoid tumors showed infiltrative growth of ECL cells to the submucosa and lymph vessel invasion. In the corpus and fundus a total of 36 carcinoid lesions were found, ranging in size from 0.1 to 8.0 mm.

**Table 1.** Laboratory results of Cases 1 and 2.

| Laboratory results     | Case 1                                | Case 2                                |
|------------------------|---------------------------------------|---------------------------------------|
| WBC                    | 7200/mm <sup>3</sup>                  | 2770/mm <sup>3</sup>                  |
| RBC                    | 386mm <sup>3</sup>                    | 288mm <sup>3</sup>                    |
| Hb                     | 11.5g/dl                              | 9.7g/dl                               |
| Ht                     | 33.8%                                 | 26.2 %                                |
| Plate                  | 28.0×10 <sup>4</sup> /mm <sup>3</sup> | 15.0×10 <sup>4</sup> /mm <sup>3</sup> |
| Parietal cell antibody | (+)                                   | ND                                    |
| LDH                    | 161 IU/l                              | 456 IU/l                              |
| Gastrin                | 1700pg/ml                             | ND                                    |
| Serotonin              | 66ng/ml                               | ND                                    |
| Urine5-HIAA            | 1.9mg/day                             | ND                                    |
| CEA                    | ND                                    | 2.2mg/ml                              |
| CA15-3                 | ND                                    | 17 U/ml                               |

ND; not done

### Patient 2

Patient 2 was a 50 year old female who had a mastectomy for stage IIIa left breast cancer. Six months later she complained of epigastric discomfort. Gastric examination showed multiple gastric polyps in the body of the stomach. Biopsies suspected poorly differentiated adenocarcinoma in the body of the stomach. Multiple carcinoid tumors were confirmed in histological and immunohistochemical studies following total gastrectomy. Thirty-one multiple carcinoid lesions ranging in size from 0.1 to 7.4 mm were found focal histologically investigated specimens of the stomach.

### Material and Methods

The resected stomachs were fixed in 10% neutral buffered formalin and then examined in serial cross-sections. The tissue blocks were dehydrated and routinely embedded in paraffin. Sections of 3-micron

thickness were cut and stained with hematoxylin and eosin, Periodic acid-Schiff (PAS) and Grimelius and Fontana-Masson stains.

For immunohistochemistry, the standard avidin-biotin-peroxidase immune complex method was employed with a Vectastain ABC Kit (Vector Laboratories, Burlingame, CA) on the formalin fixed and paraffin embedded tissue sections. Immunohistochemical staining was performed using antibodies against the following: Chromogranin A, gastrin, serotonin, somatostatin, and synaptophysin.

### Morphological examination

In both cases the fundic regions showed an atrophic change associated with a proliferation of mucous cells and moderate degree of intestinal metaplasia. ECL cells separated from the atrophic fundic glands or carcinoids were detected in the deep lamina propria, muscularis mucosa, or submucosa of the fundic regions showing the atrophic changes. A total of sixty-seven lesions of ECL cell hyperplasia or Endocrine cell micronest (ECM) and distinct microcarcinoids, ranging in size from 0.1 to 8.0 mm in size (36 in Case 1 and 31 in Case 2) were detected.

Of the 36 lesions in Case 1 of the ECL cells and microcarcinoids measuring from 0.1 to 8.0 mm in diameter (average 1.4 mm), there were 25 lesions from 0.1 to 8.0 mm (average 1.7 mm) in the mucosa, and 11 lesions from 0.1 to 6.0 mm (average 1.0 mm) in the submucosa.

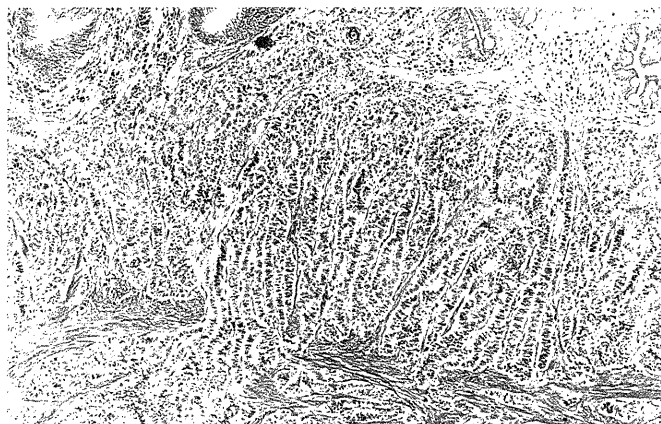
In Case 2, the 31 lesions of the ECL cells and microcarcinoids measuring from 0.1 to 7.4 mm in diameter (average 0.94 mm) were found only in the mucosa of the stomach corpus.

Morphologically, of the 36 ECL or ECM and carcinoids, 14 (39%) showed trabecular or ribbon-like structures (Fig. 1A) and 22 (61%) had solid, anastomosing trabecular, ribbon-like, glandular and/or acinar structures with fibrovascular stroma (Fig. 1B). There were various degrees of large cells with large atypical nuclei, which were about twice the size of lymphocyte nuclei. Carcinoid tumors showed an expansive growth and a conspicuous infiltration into the muscularis mucosae and submucosa. They often showed a perivascular arrangement and focal infiltration of lymphatic vessels.

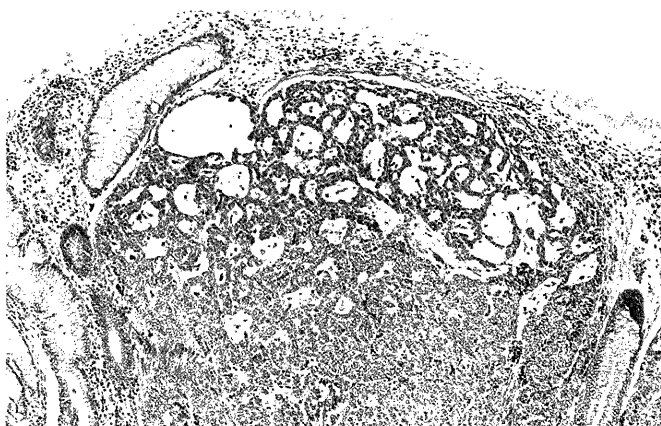
In both cases all carcinoid tumors were positive for argyrophil and argentaffin with Grimelius and Fontana-Masson silver stains.

### Immunohistochemistry

The immunohistochemical findings of carcinoid tumors are summarized in Table 2. All carcinoid lesions



**Figure 1. (A)** Carcinoid tumors illustrating a trabecular or alveolar pattern with ribbon-like structures. Tumors are comprised of small, round cells with single and round-to-oval nuclei in case 1.

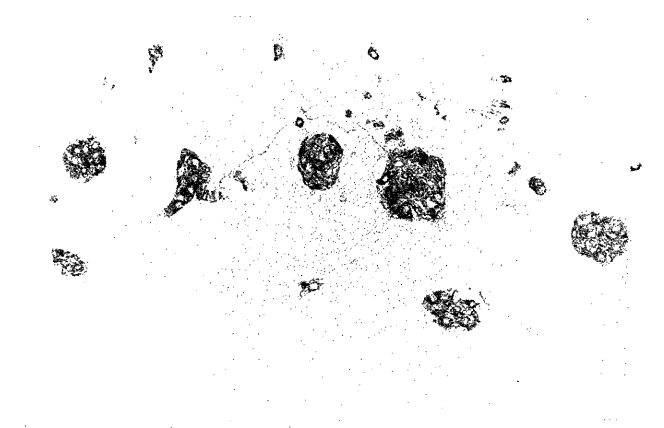


**Figure 1. (B)** Carcinoid showing an expansive growth and solid, anastomosing trabecular structure with a fibrovascular stroma, composed of large, atypical cells intermingled with small cells in case 2 (H&E; A, magnification x80; B, magnification x80).


**Table 2.** Immunohistochemical results on carcinoid tumors.

| Immunohistochemical results | Case 1 | Case 2 |
|-----------------------------|--------|--------|
| Chromogranin A              | +      | +      |
| Neuron-specific enolase     | +      | +      |
| Gastrin                     | -      | -      |
| Serotonin                   | +      | +      |
| Somatostatin                | +      | -      |
| Synaptophysin               | +      | +      |

showed diffuse positivity for Chromogranin A (Fig. 2A). In the antral region, there was a diffuse intraglandular increase in the number of gastrin positive cells in the middle zone of the pyloric glands (Fig. 2B). Synaptophysin and serotonin were scattered positive in carcinoid tumors.



**Figure 2. (A)** Hyperplastic chromogranin A-positive endocrine cells from lines in a focus of mucous neck hyperplasia and numerous micronodules in the deep lamina propria.



**Figure 2. (B)** Proliferation of gastrin positive cells in the antral region. Scattered gastrin positive cells are present even in the foveolar epithelium (A, magnification x80; B, magnification x80).

**Discussion**

Gastric carcinoids compose only 0.3% of all gastric tumors and 2.2% of all carcinoid tumors<sup>15</sup>. Gastric carcinoids are derived from ECL cells present in the body of the stomach<sup>16</sup>. In patients with or without pernicious anemia, antral G cells secrete enormous quantities of gastrin in response to achlorhydria resulting in proliferation of ECL cells<sup>10,16,17</sup>. The spectrum of these proliferative changes include hyperplasia,

dysplasia, and neoplasia<sup>18</sup>.

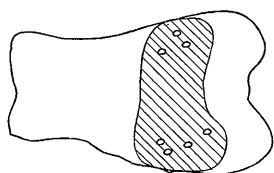
Although the preoperative clinical examinations indicated hypergastrinemia in the two cases presented here, the histological and immunohistochemical findings were consistent with the characteristics of gastric carcinoid tumors comprised of argyrophilic cells. In the rat, hypergastrinemia by itself has been reported to stimulate the development of gastric argyrophilic or ECL cell carcinoid tumors<sup>19</sup>. However, in patients with Zollinger-Ellison syndrome (ZES), hypergastrinemia simply leads to a proliferation of argyrophilic or ECL cells within the confines of the fundic mucosa<sup>20</sup>. In the current cases, there was no history of diarrhea, symptoms of carcinoid syndrome and ZES, evidence of multiple endocrine neoplasia type 1 (MEN-1), or pernicious anemia.

Autoimmune diseases such as hypothyroidism and diabetes mellitus may coexist with gastric multiple carcinoid tumors. Clinical management is still undefined<sup>21</sup>. In the current study, ECL cell hyperplasia or ECM nodules were localized in the lower third of the mucosa and showed scattered staining for the hormone serotonin but none for gastrin. However, in the 25 carcinoid lesions observed in this study, each carcinoid was accompanied by a large number of pe-

ripheral ECL cells or ECM, which usually were present adjacent to proliferating argyrophilic cells in multifocal pyloric gland metaplasia of atrophic gastritis. Thus, the origin and development of multiple gastric carcinoid tumors and ECM may be due to the proliferating argyrophilic cells in multifocal pyloric gland metaplasia, which in turn is caused by atrophic gastritis as well as to the trophic action of excess gastrin in the serum.

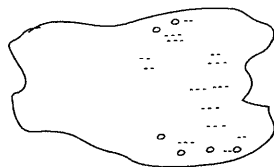
The finding of diffuse ECL cell hyperplasia or ECM within pseudopyloric metaplasia in gastric biopsies from fundus mucosa is a characteristic reported only for carcinoids with atrophic gastritis type A. In this study, the size of carcinoid tumors was less than 1 cm with focal lymph vessel invasion and scattered tumor infiltration of the mucosa and submucosa. Though it may be possible to misinterpret lymphatic invasion, true invasion of lymph vessels can be clearly distinguished by reticulin fibers between argyrophil cells that are continuous with reticulin fibers of surrounding tissue<sup>22</sup>. The ECL cell hyperplasia or ECM may finally expand to larger, infiltrating neoplasms with a significant risk of metastases<sup>15</sup>. Carcinoid tumors measuring less than 1 cm in diameter apparently bear only a very low risk of metastases and can be removed by polypectomy or circumscribed local excision. Subsequent endoscopic follow-up of these patients has been recommended. Large carcinoid tumors may require local excision and antrectomy, whereas invasive tumors may need a total gastrectomy<sup>23-25</sup>. Therefore, clinicians caring for patients with atrophic gastritis type A and hypergastrinemia must remain aware of the potential for the development of gastric carcinoid tumors.

Case 1. Total gastrectomy



▨ microscopic distribution of ECMs of the stomach  
○ macroscopic carcinoid tumors

Case 2. Total gastrectomy



.... microscopic distribution of ECMs focal histologically investigated specimens of the stomach  
○ macroscopic carcinoid tumors

**Figure 3.** Schematic distribution of endocrine cell micronests and carcinoid tumors.

## References

- 1) Williams ED, Sandler M. The classification of carcinoid tumors. *Lancet* 1: 238-9, 1963
- 2) Bordi C, Baggi MT, Davoli C, et al: Gastric carcinoids and their precursor lesions. A histologic and immunohistochemical study of 23 cases. *Cancer* 67:663-72, 1991
- 3) Grigioni WF, Caletti GC, Gabrielli M, et al: Gastric carcinoids of ECL cells. Pathological and clinical analysis of eight cases. *Acta Pathologica Japonica* 35:361-75, 1985
- 4) Lehy T, Cadiot G, Mignon M, et al: Influence of multiple endocrine neoplasia type 1 on gastric endocrine cells in patients with the Zollinger-Ellison syndrome. *Gut* 331:275-9, 1992
- 5) Muller J, Kirchner T, Müller-Hermelink HK. Gastric endocrine cell hyperplasia and carcinoid tumors in atrophic gastritis type A. *Am J Surg Pathol* 11:909-17, 1987
- 6) Rindi G, Luinetti O, Cornaggia M, et al: Three subtypes of gastric argyrophil carcinoid and the gastric neuroendocrine carcinoma: a clinicopathologic study. *Gastroenterology* 104:994-1006, 1993
- 7) Solcia E, Capella C, Sessa F, et al: Gastric carcinoids and related endocrine growths. *Digestion* 35(suppl 1):3-22, 1986
- 8) Solcia E, Capella C, Fiocca R, et al: The gastroenteropan-creatic endocrine system and related tumors. *Gastroenterol Clin North Am*

- 18:671-93, 1989
- 9) Solcia E, Capella C, Buffa R, *et al*: Endocrine cells of the gastrointestinal tract and related tumors. *Pathobiology Annual* 9:163-204, 1979
  - 10) Creutzfeldt W. The achlorhydria-carcinoid sequence: role of gastrin. *Digestion* 39:61-79, 1988
  - 11) Wilander E, Nordgren H, Öberg K. Nonantral gastric carcinoid tumors associated with hypergastrinemia. *Acta Med Scand* 219:393-7, 1986
  - 12) Bordi C, Da'Adda T, Azzoni C, Pilato F, Caruana P. Hypergastrinaemia and gastric enterochromaffin-like cells. *Am J Surg Pathol* 19(Suppl 1):S8-S19, 1995
  - 13) Solcia E, Fiocca R, Villani L, *et al*: Morphology and pathogenesis of endocrine hyperplasia's precarcinoid lesions and carcinoids arising in chronic atrophic gastritis. *Scand J Gastroenterol* 26(Suppl 180):146-159, 1991
  - 14) Modlin IM, Gilligan CJ, Lawton GP, *et al*: Gastric carcinoids. The Yale experience. *Arch Surg* 130:250-256, 1995
  - 15) Godvin JD. Carcinoid tumors: An analysis of 2837 cases. *Cancer* 36:560-9, 1975
  - 16) Rubin W. Proliferation of endocrine-like (enterochromaffin) cells in atrophic gastritis mucosa. *Gastroenterology* 57:641-8, 1969
  - 17) Sjoblom SM, Sipponen P, Karonen SL, *et al*: Mucosal argyrophyl endocrine cells in pernicious anemia and upper gastrointestinal carcinoid tumors. *J Clin Pathol* 42:371-7, 1989
  - 18) Solica E, Bordi C, Creutzfeldt W, *et al*: Histopathological classification of non-antral gastric endocrine growths in man. *Digestion* 41:185-200, 1988
  - 19) Brittain RT, Jack D, Reeves JJ, Stables R. Pharmacological basis for the induction of gastric carcinoid tumors in the rat by loxidine, an unsurmountable histamine H2 receptor blocking drug. *Br J Pharmacol* 85:843-7, 1985
  - 20) Jensen RT. Gastrinomas a model for prolonged hypergastrinemia in the human. In: Walsh JM, editor. *Gastrin*. New York: Raven Press 373-93, 1993
  - 21) Sculco D, Bilgrami S. Pernicious anemia and gastric carcinoid tumor: case report and review. *Am J Gastroenterol* 92:1378-9, 1997
  - 22) Muller J, Kirchner T, Muller-Hermelink HK. Gastric endocrine cell hyperplasia and carcinoid tumors in atrophic gastritis type A. *Am J Surg Pathol* 11(12):909-17, 1987
  - 23) Ahlman H, Kolby L, Lundell L, Olbe L, *et al*: Clinical management of gastric carcinoid tumors. *Digestion*. 55 Suppl 3:77-85, 1994
  - 24) Gough DB, Thompson GB, Crotty TB, *et al*. Diverse clinical and pathologic features of gastric carcinoid and the relevance of hypergastrinemia. *World J Surg*. 18:473-80, 1994
  - 25) Gilligan CJ, Lawton GP, Tang LH, *et al*: Gastric carcinoid tumors: The biology and therapy of an enigmatic and controversial lesion. *Am J Gastroenterol* 90:338-52, 1995