



Title	Pacemaker-induced Superior Vena Cava Syndrome : Report of One Case and Review of the Literature
Author(s)	Hirata, Tetsuya; Nonaka, Masahiro; Iliev, Ivani; Kohnoe, Atsuhiko; Seto, Shinji; Hayano, Motonobu; Yano, Katsusuke
Citation	Acta medica Nagasakiensia. 1997, 42(1-2), p.64-67
Issue Date	1997-06-20
URL	<a href="http://hdl.handle.net/10069/16083">http://hdl.handle.net/10069/16083</a>
Right	

This document is downloaded at: 2020-09-17T19:27:22Z

## Pacemaker-induced Superior Vena Cava Syndrome : Report of One Case and Review of the Literature

Tetsuya HIRATA, Masahiro NONAKA, Ivan I ILIEV, Atsuhiko KOHNOE,  
Shinji SETO, Motonobu HAYANO, Katsusuke YANO

Third Department of Internal Medicine, Nagasaki University School of Medicine

A 76-year-old man developed superior vena cava syndrome (SVCS) 20 months after the implantation of a dual chamber pacemaker, and was successfully treated with thrombolytic therapy followed by long-term anticoagulant therapy. The face and neck were markedly swollen, and superficial veins in the neck, upper arms and upper chest were prominently distended. Venography from bilateral cubital veins revealed a severe stenosis of the distal segment of the superior vena cava without the development of collateral channels. After an initial treatment with urokinase for 5 days followed by warfarin for 16 months, the symptoms and signs of the SVCS disappeared, and the digital subtraction angiography revealed a marked regression of the thrombotic stenosis. In view of the expected increase in the insertion of multiple leads in cases of dual chamber pacemakers or including fractured lead retention, more attention should be paid to the risk of the development of the SVCS in these cases.

---

**Key words :** Superior vena cava syndrome, Multiple leads of pacemaker, Thrombolytic therapy.

### Introduction

Superior vena cava syndrome (SVCS) following transvenous pacemaker implantation is a rare complication. In recent years, A-V synchronous pacemakers with multiple leads (DDD or VDD mode) have been increasingly used for the treatment of disturbances of cardiac conduction and rhythm, because these type of pacemaker have the benefits of physiological pacing. Apart from new pacemaker implantations, recently due to the failure of previously implanted leads, the number of cases of new lead insertion has also increased. To date, several cases of SVCS following the implantation of a pacemaker with multiple leads have been reported. We describe an additional case of SVCS 20 months after the implantation of a dual chamber pacemaker (DDD mode), and we review the previous reports on SVCS regarding the number of pacemaker leads, therapy and prognosis.

### Case report

A 76-year-old man began to complain of general fatigue during mild effort in January, 1988. He was diagnosed as having a 2 : 1 A-V block and was admitted to our institution in April, 1988. The subsequently performed electrophysiologic study revealed a H-V block, as a result of which a dual chamber pacemaker (Model 7008, Medtronic, Inc., Minneapolis, MN, USA) was implanted. An atrial lead (Model 4512, Medtronic) and ventricular lead (Model 4012S, Medtronic) were inserted through the left subclavian vein. The postoperative course was uncomplicated. The patient was discharged with the dual chamber pacemaker (DDD mode) showing A-V sequential pacing. The outpatient clinic follow up was also uneventful. However, 20 months after the pacemaker implantation in December 1989, the patient developed swelling of face and neck and distension of superficial veins of neck and upper chest, suggesting the occurrence of SVCS. The patient was readmitted to the hospital in January 1990, because the swelling of face and neck had increased. On admission, the pulse was 60/min, and regular. Blood pressure was 148/86 mmHg, and the temperature was 36.5°C. Face and neck were markedly swollen and the skin in these areas was slightly cyanotic. Superficial veins in neck, upper arms and the upper chest were markedly distended. The heart was not enlarged. A grade 2 systolic ejection murmur was heard at the cardiac apex. The lungs were clear. Liver and spleen were not palpable. There was no pretibial edema. The neurological examination was negative. An electrocardiogram showed a stable pacemaker rhythm with A-V sequential pacing. A chest X-ray revealed the heart to be of normal size with a cardiothoracic ratio of 48%, normal vascular marking in the lung fields and no abnormal shadow suggesting a mediastinal tumor. Two pacemaker leads were seen in the superior vena cava extending toward the right atrium and right ventricle. The computed tomography (CT) scan of the chest and the echocardiogram were unremarkable. Peripheral venous pressures measured simultaneously at bilateral cubital veins were elevated to a level of 27 cm H<sub>2</sub>O, suggesting the presence of

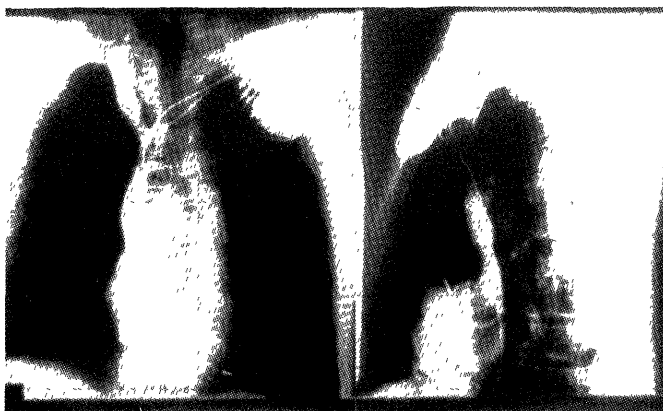


Fig. 1. Venography from bilateral cubital veins taken before treatment shows a severe stenosis of the distal segment of the SVC (arrow). The innominate veins and proximal portions of the subclavian veins are distended. Collaterals are not visible.

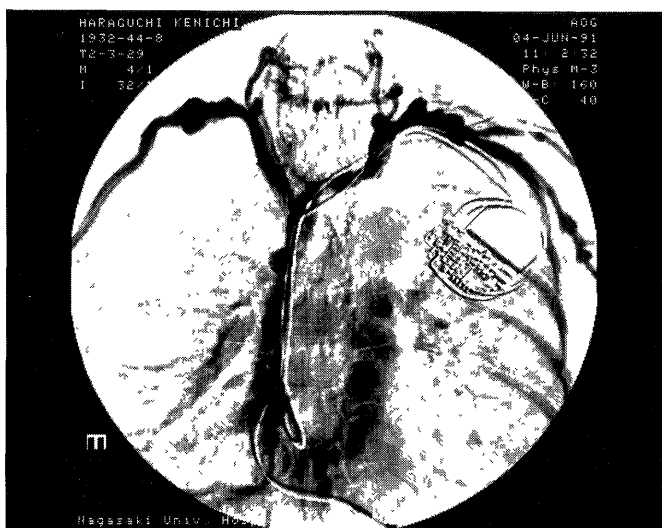


Fig. 2. The digital subtraction angiogram of the SVC from bilateral cubital veins, taken 16 months after the beginning of treatment shows a marked regression of the thrombotic stenosis of the SVC without collaterals.

severe stenosis or obstruction of the superior vena cava (SVC).

Hematological and biochemical tests revealed no significant abnormalities. Coagulation parameters and fibrinolytic activity suggested thrombus formation, but absence of hematological disease responsible for thrombosis. The prothrombin time was 11.6 sec with a control of 11.2 sec. The platelet count was 120,000/cubic mm. The fibrinogen level was 282.3 mg/dl (normal, 168.3 to 328.8 mg/dl) and fibrin degradation products were  $3.7 \mu\text{g/ml}$ .

A venography from bilateral cubital veins revealed a severe stenosis of the distal segment of the SVC without a development of significant collateral channels (Fig. 1). Based on these findings, the patient was diagnosed as

having SVCS caused by thrombotic stenosis of the distal segment of the SVC following the implantation of transvenous dual chamber pacemaker.

Urokinase (240,000 IU) was administered for 5 days followed by anticoagulant therapy with warfarin (2 to 3 mg/days). The symptoms and signs improved to some extent and the peripheral venous pressure of the left cubital vein was reduced to 17.5 cm H<sub>2</sub>O in 2 weeks. However, approximately 4 weeks after the beginning of the thrombolytic and subsequent anticoagulant therapies, a clinical aggravation was observed and the peripheral venous pressure of the left cubital vein got elevated to 24 cm H<sub>2</sub>O. Warfarin was withdrawn, and urokinase (240,000 IU) was administered for 5 days. Then, warfarin (3 to 4 mg/day) was reinstated. Three weeks after the reinstatement a slight improvement in the clinical condition was noted and the peripheral venous pressure was reduced to 22 cm H<sub>2</sub>O. Pulmonary perfusion scintigraphy and pulmonary ventilation scintigraphy were performed, but they failed to reveal any dissociation between pulmonary ventilation and perfusion. The patient was discharged on warfarin (3 mg/day).

During the follow up period at the outpatient clinic, the swelling of the face and neck and the distension of the superficial veins in the neck, upper arms and upper chest was gradually reduced and disappeared completely 13 months after discharge. Digital subtraction angiography of the SVC was performed in June 1991, 14 months after discharge. A marked regression of the thrombotic stenosis of the distal segment of the SVC without a collateral flow was observed (Fig. 2). To date, no recurrence of SVCS has been observed.

## Discussion

Up to the present, many cases of SVCS following transvenous pacemaker implantation have been reported. Over the previous 27 years, more than 39 reports<sup>1-39)</sup> of SVCS following pacemaker implantation have been published. These reports are of 52 cases, 32 males and 18 females; in 2 cases the sex of the subjects was not reported. The SVCS developed between 1 day and 17 years after the initial implantation of transvenous pacemaker, and between 1 week and 12 years after the last renewal of lead followed by withdrawal or retaining of the failed lead.

As for the possible causes of the development of SVCS, in 6 cases it was the development of an infection via the pacemaker generator or pacing lead, in 1 case it was radiation therapy for thyroid cancer, in 1 case there was a compression of the SVC by an aortic aneurysm, and there was 1 case of cardiac involvement by non-Hodgkin's lymphoma. No particular cause was detected in the remaining 43 cases.

Venography revealed obstruction or stenosis of the SVC and obstruction of the other veins such as innominate, subclavian and jugular veins.

Generally, SVCS due to transvenous pacing lead insertion is a rare event. Goudvenous et al<sup>30)</sup> observed one case of SVCS out of 3,100 primary pacemaker implantations. However, Stoney et al<sup>40)</sup> reported that venographic abnormalities indicating thrombus formation were seen in most cases of transvenous pacemaker implantation, but the incidence of clinical symptoms and signs such as facial edema was very low.

Since 1969, the SVCS was reported in 26 cases with a single lead and in 26 cases with 2 or more leads including retained leads. However, if only the data after 1980 are considered, it is seen that SVCS was reported in 12 cases with a single lead and in 24 cases with 2 or more leads. Pauletti et al<sup>41)</sup> reported that venographic abnormalities representing thrombus formation caused by the pacemaker lead were more prominent in patients with multiple leads than in patients with a single lead. Based on this literature review, it may be assumed that patients with multiple pacing leads may have a tendency to developed SVCS more frequently than patients with a single lead.

The reported treatment regimens of SVCS included anticoagulant therapy with heparin or urokinase in the majority of the reported cases. Recanalization of the obstructed site was confirmed by venography in 8 of 10 cases with thrombolytic therapy followed by anticoagulant therapy but in none of 13 cases with anticoagulant therapy only. Seven cases were treated surgically. Nine cases successfully treated recently with percutaneous transluminal balloon angioplasty of the SVC, and in one case, this was followed by venous stenting<sup>36)</sup>. Among the 52 cases reported to date, death occurred in 5 early cases that were not treated with anticoagulant or thrombolytic therapy, whereas in 47 cases in which proper treatment was applied without delay, improvement or disappearance of the symptoms and signs was reported. Thus, the prognosis of this syndrome seems to be relatively good in case of an appropriate treatment.

In the present case no particular cause for the development of SVCS, such as an infection via the pacemaker system or mediastinal tumor, could be identified. It seems likely that the transvenous insertion of 2 pacing leads promoted a thrombus formation and was involved in the development of SVCS. In this patient, the SVCS was relieved with long-term anticoagulant therapy following intravenous thrombolytic therapy with urokinase. It seems that immediate thrombolytic and anticoagulant therapy should be a first choice of treatment, but surgical treatment or angioplasty should be performed without delay when conservative treatment is unsuccessful. In view of the expected increase in the insertion of multiple leads including the retention of fractured lead, close attention should be paid to the risk of the development of SVCS in patients

with multiple pacemaker leads.

## References

- 1) London AR, Runge PJ, Balsam RF, et al. Large right atrial thrombi surrounding permanent transvenous pacemakers. *Circulation* 40: 661-664, 1969.
- 2) Kaulbach MG, Krukoniis EE. Pacemaker electrode induced thrombosis in the superior vena cava with pulmonary embolization. *Am J Cardiol* 26: 205-207, 1970.
- 3) Pereira W, Mershon JC. Permanent transvenous pacemakers. Non-electrical complications and hazards. *J Kans Med Soc.* 74: 450-455, 1973
- 4) Wertheimer M, Hughes RK, Castle CH. Superior vena cava syndrome.: Complication of permanent transvenous endocardial cardiac pacing. *JAMA* 224: 1172-1173, 1973.
- 5) Friedman SA, Berger N, Cerruti MM, et al. Venous thrombosis and permanent cardiac pacing. *Am Heart J* 85: 531-533, 1973.
- 6) Williams DR., Demos NJ. Thrombosis of superior vena cava caused by pacemaker wire and managed with streptokinase. *J Thor Cardiovasc Surg.* 68: 134-137, 1974.
- 7) Sethi GK., Bhayana JN., Scott, S. M.: Innominate venous thrombosis: A rare complication of transvenous pacemaker electrodes. *Am. Heart J.*, 87: 770-772, 1974.
- 8) Branson J. A. Radiology of cardiac pacemakers and their complications with three cases of superior vena caval obstruction. *Aust Radiol.* 22: 125-131, 1978.
- 9) Chamorro H., Rao G. Wholey MH. Superior vena cava syndrome: A complication of transvenous pacemaker implantation. *Diagnostic Radiology* 126: 377-378, 1978.
- 10) Mathews DM., Forfar JC. Superior vena caval stenosis: A complication of transvenous endocardial pacing. *Thorax* 34: 412-413, 1979.
- 11) Pauletti M. Pingitore R. Contini C. Superior vena cava stenosis at site of intersection of two pacing electrodes. *British Heart J* 42: 487-489, 1979.
- 12) Rubio PA., Coan JD., Farrell EM., et al. Subclavian thrombosis secondary to transvenous pacing wire. *South Med J*, 73: 1547, 1980.
- 13) Youngson GC., Mckenzie FN., Nichol PM. Superior vena cava syndrome: Case report. *Am Heart J*. 99: 503-505, 1980.
- 14) Krug H. Zerbe F. Major venous thrombosis: A complication of transvenous pacemaker electrodes. *Brit Heart J* 44: 158-161, 1980.
- 15) Blair, T. P., Seibel, J., Goodreau, J., et al.: Superior relief of thrombotic superior vena cava obstruction caused by endocardial pacing catheter. *Ann Thor Surg.* 33: 511-515, 1982.
- 16) Gundersen T. Abrahamsen AM. Jorgensen I. Thrombosis of superior vena cava as a complication of transvenous pacemaker treatment. *Acta Med Scand* 212: 85-88, 1982.
- 17) Chorankeril JV., Joshi RR., Ketyer S. Benign superior vena cava syndrome caused by transvenous cardiac pacemaker. *Cardiovasc Intervent Radiol.* 5: 40-42, 1982.
- 18) Fraker GC. Muller KJ. Salazar JF. et al. Total venous obstruction following atrioventricular sequential pacemaker implantation. *PACE* 6: 815-817, 1983.
- 19) Katz PO. Hackshaw BT. Barish CF. et al. Venous thrombosis as a cause of superior vena cava syndrome. *Arch Intern. Med* 143: 1050-1052, 1983.
- 20) Yakirevich V. Alagem, D. Papo J. et al. Fibrotic stenosis of the superior vena cava with widespread thrombotic occlusion of its major tributaries: An unusual complication of transvenous cardiac pacing. *J Thorac Cardiovasc Surg* 85: 632-638, 1983
- 21) Knudsen F. Ring T. Nielsen ST. Nielsen ST. Thrombosis of the subclavian vein-A rare complication of transvenous cardiac pacing. *Scand J Thor Cardiovasc Surg* 17: 125-127, 1983.
- 22) Fritz T. Richeson F. Fitzpatrick P. et al. Venous obstruction: A potential complication of transvenous pacemaker electrodes. *CHEST* 83: 534-539, 1983.
- 23) Pasquariello JL. Hariman RJ. Yudelman IM. et al. Recurrent pulmonary embolization following implantation of transvenous pacemaker. *PACE* 7: 790-793, 1984.
- 24) Montgomery JH. D'souza VL. Dyer RB. et al. Non surgical treatment

- of the superior vena cava syndrome. *Am J Cardiol* 56 : 829-830, 1985.
- 25) Fitzgerald SP, Lackie WJ. Thrombosis complicating transvenous pacemaker lead presenting as contralateral internal jugular vein occlusion. *Am Heart J* 109 : 593, 1985.
- 26) Szuman J., Lorkiewicz Z. Superior vena caval stenosis: A rare complication in permanent transvenous cardiac pacing. *J Cardiovasc Surg* 26 : 79-81, 1985.
- 27) Walpole HT., Lovett KE., Chuang VP. et al. Superior vena cava syndrome treated by percutaneous transluminal balloon angioplasty. *Am Heart J* 115 : 1303-1304, 1988.
- 28) Koike R, Sasaki M, Kuroda K. Total venous obstruction: A possible complication of transvenous dual chamber pacing. *Jpn Circ J* 52 : 1293-1296, 1988.
- 29) Blackburn T., Dunn M. Pacemaker-induced superior vena cava syndrome: Consideration of management. *Am Heart J* 116 : 893-896, 1988.
- 30) Goudvenos, J. A., Reid, P. G., Adams, P. C. et al. Pacemaker induced superior vena cava syndrome: Report of four cases and review of the literature. *PACE* 12 : 1890-1895, 1989.
- 31) Angeli SJ. Superior vena cava syndrome following pacemaker insertion post atrial septal defect repair. *Am Heart J* 120 : 433-435, 1990.
- 32) Murakami Y, Matsuno Y, Izumi S. et al. Superior vena cava syndrome as a complication of DDD pacemaker implantation. *Clin Cardiol* 13 : 298-300, 1990.
- 33) Sunder SK, Ekong AE, Sivalingam K. et al. Superior vena cava thrombosis due to pacing electrodes: Successful treatment with combined thrombolysis and angioplasty. *Am Heart J* 123 : 790-792, 1992.
- 34) Yoon J, Koh KK, Cho SK. Superior vena cava syndrome after repeated insertion of intravenous pacemaker. *Am Heart J* 126 : 1014-1015, 1993.
- 35) Ciro A, Vincenti A, Bozzano A. Cardiac involvement by non-Hodgkin's lymphoma: An unusual presentation of heart conduction disturbances. *PACE* 17 : 1561-1564, 1994.
- 36) Francis CM, Starkey IR, Errington ML, Errington ML. et al. Venous stenting as treatment for pacemaker-induced superior vena cava syndrome. *Am Heart J* 129 : 836-837, 1995.
- 37) Kastner RJ, Fisher WG, Blacky AR. Pacemaker-induced superior vena cava syndrome with successful treatment by balloon venoplasty. *Am J Cardiol* 77 : 789-790, 1996.
- 38) Ito H., Tamura H., Kinoshita T. et al. Treatment with percutaneous transluminal balloon venoplasty for superior vena cava syndrome after permanent pacemaker implantation. *Nippon Acta Radiologica* 55 : 600-602, 1995.
- 39) Kitamura J, Murakami Y, Shimada T. et al. Morphological observation by intravascular ultrasound in superior vena cava syndrome after pacemaker implantation. *Catheterization & Cardiovascular Diagnosis* 37 : 83-85, 1996.
- 40) Stoney W, Adleston RB, Alford WC. et al. The incidence of venous thrombosis following long term transvenous pacing. *Ann Thorac Surg* 22 : 166-170, 1976.
- 41) Pauletti M, Ricco GD, Solfanelli S. et al. Venous obstruction in permanent pacemaker patients: An isotopic study. *PACE* 4 : 36-42, 1981.