



Title	Genetic Analysis of Cardiac Myosin Heavy Chain(MHC)Gene in Seven Families with Hypertrophic Cardiomyopathy in Japan
Author(s)	Hayashi, Ikuo; Ashizawa, Naoto; Oku, Yasuhiko; Ozeki, Shinichiro; Ohtsuru, Akira; Yano, Katsusuke
Citation	Acta medica Nagasakiensia. 1994, 39(1-3), p.168-171
Issue Date	1994-10-25
URL	http://hdl.handle.net/10069/15995
Right	

This document is downloaded at: 2020-09-17T19:38:23Z

Genetic Analysis of Cardiac β Myosin Heavy Chain (MHC) Gene in Seven Families with Hypertrophic Cardiomyopathy in Japan

Ikuo HAYASHI, MD, Naoto ASHIZAWA, MD, Yasuhiko, OKU, MD, Shinichiro, OZEKI, MD, Akira OHTSURU, MD #, and Katsusuke YANO, MD

The Third Department of Internal Medicine, #Department of Cell Physiology, Atomic Disease Institute, Nagasaki University School of Medicine, Nagasaki, Japan

The purpose of this study was to identify the presence of either mutation or polymorphism in the cardiac β myosin heavy chain (MHC) gene of the Japanese who had familial hypertrophic cardiomyopathy (FHCM). We analyzed exons 3-25 of the cardiac MHC gene in seven unrelated Japanese families (17 affected and 10 unaffected individual with HCM), using the polymerase chain reaction (PCR)-single strand conformation polymorphism (SSCP) analysis. Our study showed that affected members of one family (proband; I.I.) had an identical pattern of aberrantly migrating band of exon 21. Similarly we found polymorphism and probable point mutation located on exon 3 of one patient with sporadic HCM (Pt; T.M.). Both proband; I. I. and Pt; T.M., developed lethal congestive heart failure with left ventricular (LV) dilatation as confirmed by autopsy. This suggest that PCR-SSCP analysis is an useful tool for clinical screening of HCM.

Introduction

The cardiomyopathies are classified according to their anatomic and pathophysiologic types, as dilated, hypertrophic and restrictive. The distinctions between these three categories are not absolute, and there is often overlap. Hypertrophic cardiomyopathy is a primary disorder of cardiac muscle characterized by hypertrophy of the left ventricle with preserved or enhanced contraction, in the absence of another cardiac disease, or systemic disease which can produce left ventricular hypertrophy. At the microscopic level, the most characteristic abnormality is the great extent of disorganization of both the cell-to-cell alignment and the regular structure of myofibrils, known as myosite disarray. Secondary myocardial hypertrophy may accompany any type of cardiovascular disorder, such as valvular, hypertensive, ischemic and congenital heart disease. Disarray may also be present in small amounts in secondary myocardial hypertrophy (about 5% of the total tissue area), but in hypertrophic cardiomyopathy it is found as much as 30% of the total tissue area. The chief morphological abnormality in

hypertrophic cardiomyopathy is greater thickening of the ventricular septum than the left ventricular free wall. Patients with hypertrophic cardiomyopathy are often asymptomatic or have non specific cardiovascular symptoms, such as dyspnea, chest pain or syncope. The most frightening clinical outcome of hypertrophic cardiomyopathy is sudden cardiac death which can occur even in asymptomatic persons. Another clinical problem is the difficulty to determine which patient is developed from hypertrophic to dilated cardiomyopathy. In over one half of patients hypertrophic cardiomyopathy is familial, while remaining cases appear to be sporadic. Familial hypertrophic cardiomyopathy (FHCM) is an autosomal dominant disorder [1, 2] and it is one of the most common forms of inheritable cardiac disease. Significant variability in the clinical and morphological expression among families, and even within the same family, suggest phenotypic heterogeneity of this disease. Recently linkage analysis in large multiplex Caucasian FHCM showed a close linkage of affected individuals with the cardiac β MHC locus on the chromosome 14 band q1 [3-5]. Missense mutations of the cardiac β MHC locus have been reported among the Japanese with FHCM. [6-10]. Using various restriction fragment length polymorphism (RFLP) markers, the FHCM locus was found to be located on Chromosome 18 (Japanese study) [11] Chromosome 16 (Italian study) [12], and Chromosome 2 (NIH study) [5], indicating genetic heterogeneity. To clarify the frequency of mutations or polymorphisms in the cardiac β MHC gene, we studied 7 unrelated families with HCM by PCR-SSCP analysis. As the recent studies reported that mutations were mainly found in the head or head-rod junction, we selected the exons 3-25 of the cardiac β MHC gene.

Method

Study group

Seven families were identified through an affected family member and underwent extensive medical history and cardiovascular examinations, including 12-lead electrocardiography, M-mode and two-dimensional echocardiographies. The diagnosis of HCM was based on unexplained ventricular hypertrophy in the absence of ather potential causes of ventricular hypertrophy such as systemic hypertension. Patients with apical hypertrophy were excluded from this study.

Genetic DNA extraction

The blood was drawn from family members after informed consent. High-molecular-weight DNAs were prepared from peripheral leucocytes, and these cells were digested using the SDS-protein K method. DNA was extracted with phenol-chloroform, and ethanol precipitate [13]. LV muscle tissue was obtained from the proband; I.I. of family I. and the sporadic case; T.M. of HCM underwent autopsy.

PCR amplification

Oligonucleotide primers for PCR amplification were synthesized by DNA synthesizer (Cyclon plus, Milligen/Biosearch, Burlington) and obtained from H. Nish et al. Using these sets of primers, genomic DNA was amplified in a thermal cycler (Program Temp Control System PC-700, Astec Inc., Tokyo) under the following conditions: 94°C for 1 minute, 55-60°C for 1 minute, 72°C for 1 minute, and final primer extension time of 4 minutes at 72°C.

PCR-SSCP analysis

The PCR-SSCP analysis and the silver staining method were performed as described by S. Hoshino et al. [14]. Formamide dye (80% formamide, 20mM EDTA, 0.01% bromophenol blue, pH8.0) was added to an aliquot of PCR products (0.1-0.2 μ g) to obtain the final concentration of 50% formamide. Samples were heat-denatured at 96°C for 5 minutes, and rapidly cooled on ice. The samples were electrophoresed in two sets of 8% polyacrylamide gels (0.1cm width, 0.4 \times TBE, acrylamide: bisacrylamide = 30:1) with and without 10% glycerol in 0.4 \times TBE (1 \times TBE: 89mM Tris-borate, 89mM boric acid, 2mM EDTA, pH8.0) at 12V/cm for 3-7 hours at room temperature. DNA fragments were visualized by a silver staining kit (Daiichi Chemical Co. Ltd., Tokyo) according to the manufacture's instructions.

Result

There were no unusual DNA fragments detected except that which was detected on exons 3 and 21. Figure 1 shows the result of the PCR-SSCP analysis of exon 21. In all affected members of family I. (indicated by an asterisk), an unusual slow-migrating DNA fragment was observed under the condition of 10% glycerol containing gel. This unusual slow-migrating DNA fragment was also found in the DNA from LV muscle of proband I.I. In exon 3, under the condition without glycerol containing gel, an unusual slow-migrating DNA fragment was observed in proband S.S. of family S (number 1) and proband I.I. of family I

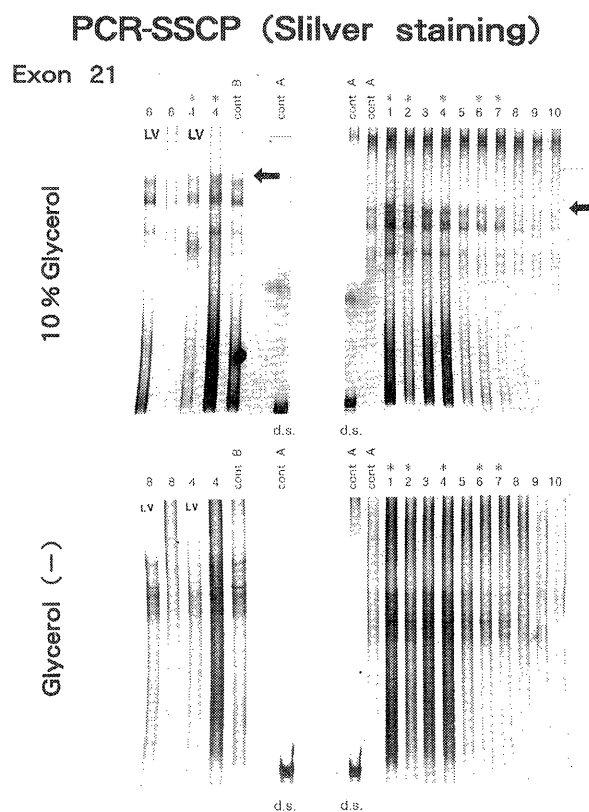


Fig 1: PCR-SSCP analysis of the cardiac β MHC gene. PCR products of exon 21 of the β MHC gene were heat-denatured and electrophoresed in 8% polyacrylamide gel with (top) and without (bottom) containing 10% glycerol.

Lane 1: elder sister, 2: elder sister, 3: elder brother, 4: proband I. I., 5: daughter, 6: son, 7: son (Family I) Lane 8: sporadic HCM Pt; T.M., lane 9: Family S (proband S. S.), Lane 10: Family D (proband H. D.), cont: normal control, LV: PCR products originated from LV muscle by autopsy, d.s.: double strand DNA (fast-migrating DNA fragment). Asteric(*) lanes revealed additional slow migrating DNA fragment.

PCR-SSCP (Silver staining)
Exon 3

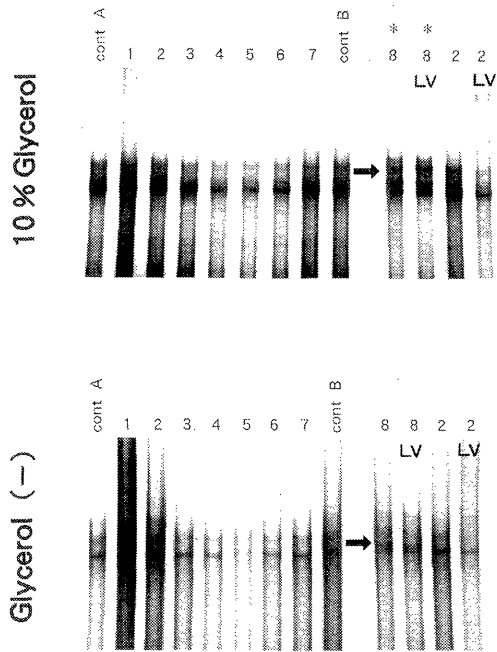
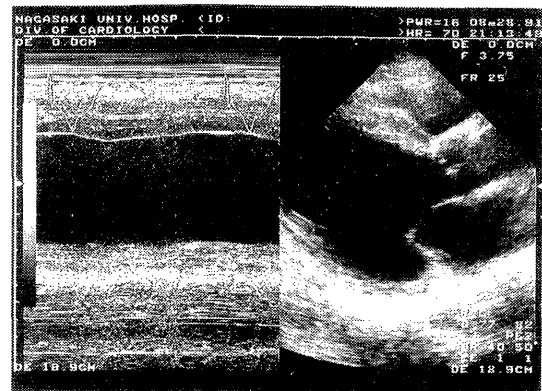
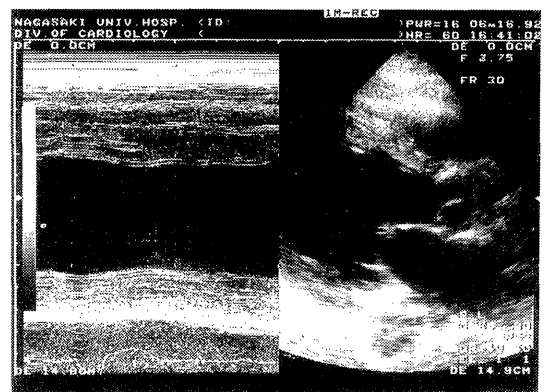


Fig 2 : PCR-SSCP analysis of the cardiac β MHC gene. PCR products of the exon 3 of the β MHC gene were analyzed as in Fig 1. Lane 1-7 show the each proband of FHCM. Asteric(*)lanes indicated additional migrating DNA fragment.

(number 2). But this fragment was also found in normal control A. One sporadic patient with HCM (Pt; T.M.) showed a different DNA migrating pattern when the DNA ran in a gel with 10% glycerol. This migration pattern was also detected in the DNA from LV muscle of the same patient (Fig.2). Both proband I.I. and sporadic HCM patient; T.M. had the same clinical course and died of congestive heart failure at the age of 59 and 64 respectively. Echocardiography obtained from these patients showed an increased diastolic LV dimension and reduction of LV ejection, instead of regression of the thickness of interventricular septum (IVS) (Fig.3). The autopsy revealed that both patients had marked cardiomegaly (proband I.I.:580g, Pt;T.M.:770g) and that there was no significant atherosclerotic luminal narrowing greater than 75% of the cross-sectional area of the coronary arteries. Figure 4 demonstrates the histological specimen of LV muscle tissue from Pt;T.M.(left) and proband I.I.(right). Irregular hypertrophy and disarray of myocyte was observed accompanied by prominent fibrosis.



T.M. 63/M



I.I. 59/M

Fig 3 : M-mode and two-dimensional echocardiograms in the parasternal long-axis view (top:sporadic HCM Pt;T.M.,bottom: proband I.I.). LV cavity enlargement and the impairment of LV ejection was observed simultaneously with less thickness of IVS.




Fig 4 : Histological specimen from sporadic HCM Pt ; T. M. (left) and proband I.I.(right). The myocardial cell enlargement and disarray was shown accompanied by prominent fibrosis (H.E. $\times 40$).

Discussion

FHCM is a primary disorder of cardiac muscle that has an autosomal dominant pattern of inheritance [1, 2]. In some families, the cardiac β MHC gene might be a crucial loci of HCM. Cardiac β MHC gene that encode regions of the MHC polypeptide consists of forty exons (Fig.5). The MHC polypeptide has two functional domains, a globular head region (exon3-22) and an elongated rod region (exon 23-40). The head region is important for myocardial function. Since the mutations were reported in the head or head-rod junction, we selected the exons 3-25 of the cardiac β MHC genes in our study. In exon 21, all affected members of one family (proband I.I.) showed an identical pattern of aberrantly migrating bands. In exon 3, we found polymorphism and probable point mutation in one patient with sporadic HCM (Pt;T.M). To confirm this mutation in cardiac tissue, PCR-SSCP was carried out using cardiac muscles obtained at autopsy. The same additional migration band was also found. Interestingly, both proband I.I. and Pt; T.M. developed lethal congestive heart failure with LV dilatation as confirmed by autopsy. It is not clear whether these point mutations may lead HCM to diastolic-phase HCM [15-17]. These observations suggest that the mutation or polymorphism in the β MHC gene exists and may cause HCM in some Japanese families. The mechanism by which mutations in the cardiac β MHC genes produce cardiac hypertrophy is still unknown. This study suggests that different mutations in the cardiac β MHC gene may cause similar clinical disease. The positive data was detected only in two lethal cases with diastolic-phase HCM, although the number of investigated families was small. To ascertain whether mutations in the same genetic locus are responsible for FHCM in other families, further investigations are required. Recently Perryman M.B. et al reported the missense mutation in exon 13 of the β MHC gene in the messenger RNA isolated from a right ventricular endomyocardial biopsy [18]. We are now confirming the mutation of genomic DNA mentioned above using direct sequencing and assessing the transcription of a mutant β MHC gene allele into messenger RNA of the LV myocardium derived from autopsy. In conclusion, genetic analysis of the cardiac β MHC gene using PCR-SSCP might be useful for screening of hypertrophic cardiomyopathy.

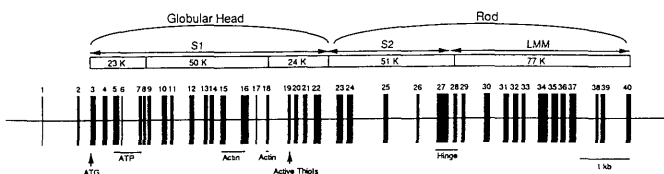


Fig 5 : Exon map adapted from Jaenicke et al (1990). A representation of the cardiac β MHC gene.

Acknowledgments

We thank Dr. Kimura A. Kyusyu University and Dr. Nishi H. Kurume University for their kindness in supplying the oligonucleotide primers.

References

- 1) Maron BJ, Bonow RO, Cannon RO, et al. Hypertrophic cardiomyopathy: interrelations of clinical manifestations, pathophysiology and therapy. *N Engl J Med* : 316: 780, 1987.
- 2) Maron BJ, Mulvihill JJ. The genetics of hypertrophic cardiomyopathy. *Ann Intern Med* : 105: 610, 1986.
- 3) Jarcho JA, McKenna W, Pare JA et al. Mapping a gene for familial hypertrophic cardiomyopathy to chromosome 14q1. *N Engl J Med* : 321: 1372, 1989.
- 4) Heitman cik JF, Brink PA, Towbin J et al. Localization of gene for familial hypertrophic cardiomyopathy to chromosome 14q1 in a diverse US population. *Circulation* : 83: 1592, 1991.
- 5) Epstein ND, Fananapazir L, Lin HJ et al. Evidence of genetic heterogeneity in five kindreds with familial hypertrophic cardiomyopathy. *Circulation* : 85: 635, 1992.
- 6) Geisterfer-Lowrance AAT, Kass S, Tanigawa G et al. A molecular basis for familial hypertrophic cardiomyopathy: A β cardiac myosin heavy chain gene missense mutation. *Cell* : 62: 999, 1990.
- 7) Tanigawa G, Jarcho JA, Kass S et al. A molecular basis for familial hypertrophic cardiomyopathy: An α/β cardiac myosin heavy chain hybrid gene. *Cell* : 62: 991, 1990.
- 8) Watkins H, Rosenzweig A, Hwang D-S et al. Characteristics and prognostic implications of myosin missense mutations in familial hypertrophic cardiomyopathy. *N Engl J Med* : 326: 1108, 1992.
- 9) Epstein ND, Cohn GM, Cyan F et al. Differences in clinical expression of hypertrophic cardiomyopathy associated with distinct mutations in the β -myosin heavy chain gene A908^{Leu→Val} mutation and a 403^{Arg→Gln} mutation. *Circulation* : 86: 345, 1992.
- 10) Nishi H, Kimura A, Harada H et al. Novel missense mutation in cardiac β myosin heavy chain gene found in a Japanese patient with hypertrophic cardiomyopathy. *Biochem Bioph Res Co* : 188: 379, 1992.
- 11) Nishi H, Kimura A, Sasaki M et al. Localization of the gene for hypertrophic cardiomyopathy to chromosome 18q. *Circulation* : 80 (suppl II): II-457, 1989.
- 12) Ferraro M, Scarton G, Ambrosini M. Cosegregation of hypertrophic cardiomyopathy and a fragile site on chromosome 16 in a large Italian family. *J Med Genet* : 27: 363, 1990.
- 13) Gross-Bellard M, Oudet P. Isolation of high-molecular-weight DNA from mammalian cells. *Eur J Biochem* : 36: 32, 1973.
- 14) Hoshino S, Kimura A, Fukuda Y et al. Polymerase chain reaction-single-strand conformation polymorphism analysis of polymorphism in DPA1 and DPB1 genes: A simple, economical, and rapid method for histocompatibility testing. *Hum Immunol* : 33: 98, 1992.
- 15) Fujiwara H, Onodera T, Tanaka M et al. Progression from hypertrophic obstructive cardiomyopathy to typical dilated cardiomyopathy-like features in the end stage. *Jpn Circ J* : 48: 1210, 1984.
- 16) Funakoshi M, Imamura M, Sasaki J et al. Seventeen year follow-up of a patient with hypertrophic cardiomyopathy which progressed to dilated cardiomyopathy. *Jpn Heart J* : 25: 805, 1984.
- 17) Yutani C, Imakita M, Ishibashi-Ueda H et al. Three autopsy cases of progression to left ventricular dilatation in patients with hypertrophic cardiomyopathy. *Am Heart J* : 109: 545, 1985.
- 18) Perryman MB, Yu Q, Marian AJ et al. Expression of a missense mutation in the messenger RNA for β -myosin heavy chain in myocardial tissue in hypertrophic cardiomyopathy. *J Clin Invest* : 90: 271, 1992.