



Title	Expression of c-myc, c-fos and CA19-9 in Human Non-Malignant and Malignant Gallbladder Tissues
Author(s)	Hamada, Yushi; Toda, Takayoshi; Kiyuna, Masaya; Muto, Yoshihiro; Miura, Myota; Sato, Nobutaka
Citation	Acta medica Nagasakiensia. 1990, 35(1-4), p.164-171
Issue Date	1990-12-14
URL	http://hdl.handle.net/10069/15834
Right	

This document is downloaded at: 2020-09-17T19:45:01Z

Expression of c-myc, c-fos and CA19-9 in Human Non-Malignant and Malignant Gallbladder Tissues

Yushi HAMADA¹, Takayoshi TODA², Masaya KIYUNA²
Yoshihiro MUTO¹, Myota MIURA³, and Nobutaka SATO⁴

- 1) Department of Surgery, School of Medicine, University of the Ryukyus
- 2) Department of Clinical and Laboratory Medicine, University of the Ryukyus, Okinawa
- 3) Department of Pathology, School of Medicine, Toho University, Tokyo
- 4) Pathology section, Kosei General Hospital, Tokyo

Received for publication, June 25, 1990

SUMMARY: Immunohistochemical study was performed on expressions of c-myc, c-fos and CA19-9 in gallbladder tissue with or without malignant lesions. A total of 81 tissues were divided into four groups including 47 carcinomas, 3 dysplasias, 17 metaplasias and 14 normal lesions. After these tissues were routinely fixed in 10% formalin solution and embedded in paraffin, 4 micrometer-thick sections were made and stained with hematoxylin-eosin to classify the type of lesions. Immunohistochemical stains were carried out for c-myc and c-fos oncoproteins, and CA19-9. The percentages of positive reaction for c-myc oncoprotein were 77%, 67%, 88% and 36%, those for c-fos oncoprotein were 83%, 66%, 35% and 7%, and those for CA19-9 were 85%, 100%, 88% and 71% in carcinoma, dysplasia, metaplasia and normal tissues, respectively. These results suggest that c-myc and c-fos oncogenes play some kind of roles in malignant transformation of the gallbladder tissues and that abnormal expression of CA19-9 is the sign of antigen reversion of carcinoma cells toward embryonic cells of the gallbladder tissue.

INTRODUCTION

Recent investigators have indicated that protooncogenes have crucial roles in normal cell proliferation and differentiation as well as in the development and progression of various tumors (2, 4, 21, 22). C-myc gene has been reported to be amplified and overexpressed in various human cancers such as uterine cancer (18), hematopoietic malignancies (19), colonic carcinoma (6), and thyroid carcinoma (24). C-fos gene has also been reported to be expressed in various types of cells and tissues at different developmental stages (7) and in a small number of human cancers (14, 15). CA19-9 (carbohydrate antigen 19-9) is one of the useful tumor markers

of the gastrointestinal tract which was originally developed by Koprowski *et al.* (13) in 1979. Several authors (1, 12, 20) have reported that serum level of CA19-9 is high in case of gallbladder carcinoma. From these considerations, we analyzed the expression of c-myc and c-fos oncogene products and CA19-9 in the gallbladder carcinoma tissues in order to obtain better understanding of roles of oncogenes and tumor marker in carcinogenesis of the gallbladder.

MATERIALS AND METHODS

Tissues specimens were obtained from a total of 81 cholecystectomized cases including 14 normal controls (N), 17 metaplasias (M), 3

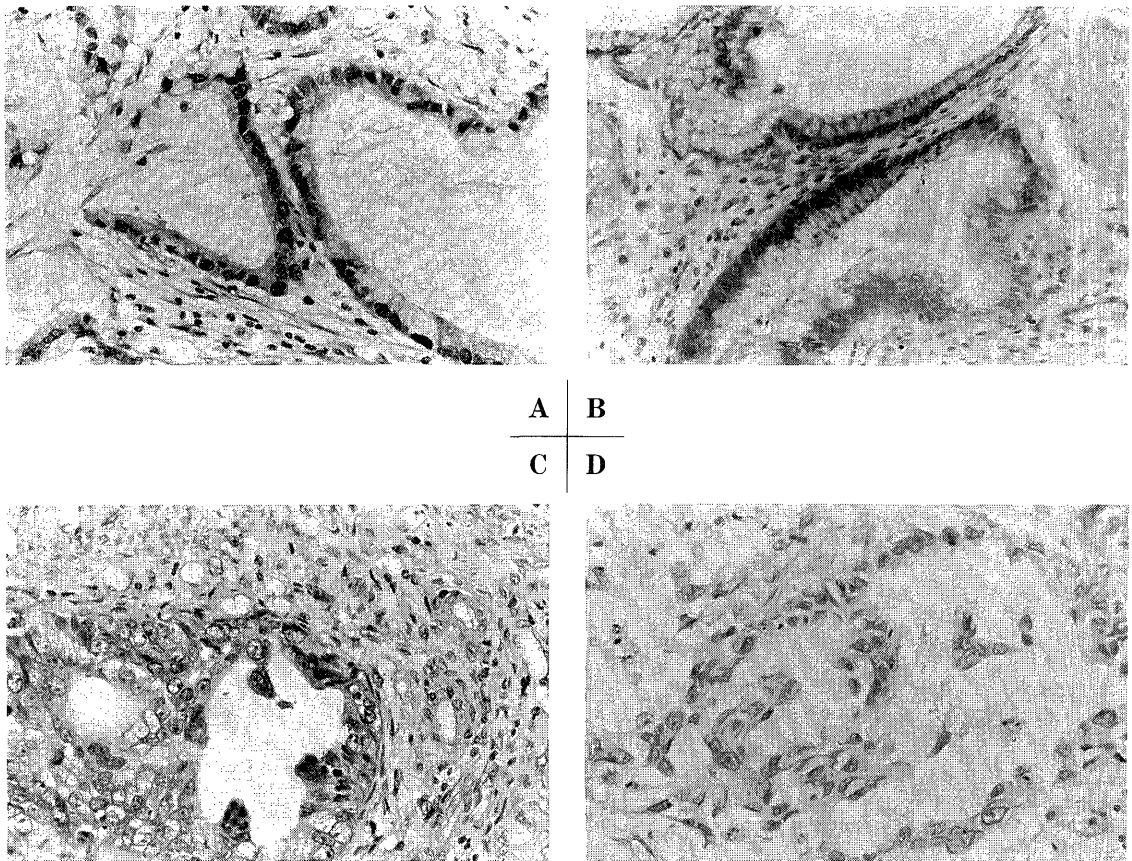


Fig. 1. Comparison of intensity of immunohistochemical reaction (Moderately differentiated adenocarcinoma)

- A: Definitely positive (+++); Positive reaction is noted in both nuclei and cytoplasm of more than 75% of carcinoma cells (c-fos $\times 100$).
- B: Moderately positive (++); Positive reaction is noted in nuclei of 50% of carcinoma cells (c-fos $\times 100$).
- C: Weakly positive (+); Positive reaction is noted in the nuclei of less than 25% of carcinoma cells (c-myc $\times 100$).
- D: Negative (-); No significant reaction is noted (c-fos $\times 100$)

dysplasias (D), and 47 carcinomas (C). Tissues were immediately fixed in 10% formalin solution. Sections embedded in paraffin were cut into 4 micrometer thickness and stained with hematoxylin-eosin (HE). In addition to the conventional histological staining, expressions of the c-myc and c-fos oncogene products, and the CA19-9 were immunohistochemically examined. The primary antibody of c-myc (Oncor), c-fos oncogene product (Cambridge Research) and that of CA19-9 (Oris) were purchased. Immunoper-

oxidase staining was performed on sectioned tissues by the peroxidase-antiperoxidase (PAP) method of Sternberger *et al.* (23). Sections were treated with 0.3% hydrogen peroxide to block endogenous peroxidase. After exposure to non-immune serum, the sections were reacted with either the primary anti-sera or non-immune sera, link antibodies, followed by peroxidase-anti-peroxidase complex for one hour at room temperature. The sections were then washed three times with 0.1 M phosphate buffered

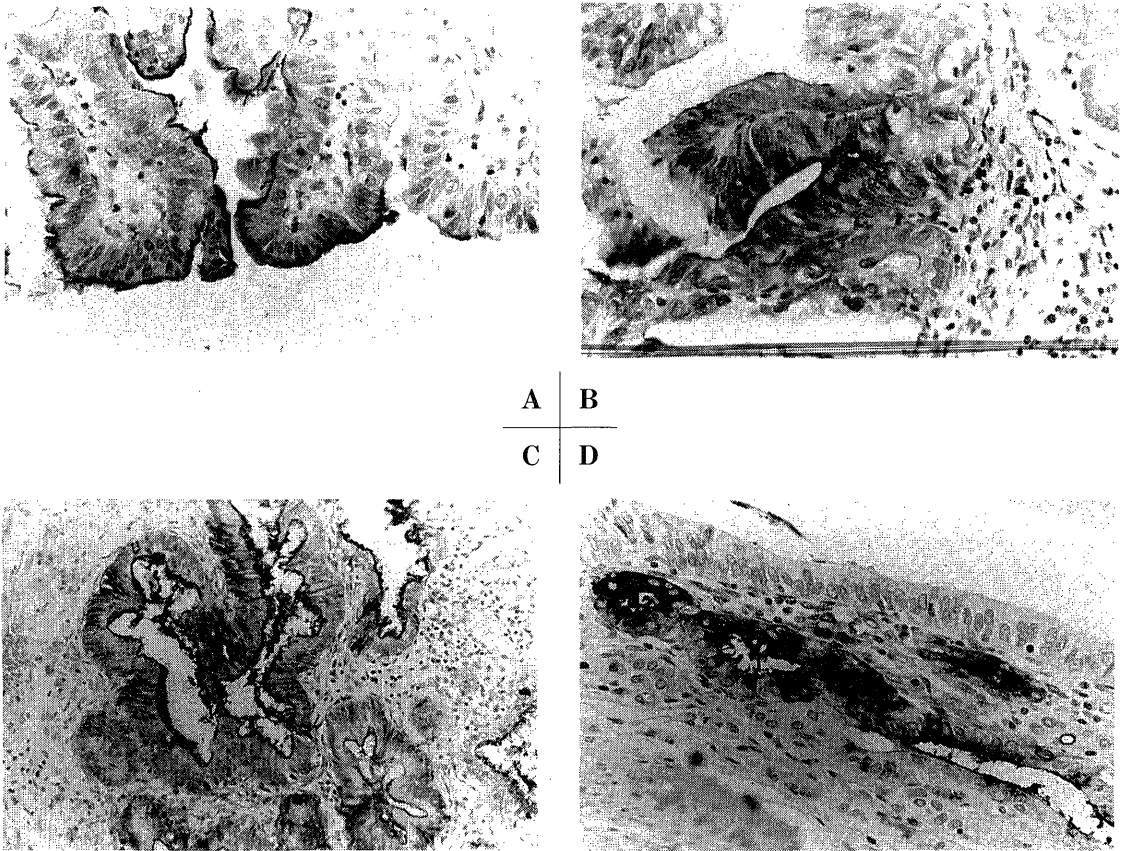


Fig. 2. Immunostaining pattern of CA19-9

- A: Apical type; Positive reaction is limited to luminal surface of the epithelium ($\times 100$).
 B: Cytoplasmic type, with polarity; Positive reaction is noted in supranuclear and luminal surface area ($\times 100$).
 C: Cytoplasmic type without polarity; Positive reaction is noted in entire cytoplasm and cytoplasmic membrane ($\times 50$).
 D: Stromal type; Positive reaction is noted in stromal cells ($\times 100$).

solution (PH 7.5) for 5 minutes after each antibody applications and were treated with diaminobenzidine in hydrogen peroxide. The intensity of immunoreaction of c-myc and c-fos oncogene products was evaluated by light microscope at the magnification of 100 times. And the following 4 gradings of intensity of immunoreaction were adopted: More than 50% of positive tumor cells, (+++); 25% to 50% of positive tumor cells, (++); less than 25% of positive tumor cells, (+); no positive cells (-)

(**Fig. 1**). For the evaluation of immunohistochemical staining pattern of CA19-9, Hamada's criteria (9) was applied as follows: 1) Only luminal cytoplasmic surface is positively stained (Apical type), 2) Supranuclear portion of the cytoplasm is intensely stained (Cytoplasmic type, with polarity), 3) Total area of the cytoplasm is positively stained (Cytoplasmic type, without polarity), 4) Surrounding stromal cells are positively stained (Stromal type) (**Fig. 2**).

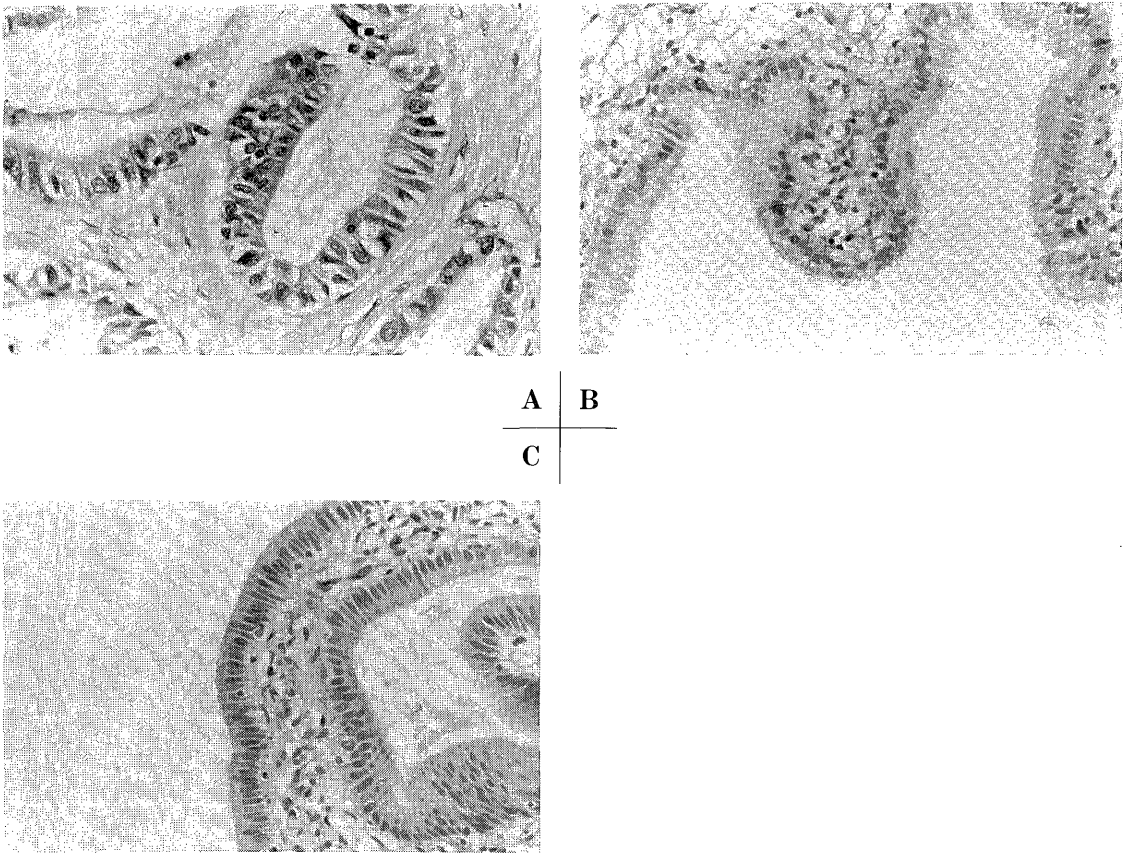


Fig. 3. Immunohistochemistry of c-myc gene product

- A : Definitely positive reaction is noted in both nuclei and cytoplasm of carcinoma cells ($\times 100$)
- B : Moderate positive reaction is noted especially in nuclei of the metaplastic epithelium ($\times 50$).
- C : Slight positive reaction is noted in nuclei of the normal epithelium ($\times 50$).

RESULTS

Intense positive reaction of c-myc gene product was seen in both nuclei and the cytoplasm of carcinoma cells. However, slight to moderate positive reaction of c-myc gene was observed especially in the nuclei of the non-carcinomatous cells (**Fig. 3**). Table 1 indicates frequency of the c-myc positive cells in C, D, M, and N groups. Positive rates of c-myc gene product was 77%, 67%, 88%, and 36% in C, D, M, and N groups, respectively. Furthermore, 11 out

of 47 carcinoma cases (23%) showed intense definitely positive reaction of c-myc oncogene product. **Fig. 4** shows immunohistochemical findings of c-fos oncogene product in various types of gallbladder lesions and immunohistochemical staining pattern of those were similar to those of c-myc gene product. Positive rates of c-fos oncogene product in various types of gallbladder lesions are listed in Table 2. Positive rates of c-fos oncogene product were 83%, 66%, 35%, and 7% in C, D, M, and N groups, respectively. Definitely positive reaction of c-fos oncogene product was observed in 9 out of 47

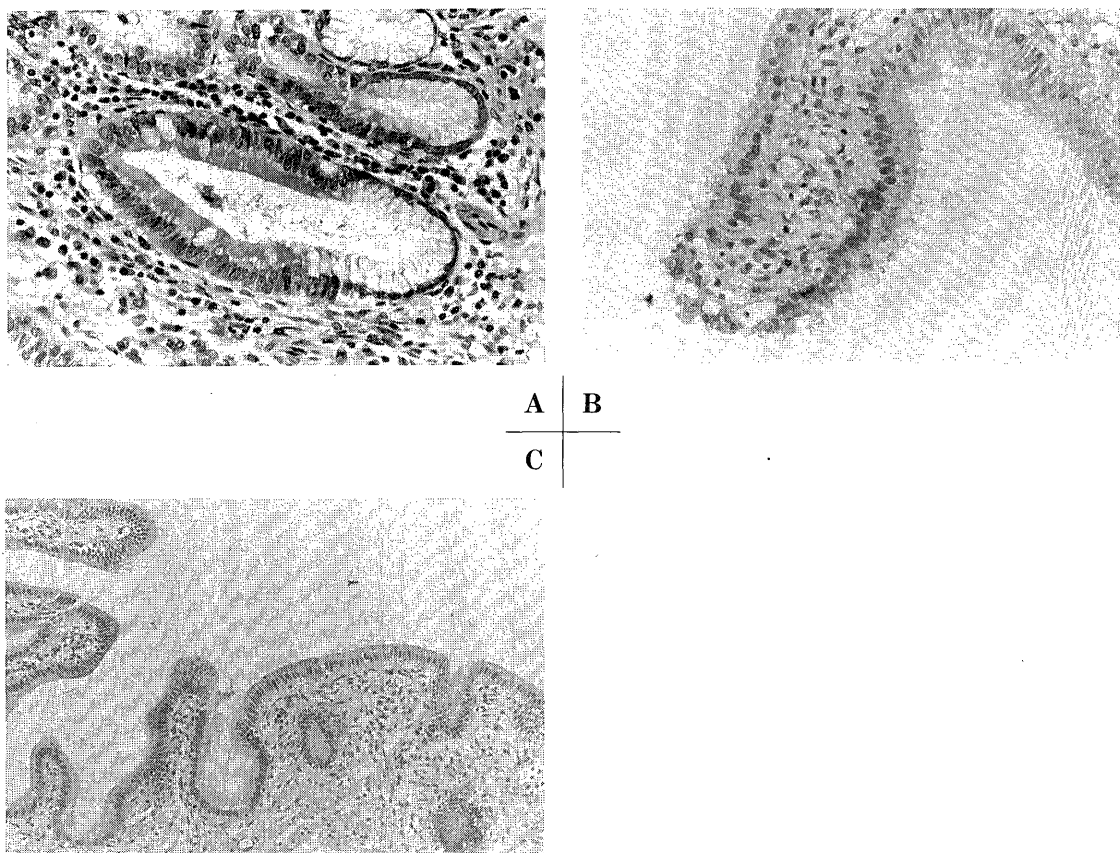


Fig. 4. Immunohistochemistry of c-fos gene product

A : Definitely positive reaction is noted in both nuclei and cytoplasm of carcinoma cells (×100).

B : Moderate positive reaction is noted especially in nuclei of the metaplastic epithelium (×50).

C : Slight positive reaction is noted in nuclei of the normal epithelium (×20).

Table 1. Immunohistochemical positive rate of c-myc gene product in gallbladder tissues of each group

	-	+	++	+++	Total
N group	9 (64%)	3 (22%)	2 (14%)	0 (0%)	14 (100%)
M group	2 (11%)	4 (24%)	10 (59%)	1 (6%)	17 (100%)
D group	1 (33%)	0 (0%)	1 (33%)	1 (33%)	3 (99%)
C group	11 (24%)	6 (13%)	19 (40%)	11 (24%)	47 (100%)

Table 2. Immunohistochemical positive rate of c-fos gene product in gallbladder tissues of each group

	-	+	++	+++	Total
N group	13 (93%)	0 (0%)	1 (7%)	0 (0%)	14 (100%)
M group	11 (64%)	2 (12%)	4 (24%)	0 (0%)	17 (100%)
D group	1 (33%)	1 (33%)	1 (33%)	0 (0%)	3 (99%)
C group	8 (17%)	18 (38%)	18 (26%)	9 (19%)	47 (100%)

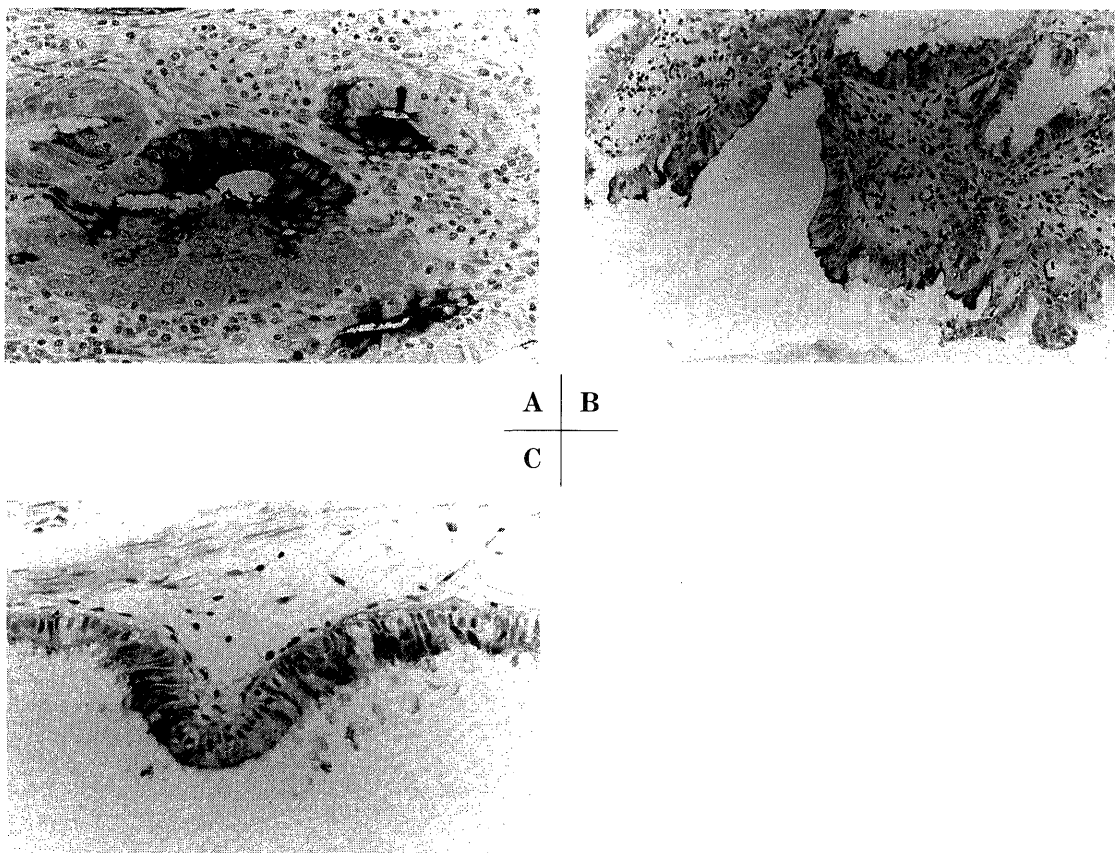


Fig. 5. Immunohistochemistry of CA19-9

- A: Positive reaction is noted in glandular epithelium of carcinoma (×100)
- B: Positive reaction is noted in mucosal epithelium of the gallbladder with gland metaplasia (×50).
- C: Positive reaction is occasionally noted in nuclei of the normal mucosal epithelium (×100).

carcinoma cases (19%). As for immunohistochemical staining pattern, numerous cases of carcinomas presented cytoplasmic without polarity type. Apical and cytoplasmic with polarity types of immunohistochemical staining patterns were frequently seen in non-carcinomatous gallbladder tissues (**Fig. 5**). Positive rates of CA19-9 in each group are listed in Table 3. Positive rates of CA19-9 were 85%, 100%, 88%, and 71% in C, D, M, and N groups, respectively. Table 4 indicates immunohistochemical staining pattern of CA19-9 in each group. Stromal type was frequently seen in

Table 3. Immunohistochemical positive rate of CA19-9 in gallbladder tissues of each group

	-	+	++	+++	Total
N group	4 (29%)	1 (7%)	8 (52%)	1 (7%)	14 (100%)
M group	2 (12%)	6 (35%)	8 (47%)	1 (6%)	17 (100%)
D group	0 (0%)	1 (33%)	2 (67%)	0 (0%)	3 (99%)
C group	7 (15%)	16 (34%)	19 (40%)	5 (11%)	47 (100%)

Table 4. Frequency of various type of immunohistochemical localization of CA19-9 in gallbladder tissues of each group

	Apical type	With type	Without type	Stromal type	Total
N group	0 (0%)	15 (100%)	0 (0%)	0 (0%)	10 (100%)
M group	0 (0%)	11 (73%)	4 (27%)	0 (0%)	15 (100%)
D group	0 (0%)	1 (33%)	2 (67%)	0 (0%)	3 (100%)
C group	0 (0%)	14 (35%)	18 (45%)	8 (20%)	40 (100%)

With type; Cytoplasmic type, with polarity

Without type; Cytoplasmic type, without polarity

Group C (20%), and cytoplasmic type with polarity was prevalently observed in Groups M (73%) and N (100%).

DISCUSSION

Various mitogens induce the c-myc gene (3, 11), expression of which is related to the transition from G₀ to G₁ of the cell cycle (17). It has been reported that induction of c-fos gene and protein by growth factors precedes activation of c-myc (16). Therefore, immunoreaction of c-myc and c-fos gene products was expected in the nuclei of the proliferating or differentiating cells in the gallbladder tissues. This hypothesis was confirmed by the present findings that c-myc and c-fos oncogene products were occasionally seen in nuclei of the cells in the gallbladder tissues. The present data also demonstrated more abundant c-myc and c-fos oncogene product in malignant lesions than in non-malignant lesions and normal tissues of the gallbladder. In situ hybridization study also demonstrated significant amount of c-myc and c-fos messenger RNA especially in malignant lesions of the gallbladder (10). Furthermore, these gene products were also seen in the entire area of the cytoplasm as well as nuclei of malignant cells suggesting deteriorated regulatory role of cell proliferation and differentiation of c-myc and c-fos in malignant cells. Further studies are required to elucidate whether overexpression of c-myc and c-fos is

the primary or secondary event of carcinogenesis of the gallbladder.

Higher serum level of CA19-9 is well documented in cancer cases of gastrointestinal and biliary tracts (5,8). It has been reported that immunohistochemical positive rate of CA19-9 was more than 70% (1, 12, 20). In accordance with results of these studies, immunohistochemical positive rate of CA19-9 in carcinoma tissues of our cases was 85%. As for immunohistochemical staining pattern of CA19-9, most carcinoma cases displayed cytoplasmic type without polarity. However, no significant staining reaction of CA19-9 was detected in 7 out of 47 carcinoma cases. This discrepancy of the results could be ascribed to several factors such as technical failure and sialosylated Lewis antigen-related epitope of CA19-9. In normal cases, immunohistochemical positive rate of CA19-9 was 71% but immunohistochemical staining pattern was exclusively cytoplasmic type with polarity. Thus, CA19-9 was predominantly restricted to the apical surface in non-malignant lesions, and was distributed over the entire cell surface in malignant lesions. These abnormalities in cell surface expression of CA19-9 suggest the antigen reversion of carcinoma cells toward embryonic cells in carcinogenesis. Further studies are required to examine the relationship between expression of oncogenes and antigen reversion.

REFERENCES

- 1) Ariyoshi, Y., Kuwahara, M., Akatuka, H., and Kitou, K.: CA19-9 as a new diagnostic tool for disease of the liver, biliary tract and pancreas. *KANTANSUI* 11: 525-531 (1985).
- 2) Alitao, K., Schwab, M., Lin, C. C., Varmus, H. and Bishop, J. M.: Homogeneously staining chromosomal regions contain amplified copies of an abundantly expressed cellular oncogene (c-myc) in malignant neuroendocrine cells from a human colon carcinoma. *Proc Natl Acad Sci USA* 80: 1707-1711 (1983).
- 3) Armelin, H. A., Armelin, M. C. S., Kelly, K., Stewart, T., Leder, P., Cochran, B. H. and Stiles, C. D.: Functional role for c-myc in the mitogenic response to platelet-derived growth factor. *Nature* 310: 655-660 (1984).

- 4) Collin, S. and Groudine, M.: Amplification of endogenous myc-related DNA sequences in a human myeloid leukaemia cell line. *Nature* **298**: 679-681 (1982).
- 5) Del Villano, B. C., Brennan, S., Brock, P., Bucher, C., Liu, V., McClure, M., Rake, B., Spase S., Westrick, B., Schoemaker, H. and Zurawski, V. R. J.: Radioimmunometric assay for a monoclonal antibody-defined tumor marker, CA19-9. *Clin Chem* **29**: 549-552 (1983).
- 6) Erisman, M. D., Rothberg, P. G., Diehl, R. E., Morse, C. C., Spandorfer, J. M., and Astrin, S. M.: Deregulation of c-myc gene expression in human colon carcinoma is not accompanied by amplification or rearrangement of the genes. *Mol Cell Biol* **5**: 1969-1976 (1985).
- 7) Gonda, T. J. and Metcalf, D.: Expression of myb, myc and fos proto-oncogenes during the differentiation of a murine myeloid leukaemia. *Nature* **310**: 249-251 (1984).
- 8) Gupta, M. K., Arciaga, R., Bocci, L., Tubbs, R., Bukowski, R. and Deodhar, S. D.: Measurement of a monoclonal-antibodydefined antigen (CA19-9) in the sera of patient with malignant and nonmalignant diseases. Comparison with carcinoembryonic antigen. *Cancer* **56**: 277-283 (1985).
- 9) Hamada, Y., Yamamura, M., Hioki, K., Yamamoto M., Nagura, H., and Watanabe, K.: Immunohistochemical study of carcinoembryonic antigen levels. *Cancer* **55**: 136-141 (1985).
- 10) Hamada, Y., Toda, T., Nagamine, M., Miura, M., and Sugamata, M.: In situ hybridization study of c-myc gene in non-malignant and malignant thyroid tissues. *J Med Soc Toho, Japan* (in press).
- 11) Kelly, K., Cochran, B. H., Stiles, C. D., and Leder, P.: Cell-specific regulation of the c-myc gene by lymphocyte mitogens and platelet-derived growth factor. *Cell* **35**: 603-610 (1983).
- 12) Kishimoto, H. and Futamura, Y.: Immunohistochemical study of CEA and CA19-9 in biliary tract epithelium. *Jpn J Gastroenterol* **83**: 2402-2410 (1986).
- 13) Koprowski, H., Stepkowski, Z., Mitchell, K., Herlyn, M., Herlyn, D. and Fuhrer, P.: Colorectal carcinoma antigens detected by hybridoma antibodies. *Somatic Cell Genet* **5**: 957-971 (1979).
- 14) Lehn, P., Sigaux, F., Grausz, D., Loiseau, P., Castaigne, S., Degos, L., Flandrin, G., and Daury, F.: C-myc and c-fos expression during interferon alpha therapy of hairy cell leukemia. *Blood* **68**: 967-970 (1986).
- 15) Mavilio, F., Sposi, N. M., Petrini, M., Bottero, L., Marinucci, M., De Rossi, G., Amadori, S., Mandelli, F. and Peschle, C.: Expression of cellular oncogenes in primary cells from human acute leukemias. *Proc Natl Acad Sci USA* **83**: 4394-4398 (1986).
- 16) Muller, R., Bravo, R., and Burckhardt, J.: Induction of c-fos gene and protein by growth factors precedes activation of c-myc. *Nature* **312**: 716-720 (1984).
- 17) Rabbitts, P. H., Watson, J. V., Lamond, A., Foster, A., Stinson, N. A., Evan, G., Fischer, W., Atherton, E., Sheppard, R. and Rabbitts, T. H.: Metabolism of c-myc gene products; c-myc mRNA and protein expression in the cell cycle. *EMBO J* **4**: 2009-2015 (1985).
- 18) Riou, G., Le, M. G., Le Doussal, V., Barrois, M., George, M., and Hale, C.: C-myc proto-oncogene expression and prognosis in early carcinoma of the uterine cervix. *Lancet*, *i*, 761-763 (1987).
- 19) Rothberg, P. G., Erisman, M. D., Diehl, R. E., Rovigatti, U. G., and Astin, S. M.: Structure and expression of the oncogene c-myc in fresh tumor material from patients with hematopoietic malignancies. *Mol Cell Biol* **4**: 1096-1103 (1984).
- 20) Sasaki, R.: Immunohistochemical study of cancer-associated carbohydrate antigens in carcinoma of the biliary tract. *J Jpn Surg Soc* **90**: 1976-1988 (1988).
- 21) Shibuya, M., Yokota, J. and Uehara, Y.: Amplification and expression of cellular oncogene (c-myc) in human gastric adenocarcinoma cells. *Mol Cell Biol* **5**: 414-419 (1985).
- 22) Slamon, D. J., De Kernion, J. B., Verma, I. M., and Cline, M. J.: Expression of cellular oncogenes in human malignancies. *Science* **224**: 256-262 (1984).
- 23) Sternberger, L. A., Hardy, P. H., Jr., Cuculis, J. J. and Howard, G. M.: The unlabeled antibody enzyme method of immunohistochemistry. Preparation and properties of soluble antigen-antibody complex (Horseradish peroxidase-antihorseradish peroxidase) and its use in identification of spirochetes. *J Histochem Cytochem* **18**: 314-333 (1970).
- 24) Yamashita, S., Ong, J., Fagin, J. A., and Melmed, S.: Expression of the myc cellular proto-oncogene in human thyroid tissue. *J Clin Endocrinol Metab* **63**: 1170-1173 (1986).