



Title	A Case of Primary Trabecular Carcinoid of the Ovary
Author(s)	Toda, Takayoshi; Shiroma, Hajime; Toda, Yumiko; Hamada, Yuhshi; Yamada, Mamoru; Nakama, Benjamin
Citation	Acta medica Nagasakiensia. 1989, 34(2-4), p.134-138
Issue Date	1989-12-09
URL	http://hdl.handle.net/10069/15775
Right	

This document is downloaded at: 2020-09-17T19:41:08Z

A Case of Primary Trabecular Carcinoid of the Ovary

Takayoshi TODA¹, Hajime SHIROMA², Yumiko TODA³,
Yuhshi HAMADA⁴, Mamoru YAMADA⁴ and Benjamin NAKAMA⁴

1 Clinical Laboratory Department, University Hospital,
University of the Ryukyus

2 Department of Gynecology, School of Medicine, University
of the Ryukyus

3 Division of Internal Medicine, Chuzan Hospital, Okinawa

4 Department of Surgery, School of Medicine, University of
the Ryukyus

Received for publication, December 26, 1987

SUMMARY : A case of trabecular carcinoid originating in the left ovary is presented. Clinically, no signs of carcinoid syndrome were noted. Various examinations including X-ray and CT, especially of gastrointestinal tracts and pelvic organs, revealed that the tumor mass is originated from the left ovary. Histologically, the resected tumor exhibited trabecular pattern of tumor cells, which contained numerous argentaffin and argyrophilic granules. Immunostaining of NSE and calcitonin was strongly demonstrated in tumor cells. On ultrastructural examination, tumor cells had uniformly round shape granules, which were interpreted as neurosecretory granules. These findings clearly indicate that this neoplasm is primary trabecular carcinoid of the ovary.

INTRODUCTION

Since STEWART *et al.* (12) reported the first case of carcinoid tumor arising in an ovarian teratoma in 1939, ovarian carcinoids including both primary and metastatic forms, although relatively unusual, have been well documented in the medical literature (4,5,6). SOGA *et al.* (10) reported histological types of carcinoid tumors such as insular, trabecular, acinar or atypical mixed types. Most are of the insular type having the pattern typically observed in carcinoids of midgut derivation. It has been reported that trabecular form, which has a ribbon pattern typical of carcinoids arising in foregut or hindgut derivatives, is less common (5). Recently, we experienced a case of primary trabecular carcinoid of the ovary

without any manifestation of carcinoid syndrome. The paper describes the histologic, ultrastructural, and immunohistologic features of this rare condition of the ovary.

A CASE REPORT

In the middle of December 1987, 74-year-old woman, gravida 6, para 6, was admitted to our hospital with chief complaint of abdominal fullness.

Physical examination disclosed abdominal distension and slight pretibial pitting edema. On pelvic examination, a tumor mass was felt in the left lower quadrant. CT and Echo revealed a solid tumor with multiple cysts suggesting of ovarian carcinoma. A total of 2,500 ml of bloody ascites was collected. The cytological examination was negative for

malignancy. Laboratory findings were as follows : Serum alpha-fetoprotein, carcinoembryonic antigen, and serotonin were within normal range, whereas CA12-5 was markedly elevated to 885 (normal <35). With a clinical diagnosis of ovarian carcinoma, a total abdominal hysterectomy and bilateral salpingo-oophorectomy were performed in January 1988. Biopsy of the omentum and the regional lymph-nodes indicated no evidence of metastases.

MATERIALS AND METHODS

Tissues for light microscopy were collected from the resected uterus and the ovaries which were fixed in 10% neutral buffered formaldehyde solution. They were dehydrated, embedded in paraffin, and cut at 4 micron in thickness. Sections were stained with hematoxylin and eosin (H & E), Mallory Azan, periodic acid-Schiff (PAS), Masson-Fontana for argentaffin granules and Grimelius for argyrophilia. The immunoperoxidase technique (11) was used to demonstrate the neuron-specific enolase (NSE) and calcitonin. During the frozen section examination, small pieces of samples were collected for electron microscopy. The tissues were fixed in 3% phosphate-buffered glutaraldehyde, washed in phosphate buffered solution, and were postfixed in 1% osmium tetroxide. They were then dehydrated in increasing concentrations of ethanol and were embedded in spur resin. The thick sections were stained with toluidine blue to locate lesions. Thin sections were cut with diamond knives and were stained with uranyl acetate and lead citrate for electron microscopic examinations with a Hitachi electron microscope.

PATHOLOGICAL FINDINGS

The left ovary had a solid, homogeneous, firm tumor with partial cystic change, measuring 27×19 cm in size. The right ovary and uterus showed almost intact appearance (Fig. 1). No evidence of tumor dissemination was noted in the abdominal cavity. Light microscopic examination showed tumor cells with oblong nuclei and finely dispersed chro-

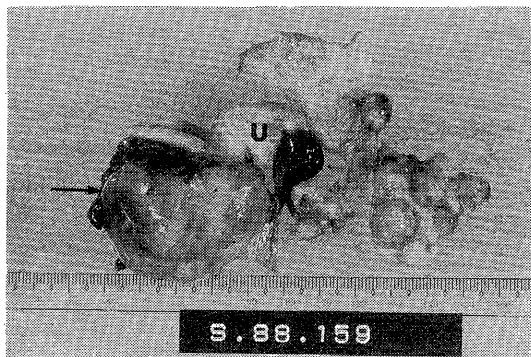


Fig. 1. Transected left ovarian tumor (arrow) and uterus (U).

matin. Mitotic nuclei of the tumor cells were rarely seen. Most of the tumor cells showed trabecular or ribbon patterns (Fig. 2-A and B). In some area, alveolar arrangement of tumor cells was observed (Fig. 3). The tumor cells had abundant cytoplasm in which argyrophil granules were moderately demonstrated (Fig. 4). On the other hand, the tumor cells showed

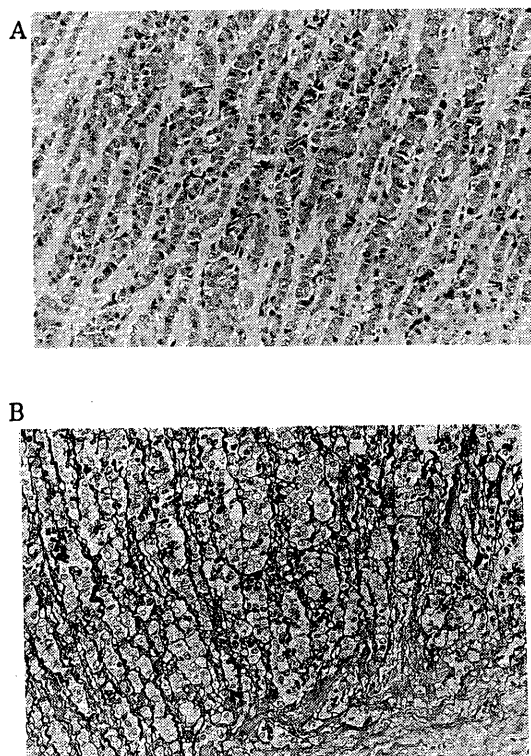


Fig. 2. Trabecular pattern of tumor cells (A : H & E ×170, B : Silver impregnation ×170).

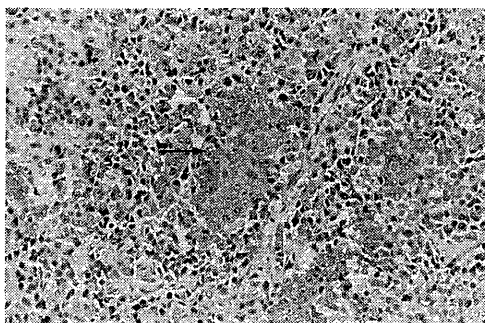


Fig. 3. Alveolar pattern of tumor cells (H & E $\times 170$).

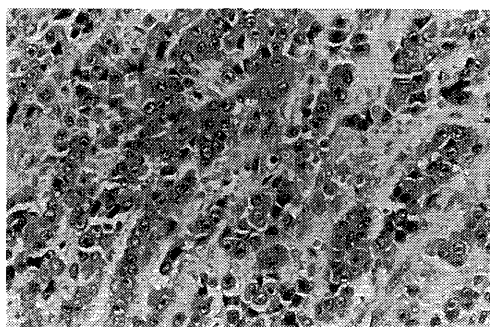


Fig. 6. Positive immunoperoxidase reaction for calcitonin is diffusely demonstrated (PAP $\times 340$).




Fig. 4. Note moderately positive argyrophil granules in tumor cells (Grimelius strain $\times 170$).

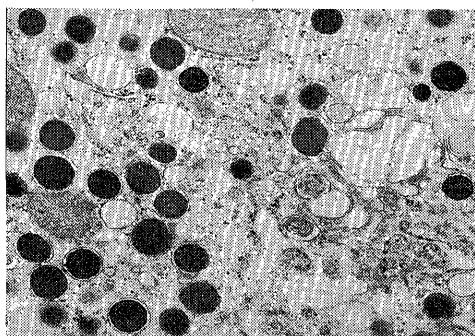


Fig. 7. Electron micrograph of ovarian carcinoid tumor cells containing abundant membrane-bound dense core granules (arrow) ($\times 24,000$).

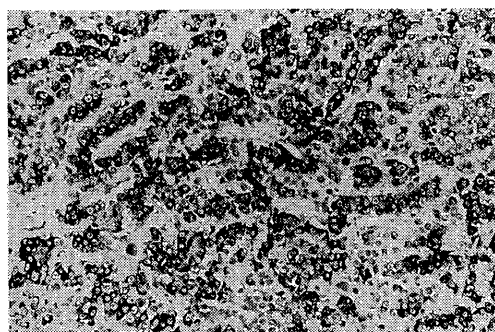


Fig. 5. Numerous strongly positive argentaffin granules are demonstrated (Masson-Fontana stain $\times 170$).

intracytoplasmic granules ranging from 314 to 153 nm in diameter (Fig. 7).

COMMENT

The light microscopic examination of the tumor on Hematoxylin and eosin staining suggested a diagnosis of carcinoid. It was confirmed with the aid of special stains including Masson-Fontana and Grimelius (15). Furthermore, immunostaining of NSE (3) and calcitonin (7) suggested the presence of neurosecretory granules.

numerous intense argentaffin granules (Fig. 5). NSE and calcitonin were positively demonstrated in these tumor cells by the immunoperoxidase method (Fig. 6). Ultrastructural examination of the tumor revealed that there were numerous uniform and round to oval

Carcinoid tumors of the ovary are classified into three main categories; 1) insular carcinoid, 2) trabecular carcinoid, and 3) strumal carcinoid (4, 5, 6, 9). The insular carcinoid is recognized by the presence of cells with central elongated nuclei and abundant

cytoplasm at both poles. The trabecular carcinoid possesses the superficial resemblance of the epithelial ribbons to the cords. The strumal carcinoid is composed of thyroid acini in a carcinoid that is often of the trabecular pattern than insular pattern. According to the classification of carcinoid tumors by ROBBOY *et al.* (4, 5, 6), this neoplasm probably should be classified as trabecular type which is the most rare type.

The majority of ovarian carcinoids have been known to arise within benign cystic teratomas of the respiratory or gastrointestinal epithelium (14). The minority of them have also been encountered with solid teratoma, in mucinous cystic tumors, or in pure forms (8). Therefore, it has been recommended by ROBBOY *et al.* (6) that careful evaluation of the intestinal tract as well as the opposite ovary is essential before concluding that the tumor is a primary carcinoid tumor of the ovary in a case where a unilateral carcinoid tumor of the ovary was not associated with obvious teratomatous elements. However, in our case there were no findings such as peritoneal metastases and bilateral ovarian involvement suggesting carcinoid metastasis to the ovary. We, therefore, concluded that the present carcinoid tumor occurred primarily in the left ovary.

It has been reported that among three types of carcinoid tumors, insular carcinoids give rise to the carcinoid syndrome in about one-half of instances, but no trabecular carcinoids produce the carcinoid syndrome (6). Despite the presence of abundant secretory granules in our case, there were neither elevation of plasma 5-hydroxy-indolacetic acid nor signs of the carcinoid syndrome such as the flushing and intractable diarrhea (13). FUKUSHIMA *et al.* (2) speculated that non-functioning tumors are incapable of forming active hormones or have enzymic defects.

From the histochemical and ultrastructural view points, Black (1) proposed three types of the histogenesis of carcinoid tumors; 1) type I-foregut (argyrophil positive, uniform-sized granules), 2) type II-midgut (argtrophil and argentaffin positive, pleomorphic granules), and 3) type III-hindgut (argyrophil negative,

uniform-sized granules). It has been reported that trabecular carcinoids contain few argentaffin granules histochemically and pleomorphic granules ultrastructurally (5). However, present case had both argentaffin and argyrophil granules histochemically and uniform-sized granules ultrastructurally. Such discrepancies are also noted by BLACK (1) who stated that the correlation of his classification of histogenesis of carcinoid tumors is not rigid.

The prognosis of the trabecular carcinoid is uncertain because there are few reported cases of trabecular carcinoid with long-term follow-up studies. ROBBOY *et al.* (5) reported that 1 of 18 cases of primary trabecular carcinoid of the ovary had a recurrence after 2 years and died after five and a half years. In addition, they suggested that since primary carcinoid of the ovary behaves in a benign fashion in most cases, regardless of their histologic subtype, surgery alone is the adequate therapy for the trabecular carcinoids clinically confined to the ovary (5).

REFERENCES

- 1) BLACK, W. C. : Enterochromaffin cell types and corresponding carcinoid tumors. *Lab Invest* 19 : 473-486 (1968).
- 2) FUKUSHIMA, D. K. and GALLAGHER, T. F. : Steroid production in 'nonfunctioning' adrenal cortical tumor. *J Clin Endocrinol. Metab.* 23 : 923-927 (1963).
- 3) HUNTRAKOON, M. : Neuroendocrine carcinoma of the parotid gland. A report of two cases with ultrastructural and immunohistochemical studies. *Human Pathol* 18 : 1212-1217 (1987).
- 4) ROBBOY, S. J., NORRIS, H. J., and SCULLY, R. E. : Insular carcinoid primary in the ovary. A clinicopathologic analysis of 48 cases. *Cancer* 36 : 404-418 (1975).
- 5) ROBBOY, S. J., SCULLY, R. E., and NORRIS, H. J. : Primary trabecular carcinoid of the ovary. *Obstet Gynecol.* 49 : 202-207 (1977).
- 6) ROBBOY, S. J. and SCULLY, R. : Strumal carcinoid of the ovary : An analysis of 50 cases of a distinctive tumor composed of thyroid tissue and carcinoid. *Cancer* 46 : 2019-2034 (1980).
- 7) SCOPSI, L., ARIAS, J., HOJEN, G., RACCHETTI, G., FOSSATI, G. L., and GALANTE, Y. M. :

- Monoclonal antibodies against calcitonin. Characterization and application in light and electron microscopy immunocytochemistry. *Histochemistry* 88 : 113-125 (1988).
- 8) SCULLY, R. E. : Recent progress in ovarian cancer. *Human Pathol* 1 : 73-97 (1970).
 - 9) SCULLY, R. E. : Tumors of the ovary and maldeveloped gonads. AFIP, p. 274-286 (1982).
 - 10) SOGA J. and TAZAWA, K. : Pathologic analysis of carcinoids. Histologic reevaluation of 62 cases. *Cancer* 28 : 990-1003 (1971).
 - 11) STERNBERGER, L. A., HARDY, P. H., CUCULIS, J. J., and MAYER, H. C. : The unlabeled antibody enzyme method of immunocytochemistry. Preparation and properties of soluble antigen-antibody complex (horse-raddish peroxidase-antiperoxidase) and its use in identificatiion of spirocheates. *J. Histoche. Cytochem.* 18 : 315-333 (1970).
 - 12) STEWART, M. J., WILLES, R. A., and SARAN, G. S. W. : Argentaffin carcinoma (carcinoid tumor) arising in ovarian teratoma : A case report of two cases. *J Pathol Bacteriol.* 49 : 207-212 (1939).
 - 13) THORSON, A. : Studies on carcinoid disease. *Acta Med scand (suppl 334)* : 161-132 (1958).
 - 14) TREVENEN, C., BANERJEE, R., and LAUCLAN, S. C. : The ovarian carcinoid. *Cancer* 31 : 1482-1486 (1973).
 - 15) WILLIAMS, R. M. : A light and EM study of ovarian and rectal carcinoid. *Histopathology.* 3 : 19-30 (1979).