



| | |
|------------|--|
| Title | The Effect of Surgical Repair for Pectum Excavatum on Cardiopulmonary Function |
| Author(s) | Tomita, Masao; Koga, Yasunori; Shibata, Koichiro; Matsumoto, Kazuhisa; Onitsuka, Toshio; Sakoda, Koichiro; Maeda, Takami; Hamasuna, Shigehito; Nakamura, Yuzuru; Ayabe, Kimihiro; Omagari, Takeyuki; Uchiyama, Takayoshi; Nakao, Susumu; Tsuji, Yasukuni |
| Citation | Acta medica Nagasakiensia. 1978, 23(1-4), p.21-26 |
| Issue Date | 1978-08-25 |
| URL | http://hdl.handle.net/10069/15604 |
| Right | |

This document is downloaded at: 2020-09-17T16:52:22Z

The Effect of Surgical Repair for Pectum Excavatum on Cardiopulmonary Function

Masao TOMITA*, Yasunori KOGA
Koichiro SHIBATA, Kazuhisa MATSUMOTO
Toshio ONITSUKA, Koichiro SAKODA
Takami MAEDA, Shigehito HAMASUNA

**The Second Department of Surgery
Miyazaki Medical College*

Yuzuru NAKAMURA**, Kimihiro AYABE
Takeyuki OMAGARI, Takayoshi UCHIYAMA
Susumu NAKAO, Yasukuni TSUJI

***The First Department of Surgery
Nagasaki University School of Medicine*

Received for publication, September 10, 1977

In five patients with corrective surgery for pectus Excavatum, the effectiveness of surgical repair were evaluated from the results of pulmonary function test as well as the finding on ECG according to follow-up study postoperatively.

Of five patient undergone the corrective surgery which sternoturnover with costalplasty employed in 4, and sternoplasty alone in 1, all of them were male and the average age except 3 years of age was 14.8 years ranging from 10 to 21 years. There are no manifestation of clinical syndrome in all 5 cases. However, the fair mental growth demands psychologically the early corrective surgery in young children.

By follow-up study after surgical correction for pectus excavatum during a period from 3 months to 3 years and 3 months, the finding on EKG of right ventricular overload revealed the improvement within 2 months after surgical correction in contrast the results of pulmonary function test disclosed no marked changes until 2 months following surgery. From the view of cosmetic efficacy of corrective surgery, sternoturnover with or without costalplasty are one of the advocating operative procedures.

*富田正雄・古賀保範・柴田紘一郎・松本和久・鬼塚敏男・迫田耕一郎・前田隆美・浜砂重仁
**中村譲・綾部公懿・大曲武征・下山孝俊・中尾丞・辻泰邦

INTRODUCTION

The surgical management for pectus excavatum is noted not only as the repair of a malformation producing a cardiopulmonary dysfunction, but also as the indispensable procedures of making a healthy ingrowth mentally. Even at present time, the etiology producing the abnormalities of pectus excavatum is not certified.

Since Brown¹⁾ thought that pectus excavatum is due to a shortened substernal ligament and central tendon of the diaphragma, corrective surgery was designed to relieve the pull of diaphragma and substernal ligament on the sternum. Furthermore, more extensive correction has become to be done by removing the deformed cartilage and elevating the depressed sternum.

Recently Wada and associates²⁾ recommend sternoturnover as corrective procedures. The aim of this present study is to ascertain the effectivenesses of corrective surgery from analyzing results of cardiopulmonary function test with elapse of time following surgery.

CLINICAL METERIAL

Five cases who underwent corrective surgery for pectus excavatum were subjected in these study. 4 of them were over 10 years of age the remaining one was 3 years of age, with severe pectus anomaly and all of 5 cases were boy. Three cases of five were asymptomatic except the slight degree of symptoms such as fatigue and exertional dyspnea in two despite of no having mental stress. (Table 1)

The size of deformities which have been shown as depressed sternum on anterior chest wall were the extent from 13cm to 20cm in length and 4.5cm in depth. Preoperative results of pulmonary function test and finding of ECG were analyzed in comparison to postoperative changes. The coexisting spinal deformities were observed in 4 of 5 cases of whose age were over 10 years old. Sternoturnover with costalplasty were applied on 4 cases except one undergone sternoplasty alone.

There were 4 complications in 5 patients. Pneumothorax in 3 cases resulted in injuries of the pleura following operative procedures of being free from adhesion between the pleura and the sternocostal cartilage. All of them responded to drainage by chest tube placed during operation. Wound infection occurred in one. However, none of them seriously compromised the final operative results.

Table 1. Cases with corrective surgery for pectus excavatum

| age | sex | size of deformity | coexisting deformity | subjective complaint |
|-----|-----|-------------------|----------------------|----------------------|
| 10 | ♂ | 13 × 8 × 2.5 | scoliosi | (—) |
| 11 | ♂ | 13 × 6 × 3 | scoliosis | fague |
| 17 | ♂ | 20 × 13 × 4.5 | scoliosis | exertional dyspnea |
| 21 | ♂ | 15 × 17.5 × 2.6 | scoliosis | (—) |
| 3 | ♂ | 6 × 8 × 2.3 | (—) | (—) |

RESULTS

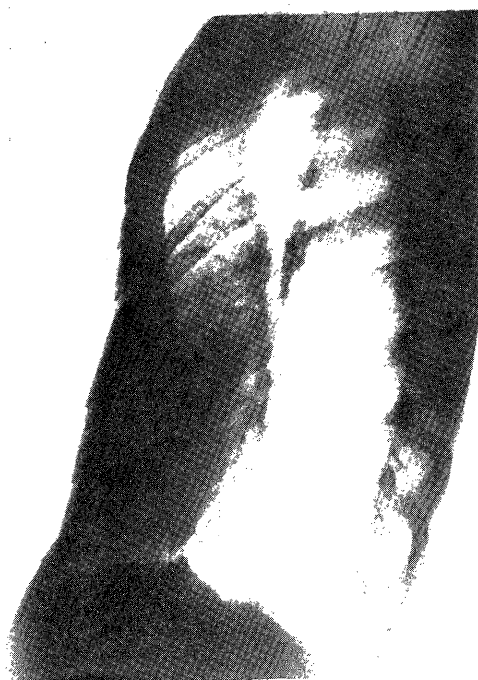The 5 patients have been followed postoperatively from 9 months to 3 years and 3 months (table 2). No patients have died and all of 5 patients have a good results which no any depressed sternum and no abdominal protuberance are seen in apperance at the time of follow-up study as fig 1. As operative procedures, sternoturnover with costalplasty were employed in 4 cases. The remaining one had sternoturnover alone.

Table 2. Preoperative and postoperative finding on ECH

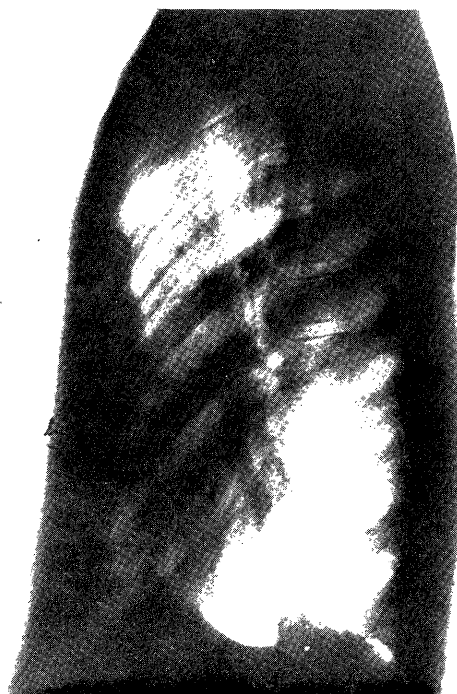| OP. method | sternoturnover | | | | | | | | sternoplasty | |
|----------------|-----------------------------|---------------|--------------------|-------------------|--------------------------|------------------|--------------|-----------------------|---------------|-------------------|
| Pt | 10y. old. boy | | 11y. old. boy | | 17y. old. boy | | 3y. old. boy | | 21y. old. boy | |
| finding on ECH | pre op | 3 yrs 3M p.o. | pre op | 1 yrs 7M p.o. | pre op | 1 yrs 2M p.o. | pre op | 9M p.o. | pre op | 11M p.o. |
| P | aV biphasic | aV negative | split | III biphasic | V simist- rocardiale | | | | | |
| O | III abnormal | III abnormal | | | | | | | | |
| RS | III notch V split | | aV notch IUBB | III notch | III V V notch IRBB | III V V notch | | II split III notch | | |
| T | III V flat V negative | aV flat | III aV negative | III V negative | aV flat V negative | V negative | | | | III V negative |

Fig 1. Corrected deformity of the sternum by sternoturnover for peactum excavatum on chest x-p.

preoperative state



postoperative state



From the study of pulmonary function preoperatively and postoperatively as shown in Fig 2, there were demonstrated the pattern of ventilatory failure on pulmonary function test in all of them up to at least 2 months after surgery, that is, the postoperative levels of %VC were low in comparison with preoperative value despite of being no any differences in both values of FVC and %MBC, According to these results, the stability of thoracic wall after corrective surgery requires the duration of more than 2 months and there is unable to observe the improvement of ventilatory function even though the compression from depressed sternum is removed by the repair of pectum excavatum. By the analysis of finding on ECG during preoperative and postoperative periods as shown in table 2 a notch formation of QRS pattern on ECG and a depression of T wave were persistently shown in 3 cases for 2 months to 2 years and 3 months postoperatively. In 2 of 5 cases, the finding of right bundle branch block on ECG disappeared within 2 months after a correction of deformities reflecting the relieve of right ventricular overload by the compression of pectus excavatum. one had the finding of axis deviation on ECG after surgery. Postoperative complication encountered in 3 cases (table 3). All of these 3 cases had pneumothorax during operation, there are no any troublesome on postoperative course because of responding to tube drainage. One of these 3 cases had infections wound healed within 1 month after surgery under local administration of antibiotics. Postoperative

Fig 2. Results of pulmonary function test
(changes of % VC, % FVC and % MBC)

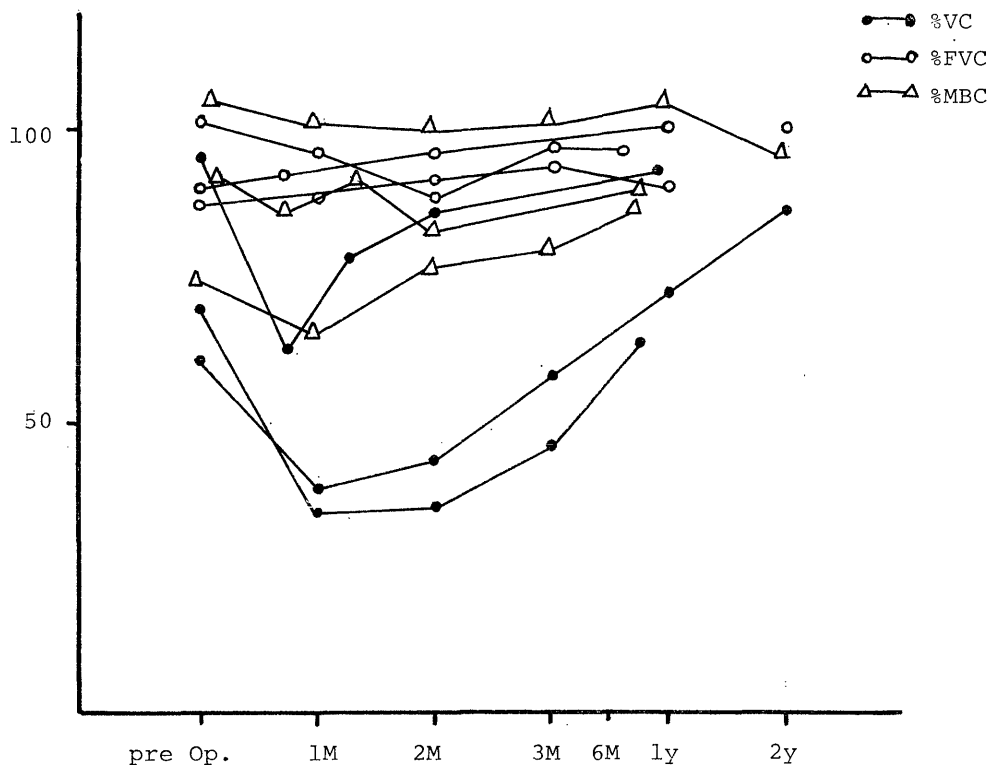


Table 3. Postoperative complication

| Complication | No. |
|-----------------|-----|
| Pneumothorax | 3 |
| right | 2 |
| bilateratl | 1 |
| Wound infection | 1 |
| total | 4 |

courses were uneventful after sternoturnover as well as sternoplasty. Especially the repair in child at the age of 3 years had a good results same as that in old children.

COMMENT

Surgical repair of pectus excavatum is necessary to achieve not only the removal of the cause which influences on cardiopulmonary function but also cosmetic and mental improvement.

Recently the repair of pectus excavatum at an early age is recommended. In this series, we had an experience with the repair of one child under 3 years of age. The result of surgical correction in this age was satisfactory without any complication. The age in remaining 4 cases were ranging from 11 to 21 of age but there were no remarkable coexisting cardiopulmonary dysfunction.

In the cases of young age the old children, concomittant spinal deformities such as scoliosis were prominents. It is suggesting that a long-term existing pectus excavatum might be attribute to provoke the spinal deformity. From this consideration, the early corrective surgery is adovocated for prevent from development of spinal deformity. The indication for performing the surgical repair might be ruled out by various conditions. However, it is believed that early repair of marked pectus excavatum in young children is efficacious in providing a suitable body contour without occurrence of spinal deformity. One of the aim of this study is to make clear as to whether functional improvement with reference to cardiac activity and ventilatory capacity are recognized or not. As a indicator of ventilatory capacity, %VC, %FVC, %MBC and RV/TLC were measured respectively to assess the operative benefit.

Up to at least 2 months after operation, the improvement of pulmonary function following corrective surgery had not entirely been observed. Epsccially the value of %VC revealed low compared with preoperative value, whereas the levels of %MBC and %FVC were similar to that of preoperative values.

From above results it seems that ventilatory capacity in pulmonary function decreased during at least 2 months following the repair of pectum excavatum owing to instability of thoracic wall produced by surgical corective procedures such as sternoturnover with costal-plasty. Despite of the effort of surgical treatment in removal of mechanical compression added to the lung, the fragility produced on thoracic wall by corrective surgery results in covering

and concealing the advantage of the repair of pectus excavatum.

The evaluation of circulatory function was also carried out from the finding of ECG. By existing pectus excavatum, the pattern of right ventricular overload on ECG was well defined in the young over 10 years of age. It seems that a long standing pectum excavatum might produce the overloading of the right ventricle and restrictive ventilatory failure. However, the impaired pattern on ECG of right ventricular function disappeared within approximately 1 month after surgery.

It is obvious that the early application of the repair for pectum excavatum prevent subsequent progressive spinal deformity and mental stress. In spite of unknown etiology with reference to pectus excavatum, the various kinds of operative procedures are designed to correct the deformities cosmetically and relieve the cardiopulmonary dysfunction physiologically. These corrective surgery were also enough to alleviate mental stress psychologically.

The superiority of efficacious correction for deformity of pectus excavatum was recognized in surgical technique of sternotomomy with costalplasty.³⁾⁴⁾ However, this operative procedures induced restrictive ventilatory failure resulted in the instability of thoracic wall during approximately 2 months postoperatively.

Furthermore, it is emphasized that early repair of pectum excavatum in children around 3 years of age brings about good results with less time consuming and less debilitating rather than in older children or adult.

REFERENCES

- 1) BROWN, AL ; pectus excavatum (funnel chest) anatomic basis : surgical treatment of incipient stage in infancy and correction of deformity in fully developed stage. *J. Thorac Surg.*, 9 : 164, 1939
- 2) WADA. J., IKEDA. I., ISHIDA. T., et al. : Results of 271. funnel chest operation. *Ann. Thorac. Surg.*, 10 : 526, 1970
- 3) HALLER, J. AJr., PETER, G. N., MAZUR, D., et al. : Pectus excavatum a twenty year surgical experience. *J. Thoracic Cardiovasc. Surg.*, 60 : 375, 1970
- 4) BEISEN, G. D., EPSTEIN, S. E., STAMPFER, M., et al. : Impairment of cardiac function in patients with pectum excavatum with improvement after operative correction. *N. Engl. J. Med.*, 287 : 267, 1972