



Title	Reconstructive Surgery of Poliomyelitic Disabled Hand and Arm with particular Reference to Opponens Plasty
Author(s)	Tamaki, Takuo; Tomonaga, Hajime; Kanemitsu, Satoshi; Kurokawa, Norio; Egawa, Tadashi; Matsushita, Akinari; Morisada., Chikami
Citation	Acta medica Nagasakiensia. 1963, 8(1-2), p.1-13
Issue Date	1963-12-25
URL	http://hdl.handle.net/10069/15472
Right	

This document is downloaded at: 2020-09-17T16:41:00Z

Reconstructive Surgery of Poliomyelitic Disabled Hand and Arm with particular Reference to Opponens Plasty

Takuo TAMAKI, Hajime TOMONAGA, Satoshi KANEMITSU,
Norio KUROKAWA, Tadashi EGAWA, Akinari MATSUSHITA,
and Chikami MORISADA.

*Department of Orthopedic Surgery
Nagasaki University, School of Medicine
Nagasaki, Japan*

Received for publication June 1, 1963

The purpose of this report is to give light on problems concerning surgical reconstruction of the hand and arm disabled by poliomyelitis. Before any surgical intervention, too much attention cannot be placed to the over-all gain sought for the patient. With regard to opponens plasty, it must be emphasized that there are inherent obstacles against the complete reconstruction of poliomyelitic thumb. Authors have come to conclude that no stereotyped measure can be made for any weak thumb.

At the Nagasaki Crippled Children's Hospital we have operated on 38 poliomyelitic children with disabled arms and hands for the past seven years. The series consists of 38 children whose age distribution appears in Table 1.

Table 1
Age distribution of 38
children operated on

Age at operation	No. of children
2-5 years	5
6-10 years	14
11-15 years	15
over 16	4
Total	38

Table II
Operation undertaken on 38 patients
with poliomyelitic sequelae

Shoulder fusion	21
Tendon transfer of shoulder	6
Elbow flexor plasty	4
Wrist fusion	2
Opponens plasty	18
Miscellaneous	6
Total	57

In Table II a survey of the type of operation is given. A total of 57 operations have been performed. The period from the onset to operation is 1~13 years.

The purpose of this paper is to define the problems concerning surgical reconstruction of the hand and arm disabled by poliomyelitis with special reference to opponens plasty.

Basic Principles

In line with the general view expressed in previous literatures, we believe, certain favorable conditions exist in poliomyelitis, which are not always present in the traumatic hand or peripheral nerve injury. They are as follows; (1) good skin and subcutaneous tissue, (2) normal sensation, and (3) good mobility of the joints. On the other hand, some unfavorable conditions are found, which cannot be neglected.

Among the unfavorable conditions the following are the most important: (1) disseminated muscle weakness, (2) substitution patterns, and (3) involvement of the trunk and other extremities.

These conditions are believed to make surgical rehabilitation of the poliomyelitic hand and arm more difficult and more unreliable.

Irwin et al discussed these unfavorable conditions in detail and stated that in no other field where rehabilitation of the hand and arm is a problem, is the danger of "examining the patient's hand through a hole in the blanket" so great as it is in poliomyelitis. We have reached same conclusion.

Before surgical intervention is undertaken, it is essential to evaluate carefully patients as a whole and consider whether they are (1) ambulatory with the aid of apparatus, (2) with or without the aid of crutches, (3) and, confined to a wheel chair. Some surgical measures which are of great benefit to one patient may be of great harm to the other. The surgeon cannot be qualified for the reconstructive surgery unless he can make sure of some profits from surgery with regard to patient's capability as a whole. In a nutshell, he should make a surgical intervention only on the basis of needs and potentialities of patients (NISSEN - LIE. IRWIN et al)

Fig. 1 A, for example, shows a girl who has been confined to a wheel chair. She had both flail shoulders, flail elbows, right flail wrist, and disseminated muscle weakness in trunk and both lower extremities as well.

If arthrodesis of wrist and shoulder had been conventionally performed in this case, it might have deprived her of ability to drive her wheel chair which was the only way of locomotion. She obtained considerable benefit from the use of the assistive suspension feeder apparatus after she had undergone the elbowflexor plasty and opponens plasty in both sides (Fig. 1 B). We had a boy who was deprived of capability

of walking with the aid of crutches as a result of the previous wrist arthrodesis including the distal radio-ulnar joint.

Although he fortunately became ambulatory without the aid of crutches as a result of the subsequent operation on the lower extremities, it is undeniable that rehabilitational period was prolonged.

Specific Procedures.

Shoulder fusion

Speaking of end results of shoulder fusion, it seems to us that technique employed in accomplishing the operation is less important than the postoperative position of shoulder and after care. Fig. 2 A and B illustrate the patient of 11 years of age whose right shoulder was fused six years ago. We have found that his fused arm assumed a position of accentuated internal rotation and did not come to the side. He was greatly discontented with the fact that his right arm did not come to the side, and complained of his inability to put his right hand into his pocket. This failure is, in our opinion, mainly due to surgeon's miscalculation. It was brought about largely because too little attention was paid to the relative position of the humerus and scapula, and too much attention to the humerus in relation to the trunk. As a result, the actual angles of abduction between the humerus and scapula came out much larger than expected. Another major failure is thought to have been brought about by negligence in holding shoulder joint immobilized at acceptable angles of internal rotation. It cannot be overemphasized that it is very important for surgeons to recognize the fact that the shoulder joint will come to internal rotation at 40~45 degrees, if the upper arm is abducted and the forearm is kept horizontally. (Report of the Research Committee of the American Orthopedic Association 1942).

We believe that it is better to fuse the shoulder in greater internal rotation but never more than 45 degrees, if the elbow and the hand on one side are weak, while the same members on the opposite side are normal. Otherwise, the shoulder should be kept immobilized in internal rotation of less than 45 degrees.

Tenoplasty in Shoulder and Elbow

Fig. 3 shows a successful example in which the trapezius had been transferred in order to restore shoulder abduction according to the modified Mayer's procedure. The presence of normal or almost normal rotator cuff is said to be prerequisite to this success. In full accordance with other authors, we believe in principle that this intervention should be undertaken on isolated or partial paresis of the m. deltoideus, and an arthrodesis is the sole procedure in the case of wide spread paresis

with loose joint.

Strictly speaking, therefore, this tendon transference is rarely indicated in poliomyelitic residual state. The advantage of tenoplasty over arthrodesis, however, lies in the fact that the capability of rotating the arm will be preserved to such extent that the patient can use his arm more freely. Although many arthors are skeptical of the reliability of tenoplasty, it seems to us that thoughtful surgeons should give serious consideration to the possibility of employing tenoplasty before they undertake arthrodesis as is the usual case. We are of opinion that we should make an all-out effort to enhance the possibility in the use of tenoplasty in shoulder. It is urgently necessary to find out some substitutes for invalid rotator cuff.

For flail elbows we have tried several methods with a view to obtain active elbow flexion. We prefer Höpf's method to Steindler's, if the powerful m. pectoralis major is available. Steindler's method is most frequently used, but it cannot correct the defective supination which usually follows the biceps paresis. The cases operated on, however, are too few to draw definite conclusions.

Opponens-plasty

The defective opposition is not uncommon sequela of poliomyelitis and its correction has been a serious problem to orthopedic surgeons.

This study is based on an evaluation of the end results in twelve poliomyelitic operations in which the sublimis tendons of the ring or long finger were transferred to the thumbs according to Bunnell's principle. Those patients who had undergone operations by Roeren's method were excluded from the series. Following Riordan's idea, we made some modification in insertion. The sublimis tendon was spilt into two segments. One of them was inserted in the short abductor tendon, and the other was fixed on the dorsal ulnar portion of the proximal phalanx of the thumb as proximal as possible.

The age of the patients at operation varied from 2 to 16 years. The interval between the onset and the operation was one to thirteen years. Needless to say, both the two powerful long flexors of the ring or long finger and good passive mobility in the thumb were indispensable conditions of operation. The duration of observation ran between one and five years. The results were classified into three groups according to Erick Severin.

- Excellent : Opposition achieved, turning the top of thumb into a good grip with the index finger and long finger or further.
- Good : Good grip, thumb-index-long finger, but without complete rotation of the thumb.
- Bad : Others.

The results were excellent in three, good in four and bad in five cases. Generally speaking, so long as the operation was successful the results depended on the preoperative assets in disabled hand including residual power of the hand, stability of the metacarpophalangeal, carpometacarpal joint and favorable conditions of soft tissues around the thumb, especially on whether the stable carpometacarpal joint or the powerful extrinsic muscles of thumb was present or not. In regard to technical fault, the following should be noted. On the occasion of passage of flexor sublimis tendon around the tendon of the m. flexor carpi ulnaris, it happened sometimes that on stretching the weak flexor carpi ulnaris muscle, the former migrated proximally and thus took a wrong direction and consequently it pulled to no effect. In such a case, BUNNELL'S method of forming a pulley by means of severed strip from the tendon of the m. flexor carpi ulnaris proved to be effective.

The method recommended by PALAZZI where the sublimis tendon is passed beneath the m. abductor digiti quinti, and drawn round the pisiforme bone appears to be very attractive but we have no clinical experience with it.

There was another problem in opponens plasty. We were confronted with the so-called substitution or trick movement pattern. Fig. 4 A illustrates an example of substitution pattern in which the m. extensor pollicis longus played a leading role. The patient of 7 years was able to show correct pinch voluntarily (Fig 4 B), but showed a substitution pattern when he held chopsticks.

Faulty patterns are difficult to overcome, and are believed to have been acquired early and have become deeply ingrained. On the other hand, there is a patient of sixteen years who has no substitution pattern that interferes with successful opponens plasty. Although it seems to us that there is close relationship between the presence of substitution pattern and elapsing period since the onset of illness, we believe that the latter does not play a decisive role in it.

A survey of these unsatisfactory results has made it clear that in poliomyelitis with varying degrees in the paralysis of the extrinsic muscles as well as intrinsic muscles of the thumb, a standard operation cannot be undertaken. Therefore we made more precise biomechanical analysis of opposition with the poliomyelitic thumb taken into account.

In the course of reviewing the previous literatures it became evident that not enough attention was given to the question of analysing the opposition in poliomyelitis.

Opposition can be divided into motions in three planes, x.y. and z, each plane moving at right angle to each other, i. e., rotation, palmar abduction and adduction which are produced by combined coordinated actions of intrinsic, extrinsic muscles of the thumb.

Participation of each motion and each muscle action in complete

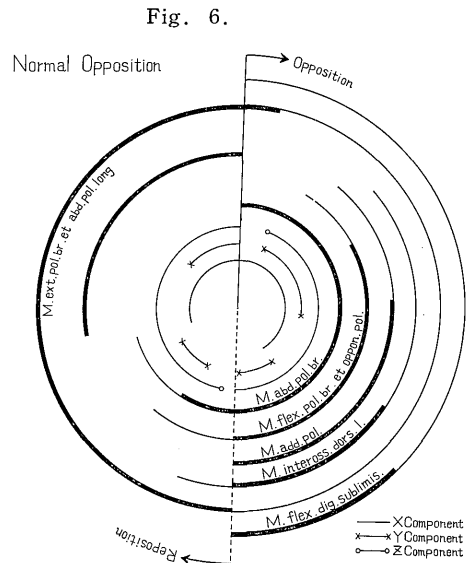
arc of opposition can be recorded by means of specially designed apparatus combined with electromyography. This apparatus consists of two attachments and a transducer (Fig. 5).

Transducer has the multiaxial joint movable in three planes. With the attachments fixed to the distal palmar crease and dorsal portion of distal phalanx of thumb respectively, subject was instructed to carry on effortless opposition from thumb in resting position to little finger or index finger. Since each motion in three planes following arc of opposition is arranged to elicit change of electric resistance, it can be separately transformed into a variation of electrical output through D. C. circuits. Electromyogram was recorded by surface electrodes, and following muscles were sampled., m. extensor pollicis brevis, abductor pollicis longus, flexor digitorum sublimis besides thenar muscles. Cathode oscillograph made synchronously possible both recordings of the global trace derived from the muscle by external electrodes and also the electrical output of each motion.

On the basis of data obtained from these experiments, we made up a sort of integral spectrum which enabled us to define the sequential participation of each motion and each muscle action in complete arc of opposition.

In normal group definite and regular patterns were consistently obtained. Fig. 6 illustrates a spectrum of normal opposition between thumb and little finger. Magnitude, phasic change, and sequential participation of each motion were found to be regular. Among three motions, rotation, i. e., X-component had the greatest amount of magnitude and accounted for about 50% of total amount, and palmar abduction, i. e. Y-component, adduction, i. e., Zcomponent were estimated at twenty five percent, each.

Electromyograms made during the opposition of the thumb indicated that this movement was not only initiated, but also carried on by the m. abductor pollicis brevis. Its activity reached the maximum immediately after the initiation and continued unchanged until the end without interruption. Activity of the abductor pollicis longus muscle was observed during the entire course of the motion, but it reached its greatest magnitude in the initial stage of opposition. The m. flexor pollicis brevis, opponens



pollicis, adductor pollicis and dorsal interosseus came into play in regular sequence and each muscle increased its activity toward the termination of the opposition.

In poliomyelitic hands, however, even if results were rated excellent, their spectra differed in pattern from case to case as well as from those of normal hands in regard to irregular motion and incoordinate muscular activity.

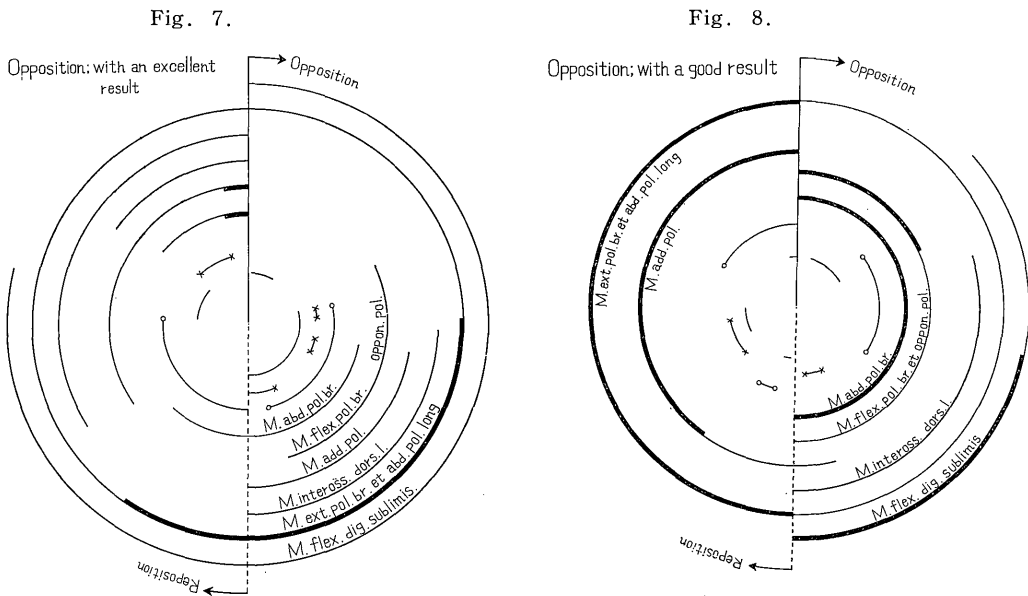


Fig. 7 shows the spectrum of poliomyelitic thumb opposition rated excellent.

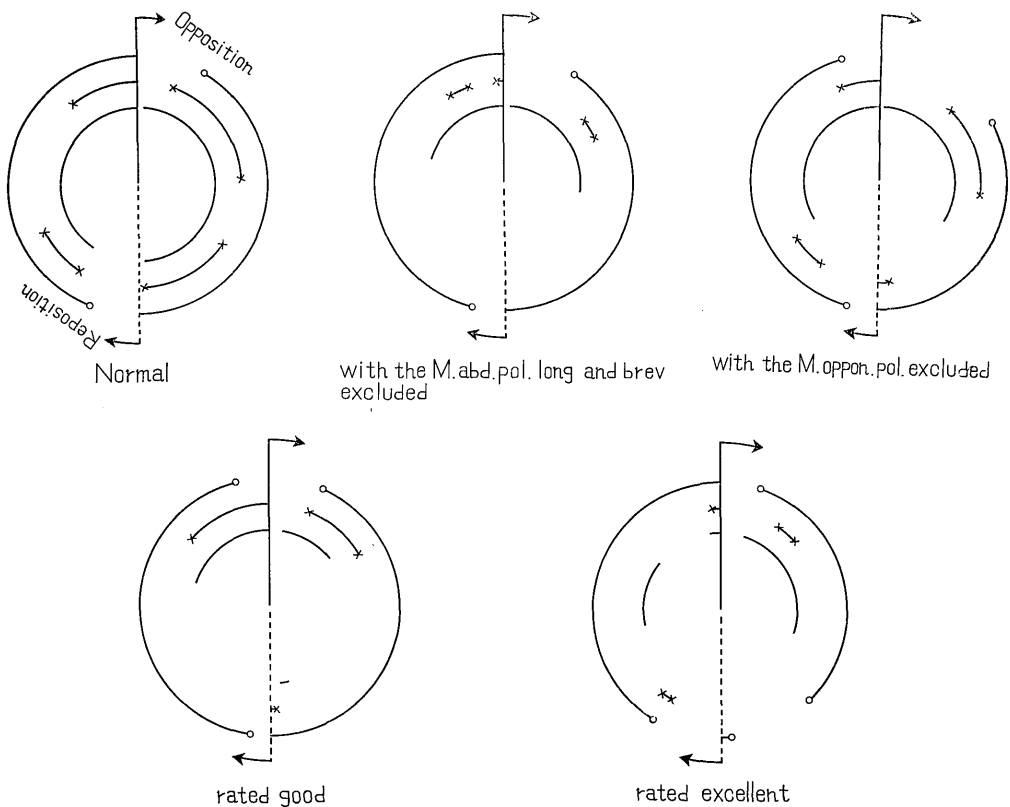
Substitution pattern of this patient is illustrated in Fig. 4 A. Preoperative conditions were : Good extrinsic, intrinsic muscles of thumb except for weak abductor pollicis brevis and defective opponens pollicis muscle. Generally speaking, there were diminished magnitude, and irregular, shortranged and interrupted participation of each motion. Muscular action also follows in irregular sequence.

Fig. 8 shows another spectrum of poliomyelitic thumb rated good. Preoperatively this patient had poor extrinsic muscles, especially the weak m. abductor pollicis longus as well as poor thenar muscles. Each motion was more irregular, fragmentary and short-ranged than in Fig. 7. Additionally, incoordinate muscle action was observed. Activity of the abductor pollicis brevis muscle was detectable but had no practical effect.

In this connection it should be noted that skeletal models played an important supplementary role in revealing the action of each of thenar muscles.

Taking the maximal amplitude of the normal m. abductor pollicis brevis as a standard, we calculated the share of each muscle in the complete opposition and translated it into a variety of tension of each rubber band so as to produce a situation similar to living one in skeletal model. Then, three dimensional analysis was made in the same way. The manner in which each motion in three planes followed, and the degree to which the normal condition was approached is thought to depend on which thenar muscles are excluded. When the working model was given the combined tension of rubber band equal to tension in a normal person, it showed almost the same pattern in each motion as in normal persons (Fig. 9). Sole exclusion of the rubber band equivalent to the opponens pollicis muscle produced a pattern similar to one of poliomyelitic hand which was rated excellent (Fig. 9).

Fig. 9.



Three dimensional analysis in skeletal model

With the m. abductor pollicis longus and brevis excluded, the pattern was closely like to one of poliomyelitic hand which was rated good (Fig. 9).

There have been many concepts concerning the mechanism of opposition.

DUCHENNE stated that opposition derived from the combined actions of the abductor pollicis brevis, the flexor pollicis brevis and the opponens pollicis with emphasis of the major role of the short abductor of thumb. BUNNELL and KAPLAN agreed with Duchenne's conclusion : KAPLAN, however, ascribed greater importance than did DUCHENNE to the abductor pollicis longus and extensor pollicis brevis in activating the sway of the thumb. Bunnell described opposition as a combination of rotation and angulation occurring at the carpometacarpal and metacarpophalangeal joints, with the abductor pollicis longus and both extensors serving as stabilizers. STEINDLER analyzed as follows : first, extension produced by the two extensors ; then abduction by the two abductors ; and finally, pronation by the opponens and the flexor pollicis brevis.

Among these opinions there is no unanimous agreement with respect to mechanism of opposition. Particular concern has been turned to the question of role of combined muscular action and sequential participation of motion in entire course of opposition. Not only this question remains unsettled, but also emerges as a pending controversial subject.

From our experimental analysis it became evident that : (i) instantaneously after initiation of opposition rotation started going on during almost the entire course of opposition until the latter one-third of arc. , : (ii) palmar abduction and adduction supervened simultaneously after a split second, and the former had some interruption in the latter half of course, while the latter continued toward the end of opposition without interruption. We ascribed rotation to combined action of the m. abductor pollicis brevis, opponens pollicis and flexor pollicis brevis with equal share. Palmar abduction was to a large extent attributed to activities of long and short abductors of thumb. Activity of the adductor pollicis that increased in intensity toward the end of opposition aided not only in performing adduction, but also counteracting against the activity of first dorsal interosseus and contributing to extension of the distal phalanx of thumb. According to Mc FARLANE the m. adductor pollicis and the abductor pollicis brevis constitute as much as 50% of power of extension of distal segment of thumb.

In poliomyelitic hands palmar abduction component was found to be most difficult to restore, and the weak abductor pollicis longus was usually responsible for defective palmar abduction. From the view point in full accordance with Kaplan's concept that long abductor of thumb plays a decisive role in performing the integral opposition, we came to definite conclusion that some measure reinforcing or substituting for its weakness needs to be added to so-called opponens plasty. Because of almost the same range of excursion as the abductor pollicis longus, the extensor carpi radialis longus is expected to be of best choice for

replacing the abductor pollicis longus weakness. An instance where the extensor carpi radialis longus was transferred to first metacarpal basis on the ground of such idea, revealed satisfactory result.

Opposition is a complex coordinate movement produced by the combined actions of so many muscles under the vast cortical control and regulated by the proprioceptive information originating from each of muscles. In poliomyelitic hands with variable combination of paralysis substitution pattern far from normal coordinate muscular action may become deeply ingrained and interfere with successful opponens plasty.

There is inherent obstacle against restoration of opposition in poliomyelitis.

It is too optimistic to consider the complete restoration of opposition to be realistic.

In this connection it may be desirable to take a counter measure against defective opposition at earliest possible date after onset of illness before incoordinate pattern becomes established.

SUMMARY

1. On the occasion of surgical intervention of the hand and arm disabled by poliomyelitis the over-all gain sought for the patient is of primary importance. An intervention which is of great benefit to one patient may be harmful to the other.

2. As far as the postoperative results of shoulder fusions are concerned, the technique employed is not so important as the postoperative immobilization of shoulder in right position. Too much attention cannot be placed to relative position of the humerus to the scapula.

3. A biomechanical study was made with the idea of attempting to learn in what mechanism the opposition might be expected to occur.

4. There are inherent obstacles against the reconstruction of poliomyelitic thumb.

5. No standard measure can be used conventionally for any weak thumb.

6. Palmar abduction is found to be most difficult to restore and the weak abductor pollicis longus is responsible for defective palmar abduction.

7. For weakness of the abductor pollicis longus the extensor carpi radialis longus, if available, is suitable for replacing the former.

Fig 1. A

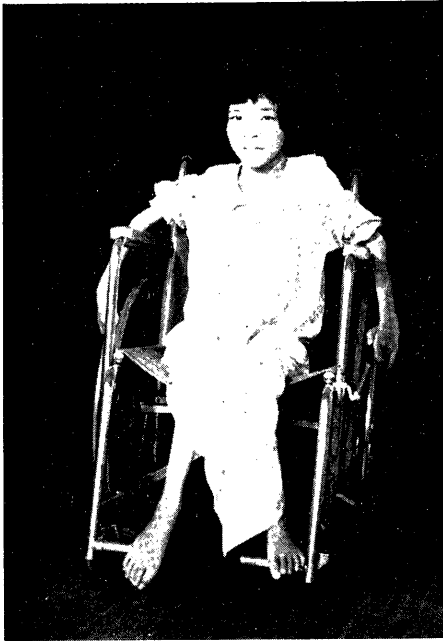

Fig 1. B

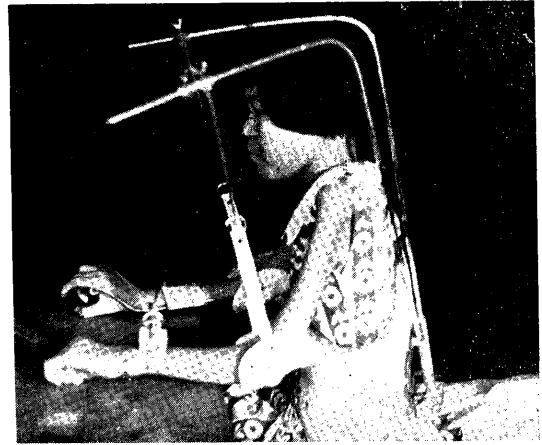


Fig 2. A

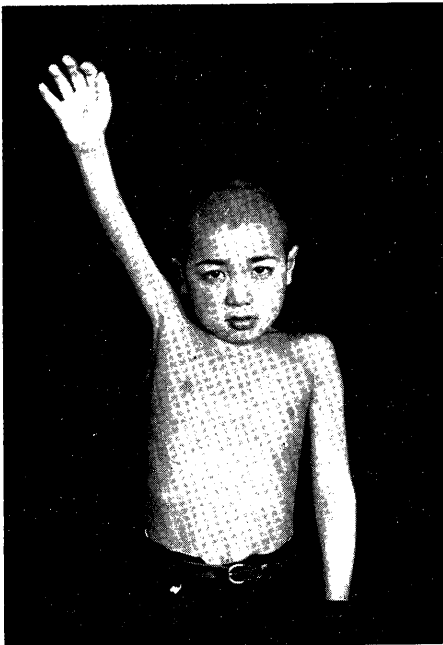


Fig 2. B

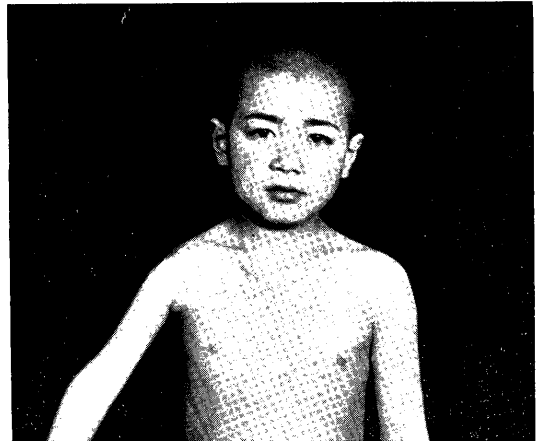


Fig 3.

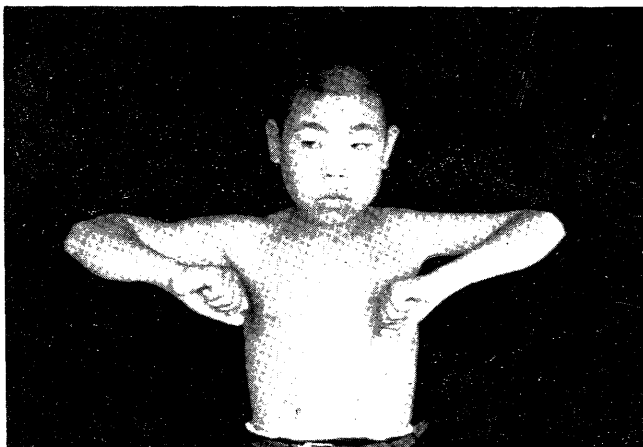


Fig 4. A

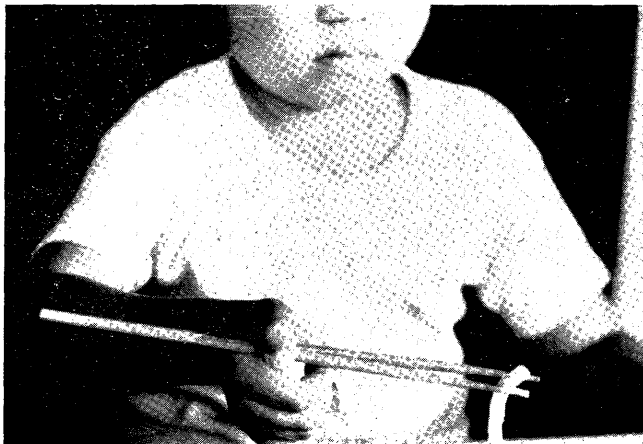


Fig 5.




Fig 4. B



REFERENCES

- 1) BJNNELL, S., : Surgery of the Hand. 3rd. Ed. Philadelphia, J.B. Lippincott. Co., 1956.
- 2) FOWLER, S. B., : Discussion of paper by GOLDNER, J. S. *J. Bone & Joint Surg.*, 35-A : 131, 1953.
- 3) GOLDNER, J.L., : Deformities of the Hand Incidental to Pathological Changes of the Extrinsic and Intrinsic Muscle Mechanisms. *J. Bone & Joint Surg.*, 35-A : 115, 1953.
- 4) IBID et al : An Analysis of Paralytic Thumb Deformities. *J. Bone & Joint Surg.*, 32-A : 627, 1950.
- 5) IRWIN, C. E. et al : Surgical Rehabilitation of the Hand and Forearm Disabled by Poliomyelitis., *J. Bone Joint Surg.*, 33-A : 825, 1951.
- 6) JACOBS, B. et al : Opposition of the Thumb and Its restoration. *J. Bone & Joint Surg.*, 42-A : 1015, 1960.
- 7) KAPLAN, E. B., Functional and Surgical Anatomy of the Hand Philadelphia, J. B. Lippincott. Co., 1953.
- 8) LITTLER, J. W., : Tendon Transfers and Arthrodeses in Combined Median and Ulnar Nerve Paralysis. *J. Bone & Joint Surg.*, 31-A : 225, 1949.
- 9) MCFARLANE' R.M., : Observations on the Functional Anatomy of the Intrinsic Muscles of the thumb. *J. Bone & Joint Surg.*, 44-A : 1073, 1962.
- 10) NISSEN-LIE, H. S., : Discussion in Proceedings of the Nordic Orthopedisk Förenings 28th Assemblg in Helsingfors June 1956.
- 11) PALAZZI, A.S., : On the Treatment of the Loss of opposition. *Acta orthop. Scand.*, 32 : 396, 1962.