

CASE REPORT

Atypical Foreign Body Aspiration in a Pediatric Palliative Care Patient: a Case Report

Çocuk Palyatif Bakım Hastasında Atipik Bir Yabancı Cisim Aspirasyonu: Olgu Sunumu

¹Ganime Ayar , ²Süleyman Arif Bostancı , ²Şükriye Demirkaya 

¹Sağlık Bakanlığı, Ankara Şehir Hastanesi, Çocuk Hastanesi, Çocuk Sağlığı ve Hastalıkları; Çocuk Palyatif Bakım Kliniği, Bilkent, Ankara, Türkiye

²Sağlık Bakanlığı, Ankara Şehir Hastanesi, Çocuk Hastanesi, Çocuk Cerrahisi, Bilkent, Ankara, Türkiye

Correspondence

Ganime Ayar, Sağlık Bakanlığı, Ankara Şehir Hastanesi, Çocuk Hastanesi, Çocuk Sağlığı ve Hastalıkları; Çocuk Palyatif Bakım Kliniği, Bilkent, Ankara, Türkiye

E-Mail: ganimedayar@gmail.com

How to cite ?

Ayar G, Bostancı SA, Demirkaya Ş. The atypical foreign body aspiration in a pediatric palliative care patient: case report. Genel Tıp Derg. 2022; 32(2): 225-228

ABSTRACT

The foreign body aspiration into the respiratory system is an emergency with a high mortality rate when diagnosis and treatment are delayed, which can cause complications and repeated hospitalizations. Although it is especially common in children under the age of five, it can be seen at any age in chronically ill children with neurological problems. However, it is rarely seen in pediatric patients with a tracheostomy who are dependent on a home mechanical ventilator due to their nutritional style and severe neurological retardation. In this study, foreign body aspiration that developed in a pediatric patient with a tracheostomy who was followed up with a home mechanical ventilator and fed from gastrostomy was presented.

Key words: aspiration, foreign body, palliative care, child

ÖZ

Solunum sistemine yabancı cisim aspirasyonu mortalitesi yüksek olan, tanı ve tedavide gecikildiğinde komplikasyonlara ve tekrarlı yatışlara neden olabilen acil bir durumdur. Özellikle beş yaş altı çocuk hastalarda sık görülmesine rağmen, nörolojik problemlere sahip kronik hasta çocuklarda her yaşta görülebilir. Ancak trakeostomili ve ev tipi mekanik ventilatöre bağımlı yaşayan çocuk hastalarda ağır nöroloji gerilik ve beslenme şekli ile ilgili olarak nadiren görülmektedir. Bu çalışmada trakeostomili ve ev tipi mekanik ventilatör ile izlemde olan ve gastrostomiden beslenen bir çocuk hastada gelişen yabancı cisim aspirasyonu sunulmuştur.

Anahtar kelimeler: aspirasyon, yabancı cisim, palyatif bakım, çocuk

Introduction

Foreign body (FB) aspiration is a life-threatening condition that is frequently encountered in childhood, especially in young children under the age of five (1). Children with swallowing problems are more at risk, especially due to neurological problems such as neuromuscular disorders, mental retardation, and cerebral palsy. (2). However, children with technological medical device-dependency, severe neurological deficits due to underlying chronic diseases, and children who are bedridden constitute a risky group in terms of food aspiration and aspiration pneumonia rather than a foreign body (3). In recent years, mortality has decreased due to the increasing prevalence of neonatal intensive care and pediatric intensive care units, the development of new treatment methods, and the increasing quality of staff and equipment. All these allow children with a low chance of survival to continue their lives with the help of medical equipment and technological devices (4). Therefore, in recent years, these patients have been followed up and treated frequently in outpatient clinics and pediatric emergencies. The increasing number of pediatric patients with chronic problems, who continue their lives dependent on medical devices

requires health professionals to improve themselves, increase their knowledge and experience, and be prepared for emergencies they may encounter.

Case

A six-year-nine-month-old female patient had hypoxia due to hanging and cardiac arrest when she was one and a half years old. Due to severe anoxic brain damage sustained afterward, she had been living with a home mechanical ventilator through a tracheostomy cannula for the last five years. It was learned that the patient had no problems in the last four months and did not go to the hospital, but for the last few hours, she was brought to our pediatric emergency outpatient clinic with a complaint of low oxygen saturation that did not improve despite aspiration, high oxygen and positive pressure ventilation with Ambu. The family stated that "during routine aspiration of the patient through the tracheostomy cannula, the saturation decreased and did not improve despite ambulation". It was learned from her story that she was hospitalized once a year in the winter with respiratory distress, and did not generally have any problems afterward. It was learned that her

last hospitalization was four months ago, and she did not have any problems after that day. In addition, they could not remember when the last tracheostomy cannula was changed. Our patient was the third child of a healthy 31-year-old mother and a 34-year-old father. They had three other healthy children apart from this child. She was taking valproic acid, phenobarbital, and levetiracetam for epilepsy, and oral baclofen for spasticity.

On physical examination, her general condition was moderate, she was conscious, her axillary temperature was 36.6 °C, blood pressure was 105/65 mmHg, heart rate was 118/min, respiratory rate was 52/min, body weight was 25 kg (50% percentile), and her height, 120 cm (25-50% percentile). She had perioral cyanosis, intercostal and suprasternal retractions, and nasal wing breathing. There were widespread coarse crackles on chest auscultation. In the meantime, despite the deep aspiration through the tracheostomy cannula and the change of the cannula by the otolaryngologist, the patient's oxygen saturations did not fully recover. Heart sounds were normal. The liver and spleen were not palpable and the trachea was open. Genitourinary system examination was normal. In the neurological examination, there was no spontaneous movement other than spontaneous blinking, and no meaningful staring or eye-tracking. In addition, the patient had no head control and no unassisted sitting and was retarded in all cognitive and motor functions.

Imaging findings: A chest x-ray was taken from the patient with the preliminary diagnosis of pneumonia. On the chest radiograph, there was an increase in aeration on the right and an image that aroused the suspicion of a foreign body (Figure 1). At the same time, because we were in a pandemic, thorax tomography was taken from the patient. Pandemic viral pneumonia was not considered in the tomography and it was reported as "an 8x10 mm circular foreign body thought to belong to the right main bronchus proximal" (Figure 2). With these findings, the patient was diagnosed with foreign body aspiration. It was consulted with the pediatric surgery department, and rigid bronchoscopy was performed under general anesthesia. On bronchoscopy, a plastic foreign body was seen in the right main bronchus and it was removed. It was seen that the foreign body that came out was the severed end of the plastic tracheostomy cannula (Figure 3). Chest radiography was taken after bronchoscopy was evaluated as normal. After the procedure, the patient was followed up in the pediatric palliative care service, and after stabilization, the patient was discharged to come back for control.

Discussion

Foreign body aspirations are one of the most important causes of preventable mortality in children and mimic the signs and symptoms of other common respiratory diseases (5). The most common symptoms of foreign

body aspiration are usually cough, wheezing, unilateral decrease in lung breath sounds, and dyspnea (5, 6). The patient's history is very important in the diagnosis of FBA. Sudden onset of cough, wheezing, bruising, or breathlessness during feeding or playing with small pieces of toys suggestive of foreign body aspiration. Especially sudden onset and recurrent wheezing is the most common complaint with a rate of 73% to 97%. (3, 6). In our case, there was a sudden onset of wheezing and coughing. However, since our patient is a severe palliative care pediatric patient living with a low glaskow score and is currently being fed with a gastrostomy tube, the possibility of such a foreign body was not initially considered. The reason for sudden respiratory distress in these patients is usually aspiration of food into the respiratory tract or obstruction of the respiratory tract by secretions (7). Children with spasticity, frequent convulsions, and swallowing difficulties are at higher risk in terms of foreign body aspiration (2) however, FBA is usually not the first thing that comes to mind when respiratory distress occurs in children with much more severe neurological conditions, with a tracheostomy, living on a ventilator and fed with a feeding tube (7, 8). In our patient, the first diagnosis that came to mind was pneumonia or solidified secretion plugs. On physical examination of our patient, there were tachypnea, dyspnea, and bilateral rhonchi. In foreign body aspiration, wheezing and decreased breath sounds on the obstructed side are the most common findings on physical examination. In the literature, a decrease in lung sounds was observed in 50-68% of cases (5, 6, 9). Normal examination findings can be detected less frequently. (9). Contrary to the literature, in our case, there was no decrease in respiratory sounds by listening to the right AC on chest auscultation, and bilateral coarse crackles were heard. In cases with suspected foreign body aspiration, chest radiography is first performed in the diagnosis. In different publications, the specificity and sensitivity of thoracic radiology are between 45-50% and 66-73%, respectively, and it has been reported that a lung tomography can be requested in necessary cases (10, 11). The lung radiography of our patient may have been sufficient for the diagnosis, but the fact that we were at the beginning of the pandemic period (covid-19) required a lung tomography to be taken. Lung tomography (CT) is not necessary in every case.

In children, aspirated objects tend to be located more on the right side, since the left main bronchus is separated at a steeper angle and its diameter is narrower (5). In our case, FB was in the right main bronchus, which is consistent with the literature.

Because of its high morbidity and mortality, bronchoscopy should be performed when necessary in cases with suspected FBA. Fiberoptic bronchoscopy is the gold standard for the diagnosis and localization of airway foreign body and provides treatment along with the diagnosis (12). Peripherally located and small FBs can be safely and successfully removed

using a fiberoptic bronchoscope (12). It also allows the visualization of organic materials, which are non-radiopaque and thus not visible on radiography. Interestingly, the foreign body removed from our patient after bronchoscopy was the lower end part of the tracheostomy cannula. There was no information in the file about the last time our patient's tracheostomy cannula was changed and how long it had been used. The family could not remember either. We could not obtain clear information about the time of cannula change, since it is not always followed up in our hospital, and it is sometimes examined in hospitals closer to home. But we estimated it had not been changed for at least four months. There is not enough data in the literature regarding the change time of the tracheostomy cannula. Different times are written on the user manuals regarding the replacement times of different brands of cannulas. In a limited number of data, it has been stated that it is necessary to comply with these periods, especially to prevent infection. (13, 14). Tracheostomy cannula tubes and recommended replacement periods vary according to the brand, as a minimum of 28 days and a maximum of 30 days, in the "child care and follow-up booklet with tracheostomy for healthcare professionals" issued by the Pediatric Chest Diseases Association in 2021. (<https://www.cocukgogus.org/tr/saglikcalisanlaricin-trakeostomili-cocuk-bakim-ve-izlem-kitapcigi-a>). The times here are the same as those specified in the user manuals of the brands. We see that the cannulas of patients who are not followed up very well or who do not apply to the hospital sometimes remain unchanged for months in practice. We think that it may be very difficult to comply with these deadlines, especially for patients with low glaskow scores, who are completely dependent on equipment and home-type mechanical ventilators, who have trouble getting to and from the hospital, and their families. Since we are in the pandemic period, bringing these patients to the hospital may have created additional reservations for their families, or the family may not have been informed or warned about cannula change times. In addition, they may have had difficulties in finding health personnel who are equipped with the skills to change cannula. Often, home care teams may not have a physician with enough experience with this equipment. For all these reasons, the cannula change period sometimes extends to months or even years, and the family may not remember the last time it was changed, as seen in our case. One of the most common complications in prolonged cannula use is an increased risk of respiratory tract infection (13). Interestingly, we observed that mechanical complications such as rupture of the tracheostomy cannula tip and obstruction in the airway may occur in this case. We wanted to present such a rare case and share our experience.

In conclusion, foreign body aspiration maybe another underlying cause of respiratory distress in patients with tracheostomy followed on a home mechanical ventilator with the diagnosis of chronic respiratory

failure. For each pediatric patient followed up with a tracheostomy cannula, the physician should inquire about the time of cannula change as part of the patient's history, and record the date of the last cannula change in the patient's file. Home care teams and palliative care teams should have know this issue. Families should also be informed about this issue by their follow-up physician, and a "follow-up card" should be created, which will facilitate patient follow-up. Regular data entry of tracheostomy cannula change times into patients records will prevent possible complications.

References

- 1.Foreign body aspiration. 2021; Available at: <https://www.ncbi.nlm.nih.gov/books/NBK531480/#article-21917.s4>. Accessed 14 February 2022.
- 2.DeRowe A, Massick D, Beste DJ. Clinical characteristics of aerodigestive foreign bodies in neurologically impaired children. *International journal of pediatric otorhinolaryngology*. 2002;62(3):243-8.
- 3.Weir K, McMahon S, Barry L, et al. Oropharyngeal aspiration and pneumonia in children. *Pediatric pulmonology*. 2007;42(11):1024-31.
- 4.Chelluri LP. Quality and performance improvement in critical care. *Indian journal of critical care medicine: peer-reviewed, official publication of Indian Society of Critical Care Medicine*. 2008;12(2):67.
- 5.Na'ara S, Vainer I, Amit M, Gordin A. Foreign body aspiration in infants and older children: a comparative study. *Ear, Nose & Throat Journal*. 2020;99(1):47-51.
- 6.Bajaj D, Sachdeva A, Deepak D. Foreign body aspiration. *Journal of Thoracic Disease*. 2020;13(8):5159-75.
- 7.Hirsch AW, Monuteaux MC, Fruchtman G, Bachur RG, Neuman MI. Characteristics of children hospitalized with aspiration pneumonia. *Hospital pediatrics*. 2016;6(11):659-66.
- 8.Chiaravalli J, Lufesi N, Shawa E, et al. Management of an obstructed tracheostomy in a limited-resource setting. *Cureus*. 2017;9(5).
- 9.Tanrıverdi Hİ, Şenel U. Çocuklarda yabancı cisim aspirasyonlarında, fizik muayene ve radyografi bulgularının tanıdaki etkinlikleri. *Çocuk Cerrahisi Dergisi*. 29(1):35-9.
- 10.Sattar A, Ahmad I, Javed AM, Anjum S. Diagnostic accuracy of chest x-ray in tracheobronchial foreign body aspiration in paediatric patients. *Journal of Ayub Medical College Abbottabad*. 2011;23(4):103-5.
- 11.Silva AB, Muntz HR, Clary R. Utility of conventional radiography in the diagnosis and management of pediatric airway foreign bodies. *Annals of Otolaryngology, Rhinology & Laryngology*. 1998;107(10):834-8.
- 12.Dikensoy O, Usalan C, Filiz A. Foreign body aspiration: clinical utility of flexible bronchoscopy. *Postgraduate medical journal*. 2002;78(921):399-403.
- 13.Barros CE, Almeida JAd, Ayres GHdS. Pediatric tracheostomy: epidemiology and characterization of tracheal secretion-a literature review. *Revista da Associação Médica Brasileira*. 2020;65:1502-7.
- 14.Avelino MA, Maunsell R, Valera FCP, et al. First Clinical Consensus and National Recommendations on Tracheostomized Children of the Brazilian Academy of Pediatric Otorhinolaryngology (ABOPe) and Brazilian Society of Pediatrics (SBP). *Brazilian journal of otorhinolaryngology*. 2017;83:498-506.

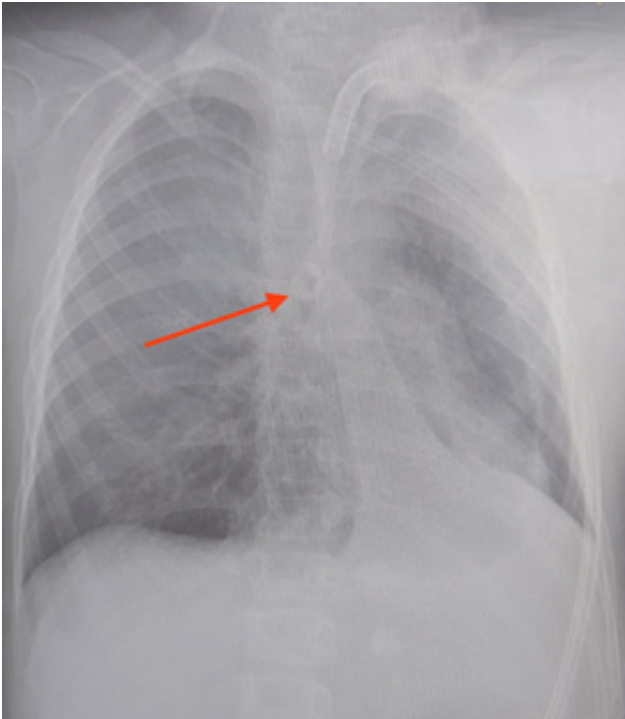


Figure 1: The radiopaque round middle part radiolucent image in the area corresponding to the right main bronchus on direct X-ray

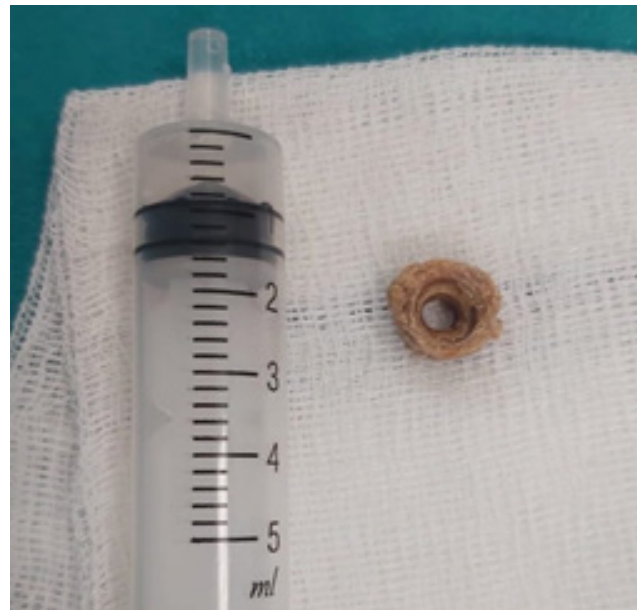

Figure 3: Deformed image of the foreign body removed by bronchoscopy.

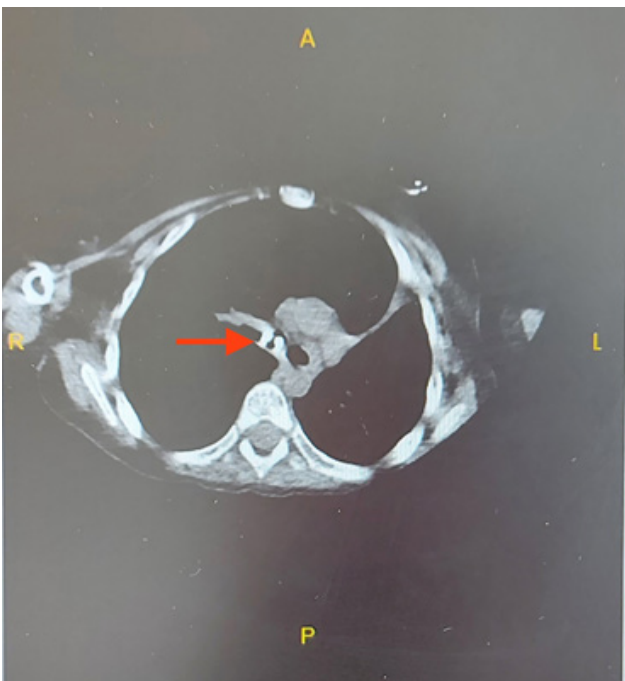


Figure 2: Foreign body image in the right main bronchus in computed tomography