



# Effect of PDE 5 Inhibitor-Avanafil on Renal Ischemia/Reperfusion Injury in Rats

## Sıçanlarda Renal İskemi/Reperfüzyon Hasarı Üzerine PDE 5 İnhibitörü-Avanafilin Etkisi

• Tuğba Nurcan YÜKSEL<sup>1</sup>, • Zekai HALICI<sup>2</sup>, • Cihangir KAYA<sup>3</sup>, • Ayşe BOZKURT<sup>4</sup>, • Taha TAVACI<sup>5</sup>, • Maide Sena CİVELEK<sup>6</sup>,  
• Bengül ÖZDEMİR<sup>7</sup>

<sup>1</sup>Tekirdağ Namık Kemal University Faculty of Medicine, Department of Pharmacology, Tekirdağ, Turkey

<sup>2</sup>Atatürk University Faculty of Medicine, Department of Pharmacology-Clinical Research, Development and Design Application and Research Center, Erzurum, Turkey

<sup>3</sup>İstanbul Pendik Veterinary Control Institute, Diagnostic Department, İstanbul, Turkey

<sup>4</sup>Van Yüzüncü Yıl University Faculty of Medicine, Department of Pharmacology, Van, Turkey

<sup>5</sup>Sakarya University Faculty of Medicine, Department of Pharmacology, Sakarya, Turkey

<sup>6</sup>Atatürk University Faculty of Medicine, Department of Pharmacology, Erzurum, Turkey

<sup>7</sup>Kafkas University Faculty of Medicine, Department of Histology and Embryology, Kars, Turkey

### ABSTRACT

**Aim:** Renal ischemia-reperfusion injury (RI/RI) damages many organs, especially the kidney. Phosphodiesterase (PDE) 5 inhibitors has antioxidant and anti-inflammatory effects. Avanafil (AVA) is a second-generation PDE 5 inhibitor with greater PDE isoform selectivity. The aim of this study is to investigate the effects of AVA on RI/RI in rats.

**Materials and Methods:** Forty rats were randomly divided into five groups (n=8): Sham; AVA 10; RI/RI; RI/RI + 5 mg/kg AVA, and RI/RI + 10 mg/kg AVA. RI/RI in rats was established by clamping renal artery. An acute surgical experiment was performed for the induction of renal ischemia for 45 min by renal artery clamping followed by reperfusion for 24 h. Kidney tissues were investigated biochemically [malondialdehyde (MDA) and glutathione (GSH) with ELISA], molecularly [relative quantification of IL-1 $\beta$ , nuclear factor-kappa B (NF- $\kappa$ B), and tumor necrosis factor-alpha (TNF- $\alpha$ ) mRNA gene expression with qRT-PCR], and histopathologically (staining with Harris hematoxylin and eosin Y).

**Results:** AVA administration ameliorated disturbances in MDA and GSH levels caused by RI/RI. AVA treatment improved the increase in the mRNA expressions of IL-1 $\beta$ , NF- $\kappa$ B, and TNF- $\alpha$  in kidney tissues induced ischemia/reperfusion injury. AVA administration ameliorated histopathologic injury in kidney tissues caused by renal ischemia reperfusion. Moreover, the values closest to those of the sham group were obtained by administering 10 mg/kg AVA to rats with RI/RI.

**Conclusion:** AVA administration improved renal ischemia/reperfusion-induced tissue injury by alleviating oxidative stress and inflammatory cascades that could be important in ischemia-reperfusion injury. These findings may provide a mechanistic basis for using AVA to treat RI/RI.

**Keywords:** Anti-inflammatory, antioxidant, avanafil, phosphodiesterase 5 inhibitor, renal ischemia/reperfusion injury

### ÖZ

**Amaç:** Renal iskemi-reperfüzyon hasarı (RI/RI) başta böbrek olmak üzere birçok organa zarar verir. Fosfodiesteraz (PDE) 5 inhibitörleri, antioksidan ve anti-enflamatuvar etkilere sahiptir. Avanafil (AVA), daha yüksek PDE izoform seçiciliğine sahip ikinci nesil bir PDE 5 inhibitörüdür. Bu çalışmanın amacı sıçanlarda RI/RI üzerine AVA'nın etkilerini incelemektir.

**Gereç ve Yöntem:** Kırk sıçan rastgele beş gruba (n=8) ayrıldı: Kontrol; AVA 10 mg/kg; RI/RI; RI/RI + 5 mg/kg AVA ve RI/RI + 10 mg/kg AVA. RI/RI sıçan modeli, renal arter klemplenerek oluşturuldu. Renal arter klempleme ile 45 dakika renal iskemi indüksiyonu ve ardından 24 saat reperfüzyon

**Address for Correspondence:** Tuğba Nurcan YÜKSEL MD, Tekirdağ Namık Kemal University Faculty of Medicine, Department of Pharmacology, Tekirdağ, Turkey

**Phone:** +90 546 573 81 41 **E-mail:** tnyuksel@nku.edu.tr **ORCID ID:** orcid.org/0000-0001-5092-1674

**Received:** 04.06.2023 **Accepted:** 05.07.2023

©Copyright 2023 by Tekirdağ Namık Kemal University / Namık Kemal Medical Journal is published by Galenos Publishing House.  
Licensed under a Creative Commons Attribution-NonCommercial-NoDerivatives 4.0 (CC BY-NC-ND) International License.



için akut bir cerrahi deney yapıldı. AVA, iskemiden 6 ve 1 saat önce oral olarak sonda ile uygulandı. Yirmi dört saatlik reperfüzyondan sonra moleküler ve biyokimyasal inceleme için böbrek dokuları çıkarıldı. Böbrek dokuları biyokimyasal [ELISA ile malondialdehit (MDA) ve glutatyon (GSH)], moleküler [qRT-PCR ile IL-1 $\beta$ , nükleer faktör-kappa B (NF- $\kappa$ B), and tümör nekroz faktörü-alfa (TNF- $\alpha$ ) mRNA gen ekspresyonları] ve histopatolojik (Harris hematoksilen ve eosin Y ile boyama) olarak incelendi.

**Bulgular:** AVA uygulaması, RI/RI'nin sebep olduğu MDA ve GSH düzeylerindeki değişiklikleri iyileştirdi. AVA tedavisi iskemi/reperfüzyon hasarından kaynaklanan böbrek dokularındaki IL-1 $\beta$ , NF- $\kappa$ B ve TNF- $\alpha$  mRNA gen ekspresyonlarındaki artışı düzeltti. AVA uygulaması renal iskemi reperfüzyonun neden olduğu böbrek dokularındaki histopatolojik hasarı iyileştirdi. Ayrıca kontrol grubuna en yakın değerler RI/RI'li sıçanlara 10 mg/kg AVA uygulanması ile elde edildi.

**Sonuç:** AVA uygulaması, iskemi/reperfüzyon hasarında önemli olabilecek oksidatif stresi ve enflamatuvar kaskadları hafifleterek RI/RI kaynaklı doku hasarını iyileştirmiştir. Bu bulgular, RI/RI'yi tedavi etmek için AVA kullanımına ilişkin mekanik bir temel sağlayabilir.

**Anahtar Kelimeler:** Anti-enflamatuvar, antioksidan, avanafil, fosfodiesteraz 5 inhibitörü, renal iskemi/reperfüzyon hasarı

## INTRODUCTION

Kidneys are one of the most perfused organs in the body, making them extremely vulnerable to changes in blood perfusion<sup>1</sup>. They play a pivotal role in physiological functions<sup>2</sup>. In the situation of ischemia/reperfusion, both molecular and cellular events set off an inflammatory cascade that disrupts the normal function of tissues by releasing reactive oxygen species (ROS), amplifying the actions of cytokines, and recruiting leukocytes. Reperfusion is the critical process of providing substrate and oxygen for adenosine triphosphate synthesis to the ischemic tissue. Nevertheless, it exacerbates tissue damage by producing additional ROS<sup>3</sup>. Exaggerated ROS generation causes renal ischemia-reperfusion injury (RI/RI) via ROS-induced anomalous signal pathways, inflammatory infiltration, cellular disorder, and renal cell death<sup>4</sup>. Moreover, reperfusion duration and the re-oxygenation stage are the key causes of negative impacts on the kidney, according to a growing body of evidence<sup>5</sup>. RI/RI can occur following an infarction, sepsis, or organ transplantation, and it magnifies tissue injury by activating an inflammatory cascade that involves ROS, chemokines, proinflammatory cytokines, and leukocytes<sup>6</sup>. The generated ROS triggers lipid peroxidation [with malondialdehyde (MDA) generated as the end product]<sup>7</sup>. Increased MDA levels with lipid oxidation damage cell membrane functions and cellular integrity<sup>8,9</sup>. Increasing the concentrations of nonenzymatic compounds such as glutathione (GSH) stimulates the cellular defense system against oxidative damage<sup>10</sup>. In addition, I/R-induced ROS production causes the activation of nuclear factor-kappa B (NF- $\kappa$ B)<sup>11</sup>. NF- $\kappa$ B activation increases the transcription of pro-inflammatory cytokines including tumor necrosis factor-alpha (TNF- $\alpha$ )<sup>12</sup>. TNF- $\alpha$  can exacerbate the harm to tissues and organs by promoting the production of IL-1 $\beta$  and other inflammatory markers<sup>13</sup>. Thus, many different inflammatory mediators take part in RI/RI. Consequently, pharmacological agents with multiple effects including anti-oxidative and anti-inflammatory, and inhibiting tubular necrosis features may be a hopeful approach for avoiding renal tissue injury.

Phosphodiesterase (PDE) 5 inhibitors are a widely used primary treatment of erectile dysfunction as well as many other illnesses, such as prostatic hyperplasia, hypertension, and coronary heart disease<sup>14</sup>. Preclinical studies have shown that PDE 5 inhibition may mitigate oxidative and inflammatory damage to the kidneys, resulting in decreased albuminuria, glomerular hyperfiltration and hypertrophy, and decreased glomerulosclerosis overall<sup>15</sup>. These renoprotective impacts and enhancements in renal tissue injury could be attributed to PDE 5 inhibitor activity through both hemodynamic and intrarenal antioxidant, anti-inflammatory, and anti-proliferative mechanisms<sup>16</sup>. Avanafil (AVA) is a second-generation PDE 5 inhibitor. The Food and Drug Administration and the European Medicines Agency introduced AVA in 2013 as PDE 5 inhibitor compounds<sup>17</sup>. AVA is more PDE isoform selective and has different physical and chemical characteristics from first-generation PDE 5 inhibitors<sup>18</sup>. In experimental studies, the defensive impacts of various PDE 5 inhibitors on ischemia/reperfusion-induced tissue injury have been individually proven in diverse tissues, including the myocardium<sup>19</sup>, spinal cord<sup>20</sup>, brain<sup>21</sup>, ovary<sup>22</sup>, and even kidney<sup>14</sup>. AVA's effects in various renal situations such as nephropathy have also been studied<sup>23,24</sup>. However, the effect of AVA on renal tissue injury ischemia/reperfusion-induced is not known. In light of this knowledge, we designed to investigate the possible protective effects of AVA on RI/RI in rats. Furthermore, the underlying mechanisms were investigated molecularly, biochemically, and histopathologically.

## MATERIALS AND METHODS

### Animals

In this study, 40 Wistar rats aged 4-5 months (weight: 250-290 gr) were purchased from Atatürk University Medical Experimental Application and Research Center. All the animals were kept in standard plastic cages under standard conditions (temperature: 22 $\pm$ 1 °C, relative humidity: 40-80%, 12 h light-dark cycle). Throughout the experiment, the animals had

unlimited access to the usual rat water and food (ad libitum). All experimental procedures were carried out in accordance with national guidelines for the use and care of laboratory animals.

This animal study and all its protocols were approved by Atatürk University Medical Experimental Application and Research Center of Ethics Committee on 04-04-2022 with document number E-75296309-050.01.04-2200103613.

## Chemicals

The PDE 5 inhibitor, AVA (Qty: 1g) was purchased from the BLDpharm Company (Cat. No: BD289977, MW: 483.95). Xylazine (Basilazin 2%) was obtained from BioTek, Turkey. Ketamine (Ketalar 500 mg/10 mL) was obtained from Pfizer, Turkey. The lab experiments required additional chemicals, all of which were bought from Sigma and Merck (Germany).

## Experimental Strategy

The 40 rats were randomly separated into 5 groups (n=8 per group, Table 1). AVA (5 and 10 mg/kg) was orally administered by gavage 6 and 1 h before the operation, as the half-life of the AVA is 6 hours, in related groups<sup>25,26</sup>.

## Surgical Procedure for Inducing Renal Ischemia/Reperfusion Injury

All animals were anesthetized with an injection of 80 mg/kg ketamine + 8 mg/kg xylazine). After disinfecting the dorsal wall, a 2.5 cm longitudinal incision was made along the posterior dorsal midline area and a right nephrectomy was performed. To achieve RI/RI, a clamp was applied to the vessels for 45 minutes, occluding the renal artery in the kidney. The organ itself was protected from harm with extra care. Color changes throughout the entire kidney provided evidence for the occlusion's effectiveness. The rats were then carefully reperfused for 24 hours to provide blood flowed into the kidneys after the clamp was removed (Table 1)<sup>27,28</sup>. All the animals were kept warm after surgery to protect them from hypothermia. After the completion of the 24 h reperfusion

phase, all rats were anesthetized with a high dose of ketamine-xylazine. All kidney tissues were collected and kept at -80 °C for biochemical and molecular investigations and at 10% formalin solution for histopathological investigations.

## Biochemical Investigations

100 mg of all specimens reserved for biochemical investigations were treated with 1 mL of PBS, ground in liquid nitrogen with a Tissue Lyser II (Qiagen), and centrifuged. Supernatants obtained by centrifugation were used as sample. MDA levels<sup>29</sup> and GSH<sup>30</sup> levels were determined with an enzyme-linked immunosorbent assay (ELISA) reader<sup>31</sup>. MDA and GSH levels of the kidney tissues were expressed respectively as nmol/mg protein. The mean and standard deviation for each set of data was displayed per mg of protein.

## Protein Determination

Utilizing commercial protein standards (Sigma Aldrich, total protein kit-TP0300-1KT-(USA), the Lowry technique was employed to calculate the protein concentrations<sup>32</sup>.

## Molecular Investigations

### Gene Expressions Analyses

A qRT-PCR was designed to assess interleukin 1 beta (IL-1 $\beta$ ), NF- $\kappa$ B, and tumor necro factor- $\alpha$  (TNF- $\alpha$ ) mRNA expression levels. In order to do this, kidney tissues were homogenized, RNA was isolated, cDNA was created, and the expression levels of various mRNAs were quantitatively assessed.

### RNA Extraction from Kidney Tissues

Kidney tissue specimens were measured separately at 20 mg. Specimens were stabilized in RNAlater RNA Stabilization Reagent (Qiagen) and homogenized with the Tissue LyserII (Qiagen). Using the RNeasy Mini Kit Qiagen and following the manufacturer's instructions in Qiaquebe (Qiagen, Hilden, Germany), total RNA was purified. The total amount of mRNA was determined utilizing nanodrop spectrophotometry (All Sheng) at 260 nm<sup>33</sup>.

**Table 1. Experimental groups and designs to investigate the effects of AVA in the renal tissue on RI/RI**

Groups	6 and 1 h before the operation	0 <sup>th</sup> hour ischemia-induced	45 min after ischemia	24 h after reperfusion-induced
1 Sham		Sham operation		Sacrification
2 AVA 10 mg/kg	AVA	Sham operation		Sacrification
3 RI/RI		Ischemia	Reperfusion	Sacrification
4 RI/RI + AVA 5 mg/kg	AVA	Ischemia	Reperfusion	Sacrification
5 RI/RI + AVA 10 mg/kg	AVA	Ischemia	Reperfusion	Sacrification

AVA: Avanafil, AVA 5: 5 mg/kg AVA, AVA 10: 10 mg/kg AVA, RI/RI: Renal ischemia/reperfusion injury

## Reversed Transcriptase Reaction and cDNA Synthesis

cDNA production from total RNA was performed with a high capacity cDNA reverse transcription kit (Applied Biosystems, Foster City, CA, USA). 10 µL RNA was used for each reaction. cDNA synthesis was achieved with T100 Thermal Cycler (BIO-RAD) according to temperature measurements. By using nanodrop spectrophotometry (All Sheng), the quantity of cDNA was determined, and the obtained cDNA was kept at -20 °C. For the cDNA synthesis reaction, the following ingredients were used: total RNA (10 µL), 25X dNTP mix (0.8 µL), 10X RT random primers (2 µL), reverse transcription 10X buffer (2 µL), diethylpyrocarbonate H<sub>2</sub>O (4.2 µL) and MultiScribe reverse transcriptase (1 µL). The cDNA concentrations were assessed and quantified using the Epoch Spectrophotometer System and Take3 Plate (Biotek)<sup>34,35</sup>.

## Quantitative Determination of IL-1β, NF-κB, and TNF-α mRNA Gene Expression by qRT-PCR

Utilizing the StepOnePlus qRT-PCR system technology (Applied Biosystems, USA) and cDNA produced from RNA of rats, analyses of relative and IL-1β, NF-κB, and TNF-α expression analyses were carried out, as previously described<sup>36</sup>. TaqMan Gene Expression Assays: Rat IL-1β (Rn00580432\_m1), rat NFKβ (Rn01399583\_m1), and rat TNF-α (Rn00562055\_m1) primers were used for the real-time polymerase chain reaction. β-actin (housekeeping gen) (Rn00667869\_m1) expression results in each tissue were used as the reference gene. Amplification and quantification processes were performed on Corbett Rotor-Gene (Thermo Fisher Scientific) device. The following TaqMan® Gene Expression Assays for 100ng cDNA were pipetted for 40 cycles with 100 ng cDNA, 10 µL TaqMan Master Mix, and 1 µL Assay and completed to 20 µL with RNase-free H<sub>2</sub>O. The cycle threshold (Ct) is the cycle count at which the quantity of fluorescent signal observed in qRT-PCR experiments exceeds the lowest value. Ct values were transformed automatically into delta delta Ct (2-ΔΔCt)<sup>37</sup> and the findings were statistically analyzed.

## Histopathological Analysis

The preparation phase of solutions, dehydration and clearing of tissue samples, section planning, and staining with Harris Hematoxylin and Eosin Y were all done by previous studies for histopathological assessment<sup>38</sup>. The kidney tissue sections obtained from rats for histopathological analysis were quickly fixed in a 3.7% formaldehyde (10% formalin) solution for 48 h. For each series of increasing alcohol concentrations of 50%, 70%, 80%, 96%, and 99%, all tissues were preserved for 1 hour to test for dehydration. The tissues were cleared for three to fifteen minutes in a solution of xylene. For infiltration, it was preserved in liquid paraffin that was molten. Tissues were meticulously blocked in paraffin after being processed. Each paraffin block of tissue was cut to a thickness of 5

micrometers for histopathological analysis after blocking. On the slide covered in adhesive, paraffin sections were cut. All slides were then stained using Harris hematoxylin and eosin Y. For histopathological examinations, tubular necrosis, inflammation, and hemorrhage areas in kidney tissues were evaluated by light microscope.

## Statistical and Semi-quantitative Analysis

For the statistical analysis of molecular results (IL-1β, NF-κB, and TNF-α) and biochemical results (MDA and GSH), we used GraphPad Prism, version 5.0, and the results are presented as the means±standard deviation. Comparisons between the groups were performed using the One-Way ANOVA and Tukey's multiple comparison tests; significance was accepted at p<0.05. P value less than 0.05 was considered statistically significant. Significant differences were detected among all groups, compared to the sham group (#p<0.05, ##p<0.01, ###p<0.001) and compared to the RI/RI group (\*p<0.05, \*\*p<0.01, \*\*\*p<0.001).

For comparison of histopathological data among all groups and to better show the extent of tissue damage, the presence of tubular necrosis, inflammation, and hemorrhage findings were scored semiquantitatively as none: 0, few: 1, moderate: 2, and severe: 3. For each tissue slide, at least five areas were assessed at ×100 magnification, and the median staining concentration score was taken into consideration. The One-Way ANOVA and Tukey's multiple comparison tests were used to compare the groups (\*p<0.0)<sup>39</sup>.

## RESULTS

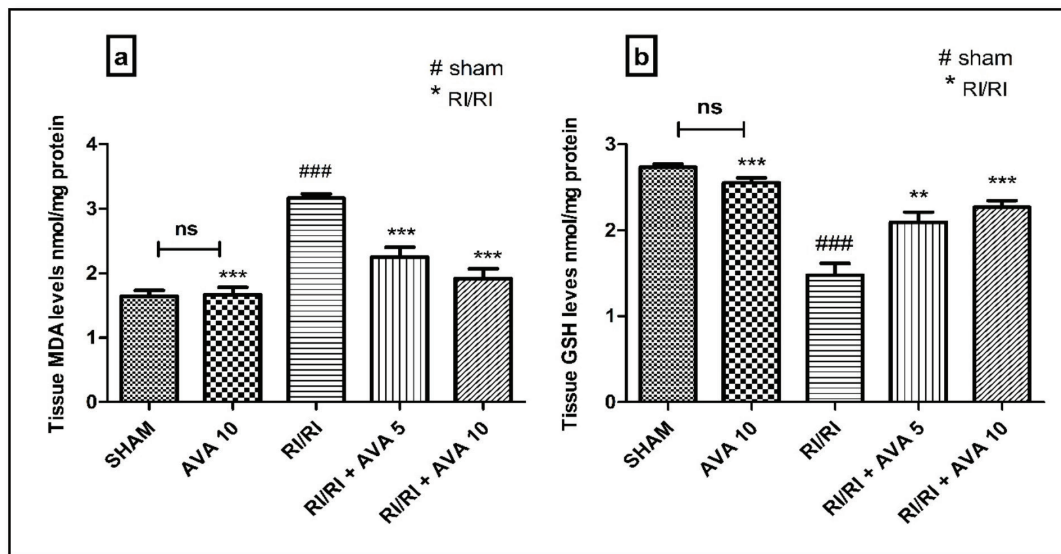
### Impacts of AVA on Oxidant and Antioxidant Parameters in Renal Tissue

MDA (Figure 1A) and GSH (Figure 1B) levels were investigated to research the antioxidant impact of AVA. MDA levels, a sign of the oxidant situation, increased in the RI/RI group (p<0.001). AVA administration reduced MDA levels in a dose-dependent manner, in comparison to the RI/RI group. GSH levels, a sign of the antioxidant situation, were dramatically lower in the RI/RI group in comparison to the sham group (p<0.001). In a dose-dependent manner, the AVA therapy reduced the drop in GSH levels brought on by ischemia/reperfusion.

### Impacts of AVA on Anti-inflammatory Parameters in Renal Tissue

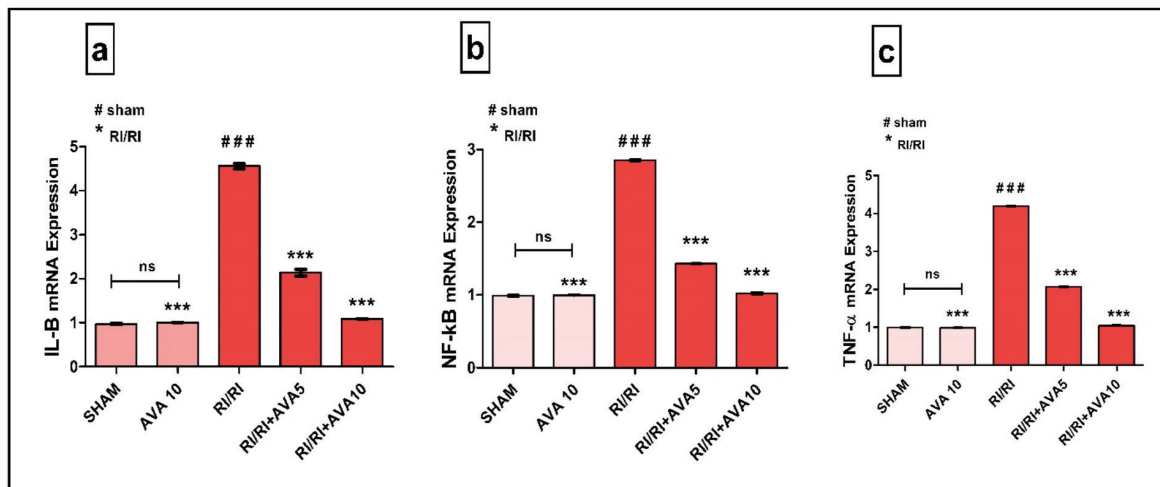
To investigate the anti-inflammatory effect of AVA, IL-1β (Figure 2A), NF-κB (Figure 2B), and TNF-α (Figure 2C) mRNA expression levels in the renal tissue of rats were analyzed. IL-1β, NF-κB, and TNF-α mRNA expression, signs of the anti-inflammatory situation, were significantly increased in the RI/RI group, compared to those in the sham group (p<0.001). The





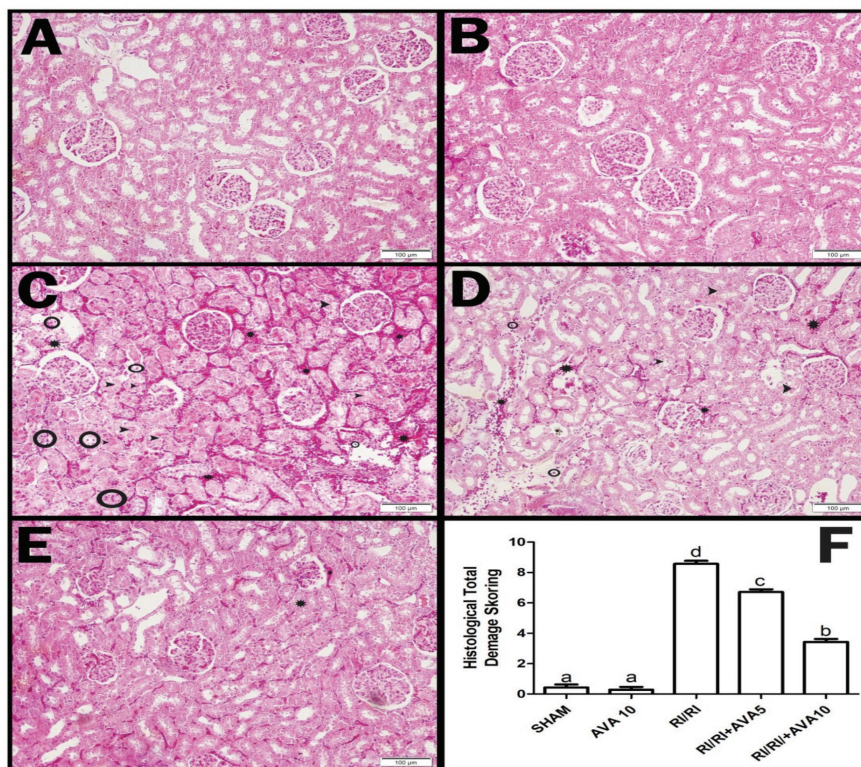
**Figure 1.** The biochemical results of the effects of AVA in the renal tissue on RI/RI. A) MDA levels (nmol/mg protein). B) GSH levels (nmol/mg protein). AVA 5: 5 mg/kg AVA; AVA 10: 10 mg/kg AVA. The levels of MDA and GSH were measured according to the modified methods with an ELISA reader. GraphPad Prism, version 5.0 was used for the statistical analysis, and the results are presented as the means $\pm$ standard deviation. Comparisons between the groups were performed using the One-Way ANOVA and Tukey's multiple comparison tests; p value less than 0.05 was considered statistically significant. Significant differences were detected among all groups, compared to the sham group (#p<0.05, ##p<0.01, ###p<0.001) and compared to the RI/RI group (\*p<0.05, \*\*p<0.01, \*\*\*p<0.001)

AVA: Avanafil, RI/RI: Renal ischemia/reperfusion injury, MDA: Malondialdehyde, GSH: Glutathione



**Figure 2.** The molecular results of the effects of AVA in the renal tissue on RI/RI. A) IL-1 $\beta$  mRNA expression levels. B) NF- $\kappa$ B expression levels. C) TNF- $\alpha$  mRNA expression level. AVA 5: 5 mg/kg AVA; AVA 10: 10 mg/kg AVA. The expression of mRNAs was detected using qRT-PCR analysis.  $\beta$ -actin was used as the reference gene. GraphPad Prism, version 5.0 was used for the statistical analysis, and the results are presented as the means $\pm$ standard deviation. Comparisons between the groups were performed using the One-Way ANOVA and Tukey's multiple comparison tests; p value less than 0.05 was considered statistically significant. Significant differences were detected among all groups, compared to the sham group (#p<0.05, ##p<0.01, ###p<0.001) and compared to the RI/RI group (\*p<0.05, \*\*p<0.01, \*\*\*p<0.001)

AVA: Avanafil, RI/RI: Renal ischemia/reperfusion injury, MDA: Malondialdehyde, GSH: Glutathione, NF- $\kappa$ B: Nuclear factor-kappa B, TNF- $\alpha$ : Tumor necrosis factor-alpha



**Figure 3.** Pathologic changes: Hematoxylin-eosin staining findings and histological total tissue damage scoring results of the effects of AVA in the renal tissue on RI/RI. A) Sham group, B) AVA-10 group, C) RI/RI group, D) RI/RI + AVA 5 group, E) RI/RI + AVA 10 group, F) Histopathology scoring graph (star: Hemorrhage, ring: Inflammatory cells, arrowhead: Tubular necrosis) (\*p<0.0)

AVA: Avanafil, RI/RI: Renal ischemia/reperfusion injury

AVA treatment improved the increase in IL-1 $\beta$ , NF-kB, and TNF- $\alpha$  mRNA expression induced by ischemia/reperfusion in a dose-dependent manner (p<0.001).

**Impacts of AVA on Histopathological Changes in Renal Tissue**

**Light Microscopy Results**

To investigate the histopathological effect of AVA in RI/RI, kidney tissue samples were stained with Harris Hematoxylin and Eosin Y staining and evaluated by a light microscope. (Figure 3A-E). Also, semi-quantitative scoring of histopathologic findings was shown in Figure 3F.

Under light microscopy, normal-looking glomerular structures, and distal and proximal tubule structures were observed in the kidney tissues of the sham group (Figure 3A). In the kidney tissues of the AVA10 group, no pathological damage was observed. The light microscopic findings of the histopathological appearance of this group’s glomerular, distal, and proximal tubule structures were similar to those of the sham group (Figure 3B).

Signs of severe tissue injury caused by ischemia/reperfusion were observed in the kidney tissue samples of the RI/RI group. In the kidney tissues of this group, hemorrhage areas in which erythrocyte cells formed piles were observed around the glomerulus, distal and proximal tubules (star). Inflammatory cells were found in some areas (ring). Along with dilatation in glomerular structures, deteriorations due to necrotic cell death were observed in proximal and distal tubules (Figure 3C). The histopathological injury resulting from ischemia/reperfusion improved in AVA-administered groups, depending on the dose (Figure 3D, 3E). Furthermore, the histopathological appearance of the 10 mg/kg AVA-administered group was similar to the sham group (Figure 3E).

**DISCUSSION**

RI/RI is a pathological condition that causes additional organ damage in ischemic tissues by causing low blood supply, followed by the restoration of blood flow<sup>40</sup>. RI/RI damages many organs, especially the kidney, which raises the mortality rate. RI/RI is regarded as a significant cause of end-stage renal failure and chronic renal failure. Kidney transplantation, embolism trauma, vascular and cardiac surgery, atherosclerosis,

and chronic renal artery stenosis are a few of the conditions that can expose the kidneys to RI/RI<sup>41</sup>. Additionally, RI/RI is the cause of acute kidney injury in more than 60% of patients<sup>42</sup>. Reperfusion of the ischemic kidney leads to necrosis or apoptosis, which exacerbates the inflammatory and oxidative condition and harms cellular honesty. The primary pathophysiological mechanisms of this situation involve the release of ROS and the generation of pro-inflammatory mediators<sup>43</sup>. With this information in mind, In the present study, we aimed to determine the effects of AVA, which is a PDE 5 inhibitor on RI/RI in rats by biochemical, molecular, and histopathological analyses.

ROS and oxidative stress are crucial factors in the development of renal tissue injury<sup>44</sup>. Exaggerated ROS production throughout RI/RI may result in endothelial dysfunction, tubular injury, and interstitial inflammation. Thus, oxidative stress is important in the development of RI/RI<sup>45,46</sup>. The MDA level is a sign of lipid peroxidation, free oxygen radical content, and the extent of renal tissue injury caused by these radicals<sup>47,48</sup>. GSH is essential in endogenous protection against oxygen-free radicals<sup>49</sup>. We investigated oxidative stress factors related to RI/RI; GSH, and the lipid peroxidation product MDA. Previous studies have shown that after RI/RI, MDA level is increased and GSH level is decreased<sup>50,51</sup>. Also, Prem and Kurian<sup>52</sup> demonstrated that markers of oxidative stress were significantly raised in a rat model of RI/RI. Our research detected the levels of GSH and MDA in kidney tissue and we found that compared to the sham group, the MDA level in the kidney tissue of rats in the RI/RI group was significantly increased while GSH levels were significantly decreased, suggesting that after RI/RI, oxidative stress reaction was aggravated in the kidney tissues. Conversely, in the RI/RI plus AVA groups, GSH levels importantly raised and MDA levels importantly reduced depending on the AVA doses. These effects of AVA seemed to be associated with the inhibition of oxidative stress, to a lesser extent, inflammatory responses. These findings demonstrated that AVA enhanced the oxidative situation. As a result, it reduced oxidative stress and alleviated RI/RI. Chowdari Gurram et al.<sup>53</sup> reported that AVA significantly reduced the markers of oxidative stress in a mice model. In addition, some researchers also reported that AVA significantly improved oxidative parameters<sup>54</sup>. Similarly, it has previously been established that PDE 5 inhibitors have a protective impact by regulating oxidative stress in kidney tissue<sup>55,56</sup>. Consistent with other findings reported in the literature, our result suggests that AVA treatment reduces oxidant parameter generation while increasing anti-oxidant parameter generation.

Inflammation is important in tissue repair, which is a response to damage<sup>57</sup>. ROS induces tissue injury in a range of manners involving inflammatory response, mitochondrial dysfunction, ER, and oxidative stress<sup>58</sup>. As a result, blocking ROS generation

is an effective method for RI/RI protection. RI/RI is a significant pathological condition and an inflammatory reaction in which the NF- $\kappa$ B family is crucial. ROS generation activates NF- $\kappa$ B, which then triggers ICAM-1 expression. Nevertheless, ROS and inflammatory reactions play important parts in the development of ischemia/reperfusion injury via NF- $\kappa$ B and the ICAM-1 progression<sup>59</sup>. By secreting TNF- $\alpha$ , which controls a spectrum of immune, inflammatory, and hematopoietic responses, immune cells play a crucial role in the inflammatory process<sup>60</sup>. TNF- $\alpha$  can stimulate the production of other inflammatory markers, including IL-1 $\beta$ , and aggravate the damage of tissues and organs<sup>13</sup>. Furthermore, the importance of the inflammatory response in RI/RI, which leads to the activation of IL-1, makes IL-1 a valuable target in RI/RI by modulating its effect. Hence, it is crucial for RI/RI treatment to reduce proinflammatory cytokines including IL-1 $\beta$ , NF- $\kappa$ B, and TNF- $\alpha$ <sup>61</sup>. In light of this information, in this study, the IL-1 $\beta$ , NF- $\kappa$ B, and TNF- $\alpha$  mRNA expression in kidney tissues after RI/RI and treatment with AVA were evaluated to appraise the possible medical significance of AVA in RI/RI. We found that compared to the sham group, the IL-1 $\beta$ , NF- $\kappa$ B, and TNF- $\alpha$  mRNA expression levels in the RI/RI group were significantly increased, suggesting that after RI/RI, the inflammatory reaction was aggravated in the kidney tissues. These results are consistent with previous research that found RI/RI-induced increases in cytokine levels<sup>62,63</sup>. Embaby et al.<sup>64</sup> demonstrated that renal TNF- $\alpha$  and NF- $\kappa$ B mRNA expressions increased in acute RI/RI in rats. Çakır et al.<sup>65</sup> showed that levels of IL-1 $\beta$ , NF- $\kappa$ B, and TNF- $\alpha$  mRNA expressions increased in rats with RI/RI. In addition, several recent studies have shown that the levels of anti-inflammatory cytokines, including IL-1 $\beta$ , NF- $\kappa$ B, and TNF- $\alpha$ , increase after RI/RI<sup>66,67</sup>. The current findings demonstrated that AVA fixed modifications to anti-inflammatory parameters were caused by RI/RI, indicating the strong anti-inflammatory feature of AVA. These findings indicated that AVA reduced tissue injury by avoiding RI/R-induced increases in cytokine levels. As a result, the anti-inflammatory effect of AVA appears to be related to the reduction of oxidative damage. AVA's anti-inflammatory effects, including suppression of pro-inflammatory cytokines, have earlier been shown in various animal models. Aydin et al.<sup>68</sup> demonstrated that AVA modulated NF- $\kappa$ B and IL-1 $\beta$  levels in the LPS-induced acute lung injury model in rats. Chowdari Gurram et al.<sup>53</sup> demonstrated that AVA improved neuroinflammatory cytokines such as Tnf R1 and NF- $\kappa$ B in LPS-induced neuroinflammation in mice. Likewise, it has earlier been established that PDE 5 inhibitors have a protective role via inhibition of IL-1, NF- $\kappa$ B, and TNF- $\alpha$  in prostate ischemia<sup>69</sup> and acute kidney toxicity<sup>70</sup> models. Consistent with previous research, our findings show that AVA decreases tissue injury by avoiding the increase in IL-1 $\beta$ , NF- $\kappa$ B, and TNF- $\alpha$  levels due to ischemia/reperfusion.



Regarding the histopathological scores in the current investigation, the histological total tissue damage score was quite high in the RI/RI group, while the score was reduced in the groups treated with 5 and 10 mg/kg of AVA. In the RI/RI group, kidney tissues also showed severe pathological alterations. The RI/RI group displayed hemorrhage, extensive inflammatory cell infiltration, and necrosis. However, in the groups that received 5 and 10 mg/kg of AVA, the histological aspect of the kidney tissues was nearly normal. Our biochemical and molecular findings were corroborated by our histology findings.

### Study Limitations

The limitations of this study include the fact that biochemical markers such as SOD data and renal function markers such as BUN could not be investigated. We think that further more detailed studies are now needed for a clearer understanding of the effect mechanism revealed in this study. However, this study is particularly valuable and original as the first to reveal the effect of AVA on RI/RI. We hope that the study will lead to further studies.

### CONCLUSION

Based on the biochemical, molecular, and histopathological findings, we have shown that AVA significantly improved ischemia/reperfusion-induced renal injury. AVA may intervene with both anti-inflammatory and antioxidant processes that may be essential in renal ischemia/reperfusion damage. The effects of AVA on RI/RI may be related to the treatment (1) reducing immunopositivity of inflammatory cytokines including IL-1 $\beta$ , NF- $\kappa$ B, and TNF- $\alpha$ , (2) alleviating adverse changes in oxidative stress-related components including MDA and GSH, (3) reducing severe histopathological modifications. AVA should be considered as a potential therapeutic agent in addition to surgery in the clinical treatment of RI/RI. These findings may provide a mechanistic basis for using AVA to treat ischemia/reperfusion-induced renal injury.

### Ethics

**Ethics Committee Approval:** This animal study and all its protocols were approved by Atatürk University Medical Experimental Application and Research Center of Ethics Committee on 04-04-2022 with document number E-75296309-050.01.04-2200103613.

**Informed Consent:** Animal experiment.

**Peer-review:** Externally peer-reviewed.

### Authorship Contributions

Surgical and Medical Practices: T.N.Y., Z.H., C.K., A.B., T.T., M.S.C., B.Ö., Concept: T.N.Y., Z.H., C.K., A.B., T.T., M.S.C., B.Ö., Design: T.N.Y., Z.H., C.K., A.B., T.T., M.S.C., B.Ö., Data Collection

or Processing: T.N.Y., Z.H., C.K., A.B., T.T., M.S.C., B.Ö., Analysis or Interpretation: T.N.Y., Z.H., C.K., A.B., T.T., M.S.C., B.Ö., Literature Search: T.N.Y., Z.H., C.K., Writing: T.N.Y., Z.H., C.K., A.B., T.T., M.S.C., B.Ö.

**Conflict of Interest:** No conflict of interest was declared by the authors.

**Financial Disclosure:** The authors declared that this study received no financial support.

### REFERENCES

1. Ray SC, Mason J, O'Connor PM. Ischemic Renal Injury: Can Renal Anatomy and Associated Vascular Congestion Explain Why the Medulla and Not the Cortex Is Where the Trouble Starts? *Semin Nephrol.* 2019;39:520-9.
2. Quadri SS, Culver S, Siragy HM. Prorenin receptor mediates inflammation in renal ischemia. *Clin Exp Pharmacol Physiol.* 2018;45:133-9.
3. Wu MY, Yiang GT, Liao WT, Tsai AP, Cheng YL, Cheng PW, et al. Current Mechanistic Concepts in Ischemia and Reperfusion Injury. *Cell Physiol Biochem.* 2018;46:1650-67.
4. Inhibition of Brd4 alleviates renal ischemia/reperfusion injury-induced apoptosis and endoplasmic reticulum stress by blocking FoxO4-mediated oxidative stress. *Redox Biol.* 2019;24:101195.
5. Martin JL, Gruszczuk AV, Beach TE, Murphy MP, Saeb-Parsy K. Mitochondrial mechanisms and therapeutics in ischaemia reperfusion injury. *Pediatr Nephrol.* 2019;34:1167-74.
6. Malek M, Nematbakhsh M. Renal ischemia/reperfusion injury; from pathophysiology to treatment. *J Renal Inj Prev.* 2015;4:20-7.
7. Akhigbe R, Ajayi A. The impact of reactive oxygen species in the development of cardiometabolic disorders: a review. *Lipids Health Dis.* 2021;20:23.
8. Sengul O, Ferah I, Polat B, Halici Z, Bayir Y, Yilmaz M, Kilic N, Keles ON. Blockade of endothelin receptors with bosentan limits ischaemia/reperfusion-induced injury in rat ovaries. *Eur J Obstet Gynecol Reprod Biol.* 2013;170:458-63.
9. Aslan M, Erkanli Senturk G, Akkaya H, Sahin S, Yilmaz B. The effect of oxytocin and Kisspeptin-10 in ovary and uterus of ischemia-reperfusion injured rats. *Taiwan J Obstet Gynecol.* 2017;56:456-62.
10. Nayki C, Nayki U, Keskin Cimen F, Kulhan M, Yapca OE, Kurt N, et al. The effect of rutin on ovarian ischemia-reperfusion injury in a rat model. *Gynecol Endocrinol.* 2018;34:809-14.
11. Hashmi SF, Rathore HA, Sattar MA, Johns EJ, Gan CY, Chia TY, et al. Hydrogen Sulphide Treatment Prevents Renal Ischemia-Reperfusion Injury by Inhibiting the Expression of ICAM-1 and NF- $\kappa$ B Concentration in Normotensive and Hypertensive Rats. *Biomolecules.* 2021;11:1549.
12. Prince PD, Rodríguez Lanzi C, Fraga CG, Galleano M. Dietary (-)-epicatechin affects NF- $\kappa$ B activation and NADPH oxidases in the kidney cortex of high-fructose-fed rats. *Food Funct.* 2019;10:26-32.
13. Zhang X, Jin C, Li Y, Guan S, Han F, Zhang S. Catalpol improves cholinergic function and reduces inflammatory cytokines in the senescent mice induced by D-galactose. *Food Chem Toxicol.* 2013;58:50-5.
14. Kucuk A, Yucel M, Erkasap N, Tosun M, Koken T, Ozkurt M, et al. The effects of PDE5 inhibitory drugs on renal ischemia/reperfusion injury in rats. *Mol Biol Rep.* 2012;39:9775-82.
15. Swiecicka A. The efficacy of PDE5 inhibitors in diabetic patients. *Andrology.* 2023;11:245-56.
16. Brown KE, Dhaun N, Goddard J, Webb DJ. Potential therapeutic role of phosphodiesterase type 5 inhibition in hypertension and chronic kidney disease. *Hypertension.* 2014;63:5-11.
17. Zucchi A, Costantini E, Scropo FI, Silvani M, Kopa Z, Illiano E, et al. The first-generation phosphodiesterase 5 inhibitors and their pharmacokinetic issue. *Andrology.* 2019;7:804-17.



18. Ahmed WS, Geethakumari AM, Biswas KH. Phosphodiesterase 5 (PDE5): Structure-function regulation and therapeutic applications of inhibitors. *Biomed Pharmacother.* 2021;134:111128.
19. Ockaili R, Salloum F, Hawkins J, Kukreja RC. Sildenafil (Viagra) induces powerful cardioprotective effect via opening of mitochondrial K(ATP) channels in rabbits. *Am J Physiol Heart Circ Physiol.* 2002;283:H1263-9.
20. Serarslan Y, Yonden Z, Ozgiray E, Oktar S, Guven EO, Sogut S, et al. Protective effects of tadalafil on experimental spinal cord injury in rats. *J Clin Neurosci.* 2010;17:349-52.
21. Ko IG, Shin MS, Kim BK, Kim SE, Sung YH, Kim TS, et al. Tadalafil improves short-term memory by suppressing ischemia-induced apoptosis of hippocampal neuronal cells in gerbils. *Pharmacol Biochem Behav.* 2009;91:629-35.
22. Celik M, Aksoy AN, Aksoy H, Aksoy Y, Halici Z. Sildenafil reduces ischemia-reperfusion injury in rat ovary: biochemical and histopathological evaluation. *Gynecol Obstet Invest.* 2014;78:162-7.
23. Zisis IE, Georgiadis G, Docea AO, Calina D, Cercelaru L. Renoprotective Effect of Vardenafil and Avanafil in Contrast-Induced Nephropathy: Emerging Evidence from an Animal Model. *J Pers Med.* 2022;12:670.
24. Huyut Z, Bakan N, Yıldırım S, Akbay HI, Huyut MT, Ahlatci A, et al. Can zaprinast and avanafil induce the levels of angiogenesis, bone morphogenic protein 2, 4 and 7 in kidney of ovariectomised rats? *Arch Physiol Biochem.* 2022;128:945-50.
25. Huyut Z, Bakan N, Yıldırım S, Alp HH. Effects of the Phosphodiesterase-5 (PDE-5) Inhibitors, Avanafil and Zaprinast, on Bone Remodeling and Oxidative Damage in a Rat Model of Glucocorticoid-Induced Osteoporosis. *Med Sci Monit Basic Res.* 2018;24:47-58.
26. Huyut Z, Bakan N, Akbay Hİ, Yıldırım S, Şekeroğlu MR. Zaprinast and avanafil increase the vascular endothelial growth factor, vitamin D3, bone morphogenic proteins 4 and 7 levels in the kidney tissue of male rats applied the glucocorticoid. *Arch Physiol Biochem.* 2022;128:1290-6.
27. Ziypak T, Halici Z, Alkan E, Akpınar E, Polat B, Adanur S, et al. Renoprotective effect of aliskiren on renal ischemia/reperfusion injury in rats: electron microscopy and molecular study. *Ren Fail.* 2015;37:343-54.
28. Nezamoleslami S, Sheibani M, Jahanshahi F, Mumtaz F, Abbasi A, Dehpour AR. Protective effect of dapson against renal ischemia-reperfusion injury in rat. *Immunopharmacol Immunotoxicol.* 2020;42:272-9.
29. Ohkawa H, Ohishi N, Yagi K. Assay for lipid peroxides in animal tissues by thiobarbituric acid reaction. *Anal Biochem.* 1979;95:351-8.
30. Sedlak J, Lindsay RH. Estimation of total, protein-bound, and nonprotein sulfhydryl groups in tissue with Ellman's reagent. *Anal Biochem.* 1968;25:192-205.
31. Bayir Y, Un H, Cadirci E, Akpınar E, Diyarbakir B, Calik I, et al. Effects of Aliskiren, an RAAS inhibitor, on a carrageenan-induced pleurisy model of rats. *An Acad Bras Cienc.* 2019;91:e20180106.
32. Lowry OH, Rosebrough NJ, Farr AL, Randall RJ. Protein measurement with the Folin phenol reagent. *J Biol Chem.* 1951;193:265-75.
33. Kose D, Kose A, Halici Z, Cadirci E, Tavaci T, Gurbuz MA, et al. Bosentan, a drug used in the treatment of pulmonary hypertension, can prevent development of osteoporosis. *Iran J Basic Med Sci.* 2021;24:922-7.
34. Cadirci E, Ugan RA, Dincer B, Gundogdu B, Cinar I, Akpınar E, et al. Urotensin receptors as a new target for CLP induced septic lung injury in mice. *Naunyn Schmiedebergs Arch Pharmacol.* 2019;392:135-45.
35. Sipahi H, Orak D, Reis R, Yalman K, Senol O, Palabiyik-Yucelik SS, et al. A comprehensive study to evaluate the wound healing potential of okra (*Abelmoschus esculentus*) fruit. *J Ethnopharmacol.* 2022;287:114843.
36. Köse D, Yüksel TN, Halici Z, Çadırcı E, Gürbüz MA. The Effects of Agomelatine Treatment on Lipopolysaccharide-Induced Septic Lung Injuries in Rats. *Eurasian J Med.* 2021;53:127-31.
37. Livak KJ, Schmittgen TD. Analysis of relative gene expression data using real-time quantitative PCR and the 2(-Delta Delta C(T)) Method. *Methods.* 2001;25:402-8.
38. Yüksel TN, Yayla M, Duygu K, Uğan RA, Toktay E, Kılıç PA, et al. Investigation of the Protective Effects of Pomegranate (*Punica Granatum L.*) Peel Extract on Lipopolysaccharide-induced Uveitis in Rats. *Trakya University Journal of Natural Sciences.* 2023;24:11-20.
39. Toktay E, Tastan TB, Gurbuz MA, Erbas E, Demir O, Ugan RA, et al. Potential protective effect of astaxanthin on ovary ischemia-reperfusion injury. *Iran J Basic Med Sci.* 2022;25:173-8.
40. Pefanis A, Ierino FL, Murphy JM, Cowan PJ. Regulated necrosis in kidney ischemia-reperfusion injury. *Kidney Int.* 2019;96:291-301.
41. Abbas W, Altemimi M, Qassam H, Hameed AA, Zigam Q, Abbas L, et al. Fimasartan ameliorates renal ischemia reperfusion injury via modulation of oxidative stress, inflammatory and apoptotic cascades in a rat model. *J Med Life.* 2022;15:241-51.
42. Park M, Kwon CH, Ha HK, Han M, Song SH. RNA-Seq identifies condition-specific biological signatures of ischemia-reperfusion injury in the human kidney. *BMC Nephrol.* 2020;21:398.
43. Shan Y, Chen D, Hu B, Xu G, Li W, Jin Y, et al. Allicin ameliorates renal ischemia/reperfusion injury via inhibition of oxidative stress and inflammation in rats. *Biomed Pharmacother.* 2021;142:112077.
44. Tian Y, Shu J, Huang R, Chu X, Mei X. Protective effect of renal ischemic postconditioning in renal ischemic-reperfusion injury. *Transl Androl Urol.* 2020;9:1356-65.
45. Zhao M, Wang Y, Li L, Liu S, Wang C, Yuan Y, et al. Mitochondrial ROS promote mitochondrial dysfunction and inflammation in ischemic acute kidney injury by disrupting TFAM-mediated mtDNA maintenance. *Theranostics.* 2021;11:1845-63.
46. Li F, Bahnson EM, Wilder J, Siletzky R, Hagaman J, Nickeleit V, et al. Oral high dose vitamin B12 decreases renal superoxide and post-ischemia/reperfusion injury in mice. *Redox Biol.* 2020;32:101504.
47. Zhu MM, Wang L, Yang D, Li C, Pang ST, Li XH, et al. Wedelolactone alleviates doxorubicin-induced inflammation and oxidative stress damage of podocytes by IκK/IκB/NF-κB pathway. *Biomed Pharmacother.* 2019;117:109088.
48. Hu B, Tang J, Zhang Y, Ma ZY, Shan YG, Liu J, et al. Glycogen Synthase Kinase-3β Inhibitor Attenuates Renal Damage Through Regulating Antioxidant and Anti-inflammation in Rat Kidney Transplant With Cold Ischemia Reperfusion. *Transplant Proc.* 2019;51:2066-70.
49. Aboutaleb N, Jamali H, Abolhasani M, Pazoki Toroudi H. Lavender oil (*Lavandula angustifolia*) attenuates renal ischemia/reperfusion injury in rats through suppression of inflammation, oxidative stress and apoptosis. *Biomed Pharmacother.* 2019;110:9-19.
50. Bayir Y, Cadirci E, Polat B, Baygutalp NK, Albayrak A, Karakus E, et al. Aliskiren - a promising strategy for ovarian ischemia/reperfusion injury protection in rats via RAAS. *Gynecol Endocrinol.* 2016;32:675-83.
51. Huang D, Chen D, Hu T, Liang H. GATA2 promotes oxidative stress to aggravate renal ischemia-reperfusion injury by up-regulating Redd1. *Mol Immunol.* 2023;153:75-84.
52. Prem PN, Kurian GA. Fisetin attenuates renal ischemia/reperfusion injury by improving mitochondrial quality, reducing apoptosis and oxidative stress. *N-S Arch Pharmacol.* 2022;395:547-61.
53. Chowdari Gurram P, Satarker S, Kumar G, Begum F, Mehta C, Nayak U, et al. Avanafil mediated dual inhibition of IKKβ and TNFR1 in an experimental paradigm of Alzheimer's disease: in silico and in vivo approach. *J Biomol Struct Dyn.* 2022:1-19.
54. Kurakula M, Naveen N R, Patel B, Manne R, Patel DB. Preparation, Optimization and Evaluation of Chitosan-Based Avanafil Nanocomplex Utilizing Antioxidants for Enhanced Neuroprotective Effect on PC12 Cells. *Gels.* 2021;7:96.
55. Jorge ARC, Marinho AD, Silveira JAM, Nogueira Junior FA, de Aquino PEA, Alves APNN, et al. Phosphodiesterase-5 inhibitor sildenafil attenuates kidney injury induced by *Bothrops alternatus* snake venom. *Toxicon.* 2021;202:46-52.
56. Mehanna OM, El Askary A, Al-Shehri S, El-Esawy B. Effect of phosphodiesterase inhibitors on renal functions and oxidant/antioxidant

- parameters in streptozocin-induced diabetic rats. *Arch Physiol Biochem.* 2018;124:424-9.
57. Lamkanfi M, Dixit VM. Inflammasomes and their roles in health and disease. *Annu Rev Cell Dev Biol.* 2012;28:137-61.
58. Malek M, Nematbakhsh M. Renal ischemia/reperfusion injury; from pathophysiology to treatment. *J Renal Inj Prev.* 2015;4:20-7.
59. Hashmi SF, Rathore HA, Sattar MA, Johns EJ, Gan CY, Chia TY, et al. Correction: Hashmi et al. Hydrogen Sulphide Treatment Prevents Renal Ischemia-Reperfusion Injury by Inhibiting the Expression of ICAM-1 and NF- $\kappa$ B Concentration in Normotensive and Hypertensive Rats. *Biomolecules* 2021, 11, 1549. *Biomolecules.* 2022;12:593.
60. Kong DH, Kim YK, Kim MR, Jang JH, Lee S. Emerging Roles of Vascular Cell Adhesion Molecule-1 (VCAM-1) in Immunological Disorders and Cancer. *Int J Mol Sci.* 2018;19:1057.
61. Vannay A, Fekete A, Langer R, Toth T, Sziksz E, Vasarhelyi B, et al. Dehydroepiandrosterone pretreatment alters the ischaemia/reperfusion-induced VEGF, IL-1 and IL-6 gene expression in acute renal failure. *Kidney Blood Press Res.* 2009;32:175-84.
62. Li Y, Xu B, Yang J, Wang L, Tan X, Hu X, et al. Liraglutide protects against lethal renal ischemia-reperfusion injury by inhibiting high-mobility group box 1 nuclear-cytoplasmic translocation and release. *Pharmacol Res.* 2021;173:105867.
63. Bai T, Wang X, Qin C, Yang K, Duan Z, Cao Z, et al. Deficiency of mindin reduces renal injury after ischemia reperfusion. *Mol Med.* 2022;28:152.
64. Embaby EM, Saleh RM, Marghani BH, Barakat N, Awadin W, Elshal MF, et al. The combined effect of zinc oxide nanoparticles and milrinone on acute renal ischemia/reperfusion injury in rats: Potential underlying mechanisms. *Life Sci.* 2023;323:121435.
65. Çakır M, Aydın A, Tekin S. Protective effect of fatty acid amide hydrolase inhibitor URB597 and monoacylglycerol lipase inhibitor KML29 on renal ischemia-reperfusion injury via toll-like receptor 4/nuclear factor- $\kappa$ B pathway. *Int Immunopharmacol.* 2023;114:109586.
66. Younis NS. Myrrh Essential Oil Mitigates Renal Ischemia/Reperfusion-Induced Injury. *Curr Issues Mol Biol.* 2023;45:1183-96.
67. Abdel-Razek HA, Rizk MS, Amer GS, Kora MA, Afifi AM, Donia SS. Impact of combined ischemic preconditioning and melatonin on renal ischemia-reperfusion injury in rats. *Iran J Basic Med Sci.* 2023;26:235-40.
68. Aydın P, Magden ZBA, Uzuncakmak SK, Halici H, Akgun N, Mendil AS, et al. Avanafil as a Novel Therapeutic Agent Against LPS-Induced Acute Lung Injury via Increasing CGMP to Downregulate the TLR4-NF- $\kappa$ B-NLRP3 Inflammasome Signaling Pathway. *Lung.* 2022;200:561-72.
69. Kobayashi H, Zha X, Nagase K, Inamura S, Taga M, Aoki Y, et al. Phosphodiesterase 5 inhibitor suppresses prostate weight increase in type 2 diabetic rats. *Life Sci.* 2022;298:120504.
70. Wadie W, Abdel-Razek NS, Salem HA. Phosphodiesterase (1, 3 & 5) inhibitors attenuate diclofenac-induced acute kidney toxicity in rats. *Life Sci.* 2021;277:119506.