







Variability in the Epithelial Expression of Ki67 and Polarization Characteristics of Collagen in Odontogenic Cysts and Tumours

Shakthi Dorai Bhadravathi¹, Srikant Natarajan¹, Karen Boaz¹, Amitha Juanita Lewis¹,
Nandita Kottieth Pallam¹, Nidhi Manaktala¹

¹Department of Oral Pathology and Microbiology, Manipal College of Dental Sciences, Manipal Academy of Higher Education, Manipal, Karnataka, India.

Correspondence: Srikant N, Department of Oral Pathology and Microbiology, Manipal College of Dental Sciences Mangalore, Manipal Academy of Higher Education, Manipal, Karnataka, India. **E-mail:** srikant.n@manipal.edu

Academic Editor: Alidianne Fábila Cabral Cavalcanti

Received: 24 January 2022 / **Review:** 13 May 2022 / **Accepted:** 08 August 2022

How to cite: Bhadravathi SD, Natarajan S, Boaz K, Lewis AJ, Pallam NK, Manaktala N. Variability in the epithelial expression of Ki67 and polarization characteristics of collagen in odontogenic cysts and tumours. *Pesqui Bras Odontopediatria Clín Integr.* 2023; 23:e220019. <https://doi.org/10.1590/pboci.2023.065>

ABSTRACT

Objective: To assess the proliferation of epithelium (using the Ki67 index) and the polarization pattern of collagen in selected odontogenic cysts and tumours. In addition, an exploratory analysis of the effect of inflammation on the proliferation rate was done. **Material and Methods:** Following immunohistochemical staining, the labelling/proliferation index of Ki67 was calculated. The thickness and corresponding polarization colour of 100 juxta-epithelial picosirius red-stained collagen fibers were assessed using linear micrometry with an eyepiece reticule under $\times 1000$ magnification. Inflammation was graded subjectively as mild, moderate, and severe. **Results:** Overall Ki-67 expression was higher in the radicular cyst, Odontogenic Keratocyst, Ameloblastoma, while suprabasal Ki-67 positivity was maximum in Odontogenic Keratocyst. The stromal collagen fibers in Ameloblastoma showed predominantly green birefringence, whereas Odontogenic Keratocyst had orange birefringence. There was no significant association of inflammation with Ki-67 expression or birefringence patterns. **Conclusion:** The highest Ki67 expression in the radicular cyst, followed by Odontogenic Keratocyst and Ameloblastoma. Differences in the collagen maturation pattern were noted innately in five lesions studied and were further influenced by inflammatory changes. Epithelial proliferation and concomitant expression of thickness and maturity of the stromal collagen are innate features of the lesion further influenced by inflammation in various odontogenic cysts and tumours and may, in turn, guide the clinical behavior.

Keywords: Odontogenic Cysts; Ki-67 Antigen; Ameloblastoma; Collagen; Birefringence.

Introduction

Odontogenic cysts and tumors are unique to the jaws and originate from tissues associated with tooth development. Although they share the same source of odontogenic epithelium, they differ biologically in development and progression. Odontogenic lesions, be they developmental or inflammatory in origin and have epithelial proliferation as an element of expansion. These proliferative rates can be assessed by immunohistochemical (IHC) markers like Ki67, PCNA, Mib, etc., out of which Ki67 has been widely studied in odontogenic cysts and tumours owing to its detection in all active phases of the cell cycle [1].

Odontogenic cysts and tumors are derived from the remnants of the dental lamina; cell rests of Malassez, reduced enamel epithelium, and they retain their innate capabilities for epithelial-mesenchymal interaction and therefore influence the stromal arrangement of connective tissue fibers. Recent studies have used picosirius red stain to assess the connective tissue changes in terms of collagen maturity in the capsules of odontogenic cysts and tumours [2].

The present study was undertaken with the hypothesis that the maturation and morphological pattern of collagen in the supporting connective tissue stroma of odontogenic cysts and tumors has a correlation with the rate of cell proliferation in the epithelial component of these lesions, and each odontogenic cyst and tumour bears a customized 'collagen signature' that effects these changes. The present study aimed to evaluate the immunohistochemical expression of the proliferation index of the epithelium (using Ki67), the maturation pattern of collagen as identified by polarizing microscopy in a selected group of lesions or structures derived from the odontogenic apparatus (i.e., odontogenic cysts and tumors and dental follicle). Secondly an exploration of the confounding effect of inflammation on epithelial proliferation was also done.

Material and Methods

Sampling

Sample size estimation was done according to the research by Gadbaile et al. [3]. The mean Ki67 values reported were 24.24 (12.27) and 12.92 (4.23) in ameloblastoma and OKC, respectively. With a power of 90% and alpha error of 5%, using the sample size formula ($N = \frac{2(Z_{1-\frac{\alpha}{2}} + Z_{1-\beta})^2 \sigma^2}{d^2}$) to compare two means to detect a clinically significant difference of 12 units, we need a sample size of 10 in each group.

Study Design

This retrospective study assessed the immunohistochemical expression of Ki-67 in formalin-fixed, paraffin-embedded tissue blocks of fifty cases of various odontogenic lesions. Ten cases each of Odontogenic Keratocysts (OKC), Dentigerous cyst (DC), Radicular cyst (RC), Ameloblastoma (Five unicystic ameloblastoma, three follicular ameloblastoma, one desmoplastic ameloblastoma, and one plexiform ameloblastoma) and Dental Follicle (as controls) were retrieved from the archives of the Department of Oral Pathology and Microbiology, Manipal College of Dental Sciences, India. The odontogenic cysts and tumours were evaluated for the epithelial and connective tissue components for diagnosis. In addition, the type and extent of inflammation in the connective tissue were graded as mild, moderate, and severe. The study commenced after obtaining clearance from the Institutional Ethics Committee.

Data Collection

Ten tissue sections of histologically-proven cases of breast carcinoma (obtained from archives of the Department of General Pathology) were selected as positive IHC control for Ki67. Breast carcinoma slide stained following the same protocol; the omission of primary antibody served as a negative control. One positive and one negative staining control was maintained when staining for each batch of cases.

Monoclonal Mouse Anti-Human Ki-67 Antigen Clone MIB-1 (Ki-67 IHC MIB-1 pharmDx (Dako Omnis) GE020) was used to stain the section using the manufacturer's protocol. The immunohistochemical expression of Ki-67 was evaluated in the basal and the suprabasal layers of the cysts in five high power fields (x40) of the epithelium following superimposition of a 49 square eyepiece reticule. In Dentigerous cyst and Unicystic ameloblastoma, the first layer of the cells over the basement membrane was considered basal and the remaining layers were suprabasal (suprabasal and superficial layer). In Odontogenic Keratocyst, Radicular cyst, and Dental Follicle, the two layers adjacent to the basement membrane were considered basal, and the remaining layers (suprabasal and superficial layer) were considered suprabasal. In follicular, desmoplastic, and plexiform ameloblastoma, the assessment was done in the peripheral and central cells of the follicles. The total number of epithelial cells and the number of epithelial cells showing positive Ki67 staining were counted, and the labeling index was calculated as the percentage of Ki67-positive cells in relation to the total number of cells [4].

Picrosirius red staining was done in each corresponding case to assess the thickness and maturity of collagen in the juxtaepithelial connective tissue capsule. Picrosirius red stained sections of each cyst/tumour were viewed under oil immersion (1000× magnification). One hundred collagen fibers were identified juxtaepithelially, and the thickness was measured using an eyepiece reticule with graduations. A maximum of two high-power fields were considered as juxta epithelial, and 15 consecutive fields were evaluated. The assessment was done by two trained and experienced pathologists. In case of discrepancy, they arrived at a consensus following a discussion with a third senior pathologist. The thickness of the collagen bundle was directly measured using micrometry (using a graduated eyepiece reticule) and noted along with the corresponding polarization colour for each fiber and tabulated in a Microsoft Excel spreadsheet. The polarizing colours of collagen were classified as green (immature), yellow (mature), or orange (intermediate), as described by Hirshberg et al. [5]. These were then grouped based on their median diameter as thick (diameter >1.83µm) or thin (diameter ≤1.83µm) fibers.

Statistical Analysis

The pattern of expression of Ki67, prevalence of thick and thin, and the proportion of each colour of birefringence were compared between the odontogenic lesions using the Kruskal-Wallis test. A descriptive analysis of the variation of the Ki67 expression with different grades of inflammation was done. The Ki67 expression of epithelium and juxtaepithelial maturation pattern of collagen indicated by their colour of birefringence were correlated using Spearman's correlation.

Results

The comparison of the median values of Ki67 Positive cells between the five groups showed the highest Ki67 expression in the basal cells of Radicular cyst (14%), followed by Odontogenic Keratocyst (13.91%), Ameloblastoma (5.68%), Dental Follicle (3.58%) and least in Dentigerous cyst (3.11%). The trend was different in the suprabasal cell positivity. The highest suprabasal expression was seen in Odontogenic Keratocyst (6.51%), followed by Radicular cyst (3.55%), Dentigerous cyst (2.72%), Dental Follicle (1.85%), and lastly Ameloblastoma (1.80%) (Table 1 and Figure 1).

Table 1. Kruskal Wallis test for comparison of the Ki67 expression, collagen thickness character, and birefringence patterns among the five odontogenic lesions.

| Odontogenic Lesions | Mean±SD | Median (IQR) | Range | p-value |
|---|-------------|--------------------|------------|---------|
| Ki67 in Basal Cells | | | | |
| Dental Follicle | 9.3±11.16 | 3.58 (1.05,20) | 0-27.89 | 0.164 |
| Dentigerous Cyst | 7.13±8.51 | 3.11 (0.47,17.14) | 0-21.6 | |
| Ameloblastoma | 10.1±14.83 | 5.68 (2.62,10.11) | 0-50.78 | |
| Radicular Cyst | 24.47±23.72 | 14 (3.97,46.61) | 0-61.07 | |
| Odontogenic Keratocyst | 15.46±11.61 | 13.91 (5.77,24.14) | 2.3-37.61 | |
| Ki67 in Suprabasal Cells | | | | |
| Dental Follicle | 4.22±4.98 | 1.85 (0.74,7.16) | 0-14.86 | 0.119 |
| Dentigerous Cyst | 6.8±9.44 | 2.72 (0.34,7.68) | 0-27.32 | |
| Ameloblastoma | 2.49±2.79 | 1.8 (0.19,3.06) | 0-7.66 | |
| Radicular Cyst | 5.21±5.17 | 3.55 (1.13,8.56) | 0.29-16.23 | |
| Odontogenic Keratocyst | 7.45±4.79 | 6.51 (3.56,11.58) | 1.47-16.36 | |
| Percentage thin fibres | | | | |
| Dental Follicle | 34.1±11.12 | 29.5 (27,42) | 22-58 | 0.158 |
| Dentigerous Cyst | 42.9±16.36 | 44 (37,54) | 17-64 | |
| Ameloblastoma | 46.6±13.97 | 49 (37,59) | 18-62 | |
| Radicular Cyst | 33.8±13.63 | 32 (28,44) | 7-55 | |
| Odontogenic Keratocyst | 42.3±18.28 | 38.5 (36,52) | 11-77 | |
| Percentage of thick fibres | | | | |
| Dental Follicle | 65.9±11.12 | 70.5 (58,73) | 42-78 | 0.158 |
| Dentigerous Cyst | 57.1±16.36 | 56 (46,63) | 36-83 | |
| Ameloblastoma | 53.4±13.97 | 51 (41,63) | 38-82 | |
| Radicular Cyst | 66.2±13.63 | 68 (56,72) | 45-93 | |
| Odontogenic Keratocyst | 57.7±18.28 | 61.5 (48,64) | 23-89 | |
| Thin fibers with green birefringence | | | | |
| Dental Follicle | 20.53±9.04 | 17.95 (13.6,29.7) | 11.1-37 | 0.743 |
| Dentigerous Cyst | 16.24±10.96 | 14.7 (7.1,27.8) | 3.7-35.3 | |
| Ameloblastoma | 26.13±20.56 | 21.85 (13.2,33.3) | 6.5-77.8 | |
| Radicular Cyst | 19.22±13.42 | 19.35 (10.3,33.3) | 0-34.8 | |
| Odontogenic Keratocyst | 17.89±14.35 | 15.7 (5.6,26.1) | 2.7-48.6 | |
| Thin fibers with orange birefringence | | | | |
| Dental Follicle | 48.95±14.08 | 50.95 (43.1,56) | 24.1-72.7 | 0.516 |
| Dentigerous Cyst | 55.45±20.57 | 60.35 (41.2,70.3) | 16.7-78.6 | |
| Ameloblastoma | 42.85±17.6 | 45.05 (27.1,54.8) | 16.7-70.3 | |
| Radicular Cyst | 46.68±19.85 | 49.35 (34.4,53.6) | 13-85.7 | |
| Odontogenic Keratocyst | 56.68±22.31 | 59.05 (36.5,72.7) | 27-89.2 | |
| Thin fibers with yellow birefringence | | | | |
| Dental Follicle | 30.51±13.29 | 30.5 (25.9,40.5) | 11.1-55.2 | 0.599 |
| Dentigerous Cyst | 28.32±16.49 | 23.7 (19,40.7) | 5.9-55.6 | |
| Ameloblastoma | 31.03±16.06 | 34.8 (26.7,43.4) | 2.7-49.2 | |
| Radicular Cyst | 34.04±12.77 | 36.95 (25,41.7) | 14.3-52.2 | |
| Odontogenic Keratocyst | 25.43±11.67 | 23.25 (18,32.7) | 8.1-48.1 | |
| Thick fibers with green birefringence | | | | |
| Dental Follicle | 14.38±9.72 | 14 (5.2,19) | 2.7-35.7 | 0.87 |
| Dentigerous Cyst | 13.38±10.29 | 12.6 (6,17.5) | 0-36.6 | |
| Ameloblastoma | 12.49±8.12 | 14.3 (4.4,17) | 0-26.8 | |
| Radicular Cyst | 13.34±13.44 | 8.2 (3.6,17.6) | 0-37.5 | |
| Odontogenic Keratocyst | 10.22±8.18 | 9.5 (3.4,14.6) | 0-25.9 | |
| Thick fibers with orange birefringence | | | | |
| Dental Follicle | 60.43±14.53 | 64.15 (49.3,69) | 33.3-80.8 | 0.397 |
| Dentigerous Cyst | 64.23±16.89 | 69.4 (54,75.9) | 29.3-82.5 | |
| Ameloblastoma | 66.72±10.99 | 69.95 (57.4,75.6) | 43.9-78.9 | |
| Radicular Cyst | 63.14±20.19 | 63.7 (53.8,82.4) | 29.2-88.5 | |
| Odontogenic Keratocyst | 75.69±17.07 | 76.35 (63.3,90.5) | 48.1-98.4 | |
| Thick fibers with yellow birefringence | | | | |
| Dental Follicle | 25.17±9.14 | 22.3 (20,26.2) | 15.4-46 | 0.14 |
| Dentigerous Cyst | 22.39±11.81 | 18.9 (14.5,31.5) | 3.4-43.5 | |
| Ameloblastoma | 20.77±5.53 | 21.45 (14.6,25.5) | 13.4-29.3 | |
| Radicular Cyst | 23.54±10.43 | 27.95 (11.8,30.8) | 4.3-33.9 | |
| Odontogenic Keratocyst | 14.07±9.31 | 14.2 (6.8,23.3) | 0-25.9 | |

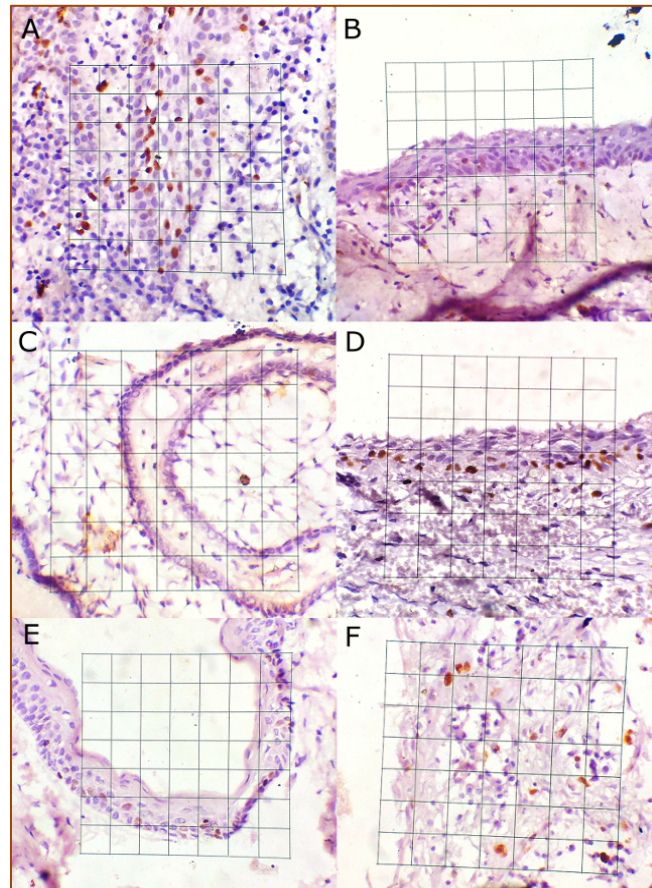


Figure 1. Ki67 expression in epithelium of Odontogenic cysts and tumours. A) Hyperplastic Dental Follicle, B) Dentigerous Cyst, C) Follicular Ameloblastoma, D) Unicystic Ameloblastoma E) Odontogenic Keratocyst F) Radicular Cyst.

As most odontogenic cysts showed some degree of inflammation, we correlated the degree of inflammation with the epithelial Ki-67 expression. Moderate to severe inflammation seen in DC showed corresponding higher Ki-67 expression. At the same time, high proliferation rates were observed irrespective of the degree of inflammation in UCA and OKC. Cases of Dental Follicle were all having moderate to severe inflammation and showed higher proliferation rates. All our cases of radicular cysts showed moderate to severe inflammation, which corresponded with an increase in both basal and suprabasal expression of Ki67 (Figure 2).

A diverse birefringence pattern (representing the maturity of the collagen fibers) was seen irrespective of collagen thickness. We observed both thick and thin fibers showing green (representing immature fibers), and yellow or orange (representing mature fibers) birefringence in picrosirius red-stained sections. The highest percentage of immature fibers (thin fibers with green birefringence) was seen in ameloblastoma (21.85%) and was the least in Dentigerous cyst (14.7%). An exact reversal was seen in the percentage of mature thin fibers (thin fibers with orange birefringence) with predominance in the Dentigerous cyst (60.35%) and least in Ameloblastoma (45.05%). The percentage of intermediate fibers (thin fibers of yellow birefringence) was higher in Radicular cyst (36.95%) and closely followed by Ameloblastoma (34.8%). The percentage of immature thick fibers (showing green birefringence) was highest in Ameloblastoma (14.3%) and least in Radicular cyst (8.2%). The thick fibers with orange birefringence (mature fibers) were highest in Odontogenic Keratocyst (76.35%), followed by ameloblastoma (69.95%), Dentigerous cyst (69.4%), Dental follicle (64.15%) and least in Radicular cyst (63.7%). The percentage of thick fibers of yellow birefringence (intermediate fibers) was highest in the Radicular cyst (27.95%) and least in OKC (14.2%) (Table 1 and Figure 3).

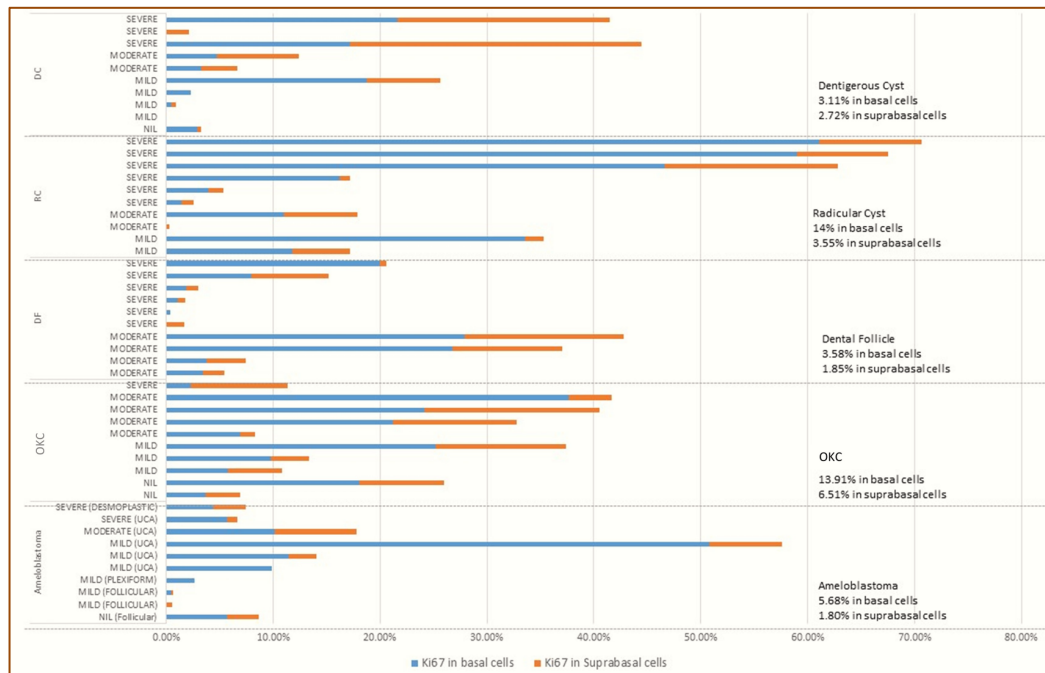
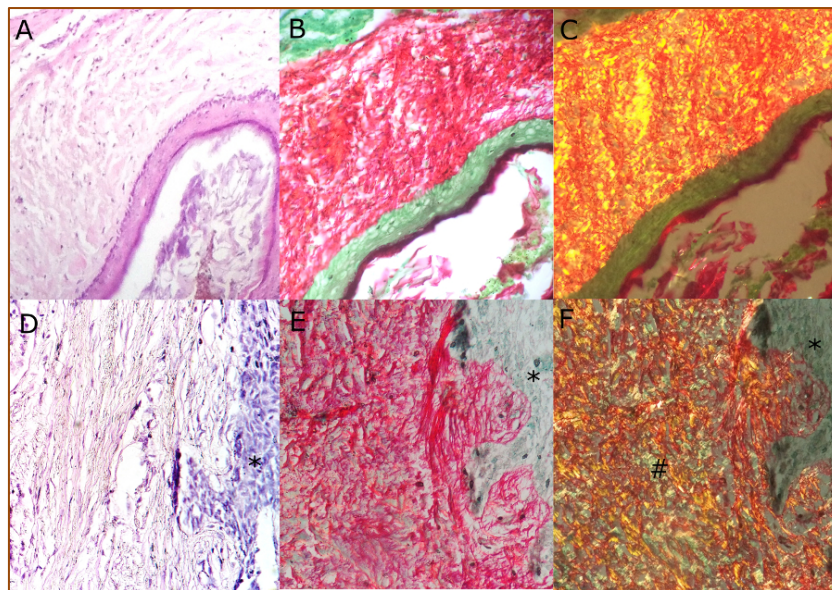


Figure 2. Expression of Ki67 in association with different levels of inflammation.



*Follicle of ameloblastoma; #Green birefringence in the stroma of ameloblastoma.

Figure 3. A, B, and C represent Odontogenic Keratocyst. D, E, F represents Follicular Ameloblastoma. A and D: Hematoxylin and Eosin, B, and E: Picrosirius Red Stain, C and F: Polarization pattern.

Discussion

Odontogenic cysts and tumours originate from the odontogenic apparatus in the alveolar process. The cells of origin could be the cell rests (serres or malassez), oral epithelium, basal cell hamartias, gubernacular dentis, etc. Although they originate from the common pool of cells, they present with diverse radiographic and histopathological appearances. This could be owing to the difference in the mechanisms of initiation, growth, and sustenance.

In our 50 cases of odontogenic cysts and tumours, Ki67 positivity in the basal cell layer was highest in Radicular cyst, followed by OKC, Ameloblastoma, Dental Follicle, and Dentigerous cyst. Comparable results

were obtained by Soluk Tekkeşin et al. [6]. The radicular cyst has an inflammatory etiology, whereas OKC is developmental in origin. In RC, the bacterial contamination of the root canal initiates a continuous inflammatory stimulus by producing growth factors like EGF and cytokines (IL-1, IL-6, TNF- α) on the odontogenic epithelium [7]. These factors lead to the proliferation of the epithelium seen histologically as an arcading pattern.

The higher Ki-67 proliferation rate in OKC, on the other hand, indicates an intrinsic growth potential independent of the inflammatory stimulus. It is known that suppression of normal p53 protein or altered p53 metabolism either due to maturation or changed turnover of wild-type p53 protein occurring in odontogenic epithelial lesions might lead to increased proliferative states [8]. de Oliveira et al. [7] have found a significant difference in p53 and PCNA expressions in OKC compared to other odontogenic lesions. Thus a presence of an altered p53 expression in OKC might explain the higher proliferative states of OKC, which also supports our findings of higher expression of Ki67 in the suprabasal epithelial cells. Soluk Tekkeşin et al. [6], Slootweg [8], Gadbaill et al. [3], and Singh et al. [9] have also reported a higher suprabasal cell proliferation rate of the Odontogenic Keratocyst. Studies have found that OKC shows higher expression of the anti-apoptotic molecule bcl2 throughout the thickness of the lining epithelium.

In contrast, this expression is seen only in the peripheral cells of RC and ameloblastoma. Less apoptotic activity is mirrored by the higher Ki67 expression in the suprabasal region of OKC, peripheral cells of ameloblastoma, and RC. The reduced suprabasal positivity of RC could be because of the expression of Bax, a pro-apoptotic gene [6,10]. de Oliveira et al. [7] studied the expression of EGFR, Ki67, and survivin in odontogenic cysts. They found that OKC shows the presence of stimulus-independent proliferative potential, a characteristic of neoplastic cells. Significant expression of survivin (an inhibitor of apoptosis) in the suprabasal region of OKC supports proliferation [11].

Our result confirms that the OKC has a proliferation and maturation pattern different from the other odontogenic lesions. de Oliveira et al. [7] and Brown et al. [12] suggested that the higher expression of suprabasal proliferation may represent epithelial disorganization similar to epithelial dysplasia.

Inflammation is a significant factor that influences the histological appearance of a cyst. Inflammatory cytokines induce epithelial proliferation leading to hyperplastic epithelium with the formation of epithelial arcades. Studies suggest that inflammation changes the cellular proliferation rate but not the biological behavior. de Paula et al. [13], from his study, showed OKC had higher Ki67 expression in increased inflammation and changed the cyst morphology to form non-keratinized epithelium. Kaplan [14] and Hishberg et al. [5] found no significant differences in proliferation rate with inflammation in OKC.

We found overall low expression of Ki67 in DC but the presence of inflammation correlated with higher expression of Ki67. A similar result was found by Singh HP et al. [9] using PCNA. Although a dentigerous cyst is categorized as a developmental cyst, studies have shown the initial inflammatory response as the initiator of a dentigerous cyst. It is hypothesized that tooth eruption incites inflammation and leads to epithelial cell proliferation. Cell stress induced by the transient inflammatory stimulus leads to cyst cavity formation by a feedback mechanism, which causes the proliferation of basal cells and the desquamation of superficial cells. Following this, the cyst enlarges independent of inflammatory stimuli and is maintained by osmotic balance [7].

In our study, inflammation and Ki-67 expression showed a positive correlation in DC but not in other cysts/tumours. This lack of correlation between inflammation and proliferative marker may be attributed to the inflammatory cytokines targeting a different cytoplasmic target. MCM-2 (minichromosome maintenance

protein) could be one such target of the inflammatory cytokine, which is expressed higher in RC than in OKC [15].

We observed that the rate of proliferation is seen predominantly in peripheral cells of ameloblastoma, and UCA had a higher proliferation index compared to the conventional form. This could be attributed to the manner of cell count. The cystic lining in UCA is composed of two or three cells. The total number of cells assessed in UCA is, therefore, quantitatively lesser compared to the other forms of ameloblastoma. As only the peripheral cells of ameloblastoma express Ki-67, the count of Ki-67 positive cells remains equivalent and results in a relatively higher proportion of positive cells. This is similar to the results reported by Meer et al. [4] and Nafarzadeh et al. [16].

The epithelial proliferation can influence the stromal collagen character, which is critical for the growth and sustenance of cysts/tumours. Picrosirius red staining can identify the maturity of stromal collagen fibers. In our study, we observed that ameloblastoma had the highest percentage of thin fibers with a predominance of green birefringence, indicating a greater proportion of immature fibers. DC had the second-highest percentage of thin fibers but showed orange birefringence. OKC showed a predominance of thick collagen fibers, and additionally, even the thin collagen fibers of OKC were predominantly of orange birefringence, indicating mature collagen. The radicular cyst had a high proportion of intermediate yellow birefringent thick collagen fibers.







Ki67 expression is highest suprabasally in OKC with an increase in orange birefringence, while ameloblastoma is proliferative in basal cells with thick green birefringence. The higher activity of collagenases in the stroma of ameloblastoma might lead to increased collagen remodeling and might be the cause of a higher proportion of immature fibers. Zhang et al. [17] and Khalifa et al. [18] have found higher activity of MMP2 in ameloblastoma than in OKC. Zhang et al. [17] also studied the expression of RECK (reversion-inducing cysteine-rich protein with Kazal motifs) in ameloblastoma. RECK inhibits MMPs, and in their study, they found lesser expression of RECK in ameloblastoma corresponded to higher expression of MMP2. De Oliveira Ramos et al. [19] found that Ki67 expression positively correlated with epithelial MMP and not in stromal MMP of OKC, which correlates with our finding of lesser green birefringent fibers with an increase in Ki67 proliferation [17-19].

OKC and ameloblastoma show similar radiographic appearance and clinical course in terms of bony extension and recurrence rate. OKC showed higher epithelial proliferation but exhibited a more mature collagenous capsule. Tightly-packed orange (mature) birefringent fibers in OKC indicates its role in providing structural support in addition to its neoplastic behavior [5]. Ameloblastoma, on the other hand, has a lower epithelial proliferation rate, with the supporting connective tissue stroma showing predominantly immature (green birefringent) fibers in thick as well as thin fibers. Thus, the local extension of these two lesions might be attributed to two different molecular scenarios, namely the proliferation of epithelium in OKC and follicles of ameloblastoma tend to invade through the less dense stroma. A higher proportion of thin fibers was seen in ameloblastoma and DC, which supports their origin from the primitive odontogenic stroma. Conventionally immature stroma is seen in the dentigerous cyst, and mature stroma is seen in ameloblastoma. We found a higher proportion of immature fibers in ameloblastoma, which is in contrast to the study by Haripriya et al. [20]. Biologically both ameloblastoma and dentigerous cysts are derived from the primitive dental follicle and its associated structures. The maturity of the collagen depends on the influence of growth factors, cytokines, and also on the age of the lesion. Thus, we must be cautious when we correlate the maturation pattern and biologic behavior of these lesions.

Conclusion

The epithelium of odontogenic keratocyst might have intrinsic growth potential, whereas the radicular cyst shows proliferation only under the influence of inflammation. We must remain cognizant of the role of epithelial proliferation and the nature of connective tissue stroma as they influence the rate of growth of the lesion. The nature of growth in odontogenic keratocyst is attributed to epithelial proliferation, whereas in ameloblastoma, it is ascribed to the loose immature connective tissue stroma, which allows the spread of the follicles.

Authors' Contributions

| | | | |
|---|---|---|---|
| SDB |  | https://orcid.org/0000-0002-1819-7951 | Conceptualization, Investigation, Data Curation and Writing - Original Draft. |
| SN |  | https://orcid.org/0000-0002-2686-0397 | Conceptualization, Methodology, Validation and Supervision. |
| KB |  | https://orcid.org/0000-0001-6033-9581 | Conceptualization, Methodology and Project Administration. |
| AJL |  | https://orcid.org/0000-0003-1691-9890 | Formal Analysis and Writing - Review and Editing. |
| NKP |  | https://orcid.org/0000-0002-0869-3839 | Resources and Writing - Review and Editing. |
| NM |  | https://orcid.org/0000-0001-9084-3383 | Formal Analysis and Writing - Review and Editing. |
| All authors declare that they contributed to critical review of intellectual content and approval of the final version to be published. | | | |

Financial Support

None.

Conflict of Interest

The authors declare no conflicts of interest.

Data Availability

The data used to support the findings of this study can be made available upon request to the corresponding author.

References

- [1] Scholzen T, Gerdes J. The Ki-67 protein: from the known and the unknown. *J Cell Physiol* 2000; 182(3):311-22. [https://doi.org/10.1002/\(SICI\)1097-4652\(200003\)182:3<311::AID-JCP1>3.0.CO;2-9](https://doi.org/10.1002/(SICI)1097-4652(200003)182:3<311::AID-JCP1>3.0.CO;2-9)
- [2] Vij R, Vij H, Rao NN. Evaluation of collagen in connective tissue walls of odontogenic cysts – a histochemical study. *J Oral Pathol Med* 2011; 40(3):257-62. <https://doi.org/10.1111/j.1600-0714.2010.00961.x>
- [3] Gadbaail AR, Patil R, Chaudhary M. Co-expression of Ki-67 and p53 protein in ameloblastoma and keratocystic odontogenic tumor. *Acta Odontol Scand* 2012; 70(6):529-35. <https://doi.org/10.3109/00016357.2011.600714>
- [4] Meer S, Galpin JS, Altini M, Coleman H, Ali H. Proliferating cell nuclear antigen and Ki67 immunoreactivity in ameloblastomas. *Oral Surg Oral Med Oral Pathol Oral Radiol Endod* 2003; 95(2):213-21. <https://doi.org/10.1067/moe.2003.62>
- [5] Hirshberg A, Sherman S, Buchner A, Dayan D. Collagen fibres in the wall of odontogenic keratocysts: a study with picrosirius red and polarizing microscopy. *J Oral Pathol Med* 1999; 28(9):410-2. <https://doi.org/10.1111/j.1600-0714.1999.tb02112.x>
- [6] Soluk Tekkeşin M, Mutlu S, Olgaç V. Expressions of bax, bcl-2 and Ki-67 in odontogenic keratocysts (Keratocystic Odontogenic Tumor) in comparison with ameloblastomas and radicular cysts. *Turk Patoloji Derg* 2012; 28(1):49-55. <https://doi.org/10.5146/tjpath.2012.01097>
- [7] de Oliveira MG, da Silva Lauxen I, Chaves AC, Rados PV, Filho MS. Immunohistochemical analysis of the patterns of p53 and PCNA expression in odontogenic cystic lesions. *Med Oral Patol Oral Cir Bucal* 2008; 13(5):275-80.
- [8] Slootweg PJ. p53 protein and Ki-67 reactivity in epithelial odontogenic lesions. An immunohistochemical study. *J Oral Pathol Med* 1995; 24(9):393-7. <https://doi.org/10.1111/j.1600-0714.1995.tb01207.x>
- [9] Singh HP, Shetty DC, Kumar A, Chavan R, Shori DD, Mali J. A molecular insight into the role of inflammation in the behavior and pathogenesis of odontogenic cysts. *Ann Med Health Sci Res* 2013; 3(4):523-8. <https://doi.org/10.4103/2141-9248.122072>
- [10] Piattelli A, Fioroni M, Rubini C. Differentiation of odontogenic keratocysts from other odontogenic cysts by the expression of bcl-2 immunoreactivity. *Oral Oncol* 1998; 34(5):404-7. [https://doi.org/10.1016/S1368-8375\(98\)00026-8](https://doi.org/10.1016/S1368-8375(98)00026-8)

- [11] de Oliveira MG, da Silva Lauxen I, Chaves AC, Rados PV, Filho MS. Odontogenic epithelium: immunolabeling of Ki-67, EGFR and Survivin in pericoronal follicles, dentigerous cysts and keratocystic odontogenic tumors. *Head Neck Pathol* 2011; 5(1):1-7. <https://doi.org/10.1007/s12105-010-0216-0>
- [12] Browne RM. Per[cyst]ent growth: the odontogenic keratocyst 40 years on. *Ann R Coll Surg Engl* 1996; 78(5):426-33.
- [13] de Paula AM, Carvalhais JN, Domingues MG, Barreto DC, Mesquita RA. Cell proliferation markers in the odontogenic keratocyst: effect of inflammation. *J Oral Pathol Med* 2000; 29(10):477-82. <https://doi.org/10.1034/j.1600-0714.2000.291001.x>
- [14] Kaplan I, Hirshberg A. The correlation between epithelial cell proliferation and inflammation in odontogenic keratocyst. *Oral Oncol* 2004; 40(10):985-91. <https://doi.org/10.1016/j.oraloncology.2004.04.017>
- [15] Guler N, Çomunoglu N, Cabbar F. Ki-67 and MCM-2 in dental follicle and odontogenic cysts: the effects of inflammation on proliferative markers. *Sci World J* 2012; 2012:946060. <https://doi.org/10.1100/2012/946060>
- [16] Nafarzadeh S, Seyedmajidi M, Jafari S, Bijani A, Rostami-Sarokolaei A. A comparative study of PCNA and Ki-67 expression in dental follicle, dentigerous cyst, unicystic ameloblastoma and ameloblastoma. *Int J Mol Cell Med* 2013; 2(1):27-33.
- [17] Zhang B, Zhang J, Xu ZY, Xie HL. Expression of RECK and matrix metalloproteinase-2 in ameloblastoma. *BMC Cancer* 2009; 9(1):1-6. <https://doi.org/10.1186/1471-2407-9-427>
- [18] Khalifa GA, Shokier HM, Abo-Hager EA. Evaluation of neoplastic nature of keratocystic odontogenic tumor versus ameloblastoma. *J Egypt Natl Canc Inst* 2010; 22(1):61-72.
- [19] de Oliveira Ramos G, Costa A, Meurer MI, Vieira DSC, Rivero ERC. Immunohistochemical analysis of matrix metalloproteinases (1, 2, and 9), Ki-67, and myofibroblasts in keratocystic odontogenic tumors and pericoronal follicles. *J Oral Pathol Med* 2014; 43(4):282-8. <https://doi.org/10.1111/jop.12131>
- [20] Haripriya P, Ananthaneni A, Guduru VS, Horatti PK, Kiresur MA, Vara JT. Collagen during odontogenesis and in ameloblastoma: A polarizing microscopic study. *J Oral Maxillofac Pathol* 2019; 23(3):474. https://doi.org/10.4103/jomfp.JOMFP_204_17