

Correlation of Structural Uterine Abnormalities with Abnormal Uterine Bleeding Among Premenopausal Women with Infertility

Udobi S.I¹, Onuh A.C², Udobi J.I³, Ezeama C.O.⁴

¹ Dept. of Radiology, Nnamdi Azikiwe University, Awka, Nigeria.

² Dept. of Radiation Medicine, University of Nigeria Teaching Hospital, Ituku-Ozzalla, Enugu, Nigeria.

³ Dept. of Maths/Statistics, Federal Polytechnic, Oko, Nigeria.

⁴ Dept. of Obstetrics and Gynaecology, Nnamdi Azikiwe University, Awka, Nigeria.

ABSTRACT:

Objective: To document the various structural uterine abnormalities detected on transabdominal ultrasonography (TAUS) and hysterosalpingography (HSG) of premenopausal women with infertility and abnormal uterine bleeding (AUB) and determine whether the structural abnormalities correlate well with the clinical forms of AUB among the patients.

Methodology: This is a prospective and analytical study of 98 infertile women with history of AUB, referred for HSG. Clinical history including the forms of AUB were obtained from the subjects. Subjects were evaluated with TAUS and HSG after obtaining both ethical clearance and informed consent. Statistical analysis was with the Statistical Package for Social Sciences (SPSS) version 21. Simple frequency, measures of central tendency and dispersion, crosstabulation as well as Pearson's correlation tests were carried out. For correlation, $p \leq 0.05$ was considered significant.

Result: Fibroids, followed by intrauterine adhesions (IUA) were the commonest structural uterine abnormalities. Fibroids were detected with both TAUS and HSG, while IUA were detected with HSG only. Shortened menstrual flow was the commonest form of AUB and occurred in 52 (53.1%) of the subjects, followed by light menstrual flow 41(41.8%). The menses were irregular in 33(33.7%), light and shortened in 32(32.7%), heavy in 21(21.4%), prolonged in 16(16.3%), and, heavy and prolonged in 9(9.2%). Fibroids occurred most frequently among those with heavy and prolonged menstrual bleeding while IUA occurred most frequently among those with scanty and reduced menstrual bleeding. On TAUS, HSG, or combined TAUS and HSG, there were significant correlations between fibroids and prolonged heavy menses, fibroids and heavy menses, and, fibroid and prolonged menses. On HSG, significant correlation existed between IUA and scanty short menses.

Conclusion: Uterine fibroids and intrauterine adhesions were the commonest structural uterine abnormalities detected. There was significant correlation between fibroids and history of heavy menstrual flow as well as between fibroids and prolonged menses, and IUA and scanty short menses.

KEY WORDS: abnormal uterine bleeding, fibroids, structural uterine abnormalities

INTRODUCTION

Abnormal uterine bleeding (AUB) also called abnormal menstrual bleeding, refers to any alteration in normal menstrual cycle pattern and may involve alteration in regularity, frequency, duration of flow and heaviness of flow.^{1,2} It can also be viewed as any significant deviation from a woman's established menstrual pattern.³ The duration of normal menstrual bleeding is 3-8 days and normal menstrual cycle has a duration of 21-35 days.⁴ A perceived deviation from normal menstrual pattern is a common source of concern among women; especially among women with infertility, as many of such women attribute their infertility to the AUB.

Many of the terms previously used to describe AUB have been found to be both confusing and vaguely defined, and therefore unsatisfactory.^{1,5,6} Likewise, defining, describing and classifying the causes of AUB in satisfactory terms had been an uphill task.^{1,6} As a result of the need to arrive at satisfactory consensus that would be simple, clear, have practical applications as well as be adoptable into different languages in describing the symptoms and the causes of AUB, the International Federation of Gynecology and Obstetrics (FIGO) committee on menstrual disorders (menstrual disorders working group) proposed a system that first defined the symptoms of abnormal uterine bleeding and secondly proffered an acronym for its common etiologies.^{1,2} The work which was

Correlation of Structural Uterine Abnormalities with Abnormal Uterine Bleeding Among Premenopausal Women with Infertility

approved by FIGO and adopted by the American College of Gynecologists (ACOG), was also followed by updates from FIGO in 2011 and 2018.^{2,7,8}

On the one hand; the above system developed by FIGO for nomenclature of symptoms of normal and abnormal uterine bleeding (AUB) in the reproductive years is designated 'FIGO AUB System 1', and on the other hand, the system for classification of causes of AUB is designated 'FIGO AUB System 2' and has the acronym PALM-COEIN.⁹

Thus, following the FIGO AUB system 1, various forms of abnormal uterine bleeding resulting from deviations from the normal menses can be described with simple terminologies that include: irregular menses, increased or reduced duration of menstrual cycle, heavy or light menstrual bleeding, and prolonged or shortened menstrual flow.¹ There are also combined forms as seen in heavy and prolonged menstrual bleeding, light and shortened menstrual flow.¹ The committee also recommended the discontinuation of some terminologies previously used to describe different forms of AUB.^{1,5,6} Those previously used terms recommended to be avoided because they were deemed confusing and vaguely defined include; oligomenorrhea, metrorrhagia, hypermenorrhea and dysfunctional uterine bleeding (DUB).^{1,5,6}

Similarly, following the FIGO AUB system 2, the causes of abnormal uterine bleeding can be defined and classified using simple terms with the acronym 'PALM-COEIN'. 'PALM-COEIN' stands for polyp, adenomyosis, leiomyoma, malignancy, coagulopathy, ovulatory dysfunction, endometrium, iatrogenic and non-classified (not yet classified, no cause detected).^{6,10} The PALM components are due to structural uterine abnormalities and can be detected and measured with radiological modalities. The COEIN components are non-structural and attributed to coagulation disorders and hormonal dysfunction or other reproductive, gynecologic or systemic morbidities.^{6,9,11} Intrauterine adhesions (IUA), though not mentioned in PALM-COEIN, have also been noted among uterine causes of AUB in premenopausal period.¹

Internationally, the prevalence of AUB among women of reproductive age is estimated at between 3% - 30%.² While some authors observed that AUB is one of the commonest complaints in gynaecologic clinics,⁹ others noted that in the peri-menopausal and post-menopausal groups, it accounts for more than 70% of all gynecological consultations.¹³ Other authors opined that it will be experienced by up to one-third of women in their life time, and that it is the reason for two-thirds of all hysterectomies.^{2,14} A study of perimenopausal women found 67.97% of the patients with AUB to be between 40 and 45 years of age.¹⁰

Heavy menstrual bleeding was reported by some authors to be the most common presentation of AUB.^{1,9} It was further noted that though heavy and prolonged menstrual bleeding was relatively common, it occurred much less commonly than heavy menstrual bleeding.¹ A study of perimenopausal women with AUB noted that 43.69% presented with heavy or prolonged bleeding.¹⁰ Premenopausal women with AUB may also present with pelvic pains and or infertility. Abnormal uterine bleeding, especially if coupled with infertility; can place serious physical, psychological, social and financial burden on the patient.^{2,12,16}

While Munro and co-workers,⁹ reported the most common cause of anatomic AUB to be fibroids or polyps; Whitaker and Critchley¹⁵ found that AUB often coexisted with fibroids, and that fibroids were highly prevalent in women that presented with AUB. Furthermore, Ryan¹⁷ noted that patients with symptomatic fibroids often presented with heavy and prolonged menses.

Some imaging modalities that are useful in investigation of AUB include ultrasound (2-dimensional, 3-dimensional, transvaginal, sonohysterography), hysterosalpingography (HSG), hysteroscopy, and magnetic resonance imaging (MRI).^{2,18,19} Abnormal uterine bleeding and pelvic diseases are well evaluated with ultrasound which is also the most commonly used modality for imaging of pelvic diseases.^{3,4} Ultrasound is a real time study and does not use ionizing radiation.³ Transabdominal ultrasound (TAUS) is readily available and affordable but less sensitive than transvaginal sonography (TVS) or three-dimensional ultrasound (3D-US) in showing lesions in the uterus and the ovaries.^{18,19} Sonohysterography is more accurate than TVS in detecting intracavitary lesions like polyp and submucosal fibroids, but is more inconveniencing to the patients.²

HSG demonstrates the cervical canal, uterine cavity and the fallopian tubes. It is regarded as the best imaging modality for demonstrating the fallopian tubes,²⁰ a quality that is very important if AUB is co-existing with infertility. However it uses ionizing radiation. MRI demonstrates more details of pelvic organs and is important in surgical planning, but is costly and not readily available especially in the developing nations.²

Using ultrasonography and histopathological studies, Talukdar and Mahela¹⁰ found uterine fibroids as the leading cause of AUB, and also noted that radiological and pathological evaluation correlated well to diagnose fibroids. They further reported that ultrasonography diagnosed fibroids in 45.63% of the patients and showed 89.13% sensitivity and 89.47% specificity when compared with histopathology as standard.¹⁰

There are very few studies in the available literature that show the correlation of various forms of AUB with radiological diagnosis of various structural uterine lesions. We did not find any such correlation study in our environment. The result of this combined

Correlation of Structural Uterine Abnormalities with Abnormal Uterine Bleeding Among Premenopausal Women with Infertility

TAUS and HSG evaluation of the uterus for structural lesions among infertile premenopausal women with AUB will be useful not only to the patients with AUB, but also to the clinicians and policy makers.

METHODOLOGY

This prospective and analytical study of 98 premenopausal women with infertility who presented with history of AUB was carried out simultaneously at the department of Radiation Medicine of the University of Nigeria Teaching Hospital (UNTH), Ituku-Ozalla, Enugu state and Hansa Clinics (a radiology centre located in Enugu).

Prior to the study, ethical clearance was obtained from the Research Ethics Committee of UNTH.

The above subjects who were booked for HSG or for both HSG and TAUS, who gave their consent to be included for the study were recruited in a consecutive pattern. Subjects who did not have history of AUB and those who declined to be included in the study were excluded in the analysis. Those with incomplete and missing data were also excluded from the analysis.

Hysterosalpingography booking was in compliance with the 10 day rule. The two procedures were conducted the same day. The TAUS was carried out first to avoid misinterpreting contrast spill into the peritoneal cavity during HSG procedure as pathological pelvic collection on TAUS.

We assigned a particular number to each subject. The number was for both TAUS and HSG. A radiologist carried out the TAUS and wrote the reports while two radiologists performed the HSG and jointly reported them without referring to the TAUS report. The numbers earlier assigned to the subjects were used later to sort out the corresponding TAUS and HSG reports for data entering and analysis.

The TAUS was done with Aloka SSD-550 machine, manufactured by Aloka, Japan 1995 which had both B-mode and Doppler facilities and was fitted with curvilinear probe of 3.5-5.0MHz frequency.

Prior to the HSG, the procedure was explained to the subjects. The subjects were also counselled and their fears allayed. Antispasmodic agent, Hyoscine bromide (20mg, i.v) was administered. As the fluoroscopy machines were not functional during the period of the study, about 5-60ml of sodium diatrizoate/meglumine diatrizoate 76% (Urografin 76%) was slowly injected into the uterine cavity through a Wilkinson's cannula in stages to demonstrate the cervical canal, uterine cavity, fallopian tubes and peritoneal spill. Anterior-posterior projection images were acquired at breath-holding, with screen-film combination, and processed manually.

Analysis was with the Statistical Package for the Social Sciences (SPSS) version 21.0 by IBM Corp. Armonk, New York, USA. Simple frequency tables, measures of central tendencies, measures of dispersion as well as Pearson's correlation test were performed. For correlation test, $p \leq 0.05$ was considered statistically significant.

RESULTS

A total of 98 subjects had positive history of abnormal uterine bleeding and were recruited for the study. The age ranged from 20 years to 47 years; with a mean of 32.8 years, median of 33 years and mode of 36 years. Those with age range of 20-29 years were 29(29.6%), those with the age range of 30-39 years were 56(57.2%), while those with ≥ 40 years were 13(13.2%).

Primary infertility occurred in 18(18.4%) while secondary infertility occurred in 80(81.6%). Seventy six 76(77.6%) had parity of ≤ 1 while 22(22.4%) had parity of ≥ 2 . The duration of menstrual cycle was within normal range in 97(99%) and abnormal in 1(1.0%). Fifty nine subjects 59(60.2%) had 28 day cycle.

Commonest uterine findings were fibroids and intrauterine adhesions.

Table 1 shows the frequencies of various forms of abnormal uterine bleeding among the subjects. The most frequent was shortened menstrual flow and it occurred in 52 (53.1%) of the subjects. This was followed by light menstrual flow 41(41.8%), irregular menses 33(33.7%), light and shortened menses 32(32.7%), heavy menstrual flow 21(21.4%), prolonged menses 16(16.3%), and finally by heavy and prolonged menstrual flow 9(9.2%).

In table 2, the major diagnoses made with TAUS and HSG evaluation of the uterus are shown. With TAUS, uterine abnormality was detected in 20(20.4%) of the subjects; uterine fibroids (leiomyoma) in 20(20.4%) and intrauterine adhesions in 0(0.0%). There was no endometrial polyp, nor adenomyosis nor uterine malignancy detected. With HSG, abnormality was detected in the uterus in 22(22.4%) of subjects, uterine fibroids in 10(10.2%) and intrauterine adhesions in 12(12.2%). It detected no polyp, adenomyosis nor malignancy. The 10 subjects diagnosed of fibroids with HSG were among the 20 diagnosed of the same lesion by TAUS, so that the TAUS diagnoses of fibroids represents the overall combined diagnosis of the lesion by combined TAUS and HSG study. There was no intrauterine adhesions detected with TAUS so that the HSG diagnosis of the lesion represents the combined diagnosis of the lesion by TAUS and HSG. The combined TAUS and HSG examination detected uterine abnormality in 32(32.7%); uterine fibroid in 20(20.4%) and, intrauterine adhesions in 12(12.2%). One patient with history of heavy and prolonged menses was diagnosed of uterine fibroid on TAUS, and of uterine fibroid and bilateral cornual occlusion on HSG.

Correlation of Structural Uterine Abnormalities with Abnormal Uterine Bleeding Among Premenopausal Women with Infertility

Table 3 further shows the TAUS findings among the specific forms of AUB. Of the 21 subjects with history of heavy menses, 8(38.1%) were diagnosed of fibroid, out of the 41 subjects with history of light menses, 6(14.6%) were diagnosed of fibroids. Fibroids were detected in 7(43.8%) of the 16 subjects with history of prolonged menstrual bleeding, and in 8(15.4%) of the 52 with shortened menses.

Out of the 9 subjects with history of heavy and prolonged menses, 5(55.6%) were diagnosed of fibroids, while out of the 32 with light and shortened menses, 2(6.3 %) had fibroids; and out of the 33 subjects with irregular menses, 7(21.2%) had uterine fibroids.

Tables 4 and 5 further show the HSG findings among the specific forms of AUB. Of the 21 subjects with history of heavy menses, 6(28.6%) were diagnosed of fibroids and 1(4.8%) was diagnosed of intrauterine adhesions. Out of the 41 subjects with history of light menses, 1(2.3%) was diagnosed with fibroids and 8(19.5%) had intrauterine adhesions; and out of the 16 subjects with history of prolonged menstrual bleeding, 5(31.3%) had uterine fibroids and 1(6.3%) had intrauterine adhesions, while out of the 52 with shortened menses, 3(5.8%) had fibroids and 8(15.4%) had intrauterine adhesions.

Out of the 9 subjects with history of heavy and prolonged menses, 4(44.4%) were diagnosed of fibroids and none showed the presence of intrauterine adhesions; while out of the 32 with light and shortened menses 0(0.0%) had fibroids and 7(21.9%) had intrauterine adhesions and out of the 33 subjects with irregular menses, 3(9.1%) had uterine fibroids and 5(15.2%) had intrauterine adhesions.

Using either TAUS or HSG, fibroids were detected frequently among the AUB subgroups in this order: the heavy and prolonged subgroup, followed by the prolonged menstrual flow subgroup, the heavy flow subgroup, irregular menses subgroup, shortened menstrual flow subgroup, light menses subgroup, and lastly, shortened and light flow subgroup, but the frequencies were higher in the TAUS study than HSG. On HSG, intrauterine adhesions in the subgroups occurred in this order: light and shortened menses subgroup, followed by the light menstrual flow subgroup, shortened flow, irregular menses, prolonged flow, heavy flow and finally, by heavy and prolonged flow subgroup.

Pearson's correlations test showed significant correlation between the clinical histories of the following pairs of clinical forms of AUB: heavy menses and increased duration of menses, scanty menses and decreased duration of menses.

Based on radiological findings, there were significant correlations of fibroids with history of prolonged heavy menses, heavy menstrual flow, as well as with prolonged flow. These significant correlations were present whether the fibroid diagnosis was made with TAUS or HSG or with combination of TAUS and HSG.

Pearson's correlation tests showed significant correlation with negative correlation coefficient between the following pairs: fibroids on TAUS with history of shortened scanty menstrual flow, fibroids on HSG with history of shortened scanty menses, and fibroids on HSG with history of light menses.

There was no significant correlation of fibroids diagnosed on TAUS, or HSG or on combined TAUS and HSG with shortened menstrual flow, or irregular menses. There was also no significant correlation between fibroids detection on TAUS and history of light menses.

On HSG study there was significant correlation of IUA with history of scanty short menses, but not with the following forms of AUB; heavy menses, prolonged menses, prolonged heavy menses, scanty menses, short menses, and irregular menses.

Out of the total of 20 patients diagnosed by TAUS as fibroids, HSG diagnosed 10 as fibroids, while all the 78 patients diagnosed by TAUS as not having fibroids were diagnosed as not having fibroids by HSG. Thus relative to TAUS in the study, HSG had a sensitivity of 50% and specificity of 100% in detection of fibroid.

Table 1. Frequencies of various forms of abnormal menses

Form of AUB	Frequency	Percentage
Heavy	21	21.4
Light	41	41.8
Prolonged	16	16.3
Shortened	52	53.1
Heavy and prolonged	9	9.2
Light and shortened	32	32.7
Irregular	33	33.7

Correlation of Structural Uterine Abnormalities with Abnormal Uterine Bleeding Among Premenopausal Women with Infertility

Table 2. Major uterine abnormalities detected in the study

Name of study	Fibroid	IUA	Total
TAUS	20(20.4%)	0(0.00%)	20(20.4%)
HSG	10(10.2%)	12(12.2%)	22(22.4%)

Table 3. Frequencies and correlation of various forms of AUB with fibroids diagnosed using TAUS

Form of AUB	Fibroids dx with TAUS		
	Frequency(%) [*]	p-value	Interpretation
Heavy	8(38.1%)	0.023	Significant
Light	6(14.6%)	0.233	Not
Prolonged	7(43.8%)	0.011	significant
Shortened	8(15.4%)	0.193	Significant
Heavy and prolonged	5(55.6%)	0.006	Not
Light and shortened	2(6.3%)	0.015**	significant
Irregular	7(21.2%)	0.890	Significant
			Significant
			Not
			significant

*Expressed as a percentage of the specific form of AUB

**Significant p-value with negative correlation coefficient

Table 4. Frequencies and correlation of various forms of AUB with fibroids diagnosed using HSG

Form of AUB	Fibroids dx with HSG		
	Frequency(%) [*]	p-value	Interpretation
Heavy	6(28.6%)	0.001	Significant
Light	1(2.3%)	0.031**	Significant
Prolonged	5(31.3%)	0.002	Significant
Shortened	3(5.8%)	0.126	Not significant
Heavy and prolonged	4(44.4%)	<0.001	Significant
Light and shortened	0(0.0%)	0.020**	Significant
Irregular	3(9.1%)	0.798	Not significant

*Expressed as a percentage of the specific form of clinical AUB

**Significant p-value with negative correlation coefficient

Table 5. Frequencies and correlation of various forms of AUB with fibroids diagnosed using HSG

Type of abnormal menses	IUA dx with HSG		
	Frequency(%) [*]	p-value	Interpretation
Heavy	1(4.8%)	0.057	Not significant
Light	8(19.5%)	0.226	Not significant
Prolonged	1(6.3%)	0.057	Not significant
Shortened	8(15.4%)	0.226	Not significant
Heavy and prolonged	0(0.0%)	0.244	Not significant
Light and shortened	7(21.9%)	0.043	Significant
Irregular	5(15.2%)	0.737	Not significant

*Expressed as a percentage of the specific form of clinical AUB

Correlation of Structural Uterine Abnormalities with Abnormal Uterine Bleeding Among Premenopausal Women with Infertility

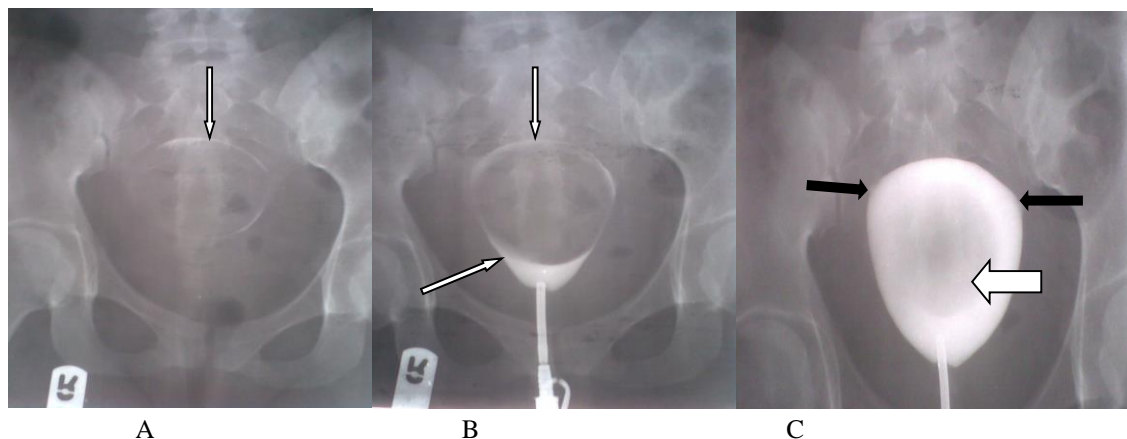


Fig. 1. HSG. Submucous fibroid seen as a pelvic mass with calcified rim (thin arrow in preliminary film A), and as intracavitary filling defect with rim/peripheral contrast opacification (thin arrow in early contrast image B), and area of reduced opacification (thick white arrow in late contrast filling image C).

There are also bilateral cornual occlusion (dark narrow arrows) in image C).

DISCUSSION

The mean age in our study (32.8 years) is slightly higher than 30.8 years obtained by Kocaoz et al.²¹ This is because our study population was limited to women of child bearing age who also presented with infertility, while theirs was of females of child bearing age with or without infertility. Similarly the minimum age in our study (21 years) was higher than theirs (15 years). This is because in our environment, a woman does not begin to present with infertility (whether primary or secondary) immediately she reaches child bearing age, but usually would have married first and have failed to achieve conception after the appropriate time interval of regular sex.²² So the minimum age of infertile women and consequently the average age will be higher than the general population of women of child bearing age.

The age range of patients with AUB in our study (21-47 years) differs from the age range of those with AUB studied by Talukdar and Mahela.¹⁰ This is because while our study population was of premenopausal female, theirs was of perimenopausal women.¹⁰ Similarly, majority of the women with AUB in our study (57.2%) were aged 30-39 years unlike in theirs in which 67.97% were aged 40-45 years.¹⁰ The difference can be explained by our study population being of premenopausal women while theirs was perimenopausal women.

Shortened menstrual flow was the commonest form of AUB in our study. This is at variance with the report by Fraser et al.¹ that noted heavy bleeding as the commonest. However our study is in agreement with their assertion that heavy and prolonged form of AUB occurs less commonly than heavy menstrual bleeding.¹

The finding of fibroids as the commonest structural uterine abnormality in our study is in concordance with the observation by Munro et al.⁹ that the commonest cause of anatomic AUB were fibroids or polyps. It is also in agreement with the assertion by Talukdar and Mahela¹⁰ that fibroids were the leading cause of AUB, and also with the observation by Njeze and Ezeofor that fibroids were the commonest structural abnormalities seen in their HSG study of women with infertility in Enugu, South East Nigeria²³. Our finding of uterine fibroids most commonly among those with heavy and prolonged menses, followed by prolonged menses and by heavy menses before other forms of AUB is in concordance with the statement by Ryan¹⁷ that symptomatic fibroids often present with heavy and prolonged menses. The frequency of fibroid diagnosed among patients with AUB in our study (20.4%) was lower than 45.63% obtained by another study.¹⁰ This is likely because the mean age in that study is higher than ours, hence their subjects had longer exposure to estrogen and progesterone and these hormones have been noted to promote the development of uterine fibroids.²⁴

Our finding of significant correlations between TAUS diagnosis of fibroids and the following clinical forms of AUB: heavy and prolonged menses, prolonged menses, and heavy menses, is in concordance with the findings by Talukdar and Mahela¹⁰ that ultrasonographic and histopathological evaluation correlated well to diagnose fibroids in their study population. This is despite the fact that their study population was perimenopausal while ours was premenopausal women and that they used TVS while we used TAUS. Thus it can be stated that regardless of use of TAUS or TVS the finding of uterine fibroids correlates well with the clinical history of AUB. Whitaker and Critchley¹⁵ similarly stated that AUB often coexist with fibroids, but Siregar²⁵ noted that AUB is likely a manifestation of fibroids rather than a causative factor.

Correlation of Structural Uterine Abnormalities with Abnormal Uterine Bleeding Among Premenopausal Women with Infertility

The finding of significant correlation (with a negative correlation coefficient) between the following pairs: fibroids on TAUS with history of shortened scanty menstrual flow, fibroids on HSG with history of shortened scanty menses, and fibroids on HSG with clinical history of light menstrual flow ; shows that the relationship between these pairs of variables, though significant, can be considered a negative correlation, more like an inverse relationship.^{26,27}

The finding of significant correlation between heavy menses and increased duration of menses can be attributed to the two forms having a common causative factor and not that one is a causative factor of another. Similar situation applies for the significant correlation between scanty menses and reduced duration of menses.

LIMITATION OF THE STUDY

This study was limited to ultrasonographic and hysterosalpingographic features in diagnosing the structural uterine lesions and did not carry out histopathological tests for confirmation.

RECOMMENDATION

Considering how few the study of this nature are in the available literature and how beneficial the information obtained will be to patients, clinicians and policy makers; more studies correlating uterine structural abnormalities with various form of abnormal uterine bleeding are recommended. The finding of uterine fibroids on both TAUS and HSG, as well as bilateral cornual occlusion on HSG, of one of our subjects with history of prolonged heavy menses and infertility, underlines the necessity of this type of study.

CONCLUSION

Uterine fibroids and intrauterine adhesions were the commonest structural uterine causes of AUB in our subjects. Fibroids were found most frequently among those with heavy and prolonged menses while intrauterine adhesions occurred most frequently among those with light and shortened menses. Significant correlations were found between fibroids and history of heavy menstrual flow as well as with fibroids and prolonged menses.

CONFLICT OF INTEREST: No conflict of interest.

ACKNOWLEDGEMENT: Nwachukwu Chibuisi P. (Noblevision Comp. Int'l), for assisting in setting the manuscript according to the recommended format.

REFERENCES

- 1) Fraiser IS, Critchley HOD, Broder M, Munro MG. The FIGO Recommendations on Terminologies and Definitions for Normal and Abnormal Uterine Bleeding. *Semin Reprod Med* 2011;29(5):383-390. DOI: <http://dx.doi.org/10.1055/s-0031-1287662>.
- 2) Davis E, Sparzak PB. Abnormal Uterine Bleeding. [Updated 2022 Feb 10]. In: StatPearls [Internet]. Treasure Island (FL): StatPearls Publishing; 2022 Jan.
- 3) Williams PL, Laifer-Narin SL, Ragavendra N. US of Abnormal Uterine Bleeding. *RadioGraphics* 2003; 23:703-718. Published online 10.1148/rg.233025150
- 4) Abnormal Uterine Bleeding: A Guide to Patients (Revised 2012). Publication of American Society for Reproductive Medicine.
- 5) Livingstone M and Fraiser IS. Mechanisms of Abnormal Uterine Bleeding. *Hum Reprod Update* 2002; 8(1):60-67.
- 6) Munro MG, Critchley HOD, Fraser IS. The Flexible FIGO Classification Concept for Underlying Causes of Abnormal Uterine Bleeding. *Semin Reprod Med* 2011; 29(5): DOI: <http://dx.doi.org/10.1055/s-0031-1287663>.
- 7) Committee on Practice Bulletins-Gynecology. Practice bulletin no. 128: diagnosis of abnormal uterine bleeding in reproductive-aged women. *Obstet Gynecol.* 2012;120(1):197-206. [[PubMed](#)]
- 8) Kotagasti T. Prevalence Of Different Menstrual Irregularities in Women With Abnormal Uterine Bleeding(AUB) - An Observational Study. *Int J Cur Res Rev* 2015;7(10):66-70.
- 9) Munro MG, Critchley HOD, Fraser IS. FIGO Menstrual Disorders Committee. The two FIGO systems for normal and abnormal uterine bleeding symptoms and classification of causes of abnormal uterine bleeding in the reproductive years: 2018 revisions. *Int J Gynaecol Obstet.* 2018; 143(3):393-408. [[PubMed](#)]
- 10) Talukdar B, Mahela S. Abnormal uterine bleeding in perimenopausal women: Correlation with sonographic findings and histopathological examination of hysterectomy specimens. *J Mid-life Health* 2016;7:73-7.
- 11) Harlowa SD, Campbell OMR. Epidemiology of menstrual disorders in developing countries: a systematic review. *Br J Obstet Gynaecol* 2004; 111: 6-16. DOI: 10.1046/j.1471-0528.2003.00012.x
- 12) Herman MC, Mol BW, Bongers MY. Diagnosis of heavy menstrual bleeding. *Womens Health* 2016; 12(1), 15-20

Correlation of Structural Uterine Abnormalities with Abnormal Uterine Bleeding Among Premenopausal Women with Infertility

- 13) Mahajan N, Aggarwal M, Bagga A. Health issues of menopausal women in North India. *J Midlife Health* 2012;3:84-7.
- 14) O'Connor VM. Heavy menstrual loss. Part 1: Is it really heavy loss? *Med Today* 2003;4(4):51-9.
- 15) Whitaker L, Critchley HOD. Abnormal Uterine Bleeding, *Best Practice & Research Clinical Obstetrics & Gynaecology* (2015), doi: 10.1016/j.bpobgyn.2015.11.012.
- 16) Onwuchekwa CR, Oriji VK. Hysterosalpingographic (HSG) pattern of infertility in women of reproductive age. *J Hum Reprod Sci* 2017;10:178-84.
- 17) Ryan GL, Syrop CH, Van Voorhis BJ. Role, epidemiology, and natural history of benign uterine mass lesions. *Clin Obstet Gynecol.* 2005;48(2):312-24.
- 18) Telner DE, Jakubovicz D. Approach to diagnosis and management of abnormal uterine bleeding. *Can Fam Physician* 2007;53:58-64
- 19) Vilos GA, Lefebvre G, Graves GR. Guidelines for the management of abnormal uterine bleeding. *J Obstet Gynecol Can* 2001;23(8):704-9.
- 20) Eng CW, Tang PH, Ong CL. Hysterosalpingography: Current Applications. *Singapore Med J* 2007: 368-374.
- 21) Kocaoz S, Cirpan R, Degirmencioglu AZ. The prevalence and impacts heavy menstrual bleeding on anemia, fatigue and quality of life in women of reproductive age. *Pak J Med Sci.* 2019;35(2):365-370. doi: <https://doi.org/10.12669/pjms.35.2.644>
- 22) Mascarenhas MN, Flaxman SR, Boerma T, Vanderpoel S, Stevens GA. National, regional, and global trends in infertility prevalence since 1990: A systematic analysis of 277 health surveys. *PLoS Med* 2012;9(12): e1001356. doi:10.1371/journal.pmed.1001356
- 23) Njeze NR, Ezeofor SN. Structural findings of hysterosalpingography in infertile women in Enugu, southeast Nigeria. *Int J Med Health Dev* 2020;25:96-100.
- 24) Saghir S, Kamran H, Khalid S, Sohail N, Naveed M. Determinants of Uterine Fibroids Among Married Women Attending Public Hospitals in Lahore, Pakistan. *Ajahs* 2019; 04(03): 33-37.
- 25) Siregar MFG. Association between menarche age and menstrual disorder with the incidence of uterine fibroid in Medan, Indonesia: based on hospital data. *Int J Reprod Contracept Obstet Gynecol* 2015;4:1025-8.
- 26) Udobi JI, Aguboshim FC. *A First Course in Statistics and Probability*. Enugu: E.M.C publications; 2022. pp272-279.
- 27) Spiegel MR, Schiller J, Srinivasan RA. *Schaum's Outlines of Probability and Statistics*. 3rd ed. New York. Mc Graw-Hill Companies Inc; 2009. pp265-313.