

## Multiple Brain Abscesses in A Child with Infective Endocarditis

Rimande U.Joel MBBS, MSc, FWACS, FMCR<sup>1</sup>, Rosethe Rimande-Joel RN, Dip. PON, BEd, PhD<sup>2</sup>, Eyo O. Ekpenyong MBBS, FWACS, Mni<sup>3</sup>, Charles Anjorin MBBS, FMCP, FWACP<sup>4</sup>, Peter Teru Yaru, MBBS, FMC Paed<sup>4</sup>, Millicent O. Obajimi MBBS, DMRD, FWACS, FMCR<sup>5</sup>

<sup>1</sup>Department of Radiology, Taraba State Specialist Hospital and Public Health Department Taraba State University Jalingo

<sup>2</sup>Peroperative Unit Federal Medical Centre and Health Education Department Taraba State University Jalingo

<sup>3</sup>Radiology Department Taraba State Specialist Hospital Jalingo.

<sup>4</sup>Department of Internal Medicine Federal Medical Centre Jalingo

<sup>5</sup>Radiology Department, University College Hospital and College of Medicine University of Ibadan

---

### ABSTRACT

**Background:** Infective endocarditis is a lethal infection affecting the endocardium of the heart and the valves. The causes are varied with staphylococcus aureus and streptococcus as the major causative agents. The triad of fever exceeding 38°C, vegetation in the heart and blood culture of the causative agents are the hallmarks of the diagnosis. The disease is known to affect all ages with the very young age group, those with congenital heart disease and those on cardiac prosthesis as the most vulnerable. Septic emboli from the septic vegetation can spread to the brain, kidney, spleen, and lungs resulting in massive metastatic infections. It therefore has multisystemic manifestations and complications. Though neurological complications are common, brain abscess is known to be rare constituting only 1.0% of neurological complications.

**Objective:** The study aimed at reporting occurrence of both cerebral and cerebellar micro- and macro-abscesses in a 3 year boy with infective endocarditis; a rare occurrence in the literature.

**Methods:** This case report was carried out at University College Hospital Ibadan.

**Results:** The boy presented with fever of 38°C for five weeks, convulsions and altered state of consciousness for ten days. In course of treatment patient however developed irritability and aggressive behaviour, which attracted the use of lorcetabp to which he reacted with extrapyramidal signs and convulsions. Within the week he developed yellowness of the eyes and increase in abdominal girth. Patient had cranial computed tomography (CT) after plain skull X-rays and was referred to University College Hospital Ibadan as a result of the radiologically diagnosed brain abscess seen on CT images. Child had grunting respiration with dyspnea, and the respiratory rate was 50/min. However, the chest was clinically clear. In the cardiovascular system (CVS); the pulse was 140/min, with moderate volume. The blood pressure (BP) was 160/110 mmHg. The first and second heart sounds were heard with a gallop rhythm. Cranial CT scan showed multiple ring enhancing hypodense lesions with surrounding hypodensity measuring 1cm in diameter and above with only a few measuring less than 1.0cm in both cerebral hemispheres and cerebellum in keeping with multiple cerebral and cerebellar abscesses.

An echocardiography showed a brightly echogenic spot attached to the papillary muscle in the left ventricle suggesting vegetation consistent with an infective endocarditis. Retroviral test was negative for both type I and II. Blood culture — was negative, however urine culture yielded klebsiella sp. Serum urea, creatinine, Ca<sup>2+</sup> and P<sub>04</sub> were all elevated. The abdominal ultrasound scan confirmed the hepatosplenomegaly with decreased echogenicity but both kidneys appeared normal. There was no demonstrable ascites. The boy was placed on antimicrobials; and had craniotomy for the drainage of the macroabscesses. He improved significantly. His renal and cardiac condition equally improved; he was subsequently discharged to continue treatment in the paediatric outpatient. The infective endocarditis still poses enormous challenge in management and the condition calls for multi-disciplinary approach. It requires high index of suspicion for early detection; as well deployment of multiple imaging modalities by the cardiologists and radiologists to arrive at a more accurate diagnosis for effective patient management. This may save financial and material resources on part of the patients, care givers, the facility managers and the society at large.

**KEYWORDS:** Computed Tomography(CT), Infective Endocarditis, Brain Abscess, Transthoracic echocardiography

---

## Multiple Brain Abscesses in A Child with Infective Endocarditis

### INTRODUCTION

A strict definition of infective endocarditis (I.E) could be confined to infection of the heart valves, septal defects and mural endocardium<sup>1,2</sup> Although in practice, it includes infection of the arterio-venous shunts, arterio-arterial shunts and coarctations as the clinical picture is usually indistinguishable.

Though incidence is difficult to determine as it is not a notifiable disease, global estimates of IE is put at 3-10 per 100,000 people<sup>3</sup>. IE is highly lethal disease with overall mortality remaining at about 25%<sup>3,4,5</sup> The Duke's diagnostic criteria for infective endocarditis are as follows:

“**Definite**” I.E— based on (i). pathologic criteria: a). demonstration of microorganisms by culture or histologic examination of a vegetation, a vegetation that has embolized or intracardiac abscesses specimen b) vegetations or intracardiac abscess confirmed by histologic examination showing active endocarditis. If either of a) or b) is present, diagnosis definite

(ii). Clinical criteria: 2 major or 1 major and 3 minor, or 5 minor.

a) Major clinical criteria are: 1. positive blood cultures, 2. positive echocardiogram.

Blood culture – yield of typical microorganisms consistent with IE from 2 separate blood cultures, persistently positive blood cultures, single positive blood culture for *Coxiella* or antiphase IIgG antibody titre >1:800.

Positive echocardiogram: abscess, new partial dehiscence of prosthetic valve, new valvular regurgitation .Note: Worsening or changing of pre-existing murmur NOT sufficient

b) . The minor clinical criteria are : 1. predisposition (congenital heart disease or acquired valvular disease, intravenous (I.V.) drug abusers etc), 2. fever > 38°C, 3. vascular phenomena: major arterial emboli, septic pulmonary infarcts, mycotic aneurysm, intracranial haemorrhage, conjunctival haemorrhages, and Janeway's lesions 4. Immunologic phenomena: Glomerulonephritis, Osler's nodes, Roth's spots, and rheumatic factor, 5. microbiologic evidence: positive blood culture does not meet a major criterion as earlier noted or serological evidence of active infection with organism consistent with IE<sup>6</sup>

“**Possible**” I.E-- based on findings consistent with infective endocarditis, not reaching enough criteria for definite<sup>6</sup>

Though the frequency of neurological complications (non-cardiac manifestations) of I.E is significantly high, i.e. between 25-70% occurrence of brain abscess appears to be relatively low (1-7%) and is known to have unfavourable prognosis.<sup>2,7</sup> . *Staphylococcus aureus* (*S. aureus*) is the most common causative agent of IE.<sup>2</sup>

The rarity of this condition coupled with the fact that the abscesses are predominantly macro-abscesses against frequently reported micro-abscesses ; and occurrence in a 3 year old who showed good response to medical and surgical intervention prompted the case report.

### CASE REPORT

O.A. is a 3 year-old boy, 2nd born to a family of 3 children. Mother is a 35 years-old secondary school teacher and father is a 43 years-old barrister. He presented with fever for five weeks, convulsions and altered state of consciousness for ten days. He was referred from a private clinic in Warri where he was admitted for four (4) weeks on account of fever. Fever was high-grade and intermittent. Initially patient was treated in the hospital with quinine, ampiclox, ampicillin, chloramphenicol, dexamethasone and was said to have improved after the 1st two weeks. Patient however developed irritability and aggressive behaviour, which attracted the use of largactil to which he reacted with extrapyramidal signs and convulsions. No associated ear pain/discharges or cough. Within the week he developed yellowness of the eyes and increase in abdominal girth. Patient had cranial computed tomography (CT) after plain skull X-rays and was referred to University College Hospital Ibadan as a result of the radiologically diagnosed brain abscess seen on CT images. Patient was not a known sickler, and had no previous history of hand and foot syndrome.

On examination, the boy was undernourished, ill-looking, febrile, with a temperature of 38°C. Patient was also anicteric with hyperpigmentation of both limbs, trunk and eyelids. Mild periorbital oedema was also seen.

The child had grunting respiration with dyspnea, and the respiratory rate was 50/mm. However the chest was clinically clear. In the cardiovascular system (CVS); the pulse was 140/mm, with moderate volume. The blood pressure (BP) was 160/110 mmHg. The first and second heart sounds were heard with a gallop rhythm. In the central nervous system (CNS); patient was conscious but lethargic with paucity of movement in the four limbs. There was reduced power of 3/5 and 2/5 in the left upper and lower limbs respectively and 1/5 in the right limbs. The deep tendon reflexes were exaggerated in all the limbs with hypertonia in the lower limbs. Clonus was present but not sustained. Plantar response was extensor.

Abdominal examination showed smooth, enlarged liver, that was soft and tender. The spleen was enlarged but no ascitis.

Fundoscopy was essentially normal in both eyes. The differential diagnoses were: 1. Acute encephalopathy with septicaemia and an intracranial space occupying lesion most likely an abscess. 2. Heart failure with hypertension.

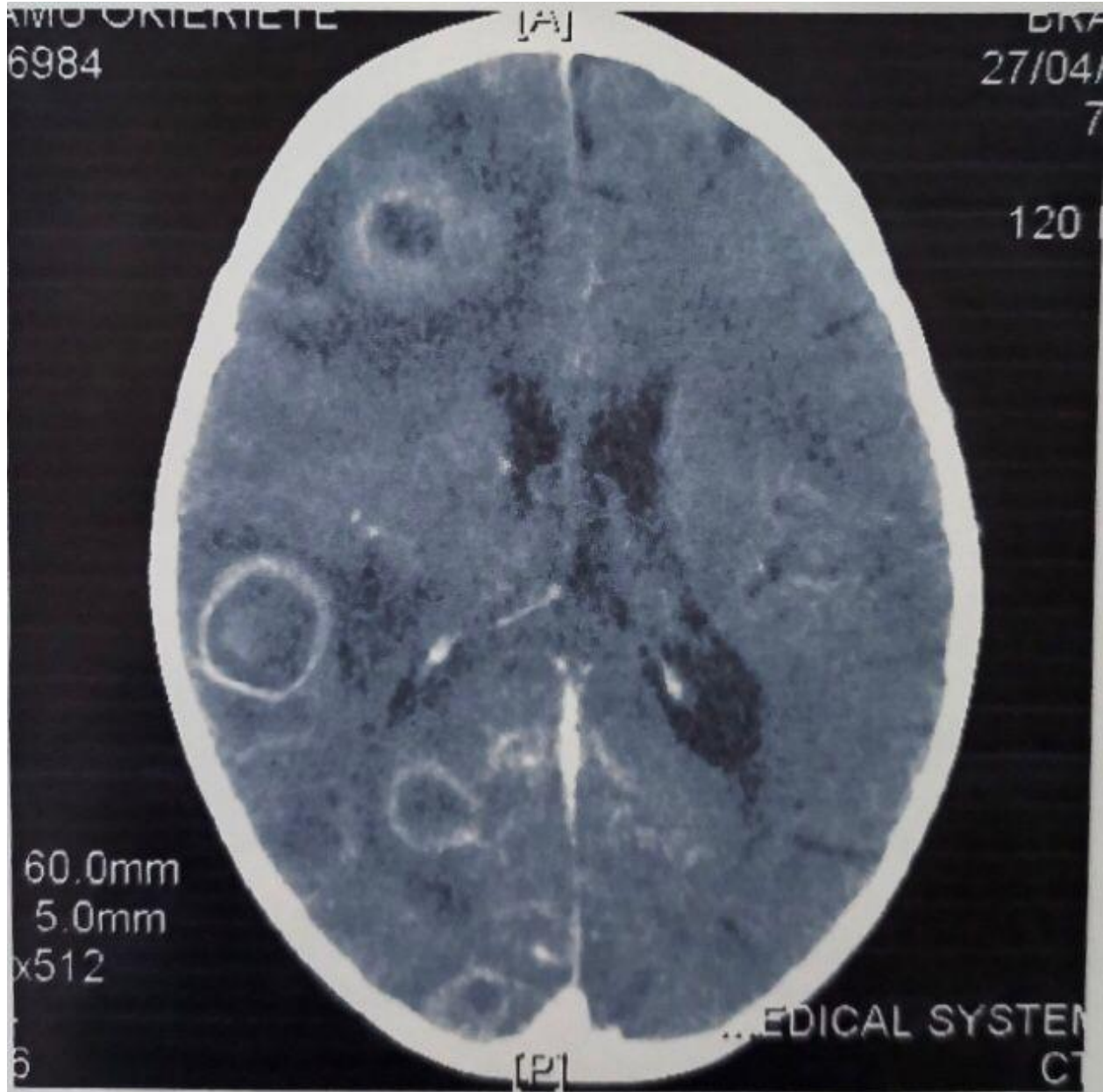The cranial CT scan done in the department showed multiple ring enhancing hypodense lesions with surrounding hypodensity. The larger ones measured up to 1cm in diameter and above in both cerebral hemispheres and cerebelli in keeping with multiple cerebral and cerebellar abscesses.

## Multiple Brain Abscesses in A Child with Infective Endocarditis

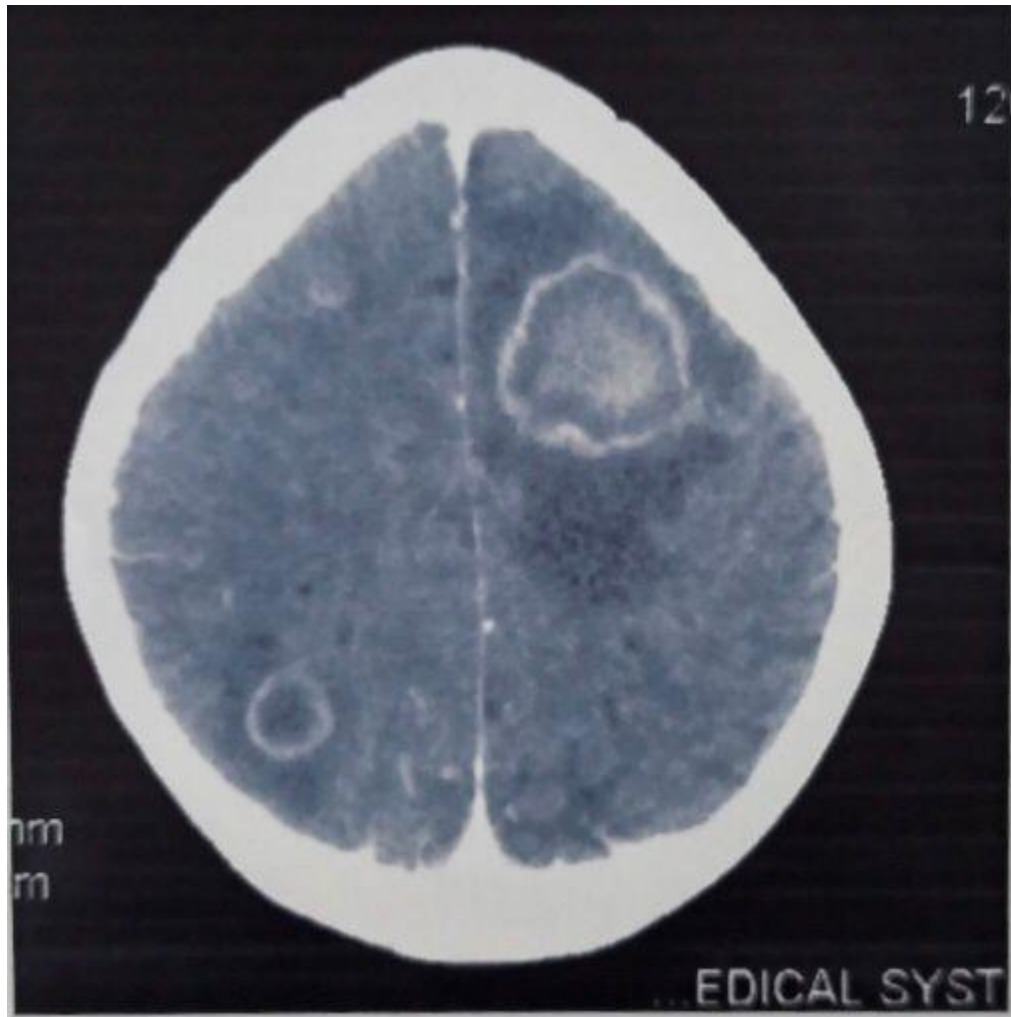
An echocardiography done on the child showed a brightly echogenic spot attached to the papillary muscle in the left ventricle suggesting vegetation consistent with an infective endocarditis. Retroviral test was negative for both type I and II.

Blood culture — was negative, however urine culture yielded klebsiella sp. Serum urea and creatinine showed elevation, creatinine - 4.1mg/dl and urea- 197mg/dl. Ca and P04 were also elevated.

The abdominal ultrasound scan confirmed the hepatosplenomegaly with decreased echogenicity. The spleen in addition showed multiple focal echogenic areas. Both kidneys were within normal limits. There was no demonstrable ascitis.

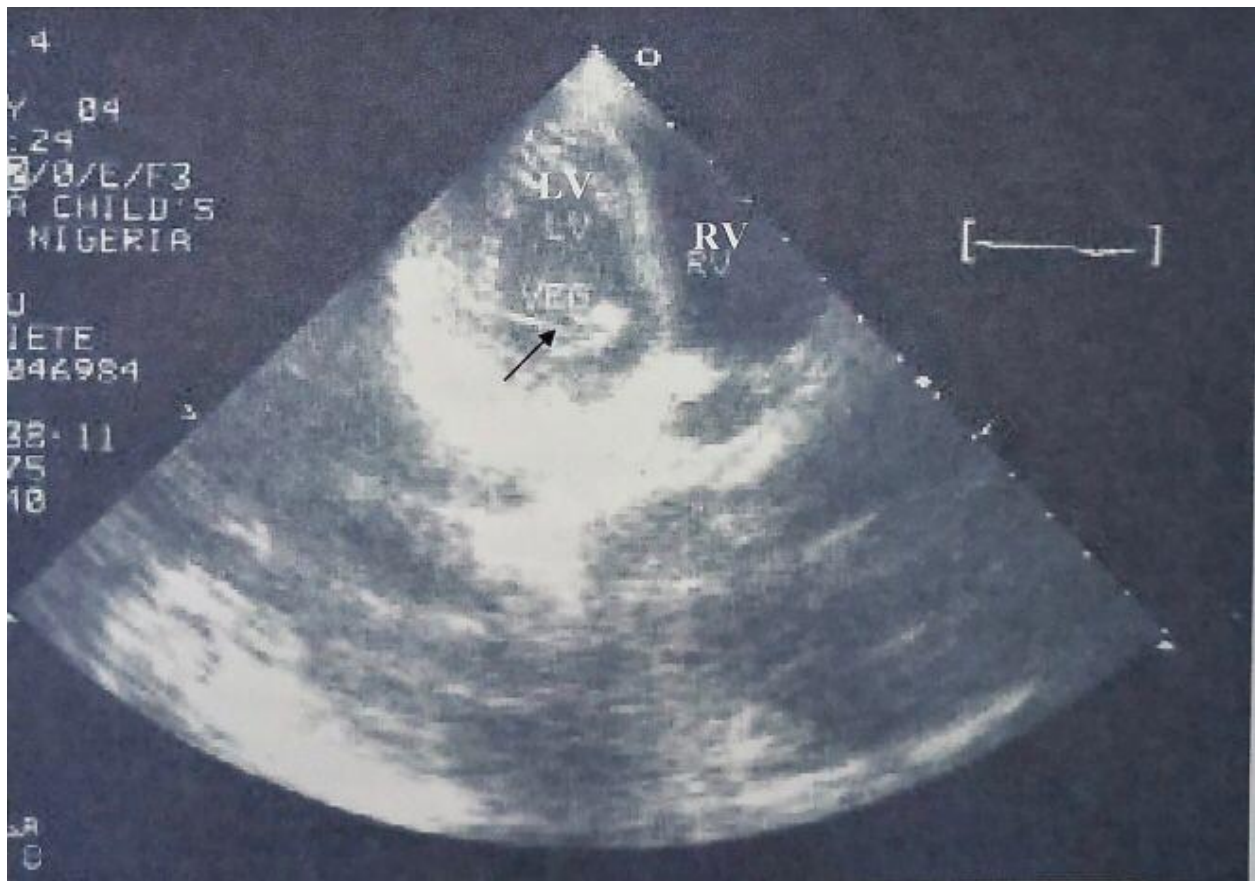


**Fig 1: An axial slice of cranial computed tomogram showing multiple micro and macro abscesses in both the grey and white matter of the brain.**



**FIG 2: An axial slice of cranial compound tomogram showing the micro and macro abscesses higher up in the cerebral hemisphere.**

## Multiple Brain Abscesses in A Child with Infective Endocarditis



**FIG 3:** A two dimensional echocardiogram showing echogenic lesion on the papillary muscle in the left ventricle arrow (↓).

### DISCUSSION

Osler in 1885<sup>8</sup> was the first person to recognise the significance of nervous system involvement in IE. He noted a clinical triad of fever, heart murmur, and hemiplegia. Since then several studies<sup>2,7,9</sup> have been carried out on the neurologic complications of infective endocarditis.

The presence of fever of 38°C lasting for more than four weeks, gallop rhythm (3rd heart sound) presumably due to heart failure, splenomegaly and vegetation in the chordae tendinae of the mitral valve on echocardiography all established the diagnosis of definite infective endocarditis and agreed with diagnostic criteria in the literature<sup>3,6,10</sup>

The term native valve endocarditis is used if IE occurs in native valve, and prosthetic valve IE if it occurs in prosthetic valve. Both have different approach to their treatment as the latter apart from having different set of antimicrobials may require surgical replacement of the prosthesis.<sup>11</sup> Our case is 3 year old boy with no history of congenital heart disease or valve replacement. His case qualifies for native IE.

Septic emboli from the septic vegetation can spread to the brain, kidney, spleen, and lungs resulting in massive metastatic infections.<sup>2</sup>

The findings of cardiac failure and acute renal failure in this case report are also compatible with complications of endocarditis already observed in the literature<sup>1,6,12</sup>. However, the absence of cardiac murmur and the markedly elevated blood pressure raised the question as to whether the heart failure was as a result of the renal complication or intracranial hypertension from the multiple macroabscesses (space occupying lesions) instead of a defective mitral valve.

The absence of positive blood culture in the presence of vegetation also agrees with reports by Jiang<sup>13</sup>, Ebato<sup>14</sup> and Sheibani and associates<sup>15</sup>. The negative blood culture in this case report could be due to the administration of several antimicrobials in the referring hospital. A more detailed echocardiographic study using the trans-oesophageal route could have revealed more as it is known to be more sensitive than the transthoracic route in diagnosis of I.E. and I.E-associated complications<sup>16</sup> but the hospital was yet to acquire this trans-oesophageal transducer at the time of the case.

Neurologic complications were defined on the basis of symptoms/signs, cranial:tomographic findings and cerebrospinal fluid (CSF) abnormalities. Based on above, three broad groups were identified by Le Cam et al<sup>17</sup>

1. Cerebrovascular (stroke and mycotic aneurysm). ii. Infections (meningitis and brain abscess) and iii. Non specific (encephalopathy, headache and seizure).

## Multiple Brain Abscesses in A Child with Infective Endocarditis

Encephalopathy was defined as mental status changes or stupor without focal neurological signs, systematic metabolic derangement, medication toxicity, or CT and CSF abnormalities. Mycotic aneurysms were considered definite when verified at angiography, and presumptive when intracranial haemorrhage occurred without a demonstrable aneurysm. Brain abscesses were divided into microscopic- less than 1cm and macroscopic > 1cm in diameter.

The recognition of cerebrovascular events (cerebral embolism and intra-cerebral haemorrhage) as the most frequent neurologic complication of IE have been widely reported by many authors; some of whom have similarly observed that brain abscess had low frequency of occurrence in their studies.<sup>2,7,9,18</sup>

Kim et al<sup>19</sup> described in detail the spectrum of cranial CT or MRI findings. They observed that tiny enhancing lesions in the white matter seemed to be valuable features which could be used to differentiate the neurological complications of I.E. from other thrombo-embolic infarcts. Similar findings were reported by Baskshi et al<sup>20</sup> who found that cortical branch infarction was quite frequent and occurred in the territory of the distal middle cerebral artery, and numerous enhancing micro abscesses in the grey-white matter junction. Frank parenchymal macroabscess/ cerebritis lesions, (>1cm in diameter) were also noted in that study.

The use of modern imaging modalities like helical CT and MRI with use of contrast no doubt have contributed to the detection of small, lesions which otherwise would not have been detected. MRI is more sensitive in IE-associated neurologic lesions<sup>20</sup>. MRI has four patterns of neurologic presentation in IE: (1) embolic infarctions, (2) multiple patch infarctions, (3) hemorrhagic infarctions, and (4) small nodular or ring enhancing white matter lesions<sup>19</sup>. Though at time of this case report the Hospital was yet to acquire a helical CT or MRI.

This case report had multiple macro- and microabscesses of diameter > 1cm and <1cm respectively numbering over ten located in both the cerebral cortex and corticomedullary junction bilaterally (Figs 1 and 2). They showed little mass effect and their characteristic ring enhancement swayed diagnosis in their favour. The management of brain abscess is essentially with the use of intensive antimicrobials in those with microabscesses whereas those with macroabscesses benefit from surgical drainage in addition to antimicrobial therapy<sup>2,18</sup>. In this case report surgical intervention was done to drain the macro abscesses in addition to antimicrobials. He made steady progress with resolution of his renal complications and cardiovascular changes. The BP returned to normal and he was discharged for follow up at the paediatric outpatient.

### CONCLUSION

A 3-year-old boy with prolonged fever, neurological and other symptoms and was diagnosed with multiple intracranial abscesses secondary to infective endocarditis is presented. The patient had complications cardiovascular, neurological and renal complications which resolved completely on antimicrobials treatment as well as surgical drainage of some of the macroabscesses. There is need for high index of suspicion by attending physicians and for echocardiography to pick up the cardiac signs early as patients may not show cardiological symptoms. The need for early cranial CT/MRI is also imperative to rule out intracranial neurological complications in patients with of IE. Multidisciplinary approach is also recommended for more effective patient management. This will save the time and cost of treatment to the patient, care givers as well as the community at large.

### Compliance with ethical standards

#### Acknowledgement

The authors acknowledge the management of the University College Hospital Ibadan for the moral support and conducive atmosphere provided for the study.

#### Disclosure of conflict of interest

No conflict of interest to be disclosed.

#### Statement of ethical approval

The study involves use of human subject, but being a case report, obtaining ethical clearance was not applicable.

#### Statement of informed consent

Informed consent was obtained from participants included in the study

### REFERENCES

- 1) Freeman R. and Hall R. Infective Endocarditis In: Julian DG, Camm AJ, Fox KM, Hall RJC, Poole-Wilson PA (Ed) (1989). Disease of the Heart. I Edition. London: Bailliere Tindall pp 853-876.
- 2) Taj S, Arshad M U, Khan H, Sidhu G S, and Singh R (2021) Infective Endocarditis Leading to Intracranial Abscess: A Case Report and Literature Review. *Cureus*. 13(1): e12660. doi: 10.7759/cureus.12660
- 3) Nishimura RA, Otto CM, Bonow RO, Carabello BA, Erwin JP 3rd, Guyton RA, et al.. American College of Cardiology/American Heart Association Task Force on Practice. (2014) AHA/ACC guideline for the management of patients with valvular heart disease: a report of the American College of Cardiology/American Heart Association Task Force on Practice Guidelines. *J Am Coll Cardiol*. 63:e57-185. 10.1161/CIR.0000000000000031

## Multiple Brain Abscesses in A Child with Infective Endocarditis

- 4) Ambrosioni J, Hernandez-Meneses M, Tellez A, Pericas J, Falces C, Tolosana JM, et al.. Hospital Clinic Infective Endocarditis Investigators. The changing epidemiology of infective endocarditis in the twenty-first century. *Curr Infect Dis Rep.* (2017) 19:21. 10.1007/s11908-017-0574-9
- 5) Chen H, Zhan Y, Zhang K, Gao Y, Chen L, Zhan J, Chen Z, and Zeng Z (2022) The Global, Regional, and National Burden and Trends of Infective Endocarditis From 1990 to 2019: Results From the Global Burden of Disease Study 2019 *Front Med (Lausanne)* 9: 774224. doi: 10.3389/fmed.2022.774224
- 6) Durack, D.T (2023) Duke Criteria for Infective Endocarditis. Diagnostic criteria for endocarditis. <https://www.mdcalc.com/calc/1731/duke-criteria-infective-endocarditis>
- 7) Morris N.A., Matiello M., Lyons J.L, Samuels M.A..(2014) Neurologic complications in infective endocarditis. *Neurohospitalist.* 2014;4:213–222.
- 8) Osler W. (1885) Guistonian lectures on malignant endocarditis. *Lancet.* 415: 459-465.
- 9) Boukobza, M., Ilic-Habensus, E., Mourvillier, B., Duval X, & Laissy, J.P. (2023) Brain abscesses in infective endocarditis: contemporary profile and neuroradiological findings. *Infection* . <https://doi.org/10.1007/s15010-023-02008-9>
- 10) Wang A, Gaca JG, Chu VH. (2018) Management considerations in infective endocarditis: a review. *JAMA.* 320:72–83. 10.1001/jama.2018.7596
- 11) Wang A, Holland MT (2023) Overview of management of infective endocarditis in adults. <https://www.uptodate.com>
- 12) Harris PS, Cobbs CG. (1996) Cardiac, cerebral, and vascular complications of infective endocarditis. *Cardiol. Clin* 14: 437-450.
- 13) Jiang C, Lu H, Guo Y, Zhu L, Luo T, Zhai W, and Wang J (2018) Blood Culture-Negative but Clinically Diagnosed Infective Endocarditis Complicated by Intracranial Mycotic Aneurysm, Brain Abscess, and Posterior Tibial Artery Pseudoaneurysm. *Case Report. Neurol Med.* : 1236502 doi: 10.1155/2018/12365021)
- 14) Ebato, M (2018) Negative Endocarditis. *IntechOpen* DOI: 10.5772/intechopen.76767
- 15) Sheibani H, Salari M, Azmoodeh E, Kheirieh A, and Chaghazardi S. (2020) Culture-negative endocarditis with neurologic presentations and dramatic response to heparin: a case report. *BMC Infect Dis.* 20: 476. . doi: 10.1186/s12879-020-05206-0
- 16) Kemp WF, Jr, Citrin B, Byrd BF (1999). Echocardiography in infective endocarditis. *South Med. J.*; 92: 744-54.
- 17) Le Cam B, Guiworch G, Boles JM, Gaffe M, Cartier F. (1984) Neurologic complications in a group of 86 bacterial endocarditis patients. *Eur. Heart J.* 5: 97-100.
- 18) Daoud H, Abugroun A, Olanipekun O, Garrison D. (2019) Infective endocarditis and brain abscess secondary to *Aggregatibacter aphrophilus*. *Case Report.* open access. <https://doi.org/10.1016/j.idcr.2019.e00561> Get rights and content
- 19) Kim Si, Lee JY, Kim TH, Kim Sc, Choi YH, Pai H, Choice WS. (1998). Imaging of the neurological complications of infective endocarditis. *Neurorad* 40:109-13.
- 20) Bakshi R, Wright PD, Kinkel PR, Bates VE, Mechtter LL, Kamran S, Pullicino PM, Sirotkin I, Kinkel WR. (1999) *J Neuro imaging.*; 9: 78-84.