

SHORT REPORT

Early Experience with the New Ovation Alto Stent Graft in Endovascular Abdominal Aortic Aneurysm Repair

Gianmarco de Donato^{*}, Edoardo Pasqui, Claudia Panzano, Giuseppe Galzerano, Alessandro Cappelli, Giancarlo Palasciano

Department of Medicine, Surgery, and Neuroscience, Vascular Surgery Unit, University of Siena, Italy

Introduction: Since 2010, the Ovation Abdominal Stent Graft System has offered a new sealing concept, achieved by a sealing ring filled with polymer 13 mm from the renal arteries. In the latest version, called Ovation Alto, the sealing ring is relocated 6 mm closer to the top of the fabric. This study describes the early clinical outcomes, after CE Mark approval in August 2020, of endovascular aneurysm repair with the Alto endograft.

Report: Eleven patients underwent endovascular aneurysm repair with implantation of Ovation Alto endografts. All patients were male, and the median age was 75 (IQR 5.5) years. Hostile proximal aortic neck (<10 mm) was identified in six cases (54.5%). All procedures were performed using bilateral percutaneous approaches with no groin complications. The median procedure time was 58 (IQR 7.2) minutes, the median contrast volume used was 65 (IQR 4.2) mL, and the median blood loss 40 (IQR 12.4) mL. Technical success was achieved in all cases. The median stent graft landing distance between the top of the fabric and the lowest renal artery was 1.4 (IQR 0.8) mm. No intra-operative high flow endoleaks were registered. At one and six month follow up, there was 100% clinical success (no type I/III endoleak, sac enlargement, stent graft migration, polymer leakage, abdominal aortic aneurysm related mortality, or secondary intervention).

Discussion: Initial experience confirms the early technical and clinical success of the new Ovation Alto stent graft. Technical modifications to the endograft could allow for accommodation of a more comprehensive range of anatomies on label. Further studies are needed to evaluate long term durability outcomes.

© 2021 The Authors. Published by Elsevier Ltd on behalf of European Society for Vascular Surgery. This is an open access article under the CC BY-NC-ND license (<http://creativecommons.org/licenses/by-nc-nd/4.0/>).

Article history: Received 4 April 2021, Revised 21 October 2021, Accepted 22 November 2021,

Keywords: Aortic aneurysm, Endovascular, EVAR, O-ring, Polymer based stent graft

INTRODUCTION

Endovascular aneurysm repair (EVAR) has become an effective treatment of abdominal aortic aneurysm (AAA) in challenging anatomy such as hostile neck and narrow access. Such treatment has been achieved thanks to continuous technological development to overcome the previous limitation in EVAR applicability. Since 2010, the Ovation Abdominal Stent Graft System (Endologix Inc. Irvine, CA, USA) has offered a new sealing concept, achieved by a network of O rings filled with a polymer, that can treat a great variety of difficult anatomies through a low profile platform.^{1,2} In the latest version of the stent graft, called Ovation Alto, the conformable O rings with polyethylene glycol (PEG) polymer have been repositioned nearer the top of the endograft, providing a seal just below the renal arteries (optimally 7 mm below the lowest renal artery).

This study describes the early clinical outcomes of the initial experience with the Ovation Alto stent graft, which represents evolution of the low profile Ovation Prime and iX endograft (Fig. 1). The ring network is still filled by a low viscosity radiopaque polymer intra-operatively but is now injected at a lower pressure than before (0.8 ATM in Alto endograft vs. 1 ATM in previous versions). The iliac limbs have not changed.

The new feature of the Ovation Alto is relocation of the proximal sealing ring 7 mm from the main body fabric's proximal edge. In previous versions, this distance was 13 mm. The low permeability graft material and the suprarenal 35 mm freeflow stent remain unchanged. It is still delivered via a flexible, hydrophilic coated, low profile delivery system (15 Fr outer diameter for all main body measures).

Another design modification is represented by integration of a compliant balloon fixed to the delivery system. The balloon is highlighted by a proximal radiopaque marker that coincides with the first sealing ring location. Deployment of the device is performed with a two time manoeuvre. Endograft sealing and fixation are maintained separately as before (Fig. 2). Initially, the lower part of the uncovered stent and the endograft module are deployed and expanded with the integrated, compliant balloon. The upper part of the bare stent remains temporarily undeployed. This system

^{*} Corresponding author. Department of Medicine, Surgery, and Neuroscience, Vascular Surgery Unit, University of Siena, Italy.

E-mail address: dedonato@unisi.it (Gianmarco de Donato).

2666-688X/© 2021 The Authors. Published by Elsevier Ltd on behalf of European Society for Vascular Surgery. This is an open access article under the CC BY-NC-ND license (<http://creativecommons.org/licenses/by-nc-nd/4.0/>).

<https://doi.org/10.1016/j.ejvsf.2021.11.003>

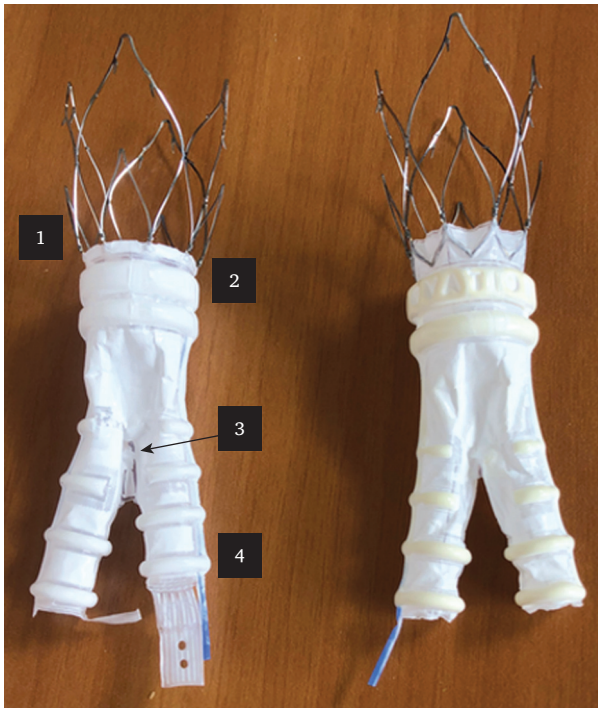


Figure 1. Comparison between Ovation Alto endograft (left) and Ovation iX (right) endograft. 1, Shorter mid-crown segment of proximal fixation stent. 2, Sealing ring centre 7 mm from the fabric edge. 3, Lengthier webbing at graft bifurcation. 4, Longer contralateral limb.

allows repositioning of the endograft before final deployment. After full stent graft positioning and polymer injection, the whole delivery system with the integrated balloon is advanced by 5–7 mm to correctly align the balloon to the area that is being moulded; any minimal deformation that may occur is considered acceptable.

Other minor modifications of the Ovation Alto design include: 1) the inner diameter of the docking limb has been increased to 11 mm for all main body sizes, the previous 9 mm docking limb for endograft main body from 20 to 26 mm added some cannulation challenges; 2) a larger polymer web bridging the main body “crotch” connects both limbs and prevents excess limb movement, especially in the contralateral limb; 3) the aortic body contralateral limbs were offset by five mm to improve their identification during the procedure.

METHODS

Study population

From November 2020 to January 2021 a total of 31 patients received endovascular repair of an infrarenal AAA. Eleven were selected for Ovation Alto implantation for one or more of the following reasons: short neck (<10 mm), narrow iliac access (<6 mm), and operator preference.

All EVAR procedures were performed by a vascular team of surgeons with considerable EVAR experience with previous Ovation endograft (>200 procedures).

Patient demographics, intra-operative data, and post-operative outcomes were collected prospectively from hospital charts. Hypertension, diabetes mellitus, dyslipidaemia, smoking history (any current or past regular use of tobacco), coronary artery disease, congestive heart failure, atrial fibrillation, chronic obstructive pulmonary disease, and renal disease (chronic renal insufficiency defined by serum creatinine >1.2 mg/dL), were taken into account as comorbidities.

Patients included in this study gave consent to participate in this case series and publication, and the local ethical committee was informed of the study’s non-experimental nature.

Outcomes

Technical success for EVAR cases was defined as successful endograft deployment with secure fixation and patency, and absence of type I or III endoleaks within the first 24 hours.

Clinical success was defined as successful deployment of the endovascular device at the intended location without death as a result of aneurysm related treatment, type I or type III endoleaks, graft infection or thrombosis, aneurysm expansion (diameter >5 mm or volume >5%), aneurysm rupture, or conversion to open repair (OR).

Post-operative renal deterioration was evaluated: blood sampling with serum creatinine measurement was repeated on the first and second post-operative days. Contrast induced nephropathy (CIN) was defined as a serum creatinine rise of >25% or >0.5 mg/dL (44 mmol/L) from baseline within 48 hours.

Endoleaks, graft patency, and graft migration were detected with duplex ultrasound (DUS) and/or CTA examination following the scheduled follow up programme. The post-operative follow up protocol included DUS examination at one, three, and six months, and annually thereafter, while CTA was performed one month after the index procedure or in the case of suspected findings at DUS examination.

For analysis of endoleaks, an event was considered as present from the first time that it was detected. Graft migration was defined by distal displacement of the stent graft of ≥ 10 mm. Graft patency was also evaluated by DUS and/or CTA examination.

Residual aneurysm sac shrinkage was defined as a decrease in the maximum sac diameter measured with both CTA and DUS, with respect to the maximum pre-operative sac diameter.

Secondary interventions performed to fix or to avoid a potential complication included endovascular procedures (proximal cuff and stent implantation, distal extension implantation, catheter based thrombolysis, iliac angioplasty, coil or glue embolisation of aortic branch vessels) and surgical intervention (balloon thrombectomy, femorofemoral bypass, conversion to OR, open or laparoscopic ligation of collaterals).

Statistical analysis

A descriptive analysis of variables was performed. Median and interquartile range were used to analyse continuous

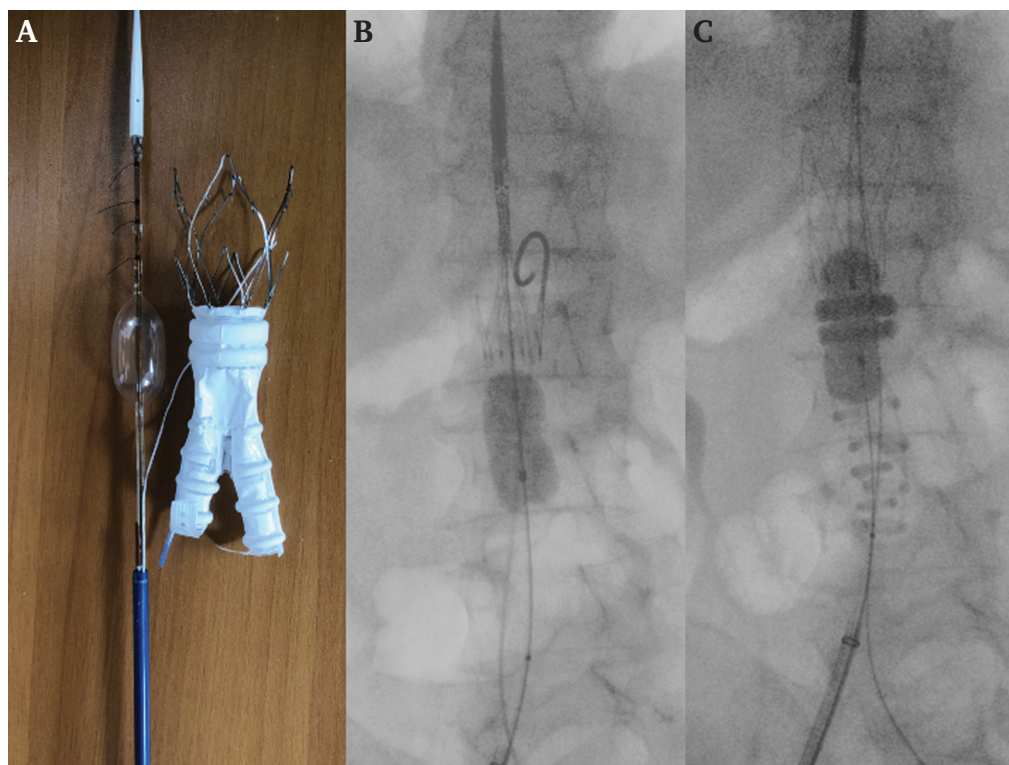


Figure 2. (A) Ovation Alto endograft model with the incorporated compliant balloon inflated. (B) Intra-operative fluoroscopy with Ovation Alto semi-deployed with the incorporated balloon partially inflated. (C) Intra-operative fluoroscopy with Ovation Alto endograft main body deployed, with O rings polymer filled. The incorporated balloon is advanced 5–7 mm and fully inflated.

variables. Categorical variables were indicated as percentages.

Changes in patients' renal function were determined comparing post-operative with pre-operative serum creatinine levels. The creatinine difference was indicated as a percentage comparing pre-operative and the 48 hour post-operative creatinine levels.

RESULTS

Initial experience with implantation of Ovation Alto endografts consisted of 11 consecutive patients from November 2020 to January 2021. All patients were male, and the median age was 75 (IQR 5.5). Full baseline characteristics are shown in Table 1. Anatomical case features and intra-operative data are listed in Table 2.

Four patients (36.4%) presented with standard anatomy that fulfilled the IFU for other stent grafts. Alto was implanted according to operator preference.

Seven patients (63.6%) had complex anatomy that was judged eligible only for Ovation Alto (neck <10 mm $n = 6$; iliac access <6 mm $n = 7$; short neck and small access $n = 5$). Notably, three of the patients eligible for Alto would not have satisfied the IFU for Ovation iX (diameter of proximal neck 13 mm below the renals ≥ 31 mm).

Technical success was achieved in all cases. No intra-operative high flow endoleaks were registered. No intra-procedural polymer leakage occurred. All procedures were performed using bilateral percutaneous approaches with no

groin complications. The median procedure time was 58 (IQR 7.2) minutes, the median contrast volume was 65 (IQR 4.2) mL, and the median blood loss 40 (IQR 12.4) mL. No CIN was registered. The serum creatinine level remained stable in five patients (<5%), while the remaining six patients had a median increase of post-operative creatinine level of only 13.6%. All patients were discharged uneventfully on the second post-operative day, as the minimum in hospital stay required for full reimbursement from the National Health System.

Table 1. Baseline demographics.

	All patients ($n = 11$)
Male ($n, \%$)	11 (100)
Age (median; IQR)	75 (5.5)
Hypertension ($n, \%$)	7 (63.6)
Diabetes Mellitus ($n, \%$)	2 (18.2)
COPD ($n, \%$)	1 (9.1)
Coronary Artery Disease ($n, \%$)	3 (27.3)
Atrial Fibrillation ($n, \%$)	1 (9.1)
Congestive heart failure ($n, \%$)	2 (18.2)
Chronic renal insufficiency ($n, \%$)	3 (27.3)
Dyslipidaemia ($n, \%$)	7 (63.6)
Smoke ($n, \%$)	6 (54.5)
Current smoker	2 (18.2)
Former smoker	4 (36.4)
Hostile abdomen ($n, \%$)	3 (27.3)

IQR = interquartile range; COPD = chronic obstructive pulmonary disease.

Table 2. Baseline anatomical features of the 11 patients treated with Ovation Alto endograft.

AAA characteristics and evolution	AAA diameter – mm	AN length – mm	IR 0 – mm	IR 7 – mm	IR 10 – mm	IR 13 – mm	AN features		Circumferential thrombus – mm	Circumferential thrombus – %	Circumferential calcification – %	Small iliac access (<6 mm) (right and left)		Iliac Tortuosity Index >1.5 (right and left)	
							Thrombus thickness	mm				R	L	R	L
1 Fusiform	55	18	24.1	23.3	23.4	24.3	3	15	10	+	+	-	-		
2 Saccular	52	14	25.7	26.0	26.3	26.5	0	0	10	-	-	+	-		
3 Fusiform	56	13	24.2	25.1	24.7	24.8	4	15	0	+	+	-	-		
4 Fusiform, rapid AAA enlargement	53	8	20.4	20.8	23.6	31.3	7	18	25	-	-	+	-		
5 Fusiform, rapid AAA enlargement	54	17	25	25.7	26	26.2	5	24	30	-	-	-	-		
6 Fusiform	61	10	21.2	21.0	24.5	27.0	4	10	10	+	+	+	-		
7 Fusiform	90	9	25.4	26.1	30.8	35.1	4	5	10	-	+	-	+		
8 Fusiform	62	7	27.0	28.3	32.0	36.5	6	15	30	-	-	-	+		
9 Saccular	54	11	24.3	24.5	25.0	25.3	3	10	15	-	+	-	-		
10 Fusiform	56	9	25.1	25.2	25.6	25.7	3	15	35	-	+	+	+		
11 Fusiform	61	10	26.2	27.1	29.1	29.6	7	36	10	-	-	+	-		

AAA = abdominal aortic aneurysm; AN = aortic neck; IR = infrarenal.

All 11 patients fulfilled one month follow up with duplex ultrasound and CTA (Fig. 3). The median stent graft landing distance from the lowest renal artery was 1.4 ± 0.8 mm (extrapolated from the first follow up CTA). Neither stent graft migration nor neck enlargement was observed. Sac shrinkage was registered in five (45.5%) patients (>3 mm), but the sac size was stable in the remaining six (54.5%) patients. There was one type II endoleak. No type I and III endoleaks were highlighted, and no re-interventions were needed.

All patients completed the six month follow up evaluation with DUS. No endoleak was detected, and there was resolution of the previous type II endoleak. No cases of sac enlargement were recorded. Clinical success at six months was 100%.

DISCUSSION

Since its appearance on the market in 2010, the Ovation endograft has offered an innovative sealing concept by non-expansive circumferential apposition of inflatable rings filled with a low viscosity polymer.³ The polymer filled system adapts to the patients' aortic neck determining a continuous, customised concentric seal that allows greater on label patient eligibility than that of other stent grafts.⁴

The Ovation Alto Stent Graft System received FDA approval on 16 March 2020. The United States commercial launch of the device was announced on 30 July. On 5 August, Endologix received CE Mark approval in the European Union for EVAR. In Italy, the commercial launch was in November 2020, in centres with a large experience with the Ovation Prime and iX.

The present authors' experience with 11 consecutive patients with standard or complex anatomical features confirms the early safety and efficacy of Ovation Alto implantation. The new sealing zone is closer to the renal arteries and may offer sealing in aneurysms with irregular <10 mm long neck. The present authors have already described the possibility of treating juxtarenal aortic aneurysms unfit for open surgery and fenestrated/branched EVAR by physician modified implantation of Ovation iX, called a "vent" technique,⁵ which offered a preliminary evaluation of how the polymer ring might behave close to the renal ostium as now adopted by the new design of the Ovation Alto. The use of Alto inside the IFU allows treatment of patients with proximal necks <10 mm who are not eligible for standard EVAR and would be treated with adjunctive fixation options (Heli-FX endoanchors, Medtronic Vascular, Santa Rosa, CA, USA) or by FEVAR. Future research would be worthwhile to analyse the cost effectiveness of Alto vs. FEVAR in patients with short necks.

In this early experience with Alto both standard cases eligible for other stent grafts (36.4%) and complex cases with short neck or small access (63.6%) were treated. In particular, three patients were included who would not have been eligible for Ovation iX (diameter at IR, infrarenal $13 > 30$ mm), demonstrating that Alto may increase the range of on label anatomies.

Inaccurate deployment of the sealing ring with the previous Ovation version has been described as responsible for

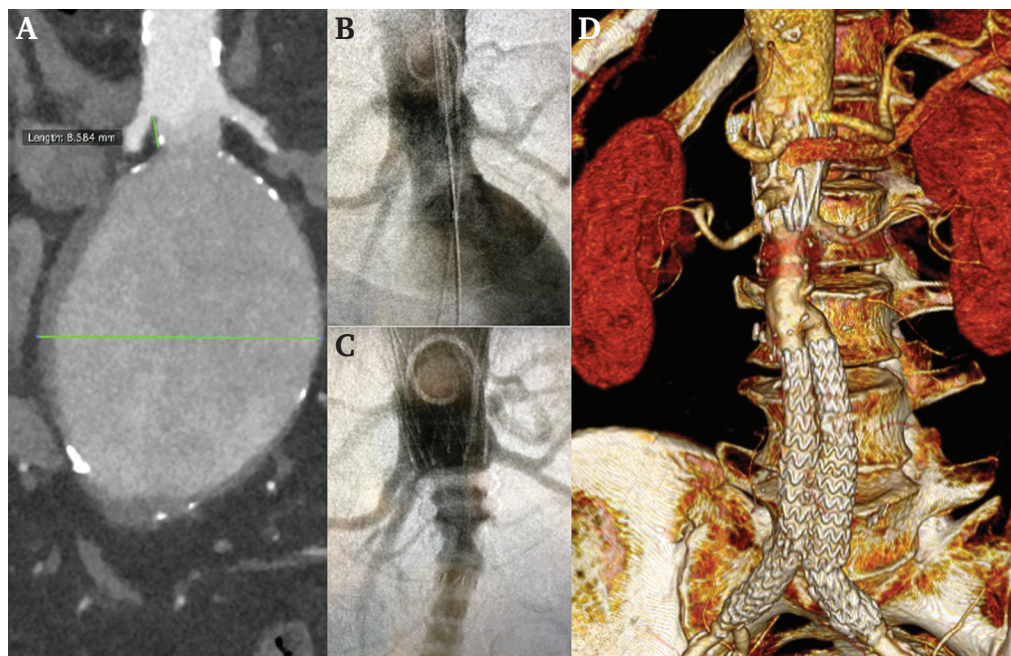


Figure 3. Endovascular aneurysm repair with the Ovation Alto endograft. (A) Computed tomography angiography (CTA) scan of a 9 cm AAA with hostile proximal neck and highly calcified bilateral iliac access. (B) Intra-operative fluoroscopy highlighting the complex aortic neck. (C) Final angiogram revealing the accurate deployment of Ovation Alto endograft, good patency of renal arteries, and no high flow endoleak. (D) 3D volume rendering of one month CTA follow up shows the correct exclusion of the aneurysm sac with good proximal sealing.

an early technical failure.⁶ The present authors' feedback is that the incorporated compliant balloon in the new version with markers that intuitively identify the first ring's landing, makes the deployment more precise.

Although no cases of polymer leakage occurred in this experience with Alto, such a complication has been reported only rarely with Ovation iX (0.26%). Hypothetical reasons include polymer line disconnection secondary to incorrect device manipulations during the procedure (excessive twisting of the delivery shaft), early ballooning before complete polymer cure, lower body temperature which can slow the polymer cure rate, or manufacturing issues (polymer network hole).⁷ It will be important to collect these data on future prospective Alto dedicated registries.

Although the profile of the Ovation Alto has slightly increased (from 14Fr to 15Fr for 20/23/26 mm main body sizes), trackability has not changed and still achieves small iliac access (<6 mm), with the possibility of performing percutaneous procedures, as highlighted by the present case series, leading to reduced blood loss, groin complications, and earlier discharge.

Good five year EVAR results with the Ovation platform have been reported, demonstrating excellent long term durability of this endograft despite 41% of patients having anatomy unsuitable for other stent grafts.⁸

Holden et al. demonstrated promising results in the first in human experience with the Ovation Alto.⁹ At the moment, only the early outcomes from the series of seven patients have been published, with five year results from

the Expanding Patient Applicability with Polymer Sealing Ovation Alto Stent Graft (ELEVATE) clinical trial awaited in 2023.

Conclusion

This initial experience confirms that the new Ovation Alto stent graft offers acceptable early technical and clinical success rates. Technical improvements may allow the stent graft to accommodate a more comprehensive range of anatomies on label, with modified deployment of the sealing ring. Further studies and national prospective registries are needed to evaluate long term durability outcomes.

CONFLICTS OF INTEREST

GdD is a consultant for Endologix and receives speaker fees and travel grants.

FUNDING

None.

REFERENCES

- 1 de Donato G, Setacci F, Sirignano P, Galzerano G, Borrelli MP, di Marzo L, et al. Ultra-low profile Ovation device: is it the definitive solution for EVAR? *J Cardiovasc Surg (Torino)* 2014;**55**:33–40.
- 2 Morgan-Bates K, Chaudhuri A. Use of the Ovation endograft system to treat abdominal aortic aneurysms with hostile anatomy. *Eur J Vasc Endovasc Surg* 2020;**60**:786–7.

- 3 Sirignano P, Mansour W, Capoccia L, Cuzzo S, Camparini S, de Donato G, et al. Immediate results of the expanding indications for treatment with standard EVAR in patients with challenging anatomies, a multi-centric prospective evaluation - EXTREME Study. *EuroIntervention* 2019;**16**:e1544–50.
- 4 Kontopodis N, Galanakis N, Tzartzalou I, Tavlas E, Georgakarakos E, Dimopoulos I, et al. An update on the improvement of patient eligibility with the use of new generation endografts for the treatment of abdominal aortic aneurysms. *Expert Rev Med Devices* 2020;**17**:1231–8.
- 5 de Donato G, Pasqui E, Mele M, Panzano C, Giannace G, Setacci F, et al. The use of a low-profile stent graft with a polymer ring sealing technology combined with bare renal stent (vent technique) in patients with juxtarenal aneurysm not eligible for open surgery and fenestrated endograft. *J Vasc Surg* 2020;**71**:1843–50.
- 6 Kontopodis N, Tavlas E, Galanakis N, Chronis C, Kafetzakis A, Tsetis D, et al. Spontaneous Type Ia endoleak sealing in patients undergoing endovascular aneurysm repair with the ovation stent graft. *Ann Vasc Surg* 2019;**54**:240–7.
- 7 de Donato G, Pasqui E, Panzano C, Brancaccio B, Grottola G, Galzerano G, et al. The polymer-based technology in the endovascular treatment of abdominal aortic aneurysms. *Polymers (Basel)* 2021;**13**:1196.
- 8 Barleben A, Mathlouthi A, Mehta M, Nolte T, Valdes F, Malas MB. Ovation trial investigators. Long-term outcomes of the Ovation Stent Graft System investigational device exemption trial for endovascular abdominal aortic aneurysm repair. *J Vasc Surg* 2020;**72**:1667–16673.e1.
- 9 Holden A, Lyden S. Initial experience with polymer endovascular aneurysm repair using the Alto stent graft. *J Vasc Surg Cases Innov Tech* 2020;**6**:6–11.