

Unicuspid aortic valve in young female patient: a rare congenital abnormality

Dubravka Šušnjar^{1*},
Igor Rudež^{1,2}

¹Dubrava University Hospital,
Zagreb, Croatia

²University of Zagreb, School
of Medicine, Zagreb, Croatia

KEYWORDS: aortic valve abnormalities, congenital aortic stenosis.

CITATION: *Cardiol Croat.* 2023;18(5-6):147. | <https://doi.org/10.15836/ccar2023.147>

***ADDRESS FOR CORRESPONDENCE:** Dubravka Šušnjar, Klinička bolnica Dubrava, Avenija Gojka Šuška 6, HR-10000 Zagreb, Croatia. / Phone: +385-99-2904-019 / E-mail: dubravka.susnjar@gmail.com

ORCID: Dubravka Šušnjar, <https://orcid.org/0000-0002-9644-9739> • Igor Rudež, <https://orcid.org/0000-0002-7735-6721>

Introduction: Unicuspid aortic valve (UAV) is a very rare congenital malformation, with prevalence of 0.02 % in the adult population, usually diagnosed already in childhood. It is most often associated with other cardiovascular abnormalities such as aortic stenosis and aortic insufficiency. UAV are classified into two types: the unicommissural type and the acommissural type described based on the absence (or presence) of a lateral attachment of the commissures to the aorta at the level of the orifice¹.

Case report: 18-year-old female patient with the diagnosis of bicuspid aortic valve (BAV) confirmed in childhood. She reported no family history of cardiac disease or sudden cardiac death. She was without symptoms such as chest pain and syncope, but in last half year she presented with dyspnea during exercise. The patient was under regular cardiological controls with repeated cardiac MRI, which showed a moderate bicuspid AV stenosis, with maximum velocity > 3 m/s, with mild insufficiency. The diameter of the aortic root is 34mm, STJ 29mm, ascend-

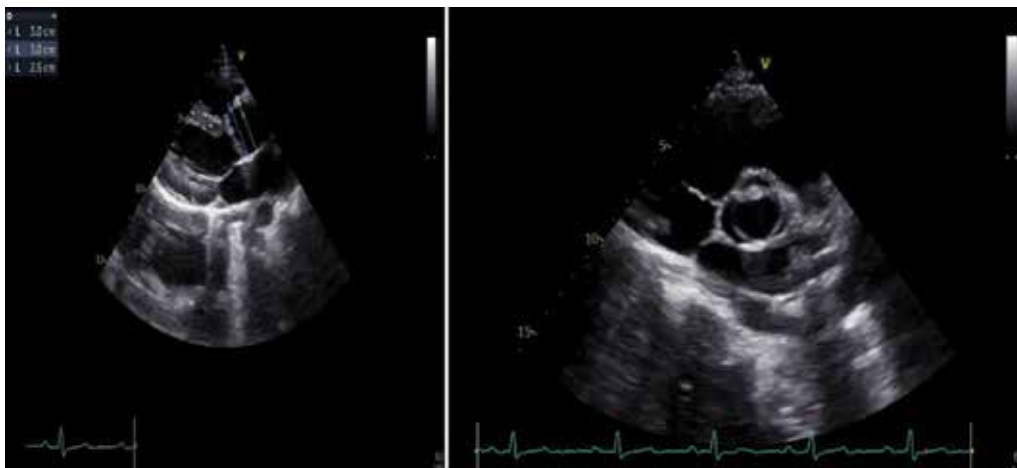


FIGURE 1. The parasternal long and short axis view showed an unicuspid aortic valve.

ing aorta 35mm. The left ventricle is of adequate size with preserved global systolic function (EF 60%). There were no other complications, such as ascending aortic dilatation, patent ductus arteriosus, and coarctation of the aorta which are often accompanied by UAV. Transthoracic echocardiography (TTE) showed marginally changed aortic valve leaflet (Figure 1), visible cuspis raphae with lateral commissure, confirmed to be unicuspid, with maximum velocity 3.48 m/s, and maximum gradient PPG 48.49 mmHg. The aortic stenosis was moderately severe with a valve area AVA (VTI) of 1.4 cm². Moderate aortic insufficiency, with a vena contracta of 7 mm and a pressure half time of 350 milliseconds, was found with eccentric regurgitant flow to the left ventricle's posterior wall. Findings on the transesophageal echocardiographic confirmed UAV stenosis with insufficiency. Patient underwent aortic valve surgery, intraoperative finding confirmed UAV. Bioprosthetic aortic valve (Edwards Inspiris Resilia 23 mm) was implanted, with good function on control echocardiography.

Conclusion: The diagnosis of UAV can be made with use of two-dimensional or three-dimensional TTE or TEE, cardiac computed tomography, or cardiac magnetic resonance imaging. With echocardiography, a UAV is best imaged during systole, because the absence of cusp separation during aortic valve opening reveals the classical eccentric "teardrop" opening². In our case, transesophageal echocardiographic TEE proved to be superior to MR.

LITERATURE

1. Anderson RH. Understanding the structure of the unicuspid and unicommissural aortic valve. *J Heart Valve Dis.* 2003 Nov;12(6):670-3. **PubMed:** <https://pubmed.ncbi.nlm.nih.gov/14658803/>
2. Novaro GM, Mishra M, Griffin BP. Incidence and echocardiographic features of congenital unicuspid aortic valve in an adult population. *J Heart Valve Dis.* 2003 Nov;12(6):674-8. **PubMed:** <https://pubmed.ncbi.nlm.nih.gov/14658804/>

RECEIVED:
March 26 2023

ACCEPTED:
March 29, 2023

