

SZAWŁOGA, Tomasz, ORZECHOWSKA, Aleksandra & SOBIESZCZAŃSKA-DROŹDZIEL, Aleksandra. Persistent diurnal enuresis in a 6-year-old boy after bilateral ureteroneocystostomy. *Journal of Education, Health and Sport*. 2023;36(1):43-48. eISSN 2391-8306. DOI <http://dx.doi.org/10.12775/JEHS.2023.36.01.005>
<https://apcz.umk.pl/JEHS/article/view/43820>
<https://zenodo.org/record/7996002>

The journal has had 40 points in Ministry of Education and Science of Poland parametric evaluation. Annex to the announcement of the Minister of Education and Science of December 21, 2021. No. 32343. Has a Journal's Unique Identifier: 201159. Scientific disciplines assigned: Physical Culture Sciences (Field of Medical sciences and health sciences); Health Sciences (Field of Medical Sciences and Health Sciences). Punkty Ministerialne z 2019 - aktualny rok 40 punktów. Załącznik do komunikatu Ministra Edukacji i Nauki z dnia 21 grudnia 2021 r. Lp. 32343. Posiada Unikatowy Identyfikator Czasopisma: 201159. Przynależność dyscypliny naukowej: Nauki o kulturze fizycznej (Dziedzina nauk medycznych i nauk o zdrowiu); Nauki o zdrowiu (Dziedzina nauk medycznych i nauk o zdrowiu).
© The Authors 2023;
This article is published with open access at License Open Journal Systems of Nicolaus Copernicus University in Torun, Poland
Open Access. This article is distributed under the terms of the Creative Commons Attribution Noncommercial License which permits any noncommercial use, distribution, and reproduction in any medium, provided the original author (s) and source are credited. This is an open access article licensed under the terms of the Creative Commons Attribution Non commercial license Share alike. (<http://creativecommons.org/licenses/by-nc-sa/4.0/>) which permits unrestricted, non commercial use, distribution and reproduction in any medium, provided the work is properly cited.
The authors declare that there is no conflict of interests regarding the publication of this paper.
Received: 03.05.2023. Revised: 10.05.2023. Accepted: 05.06.2023. Published: 05.06.2023.

Persistent diurnal enuresis in a 6-year-old boy after bilateral ureteroneocystostomy

Tomasz Szawłoga¹, Aleksandra Orzechowska¹, Aleksandra Sobieszczńska-Droździel²

1 Students' Scientific Group at the Department of Pediatric Nephrology, Medical University of Lublin, Poland

2 Department of Pediatric Nephrology, Medical University of Lublin, Poland

Tomasz Szawłoga <https://orcid.org/0000-0002-4025-9813> tomasz.w.szawloga@gmail.com

Aleksandra Orzechowska <https://orcid.org/0000-0002-6919-0928>

olaorzechowska14@gmail.com

Aleksandra Sobieszczńska-Droździel <https://orcid.org/0000-0003-2702-5083>

aleksandra.sobieszczanska-drozdziel@umlub.pl

Abstract

Urinary incontinence is one of the most common symptoms in children and adolescents. Due to numerous causes, a thorough examination is necessary. We present a case of a 6-year-old boy with diurnal enuresis, who was admitted to our Department for further treatment after the procedure of bilateral ureteroneocystostomy due to suspected bilateral ureter stenosis. With the persistence of the incontinence, our examination revealed a posterior urethral valve which was incised and the symptoms subsided.

Keywords: diurnal enuresis, hydronephrosis, vesicoureteral reflux, posterior urethral valves

Case presentation

A 6-year-old boy of Ukrainian origin was admitted to the Department of Pediatric Nephrology after bilateral ureteroneocystostomy with suspicion of neurogenic bladder. The patient was born naturally in the 38th week of gestation. Pregnancy was uneventful and the fetal ultrasound was normal. His body weight and length were 3580 g (75th percentile) and 54 cm (95th percentile), respectively. APGAR scores were 8 in the 1st and 10 in the 5th minute.

Although his psychomotor development was appropriate and the patient was toilet trained, diurnal enuresis persisted. It was accompanied by frequent (about 15 times a day) urination. Urinalysis results were normal and urinary tract infections were ruled out. While frustrating for the patient's mother it was disregarded by the paediatricians with the suggestion of a psychological cause.

At age 5 severe bilateral hydronephroses with megaureters were accidentally found in abdominal ultrasound. Consequently, the patient was referred to a pediatric urologist, and

urography and cystography were performed. (Fig1) Although in cystography voiding phase was omitted bilateral ureteral stricture was diagnosed and then operated on. Left- and right-sided ureteroneocystostomies were successively performed. However, hydronephrosis and micturition disorders persisted. The neurogenic bladder was then suspected and the initiation of clean intermittent bladder catheterization was considered, but the patient emigrated to Poland as a war refugee.

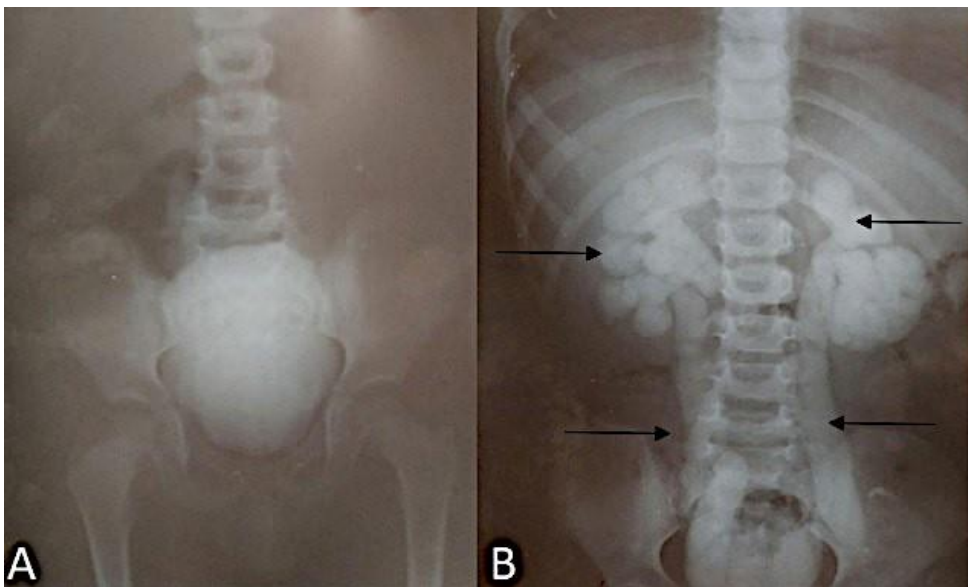


Figure 1. A. Cystography without micturition. B. Urography of the patient, note bilateral megaureters and hydronephrosis- arrows (Photos provided by the patient's mother)

After admission to our Department ultrasound confirmed severe bilateral hydronephrosis with megaureters. In laboratory tests, serum creatinine was 0.67 mg/dL (eGFR: 98.5 mL/min/1.73m²) and urinalysis was normal. Hypertension, secondary to kidney damage, was diagnosed and successfully treated with amlodipine. Videocystometry revealed vesicoureteral reflux (VUR), bladder diverticles, and obstruction in the posterior urethra. (Fig. 2) Neurological examination and spinal MRI excluded underlying neurological problems. The patient was consulted with a pediatric urologist and a urethrocystoscopy was performed. Examination confirmed posterior urethral valves type I which were incised. To prevent further complications such as bladder dysfunction and urinary tract infections tolterodine (1mg twice a day) and doxazosin in one dose of 2 mg were introduced with furazidone prophylaxis at a dose of 2 mg/kg in the evenings. For renal function assessment scintigraphy was performed and showed major defects in radiotracer uptake in the right kidney with numerous parenchyma scars and significant disturbances in urine outflow at the level of the left ureter, with the relative function of 87.9% and 12.9% in left and right kidney respectively. The first

follow-up had taken place 4 months after the valve incision, the diurnal enuresis subsided, the single urine portions increased and uroflowmetry curves normalized. Serum creatinine was 0,59 mg/dL (eGFR 113 mL/min/1.73m²). Unfortunately due to persistent hypertension intensification of hypotensive treatment was necessary and the daily amlodipine dose was increased to 5 mg.

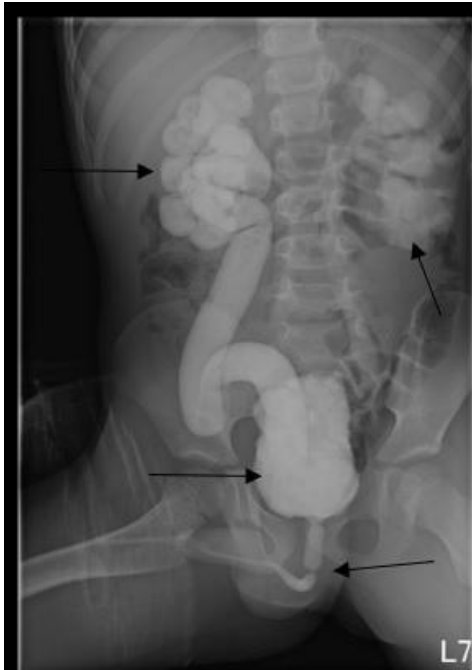

Fig. 2 Videocystometry of the presented patient at the age of 6. Note vesicoureteral refluxes (grade IV and III on the right and left side respectively), severe bladder trabeculation, and urethral obstruction – arrows (Department of Pediatric Radiology, Medical University of Lublin)

Discussion

PUV diagnosis at age of 6 like in the presented patient is quite unusual, almost 25-50% of cases can be seen neonatally and 50%-70% of cases are diagnosed in the first year of life [1]. Although, intrauterine obstruction can be presented in prenatal ultrasound (US) as bilateral hydronephrosis with an enlarged bladder, in our patient fetal ultrasounds were normal. Thakkar et al. reported only 3 of 71 patients diagnosed after the age of 5 [2] while Petersen et al. found 12 (6,6%) of patients diagnosed over the age of 5 through 28 years [3]. Due to differences in the severity of the obstruction, they can manifest shortly after birth or rarely as late as adulthood [4]. Surprisingly our patient had only diurnal enuresis and abdominal pain possibly caused by hydronephrosis. Although voiding cystourethrography is considered to be

a golden standard [5] of PUV detection, only urethroscopy can confirm valves, identify their type, and enables causative treatment (ablation/ incision of PUV) [6]. Unfortunately in the presented case in the first cystourethrography urethra was not visualized which was misleading. However, reimplanting the ureters without visualization of the lower urinary tract is unacceptable. Even with early surgical intervention, 75% of males with PUV show bladder dysfunction called valve bladder syndrome (VBS) [7]. Bladder changes in boys with PUV go through three phases. First hypertrophy of bladder muscles increases voiding pressure to help bladder emptying. Simultaneously high pressure is transmitted to the upper urinary tract and may cause dilatation, vesicoureteral reflux (VUR), and hydronephrosis. The second phase of compensation occurs when bladder volume increases. In the last third phase of myogenic failure bladder capacity progressively increases, however without effective detrusor contraction [8]. To prevent such outcomes we introduced anticholinergics to decrease volume pressure [8] and alpha-adrenergic blockade for relieving secondary bladder neck obstruction before and after PUV ablation [8]. VUR and hydronephrosis both are responsible for maintaining elevated pressure in the upper urinary tract. This phenomenon leads to obstructive uropathy and kidney parenchyma atrophy. Additionally, VUR is one of the risk factors for UTI thus antibacterial prophylaxis is recommended [1]. UTI and high-grade VUR, such as in the presented patient, are risk factors for kidney parenchyma scarring [9] thus kidney scintigraphy may help in the evaluation of kidney function. Recurrent UTI and bladder dysfunction are risk factors for chronic kidney disease (CKD). In PUV patients up to 50% may develop CKD and 20% end stage kidney disease (ESKD) [10]. Consequently, those patients require long-term urologic and nephrologic management to avoid such outcomes or slow down their progression

The presented patient is an example of treating PUV as a disease of infancy. Lack of proper assessment of lower urinary tracts cannot be an excuse for invasive treatment. With a high possibility of bladder dysfunction and chronic kidney disease development, PUV patients need to be under the constant care of specialists

References

1. Hodges SJ, Patel B, McLorie G, Atala A. Posterior urethral valves. *ScientificWorldJournal*. 2009;9:1119-1126. doi:10.1100/tsw.2009.127

2. Thakkar D, Deshpande AV, Kennedy SE. Epidemiology and demography of recently diagnosed cases of posterior urethral valves. *Pediatr Res.* 2014;76(6):560-563. doi:10.1038/pr.2014.134
3. Petersen KL, Moore DP, Kala UK. Posterior urethral valves in South African boys: Outcomes and challenges. *S Afr Med J.* 2018;108(8):667-670. doi:10.7196/SAMJ.2018.v108i8.12934
4. Kilciler M, Basal S, Irkilata HC, Zor M, Istanbuluoglu MO, Dayanc M. Adult posterior urethral valve: a case report. *Ger Med Sci.* 2010;8:Doc08. doi:10.3205/000097
5. Mirshemirani A, Khaleghnejad A, Rouzrokh M, Sadeghi A, Mohajerzadeh L, Sharifian M. Posterior Urethral Valves; A single Center Experience. *Iran J Pediatr.* 2013;23(5):531-535.
6. Fishberg SE, Landau EH, Duvdevani M, Gofrit ON, Friedman SE, Hidas G. Posterior urethral valves: prenatal, neonatal, and long-term management. *NeoReviews* 2018;19:e753-e761 <https://doi.org/10.1542/neo.19-12-e753>
7. Lopez Pereira P, Martinez Urrutia MJ, Espinosa L, Jaureguizar E. Long-term consequences of posterior urethral valves. *J Pediatr Urol.* 2013;9(5):590-596. doi:10.1016/j.jpuro.2013.06.007
8. Chan EP, Wang PZT, Dave S. Valve Bladder Syndrome Associated with Posterior Urethral Valves: Natural History, Work-up, and Management. *Curr Bladder Dysfunct Rep.* 2020;15:76–82.
9. Chen MJ, Cheng HL, Chiou YY. Risk factors for renal scarring and deterioration of renal function in primary vesico-ureteral reflux children: a long-term follow-up retrospective cohort study. *PLoS One.* 2013;8(2):e57954. doi:10.1371/journal.pone.0057954
10. Klaus R, Lange-Sperandio B. Chronic Kidney Disease in Boys with Posterior Urethral Valves-Pathogenesis, Prognosis and Management. *Biomedicines.* 2022;10(8):1894. doi:10.3390/biomedicines10081894