

Sirman Y. V., Savytskyi I. V., Preys N. I., Blavatska O. M. Results of histological examination of experimental diabetic retinopathy and its correction with metformin, aflibercept, L-arginine solution and cyticolin. *Journal of Education, Health and Sport*. 2020;10(12):426-435. eISSN 2391-8306. DOI <http://dx.doi.org/10.12775/JEHS.2020.10.12.042>
<https://apcz.umk.pl/czasopisma/index.php/JEHS/article/view/JEHS.2020.10.12.042>
<https://zenodo.org/record/7112906>

The journal has had 5 points in Ministry of Science and Higher Education parametric evaluation. § 8. 2) and § 12. 1. 2) 22.02.2019.

© The Authors 2020;

This article is published with open access at Licensee Open Journal Systems of Nicolaus Copernicus University in Torun, Poland
Open Access. This article is distributed under the terms of the Creative Commons Attribution Noncommercial License which permits any noncommercial use, distribution, and reproduction in any medium, provided the original author (s) and source are credited. This is an open access article licensed under the terms of the Creative Commons Attribution Non commercial license Share alike. (<http://creativecommons.org/licenses/by-nc-sa/4.0/>) which permits unrestricted, non commercial use, distribution and reproduction in any medium, provided the work is properly cited.
The authors declare that there is no conflict of interests regarding the publication of this paper.

Received: 09.11.2020. Revised: 25.11.2020. Accepted: 29.12.2020.

UDC:616-06:616-092.9

Results of histological examination of experimental diabetic retinopathy and its correction with metformin, aflibercept, L-arginine solution and cyticolin

Y. V. Sirman, I. V. Savytskyi, N. I. Preys, O. M. Blavatska

GE «Ukrainian Research Institute of Transport Medicine of the Ministry of Health of Ukraine»

Correspondence author: *Savytskyi Ivan Volodymyrovich, 65039, Odesa, Fountain road 4-a/29, tel.+38050-381-21-83, e-mail-farmakod@ukr.net*

Abstract

The purpose of the study was to analyze the histological changes in the structures of the eyeball in experimental diabetic retinopathy and its correction with metformin, aflibercept, L-arginine solution and citicoline.

The obtained results indicate about the development of pathological changes in the retina against the background of the progression of experimental diabetes when streptozotocin is administered at dose 55 mg/kg of animal weight against the background of a high-fat diet. The development of simulated streptozotocin diabetes is accompanied by disturbance in the retina in the form of edematous shifts of fibers and swelling of the cells forming it, uneven distribution of cells of the ganglion layer and vacuolization of the cytoplasm some of them. The using of corrective drugs complex for metabolic disorders and angiopathy, which are characteristic of diabetes mellitus, affects on the retina condition. Under the influence of

aflibercept, solution of L-arginine, citicoline, and metformin administration was established that edematous changes in its structural elements are significantly reduced, the number of vessels on the border with the retina visually increases, and the staining of the cells of the ganglion layer becomes more freshly.

Key words: experimental diabetic retinopathy; streptozotocin diabetes; histological examination; correction; metformin; aflibercept; L-arginine; citicoline.

Introduction. According to the WHO, diabetic retinopathy (DR) is the main cause of vision loss and blindness in diabetes. This pathology is the main cause of visual impairment in the population of economically developed countries [1-4] and is diagnosed in 40-85 % of patients suffering from diabetes.

It is noting that even with the compensation of carbohydrate metabolism, the development of DR continues. An important factor in the development of retinopathy in diabetes is not only hyperglycemia, but also arterial hypertension [5-9]. The key role of endothelial dysfunction in the occurrence and progression of DR has been proven [10,11]. The pathogenesis of complications of diabetes mellitus is multifactorial in nature. Factors such as increased permeability of blood vessels, disruption of the energy balance, changes in the metabolism of cell membranes, and the induction of polypeptide growth factors are significant. In each specific case, the set and severity of individual chronic complications vary from their paradoxical almost complete absence, despite the significant duration of the disease, to a combination of all possible options in severe form [12, 13].

The aim of work – is the analysis of histological changes in eyeball structures in experimental diabetic retinopathy and its correction with metformin, aflibercept, L-arginine solution and citicoline.

Materials and methods. The study was conducted on white Wistar rats weighing 180-200 g. According to the tasks, the animals were divided into 3 groups:

1st group – intact animals;

2nd group – 60 animals with modelling of DR without correction (control pathology);

3rd group –60 animals with modelling of DR with correction of hyperglycemia, administration of aflibercept, L-arginine solution and citicoline.

Type 2 diabetes and DR were modeled by intraperitoneal administration of streptozotocin (Sigma, USA) dissolved in 0.1 M citrate buffer with pH 4.5 [14, 15]. Dose of streptozocin of 55 mg/kg of animal weight was divided into two administrations. Administration of streptozocin was preceded by a high-fat diet for 28 days [16].

Animals were subjected to research by decapitation in accordance with the "Rules for the performance of work using experimental animals", approved by the Order of the Ministry of Health of Ukraine No. 249 of 01.03.2012 and the Law of Ukraine No. 3447-IV "On the Protection of Animals from Cruelty" (as amended on 15.12.2009 and 16.10.2012).

The hypoglycemic medicine – metformin (Merck Sante, manufactured in France) - at a dose of 300 mg/kg body weight [17] in a 0.9 % sodium chloride solution through a syringe with an intragastric probe daily, during the entire experiment.

The introduction of L-arginine solution, which is NO donor, (SIMESTA, manufactured in China, quality standard USP32) was carried out by intragastric administration of L-arginine solution in 0.9 % sodium chloride solution at a dose of 500 mg/kg [18] through a syringe with an intragastric probe.

Aflibercept (anti-VEGF therapy) was administered in the form of subconjunctival injections at a dose of 0.08 ml (25 mg/ml) [19] with an interval of 1 injection every 30 days.

Citicoline – 81.8 mg/kg (0.33 ml/kg) was administered intramuscularly once per a day [20].

Histological examination: after removing the rats from the experiment, enucleation was performed. One eyeball was fixed for 24 hours in a 4 % paraformaldehyde solution, then the obtained materials were passed through alcohols of increasing concentration and poured into celloidin according to the generally accepted method. From the obtained blocks, histological sections of 7-9 microns were made, which were stained with hematoxylin-eosin. The obtained preparations were examined under a light microscope and structural changes in the formations of the eyeball were determined.

Results of study and their discussion:

The study of histological preparations of the retina of a healthy rat showed the following. The retina is a multi-layer formation according to its organization. The outer (pigment) layer is formed by flattened cells with flattened oval nuclei, the cytoplasm of which contains individual melanin granules of various sizes. The layer above them is formed by columnar structures of eosinophilic staining – rods and cones. This layer is covered with a thin, dense, uniform membrane. A sufficiently wide layer of cells with rounded nuclei of different chroma is located closer to the inside (Fig. 1.)

Nucleus is a different size, mostly medium. The cytoplasm of cells is represented by a thin rim around the nucleus. It is colored pale eosinophilic. The outer granular, the outer edge of this layer is weakly expressed. This layer is separated from more internal formations by

layer that is formed by irregularly arranged short thin fibers. Above it is a layer with rounded cells that have medium, pale colored nuclei and a thin rim of cytoplasm.

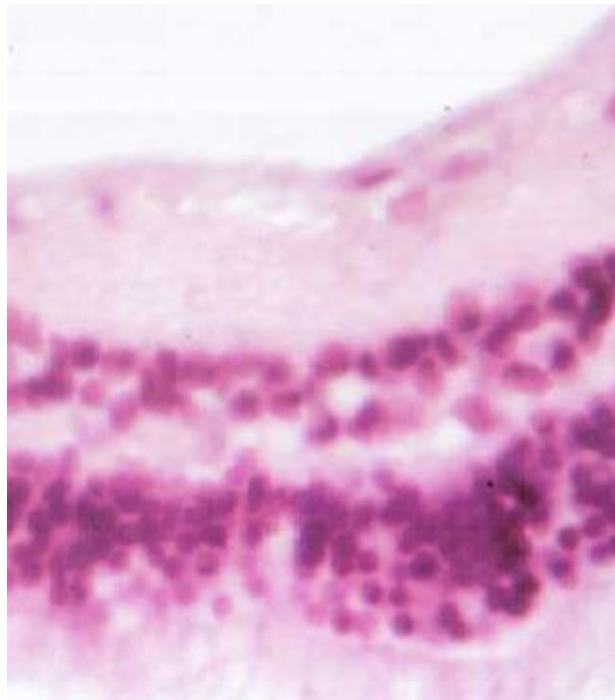


Fig. 1. Retina of healthy rat. An outer granular layer with a wavy outer edge. A thin inner granular layer with cells with large nuclei. The ganglionic layer contains neurons with different chrominity of the nuclei. Tinc. Hematoxylin-eosin. Phf.: x 300.

These cells are similar in appearance to the previously described outer granular layer, but it is visually smaller in width. Above it is a layer formed by thin, delicate, short, pale eosinophilic fibers. Closer to the eye cavity, there are ganglion cells in one row, which are characterized by the presence of medium-sized nuclei with varying degrees of staining intensity and sufficiently large volume of very palely stained cytoplasm. A thin layer of disordered thin fibers is defined above it, some of which form arch-like formations. The retina is covered with a thin homogeneous, strongly eosinophilic membrane.

Histological examination of the rat's retina with simulated diabetes showed the following. The layered organization of the experimental animals' retina is preserved. The outer pigment layer is represented by one row of cells, mainly with flat nuclei, which lack pigment granules. The density of cells is visually slightly lower than in the control. There is also the presence of single cells with rounded nuclei, the staining of which is lighter than that of flat cells. The outer glial membrane is thin, pale eosinophilic. The layer of rods and caps is represented by dense structures arranged in columns. The peculiarity of this layer in experimental animals was the unequal intensity of their staining, next to moderately

eosinophilic formations. Pale columnar structures were present, and there were also small "gaps" in this layer.

The outer granular layer is visually the same width as in intact animals. The cells located in it have rounded, moderately chromic nuclei. The peculiarity of experimental rats is that instead of the slight undulation of the outer edge of this layer in intact rats, in them it forms rather significant protrusions in which the cells are rarefied, most likely due to edema. The outer flexiform layer is formed by short thin fibers, pale eosinophilic. In contrast to the control, the location of the fibers is swollen and rarefied. The number of fibers is visually reduced. The inner granular layer is thinned and represented by cells with rounded nuclei and varying degrees of chromicity. The peculiarity of this layer in the experimental animals was the pronounced rarefaction of their distribution and the uniformly small size of the nuclei. This may be due to a decrease in the number of cellular elements or tissue swelling. The width of the inner reticular layer of the retina corresponds to the data of control animals. In that part of this layer, which is adjacent to the ganglion layer, the presence of areas of edematous-thinned areas is observed. The fibers that form this layer are thin, pale eosinophilic, and short. The layer of ganglion cells is distinguished by an uneven distribution of cells. Areas with evenly distributed neurons border areas where such cells are single. Vacuolation of a significant part of ganglion cells should be emphasized. At the same time, in areas with a denser arrangement of cells, the vacuoles in their cytoplasm are small, and the nuclei are large enough, with a moderate chrominity. In areas where ganglion cells are rarefied in their cytoplasm, the vacuoles are large and the nuclei are small, darkly stained. (Fig. 2).

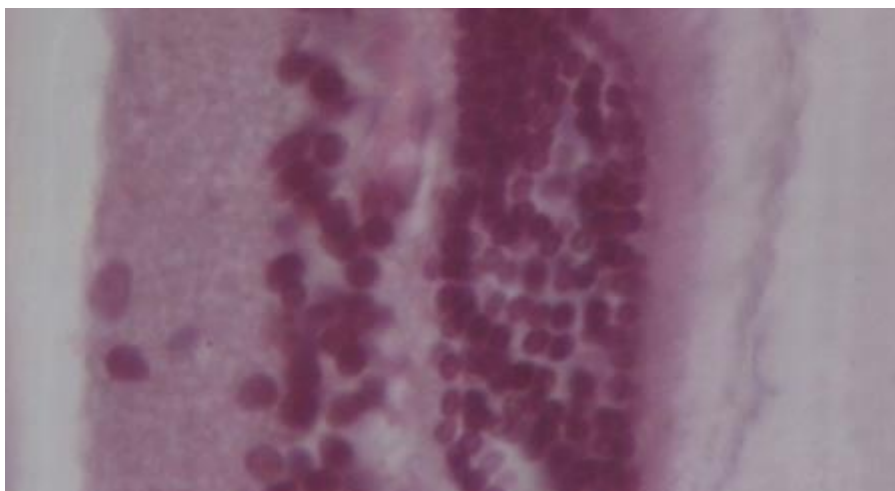


Fig. 2. Retina of rat with simulated diabetes. 60th day of research. Thinning of the inner granular layer. Rarefaction of cells in the ganglionic layer, their different chroma. Tinc. Hematoxylin-eosin. Phf.: x 300.

In the layer of nerve fibers, the arch organization of their distribution is smeared, and the fibers themselves are swollen. The outer glial membrane with areas of swelling and loosening, pale-colored. A feature of the eye structure of these animals was the presence of individual dark granules in the lens closer to its outer surface (Fig. 3).

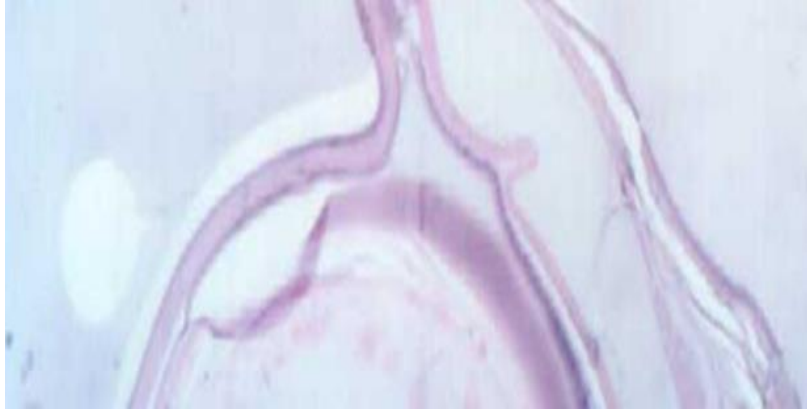


Fig. 3. The presence of inclusions in the lens of a rat with experimental diabetes. Tinc. Hematoxylin-eosin. Phf.: x 300.

A morphological study of the retina of rats with a model of diabetes mellitus, which received complex correction, revealed several positive changes in comparison with the data of animals in which the pathological process was simulated without further correction. The state of the outer pigment layer is practically no different from the intact group. It mainly consists of cells with flattened nuclei, there are individual cells with rounded light nuclei. Granules of the pigment are individual, separate, small, rarely found. The peculiarity of this group was the presence of moderately full blood vessels, which were adjacent to the pigment layer. Visually, they are slightly more than in animals with uncorrected diabetes.

The outer glial membrane is thin, homogeneous, pale eosinophilic. The layer of rods and cones is represented by columnar structures of monotonous moderate eosinophilic staining. Gaps in this layer were observed in animals with uncorrected diabetes, visually they are individually smaller than in animals in the previous group. The outer granular layer is characterized by a width that is close to the control indicators. Its feature is that these cells form either dense clusters or areas with moderate distribution density. The cells of this layer have rounded nuclei, freshly colored, mostly of medium size. Another feature of this layer is the weak expression of the waviness of the outer layer. The layer of fibrous fibers differs in that the areas where single fibers are located border the areas where cells from the granular layers penetrate (Fig. 4).

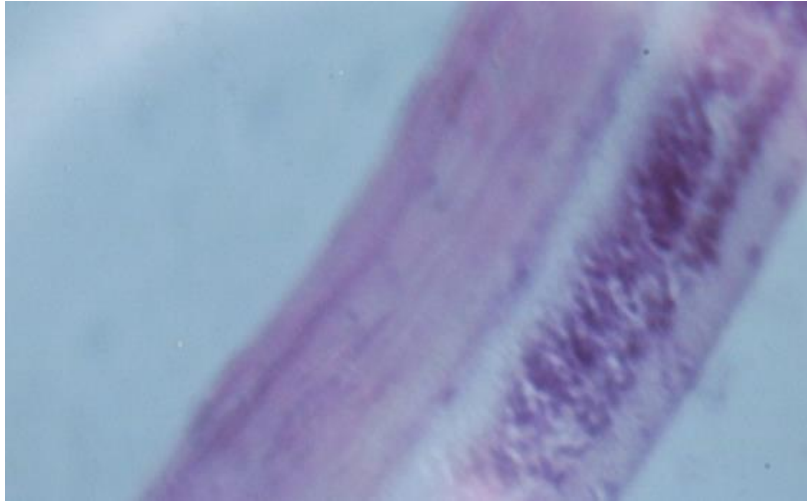


Fig. 4. Rat's retina on the 60th day of the diabetes modelling with correction. Outer granular layer of different density of cell distribution. Penetration of cells into the reticular layer. Tinc. Hematoxylin-eosin. Phf.: x 300.

The inner granular layer is thin, the distribution of cells is even. Edematous rarefaction is not pronounced. Only single cells penetrate neighboring layers. The inner layer of fibers (layer of nerve fibers) is quite homogeneous. The fibers are pale colored. A feature of this layer in rats that received complex correction is the absence of pronounced edema or vacuolization of the structures of this layer. It should be emphasized that this is more pronounced in the part of this layer that is close to the granular layer. As for the ganglion layer, visually, the density of the distribution of cells on it is higher in animals with corrected pathological condition. However, this is due to the appearance between neurons of cells with colored nuclei, which have separated from the internal granular layer. Ganglion cells are characterized by swelling of the body and its indistinct borders, with rather pale colored nuclei. Vacuolation of cells is not observed (Fig. 5).

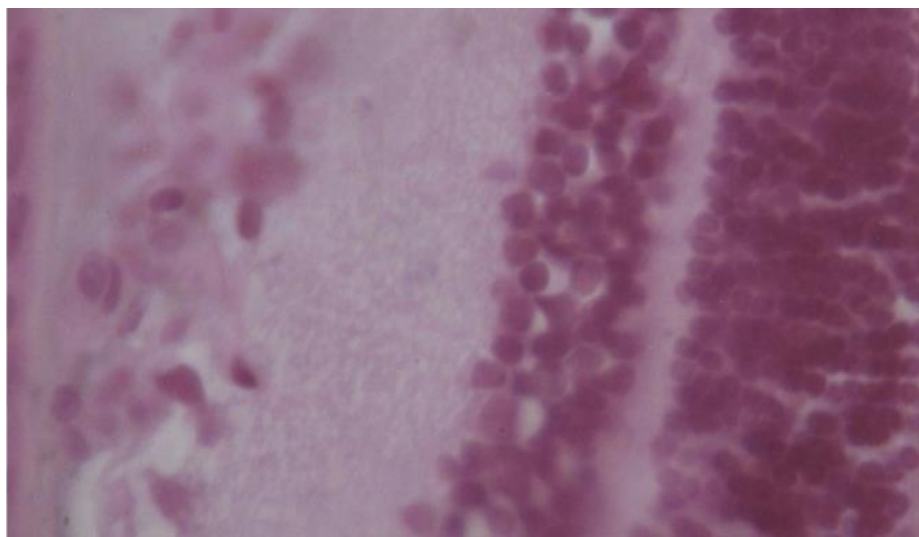


Fig. 5. Rat's retina on the 60th day of the diabetes modelling. Rarefaction of the inner granular layer. Rarefaction of cells in the ganglionic layer, their different chroma.

Tinc. Hematoxylin-eosin. Phf.: x 300.

The layer of nerve fibers is characterized by their swelling and disordered distribution. Dark, punctate inclusions remain in the lens.

Conclusions:

1. The obtained results indicate about the development of pathological changes in the retina against the background of the progression of experimental diabetes when streptozotocin is administered at dose 55 mg/kg of animal weight against the background of a high-fat diet.

2. The development of simulated streptozotocin diabetes is accompanied by disturbance in the retina in the form of edematous shifts of fibers and swelling of the cells forming it, uneven distribution of cells of the ganglion layer and vacuolization of the cytoplasm some of them.

3. The using of corrective drugs complex for metabolic disorders and angiopathy affects on the retina condition.

4. Under the influence of aflibercept, solution of L-arginine, citicoline, and metformin administration was established that edematous changes in its structural elements are significantly reduced, the number of vessels on the border with the retina visually increases, and the staining of the cells of the ganglion layer becomes more freshly.

References:

1. Vorob'eva I. V., Repkina M. Ju. Prakticheskie rekomendacii o nabljudenii bol'nyh s diabeticheskoj retinopatiej // RMZh. Jendokrinologija. —2009. — T. 17, № 24. — S. 1591-1595.
2. Ametov A. S. Saharnyj diabet i serdechno-sosudistye zabojevanija [Elektronnyj resurs] / A.S. Ametov, I.O. Kurochkin, A.A. Zubkov // RMZh. — 2014. — № 13. — S. 954–959. — Rezhim dostupa: http://www.rmj.ru/articles_9505.htm
3. Abbate M, Cravedi P, Iliev I, et al. Prevention and treatment of diabetic retinopathy: evidence from clinical trials and perspectives // Curr Diabetes Rev. — 2011. — Vol. 7. — P. 190-200.
4. Vorob'eva I.V., Giginishvili D.N. Rol' disfunkcii jendotelija v patogeneze diabeticheskoj retinopatii u bol'nyh saharnym diabetom 2 tipa. Obzor. Oftal'mologija. 2012;9(3):9-13.
5. American Diabetes Association: Standarts of medical care in diabetes-2011 // Diabetes care. — 2011. — Vol. 34, Suppl. I: S4–88.
6. Shestakova M. V., Shamhalova M. Sh. Sovremennyj podhod k profilaktike i lecheniju diabeticheskoj retinopatii: rezul'taty issledovanija DIRECT, 2009. Spravochnik poliklinicheskogo vracha. — 2009. — № 1. — S. 3-39.
7. Delano FA, Chen AY, Wu KI, et al. The autodigestion hypothesis and receptor cleavage in diabetes and hypertension // Drug Discov Today Dis Models. — 2011. — Vol. 8. — P. 37-46.
8. Wright AD; Dodson PM. Diabetic Retinopathy and Blockade of the Renin Angiotensin System: New Data from the DIRECT Study Programme // Eye. 2010. — Vol. 24. —P. 1-6.
9. Porta M, Maldari P, Mazzaglia F. New approaches to the treatment of diabetic retinopathy // Diabetes Obes Metab. — 2011. — Vol. 13. — P. 784-790.
10. Gavrilova N.A., Tishhenko O.E. Vlijanie sulodeksida na funkcional'noe sostojanie jendotelija u bol'nyh saharnym diabetom i diabeticheskoj retinopatiej // Saharnyj diabet. 2011. № 2. S. 66–68.
11. Astahov Ju.S., Shadrichev F.E., Lisoehkina A.B. Diabeticheskaja retinopatija // Oftal'mologija – 2006. Klinicheskie rekomendacii / pod red. L.K. Moshetovoj, A.P. Nesterova, E.A. Egorova. M.: GJeOTAR-Media, 2006. S. 139–163.

12. Galstjan G.R. Hronicheskie oslozhnenija saharnogo diabeta: jetiopatogenez, klinika, lechenie / G.R. Galstjan // Russkij medicinskij zhurnal. - 2002,- № 27, T. 10. - S. 23-31.
13. Williamson J.R. Basement membrane abnormalities in diabetes mellitus: relationship to clinical microangiopathy / J.R Williamson, R.G. Tilton, K. Chang // Diabetes Metabolism reviews. - 1998. -N 4. - P. 339-370.
14. Poltorak V.V., Bloh K.O., Malashenko A.M. Jeksperimental'noe modelirovanie saharnogo diabeta dlja izuchenija specificheskogo jeffekta novyh antidiabeticheskikh veshhestv (Metod. rekomend.). Har'kov, 1991. 20 s.
15. Pasechnikova N. V. Zashhitnoe dejstvie kvercetina i lipoata na funkcional'nye gruppy belkov setchatki pri modelirovanii diabeta / N.V. Pasechnikova, O.A. Moroz // Oftal'mologichnij zhurnal. – 2015. – № 3. – S. 76-81
16. Jeksperimental'naja model' saharnogo diabeta 2-go tipa u krysv, vyzvannaja dietoj s vysokim sodержaniem zhиров i streptozotocinom v nizkoj doze / O.A. Kajdash, V.V. Ivanov, A.I. Vengerovskij, E.E. Bujko, I.A. Shhepetkin // Bjulleten' sibirskoj mediciny. – 2020. – №19(2). – S.41-47.
17. Rol' metformina v profilaktike diabeticheskoy nefropatii pri jeksperimental'nom saharnom diabete 2 tipa / V.K. Bajrasheva, A.Ju. Babenko, Ju.V. Dmitriev, A.A.Bajramov, S.G. Chefu, I.S. Shatalov, A.N. Aref'eva, I.Ju. Pchelin, N.V. Hudjakova, P.G. Aliev, E.N. Grineva // Regionarnoe krovoobrashhenie i mikrocirkuljacija. – 2016. – №15(3). – S.70-80.
18. Pokrovskij M.V. Jendotelioprotektornye jeffekty L-arginina pri modelirovanii deficita okisi azota / M.V. Pokrovskij, T.G. Pokrovskaja V.I. Korchakov // Jeksperimental'naja i klinicheskaja farmakologija. – 2008. – № 71 (2). – S. 29–31.
19. Efficacy of Subconjunctival Aflibercept Versus Bevacizumab for Prevention of Corneal Neovascularization in a Rat Model / Orly Gal-Or 1, Eitan Livny, Ruti Sella, Yael Nisgav, Dov Weinberger, Tami Livnat, Irit Bahar // Cornea. – 2016. – Vol. 3. – Issue 7. – R. 991-996.
20. Savytskyi. I. V.; Levytskyi, I. M.; Levytska, G. V.; Miastkivska, I. V.; Kuzmenko, I. A. Dynamics of vasoconstriction and vasodilation potential on the background of experimental rhegmatogenous retinal detachment and its correction. Journal of Education, Health and Sport 2016, 6 (2), p. 367-375.