

Hoffman, Zofia, Homa, Piotr, Gałazka, Jakub Krzysztof, Sakwa, Leon, Szymoniuk, Michał, Domagalski, Łukasz, Wdowiak, Marcin, Czyżewski, Wojciech, Rola, Radosław, Antonov, Sergey. Multidisciplinary approach for a severe head burn caused by high-voltage electrical shock – a case report. *Journal of Education, Health and Sport*. 2022;12(9):754-762. eISSN 2391-8306. DOI <http://dx.doi.org/10.12775/JEHS.2022.12.09.089> <https://apcz.umk.pl/JEHS/article/view/39771> <https://zenodo.org/record/7076385>

The journal has had 40 points in Ministry of Education and Science of Poland parametric evaluation. Annex to the announcement of the Minister of Education and Science of December 21, 2021. No. 32343. Has a Journal's Unique Identifier: 201159. Scientific disciplines assigned: Physical Culture Sciences (Field of Medical sciences and health sciences); Health Sciences (Field of Medical Sciences and Health Sciences).

Punkty Ministerialne z 2019 - aktualny rok 40 punktów. Załącznik do komunikatu Ministra Edukacji i Nauki z dnia 21 grudnia 2021 r. Lp. 32343. Posiada Unikatowy Identyfikator Czasopisma: 201159. Przynależność dyscypliny naukowej: Nauki o kulturze fizycznej (Dziedzina nauk medycznych i nauk o zdrowiu); Nauki o zdrowiu (Dziedzina nauk medycznych i nauk o zdrowiu).

© The Authors 2022;

This article is published with open access at Licensee Open Journal Systems of Nicolaus Copernicus University in Torun, Poland  
Open Access. This article is distributed under the terms of the Creative Commons Attribution Noncommercial License which permits any noncommercial use, distribution, and reproduction in any medium, provided the original author(s) and source are credited. This is an open access article licensed under the terms of the Creative Commons Attribution Non commercial license Share alike. (<http://creativecommons.org/licenses/by-nc-sa/4.0/>) which permits unrestricted, non commercial use, distribution and reproduction in any medium, provided the work is properly cited.

The authors declare that there is no conflict of interests regarding the publication of this paper.  
Received: 01.09.2022. Revised: 02.09.2022. Accepted: 13.09.2022.

## Multidisciplinary approach for a severe head burn caused by high-voltage electrical shock – a case report

Zofia Hoffman<sup>1</sup>, Piotr Homa<sup>2</sup>, Jakub Krzysztof Gałazka<sup>3</sup>, Leon Sakwa<sup>4</sup>, Michał Szymoniuk<sup>5</sup>, Łukasz Domagalski<sup>5</sup>, Marcin Wdowiak<sup>6</sup>, Wojciech Czyżewski<sup>6</sup>, Radosław Rola<sup>6</sup>, Sergey Antonov<sup>7</sup>

1 – Students' Scientific Association at Chair of Human Anatomy, Medical University of Lublin, Jaczewskiego 4, 20-090 Lublin, Poland; [zofhof@gmail.com](mailto:zofhof@gmail.com)

2 – Students' Scientific Association at the Department of Pediatric Hematology, Oncology and Transplantation, Medical University of Lublin, Profesora Antoniego Gebali 6, 20-093 Lublin, Poland; [p.k.homa@gmail.com](mailto:p.k.homa@gmail.com)

3 – Students' Scientific Association at Chair and Department of Clinical Immunology, Medical University of Lublin, Chodźki 4A, 20-093 Lublin, Poland; [jakubgalazka2@wp.pl](mailto:jakubgalazka2@wp.pl)

4 – Student Scientific Society, Kazimierz Pulaski University of Technologies and Humanities in Radom, Chrobrego 27, 26-600 Radom, Poland; [sakwus@gmail.com](mailto:sakwus@gmail.com)

5 – Students' Scientific Association at Department of Neurosurgery and Paediatric Neurosurgery, Medical University of Lublin, Jaczewskiego 8, 20-090 Lublin, Poland; [michmatsz@gmail.com](mailto:michmatsz@gmail.com)

6 – Department and Clinic of Neurosurgery and Paediatric Neurosurgery, Medical University of Lublin, Jaczewskiego 8, 20-090 Lublin, Poland; [wojciech.w.czyzewski@gmail.com](mailto:wojciech.w.czyzewski@gmail.com) (W.C.)

7 – Department of Plastic and Reconstructive Surgery, St. John's Cancer Center, Jaczewskiego 7, 20-090 Lublin, Poland

### Abstract

In modern reconstructive medicine, personalized bone substitutes provide therapeutic hope for patients with non-standard bone defects. The study aims to present a description of a case of using a personalized bone substitute material, taking into account the vascular connections formed after a previous skin transplant.

The 29-year-old patient was admitted to the plastic surgery department urgently after being electrocuted with high voltage. Due to extensive scalp burns, a skin graft was performed in the area of previously removed skin along with a charred skull bone vault.

After a few months, the patient was qualified for cranioplasty with the use of personalized bone substitutes. The necessity to make cuts around the vascular connections present in the transplanted tissue was the main difficulty in the for the operator.

The operation was successful and the recovery was uneventful. The patient was discharged home in good general and local condition.

The presented case illustrates the need to take into account creating vascular connections with the use of personalized bone substitutes in patients after skin transplants.

**Keywords:** burn, reconstructive neurosurgery, reconstruction of skull bones defects, head injury, cranioplasty

## **The effect of high voltage current on the human body**

Although the global widespread use of electrical energy has numerous advantages, including improvements in healthcare, on the other hand, we should not forget about the possible dangers stemming from human contact with electricity. Direct contact of electricity with a cell may result in its death by membrane electroporation and severe failure in organelle function [1].

The first case of death caused by electrical injury took place in 1879. Presently 3-5% of reported burns are caused by electricity, which makes electric injury (EI) a rare occurrence [2]. Classification of electrical injuries is typically divided into low-voltage (<1000 volts) and high-voltage (>1000 volts). EI mortality also is low and estimated from 2,6% to 5,2% depending on electricity voltage according to metanalyses [3].

The severity of damage in EI strongly depends on tissue resistance. More than 99% of the body's resistance to current flow is at the epidermis. On the other hand, a wide range of factors can impress the resistance of the human body – for example, callousation increases skin resistance, whereas moisture decreases it [2]. That difference explains why the majority of patients (56,3%) with EI have pure contact burns, whereas significantly lower percentages (29,1%) have pure electrical flash burns and the rest (14,6%) have mixed injuries [4]. The areas of increased risk of EI are borders between high (muscles) and low (bones and tendons) resistance in limbs [2]. According to metanalyses, from 54,1% (low-voltage) to 79,6% (high-voltage) of EI is treated by surgical intervention. Mainly reported clinical features are ECG changes, myoglobinuria, renal dysfunction, and secondary infections [3], which are also main causes of death in the EI course [4]. Although EI mortality is low, it may cause severe complications – according to a single-center retrospective study, 38,8% of patients with EI need amputation [4], and according to mentioned metanalyses, 32,6% of patients with high-voltage EI need reconstructive flaps [3].

This case report aims to present a patient with high-voltage EI and severe burns, who needed a scalp implant, which preserved present vessel anastomoses.

## Introduction

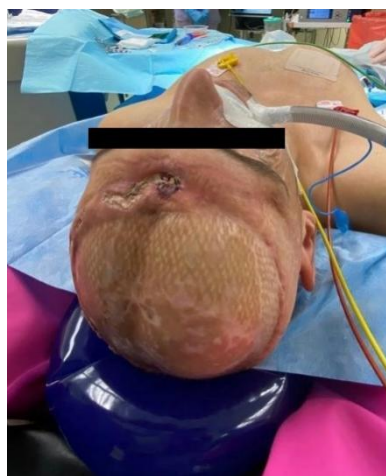

Figure 1 Patient prepared for plastic surgery

A 29-year-old male patient suffered a 3rd / 4th-degree electric burn affecting both legs and head. The burn, which occurred on December 24, 2019, was caused by high-voltage electricity in a transformer station. After the accident, the man was immediately transported to the anesthesiology and intensive care unit. As soon as the patient's condition stabilized, his treatment began at the plastic and burn surgery department and at another burn treatment center. These two separate medical facilities situated almost 600 km from each other cooperated throughout the patient's treatment. During the performed surgical operation, the left lower limb was amputated at the shin level as well as the right forefoot. CT of the head showed slight hypodense areas in the top parts of the frontal lobes, especially on the right side. A necrectomy was performed. During the operation, surgeons found complete necrosis of the parietal and frontal bones. In the central area above the sagittal sinus, a pale dura mater was visualized. Fragments of the cranial vault were removed, revealing the dura mater, and skin grafts of intermediate thickness were placed on the tissue defects.

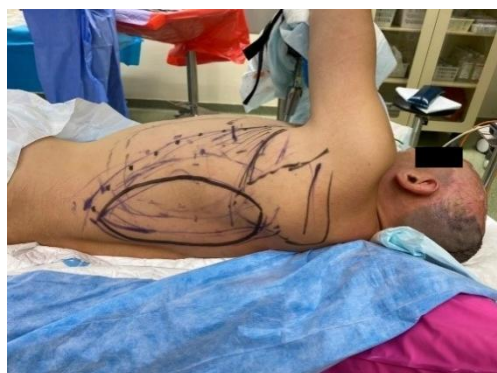

Figure 2 Determining the LD flap collection site

Initially, the grafts healed well, except for the fragment above the damaged dura mater. However, subsequent dressings changes revealed necrosis of the grafts. The treatment was repeated several times. After the end of treatment in the district hospital and regional burn treatment center, the patient was admitted to the department of plastic and reconstructive surgery to continue the treatment. Under general anesthesia in the position on the right side, after the operating field was prepared in the usual way, a revision was performed, during which it was established that there is a defect in the frontal-parietal-temporal area of the skull, 18 x 17 cm, covered with healed free grafts of the intermediately thick skin. The bony edge of the opening in the projection of the frontal sinuses and in the area of the left temple was exposed in places, the bone was dry with small necrotic areas, single fistulas, and the frontal sinuses were open. Longitudinal incisions of the skin were made,

forming a cutaneous island of the LD flap (latissimus dorsi m.), then the incision was extended with a sharply meandering shape of a zigzag to the armpit.

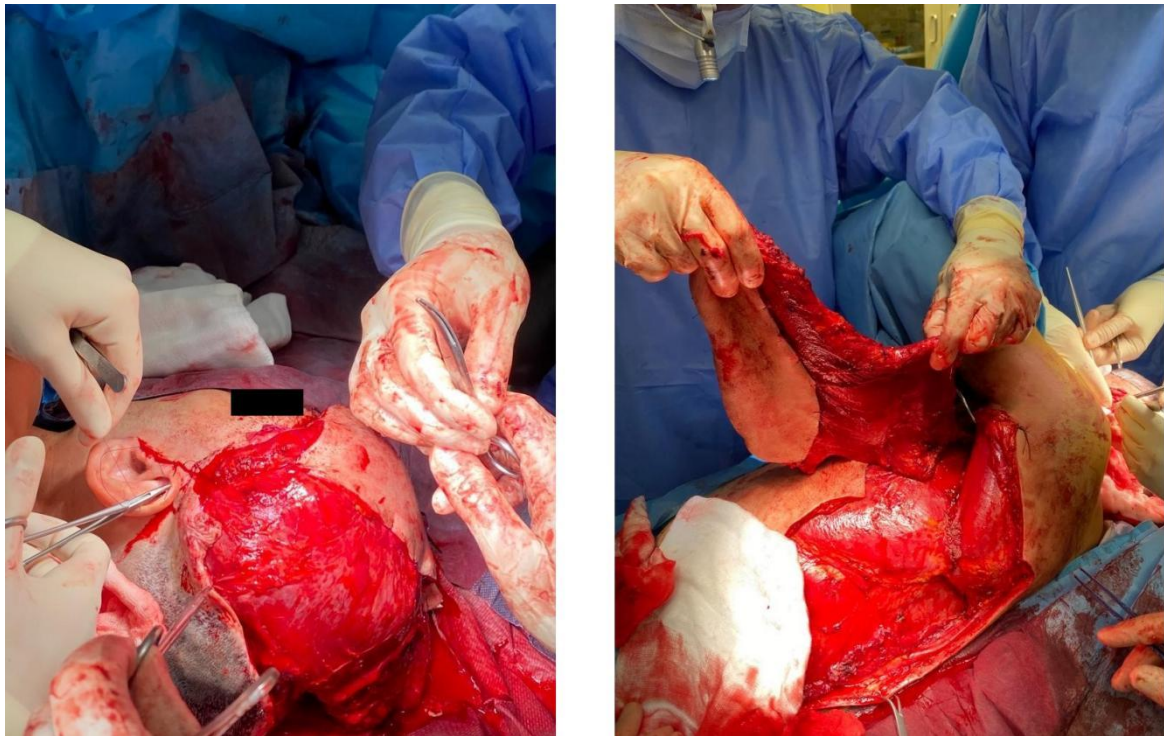


Figure 3 and 4 Flap transplantation

A vascular pedicle was found in the area of the upper edge of the muscle and dissected up to the point of the subscapular artery exit. The vessels were approximately 2 mm in diameter. Then the muscle was cut, forming a flap measuring 20x20 cm, the thickness of the muscle was about 2-3 cm. After the flap was completely dissected, its blood supply was assessed as satisfactory. Capillary recurrence was about 1.5 seconds. The flap was cut from the stalk after the dishes were clipped. Using the operating microscope, preparation of the lobe stalk vessels was performed. Then, a micro-anastomosis of the stumps of the temporal vessels and the stalk of the lobe end-to-end was performed.

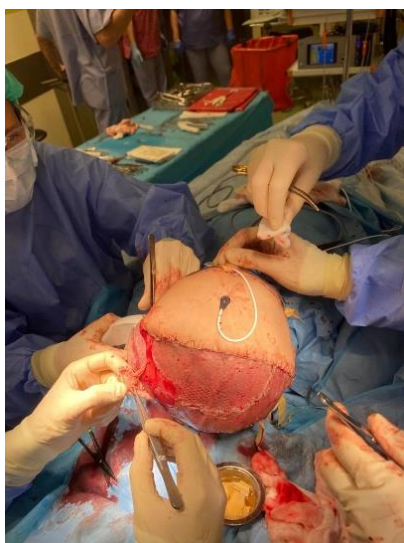

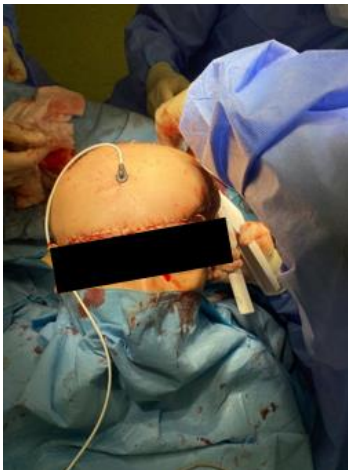Figure 5 Placement of free grafts of skin

A cut around the defect was made and the edges of the wound were mobilized. Deepithelization of the area covered with healed grafts of the skin with intermediate thickness in the area of the defect was performed. A chisel was used to perform

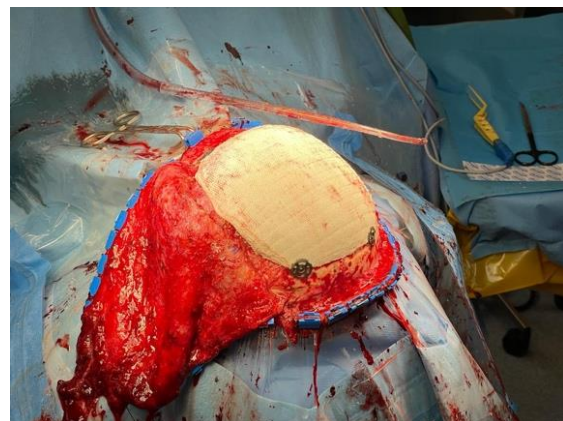


osteonecrectomy of necrotic and dry bone fragments in the area of the temporal edge of the skull bone defect on the left side and in the projection of the frontal sinuses. The flap was placed over the prepared wound, the muscle part was inserted under the released edges of the wound and fixed with sutures. Drains were placed under the flap. The skin island was fixed with single sutures. Free grafts of the intermediately thick skin, taken from the right thigh, were placed on the rest of the muscle and fixed with single sutures. Finally, a dressing in the form of a special gauze weave, saturated with white, soft paraffin and 0.5% solution of chlorhexidine acetate and sterile gauze was made. After the surgery, the patient's dressings were changed every day and the patient was given intravenous antibiotic therapy. After 11 days in the ward, the patient was discharged home.

### **The course of the operation**



*Figure 6 Final result*



*Figure 7 Industrially fabricated cranial prosthesis*

After a few months' time patient was qualified for cranioplastic surgery. Because of the removal of a large portion of the bone, the patient needed a customized implant made from bone substitute material. The surgery was conducted in cooperation with the cosmetic surgery ward of the closest center of oncology to avoid necrosis of the extensive skin graft.

It was performed under general anesthesia, in a supine position with the usage of a cranial stabilization system. The first aim and difficulty of that surgical procedure were to save the vessel anastomoses, nourish the graft and not damage the superior sagittal sinus while making incisions on the skin and muscles. The selected cutting line was mostly overlapping with the one made during the previous surgery. The musculocutaneous flap was carefully dissected from connective tissue covering the dura mater. After peeling back the scalp, the verges of the bone surrounding the defect were exfoliated with a dissector from dura mater, to

prepare a place for the cranial plate. Following that, the prefabricated, customized implant was placed into the bone defect. It was ground to match the edges of the bone and then it was attached to the surrounding cranial bones and secured with titanium clamps. Having it cleaned and disinfected with hydrogen dioxide, the skin was moved back to its original position and after the control of color and temperature of the skin graft, it was closed with a suction drain left in the place of the surgery. The procedure was conducted successfully without any further complications.

## **DISCUSSION**

Scalp damage can be caused by many different insults including tumors, and congenital lesions, as a result of trauma, infections, and as it happened in the presented case –burns.<sup>5</sup> The area of the burn is a limiting factor for the techniques that can be used. The solution used in this case requires a great deal of knowledge and experience due to the possible necrosis of the transplanted tissues. An alternative to the procedure chosen in this case is scalp tissue expansion, applied successfully with satisfactory results on at least 10 patients.<sup>6</sup>

Establishing a good vascularization of the transplanted skin was an important part of the operation due to the high chance of local infection, which could lead to the necessity for reoperation. The occurrence of infection after cranioplasty is reported on average at about 8% of surgeries<sup>7</sup>, but in this case, this complication was avoided.

The surgical treatment used in this case is one of the best that can be offered to those affected by the effects of high-intensity current, as shown by widely reported cases<sup>8-10</sup> but it is important to know about free flaps' disadvantages– extended surgery duration, risk of losing the flap and a worse aesthetic effect because of lack of hair.<sup>5</sup>

The vast majority of skin defects are treated with local flaps of the scalp and sometimes with the addition of skin grafting but when it comes to subtotal and total defects the decision is made depending on the calvaria defect.<sup>5, 8</sup> The single-stage reconstruction may be performed but sometimes the patient requires multiple operations, as it happened in this particular case. It was necessary to resect the bone then cover the defect with a free flap and at the end perform additional reconstructive procedures. In a similar case featured in Robert Hierner's team article, the patient needed a similar sequence of surgeries. Also, the same decision was made to take as a graft a latissimus dorsi flap – because of its big enough area and anatomical reliability. The other possible option in similar cases is to take the greater omentum flap<sup>8</sup>

Burn injuries, although relatively rare, can be a very serious medical condition to deal with, also because some publications suggest an increase in their occurrence during the COVID-19

pandemic, according to lockdown policy<sup>11</sup> or more common usage of alcohol-based sanitizing fluids<sup>12</sup>.

During burn injuries affected by high-voltage electricity, head regions are the second most often reported, whereas lower limb injuries are classified as a minority<sup>3</sup>. In most cases, the injury includes only skin or skin with subcutaneous tissue, which correlated with a better prognosis<sup>13</sup>. Bone inclusion may be more common when the injury region has a small skin-to-bone distance (f.x. hand). To compare, in the present case the injury was deeper, and its operative treatment included osteonecrotomy. Despite this, the patient left a ward specializing in burn injuries treatment after 11 days, which can be explained (for example) by good pre-hospital treatment and fast reaction, because the short time of tissue hypoperfusion enhances the chances of patient survival and smaller cosmetic defect<sup>14</sup>. On the other hand, in the pediatric population, the correlation between prolonged hospitalization and shorter healing period was questioned among all patients with burn injuries<sup>15</sup>.

Scalp bone reconstruction, precognitive for neovascular connections, wasn't used until the presented case, to high-voltage burn injury, according to papers collected by authors. According to the higher occurrence and the need to keep those joints efficient, this (or similar) treatment was used in hand regions, also in pediatric patients<sup>16</sup> – but, on the other hand, used materials didn't include bone substitutes. The vascularisation of the scalp region (in reconstructive surgery) usually is achieved using tissue transplants with big vessels – for example bipediced superficial temporal artery scalp flap used in high-voltage burn injury of calvaria<sup>10,17</sup>, or anterolateral thigh perforator flap and fascia lata transplantation<sup>18,19</sup>. Unfortunately, the method of ensuring tissue perfusion after scalp reconstruction is sometimes unmentioned even in single-centered studies on electrical burn injuries<sup>20</sup>.

The patient after high-voltage burn injury may be exposed to various range of complications, from implants to post-trauma stress disorder<sup>3,21</sup>. According to the author's knowledge, the patient is under the care of a neurosurgery outpatient clinic from intervention, where clinical attention is preserved.

## References

1. Batista Napotnik, T., Polajžer, T. & Miklavčič, D. Cell death due to electroporation - A review. *Bioelectrochemistry* **141**, (2021).

2. Lee, D. H., Desai, M. J. & Gauger, E. M. Electrical Injuries of the Hand and Upper Extremity. *Journal of the American Academy of Orthopaedic Surgeons* **27**, E1–E8 (2019).
3. Shih, J. G., Shahrokhi, S. & Jeschke, M. G. Review of Adult Electrical Burn Injury Outcomes Worldwide: An Analysis of Low-Voltage vs High-Voltage Electrical Injury. *J Burn Care Res* **38**, e293–e298 (2017).
4. Gandhi, G., Parashar, A. & Sharma, R. K. Epidemiology of electrical burns and its impact on quality of life - the developing world scenario. *World J Crit Care Med* **11**, 58 (2022).
5. Chang, K. P. *et al.* Free flap options for reconstruction of complicated scalp and calvarial defects: Report of a series of cases and literature review. *Microsurgery* **30**, 13–18 (2010).
6. Cho, J. Y. *et al.* One Stage Reconstruction of Skull Exposed by Burn Injury Using a Tissue Expansion Technique. *Arch Plast Surg* **39**, 118 (2012).
7. Yoon, T. & Kim, S. W. Scalp Reconstruction and Cranioplasty using the Latissimus Dorsi Musculocutaneous Flap in a Patient with Recurrent Wound Dehiscence Accompanied by MRSA Infection. *Korean Society for Head and Neck Oncology* **38**, 59–63 (2022).
8. Hierner, R., Loon, J. van, Goffin, J. & Calenbergh, F. van. Free latissimus dorsi flap transfer for subtotal scalp and cranium defect reconstruction: Report of 7 cases. *Microsurgery* **27**, 425–428 (2007).
9. Coruh, A. High Voltage Electric Burn Repair of the Forehead by Reverse Flow Temporalis Muscle Flap. *J Burn Care Res* **40**, 373–376 (2019).
10. Jadhav, C. N. & Sharma, R. K. Bipedicled scalp flaps for reconstruction of high-tension electric burns of calvarium. *J Craniofac Surg* **25**, e406–e408 (2014).
11. Bell, A., Christoduolides, N., Ibrahim, S. & O’ Sullivan, J. B. The danger of DIY Do-It-Yourself related full thickness burn injury: Case report during COVID-19 lockdown in Ireland. *Burns Open* **6**, 146–151 (2022).
12. Dahmardehei, M., Rezaiyan, M. K., Safarnejad, F. & Ahmadabadi, A. An unprecedented increase in burn injuries due to alcohol-based hand sanitizers during the COVID-19 outbreak. *Med J Islam Repub Iran* **35**, 1–4 (2021).
13. Bounds, E. J., Khan, M. & Kok, S. J. Electrical Burns. *StatPearls* (2022).



14. Kolbenschlag, J. *et al.* Transplantation of a latissimus dorsi flap after nearly 6 hr of extracorporeal perfusion: A case report. *Microsurgery* **41**, 75–78 (2021).
15. Bhatti, D. S., Chowdhury, R., Ang, K. K. & Greenhowe, J. Paediatric Burns of the Hand: Our Experience Over Three Years. *Cureus* **13**, (2021).
16. Aba, L. *et al.* Gyermekkori, áramégés okozta kézujjsérülések ellátásáról és késői szövődményeiről. *Orv Hetil* **163**, 564–568 (2022).
17. Roehl, K., Geoghegan, J., Herndon, D. N., Patterson, J. & McCauley, R. L. Management of class IV skull burns using the bipediced superficial temporal artery scalp flap. *J Craniofac Surg* **19**, 970–975 (2008).
18. Li, X. Q. *et al.* [Effects of anteriolateral thigh perforator flap and fascia lata transplantation in combination with computed tomography angiography on repair of electrical burn wounds of head with skull exposure and necrosis]. *Zhonghua Shao Shang Za Zhi* **34**, 283–287 (2018).
19. Zhang, W., Xie, W. G., Yang, F., Zhang, W. D. & Chen, L. [Clinical application of lobulated transplantation of free anterolateral thigh perforator flap in the treatment of electric burns of limbs]. *Zhonghua Shao Shang Za Zhi* **35**, 790–797 (2019).
20. Sarygin, P. v., Popov, S. v. & Ukhin, S. A. [Surgical treatment of post-burn defects of face and calvaria]. *Khirurgiia (Sofia)* 17–22 (2020) doi:10.17116/HIRURGIA202008117.
21. Chudasama, S. *et al.* Does voltage predict return to work and neuropsychiatric sequelae following electrical burn injury? *Ann Plast Surg* **64**, 522–525 (2010).