

Lurin I. A., Khomenko I. P., Nehoduiko V. V., Tertyshnyi S. V., Vastyanov R. S. Experimental investigation of animals survival adequacy and efficacy in case of their soft tissues gunshot wounds using the thermometry technique. *Journal of Education, Health and Sport*. 2022;12(1):473-492. eISSN 2391-8306. DOI <http://dx.doi.org/10.12775/JEHS.2022.12.01.040>
<https://apcz.umk.pl/JEHS/article/view/JEHS.2022.12.01.040>
<https://zenodo.org/record/6827055>

The journal has had 40 points in Ministry of Education and Science of Poland parametric evaluation. Annex to the announcement of the Minister of Education and Science of December 1, 2021. No. 32343. Has a Journal's Unique Identifier: 201159. Scientific disciplines assigned: Physical Culture Sciences (Field of Medical sciences and health sciences); Health Sciences (Field of Medical Sciences and Health Sciences).

Punkty Ministerialne z 2019 - aktualny rok 40 punktów. Załącznik do komunikatu Ministra Edukacji i Nauki z dnia 1 grudnia 2021 r. Lp. 32343. Posiada Unikatowy Identyfikator Czasopisma: 201159. Przypisane dyscypliny naukowe: Nauki o kulturze fizycznej (Dziedzina nauk medycznych i nauk o zdrowiu); Nauki o zdrowiu (Dziedzina nauk medycznych i nauk o zdrowiu).

© The Authors 2022;

This article is published with open access at Licensee Open Journal Systems of Nicolaus Copernicus University in Torun, Poland
Open Access. This article is distributed under the terms of the Creative Commons Attribution Noncommercial License which permits any noncommercial use, distribution, and reproduction in any medium, provided the original author(s) and source are credited. This is an open access article licensed under the terms of the Creative Commons Attribution Non commercial license Share alike. (<http://creativecommons.org/licenses/by-nc-sa/4.0/>) which permits unrestricted, non commercial use, distribution and reproduction in any medium, provided the work is properly cited.
The authors declare that there is no conflict of interests regarding the publication of this paper.

Received: 15.12.2021. Revised: 25.12.2021. Accepted: 31.01.2022.

UDK 613.67:617-001.45(075.8)

EXPERIMENTAL INVESTIGATION OF ANIMALS SURVIVAL ADEQUACY AND EFFICACY IN CASE OF THEIR SOFT TISSUES GUNSHOT WOUNDS USING THE THERMOMETRY TECHNIQUE

I. A. Lurin¹, I. P. Khomenko², V. V. Nehoduiko³, S. V. Tertyshnyi^{4,5}, R. S. Vastyanov⁵

¹National Academy of Medical Sciences of Ukraine, Kyiv, Ukraine

²National Military Medical Clinical Center of the Ministry of Defense of Ukraine, Kyiv, Ukraine

³Military Medical Clinical Center of the Northern Region of the Medical Forces Command of the Armed Forces of Ukraine, Kharkiv, Ukraine

⁴Military Medical Clinical Center of the Southern Region. Ministry of Defense, Ukraine, Odesa, Ukraine

⁵Odesa National Medical University, Odesa, Ukraine

Abstract

The problem of gunshot wounds treatment is one of the urgent and incompletely resolved issues of modern surgery. Diagnosis of gunshot wounds is currently not efficient enough. There was a need to improve the content and scope of medical care with the possibility of strengthening its diagnostic chain. The aim of the work is to substantiate experimentally the feasibility and effectiveness of using diagnostic infrared thermometry in

gunshot wounds of the soft tissues of the extremities. Experimental studies were performed under the chronic experimental conditions on Shinshilla breed rabbits which were subjected to gunshot wounds followed by laboratory, morphological and functional examination for 5 days. The animals were divided into 3 groups depending on the type of gunshot wound that was inflicted. The animals were removed from the experiment by the introduction of chloroethyl anesthesia on the 1st, 3rd and 5th days, after which the soft tissues with the capsule surrounding the fragment were subjected to histological and electron microscopic examination. On the 1st day of the study, a significant decrease in the diameter of the blood vessels of the affected area was determined in the group of animals that were subject to injury with firearms and metal fragments from the explosion of a grenade and an improvised explosive device. It was in these groups that the highest mortality rate was registered. Under the specified conditions of injury to the limbs of animals, as well as when injured by a pneumatic weapon with a temperature of fragments of 100 °C, pronounced changes in pulse and respiratory rate were noted. In further studies on rabbits on the 3rd and 5th days of the experiment, the actual results did not differ from those obtained 24 hrs after injury. Those rabbits that survived after the reproduction of various gunshot wounds had the greatest value. The results of their thermometric measurements were evaluated in the dynamics of experimental gunshot wounds and revealed the dependence of animal survival after gunshot wounds on the temperature of the limb in the area of the wound.

There are the following leading criteria in favor of animals further survival after gunshot wounds - the presence of a perforating vessel in the area surrounding the affected space; the size of the diameter of the vessels in the adjacent area; no hemorrhage in the muscle tissue located near the affected area; comparable with normal data of the functional parameters of the animal's body – heart rate, blood oxygen pressure and respiration; thermometry results. The limb thermometry has the important prognostic value after their gunshot wound in terms of experimental animals survival. The correspondence of high thermometry indexes after a gunshot wound vs the higher risk of an animal death is statistically reliable and, accordingly, insignificant thermometric dynamics throughout the experiment is in favor of a positive outcome after injury. It is extremely important to evaluate thermometry data during the first 24 hours after receiving gunshot wounds, since we found out the maximum validity of this method in the early time intervals. All this, with adequate clinical testing and verification, has the most important medical prospects, aimed primarily at saving time for diagnostic measures and procedures. Thermometry allows to judge the

activity and severity of connective tissue inflammation or sclerosis in the lesions of each wound and provides the possibility of clinical application of remote thermography as a non-invasive method of diagnosis and prediction of complications in wounded with gunshot and explosives in various wounds.

Key words: gunshot wounds; soft tissues; thermometry; diagnostic; rabbits survival; lethality; vital functions; technique adequacy and efficacy.

Introduction. Throughout the history of mankind, the progress of surgery was determined primarily by the development of military field surgery. Since ancient times, surgical experience has been gained on the battlefields while helping the wounded. Firearms appearance in the 14th century has qualitatively changed the nature of combat trauma [1, 2]. The problem of treatment of gunshot wounds remains to be one of the most pressing and largely unresolved issues of modern surgery. Given the multifaceted global trends, which get manifested in the increase in the number of illegal firearms, the increase in social, political, ethnic, racial and religious conflicts with the use of firearms, the diagnosis and treatment of gunshot wounds becomes more and more important. This problem is especially important during local and widespread hostilities, peacekeeping missions, anti-terrorist operations, as well as in cases of massive gunshot wounds [3].

Gunshot wounds differed from stab wounds in the severity of the course and the frequent occurrence of complications. Actual problems of military field surgery today are an objective assessment of the severity of a combat injury, the study and implementation of the tactics of programmed multi-stage surgical treatment of the wounded at the stages of medical evacuation, the use of angiotraumatology in combat wounds of blood vessels of all localizations, the dissemination of prevention and treatment methodology infectious complications [4, 5].

The widespread use of firearms with high kinetic energy of bullets and explosive devices of a new generation has led to an increase in the number of severe injuries, characterized by significant damage to soft tissues, blood vessels and comminuted fractures. In the structure of modern combat surgical trauma gunshot wounds of soft tissues are observed in 64.9-68.2 % [6, 7]. The experience of anti-terrorist operation/JFO revealed that in the structure of sanitary losses of surgical profile, wounded with limb injuries make up for 56.7-62.6 % [8]. It is known that 70 % of all gunshot wounds require primary surgical

treatment and subsequent medical care according to the location, volume, severity of the wound, the presence of complications and other related circumstances [9].

The introduction into clinical practice of modern methods of influencing the wound (vacuum treatment, abacterial environment, medical lasers, etc.) has significantly improved the results of providing surgical care to the wounded. However, the mentioned physical methods of treating wounds at the advanced stages of medical evacuation, due to the technical complexity of their implementation in the mass flow of the wounded and injured, have not been widely used [10]. Currently, the diagnosis of gunshot wounds is based on clinical and anamnestic data, data of laboratory and instrumental studies, but existing errors in their diagnosis stimulate the development of an original comprehensive and objective approach to the choice of treatment and diagnostic tactics for such a contingent of wounded [4, 11]. There is a need to improve the content and scope of medical care with the possibility of strengthening its diagnostic chain [8, 12].

In recent years, clinical medicine has been enriched by a large number of diverse methods of diagnosis and treatment of wounded with firearms [12, 13]. In many countries, thermographic examinations are successfully used for early diagnosis and timely treatment of various diseases. This technique allows to precisely determine the surface temperature of a certain anatomical area, changes in which and their dynamics may be a clinical symptom of a pathological process [11, 13, 14].

The experience of providing medical care to wounded servicemen during anti-terrorist operation/JFO proved to be insufficient diagnostic-wise regarding traditional methods of assessing the severity and integrity of anatomical injuries in the wounded, which did not improve treatment outcomes. In these conditions, a promising direction in the diagnosis and surgical treatment of gunshot wounds is the use of thermographic and/or Doppler examination followed by multimodal approach to reconstruction of soft tissues' gunshot defects [15].

Aim of the work: In experimental conditions, to substantiate the feasibility and effectiveness of using diagnostic infrared thermometry in gunshot wounds of the soft tissues of the extremities.

Materials and methods

Shinshilla rabbits in the number of 110 males, aged 6-7 months, with an average weight of 3100 ± 126 g, were used as experimental material and object for the study of gunshot wounds. their biological condition as a result of planned shrapnel wounds at different fixed temperatures of the striking element (fragment).

The content, care and methods of experimental work with animals corresponded to the generally accepted Ukrainian and European norms and rules of conducting experiments with vertebrates for scientific purposes.

The animals were injured with airguns and firearms and during the process of ammunition blasting in a specialized shooting range (Safari shooting range, Latek LLC) and at the training ground (Ministry of Internal Affairs training ground, Ruska Lozova village, Kharkiv region) in compliance with generally accepted safety measures. The wounds were inflicted by a shard of low quality steel, measuring 5-6×4 mm, weighing 0.36-0.52 grams from a distance at which blind injuries were received.

Animals were labeled (on the inner surface of the auricle), fixed in the machine and anesthetized before and after the study with nalbuphine at a dose of 0.3 mg/kg. The sites of the alleged hip injury and the opposite symmetrical area were shaved an hour before the study.

There were 3 groups of experimental studies: 1 group (n=54) – wounds from airguns with single metal fragments at a temperature that coincided with the ambient temperature, temperature 50°C and 100°C (respectively, 18 animals in each series of observations). Group 2 (n=18) – gunshot wounds. Group 3 (n=32) – wounds by metal fragments from a grenade explosion and an improvised explosive device. The control animals were the 6 of them that were not injured.

The basic arrangement of the place of infliction of a gunshot wound is shown in Fig. 1 where each could see the special guide-device localization for gunshot wounds modelling.




Fig. 1. The place organization and method of a gunshot wound infliction. Fragments A and B – guide-device for gunshot wounds modelling.

The full layout of our original device and the arrangement of its components at the experimental site you can see on Fig. 2.




Fig. 2. The final view and all details composition in the original device of a gunshot wound infliction.

Fragment A – RGD-5 attached directly in front of the guide-device;


Fragment B – method of application and complete view of the site of gunshot wound to experimental animals.

Animals were euthonized using chloroethyl anesthesia on the 1st, the 3rd and the 5th days, after which the soft tissues with a capsule surrounding the fragment were subjected to histological and electron microscopic examination. The back thigh muscles were examined.

Measurements of the temperature of the fragment, the area of the wound (thigh) and the opposite area (thigh) were performed using a thermal imager “Fluke Ti125” (USA) and an IRTIS 2000C thermograph (RF, Fig. 3).

Fragments A and B - thermometry of the area of experimental animal limb soft tissues gunshot injuries.

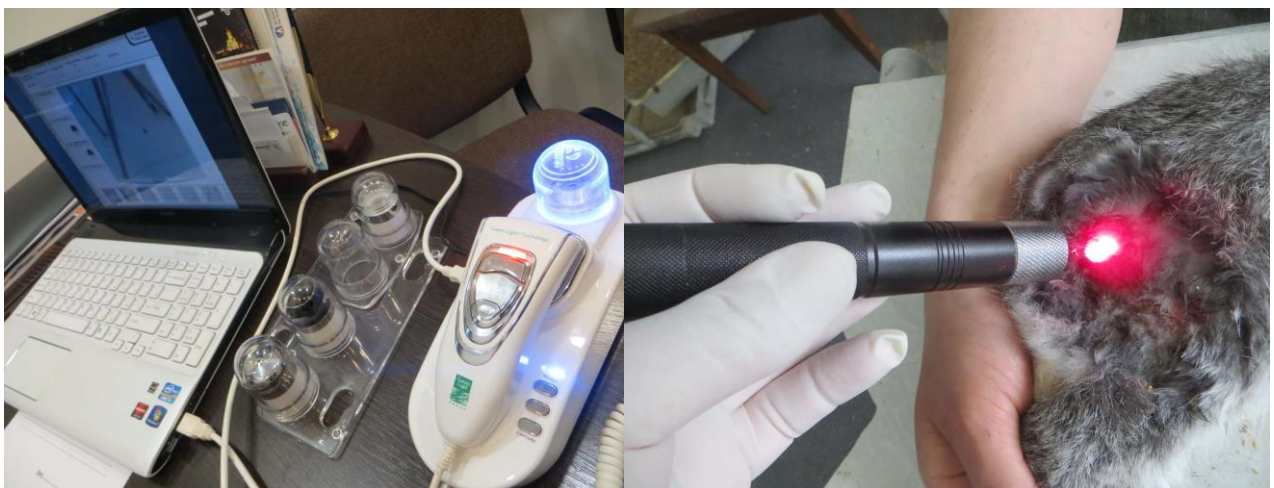The main indicator of local temperature was the option when the readings of the devices matched. In living tissues of experimental animals, the degree of ischemia and destruction was assessed by examination using an optical diagnostic device “Green Light” with software and ×60 nozzle (Fig. 4).



A

B

Fig. 3. Inspection of the area of gunshot wounds of soft tissues of experimental animals.



A

B

Fig. 4. Determining the presence of ischemia and the severity of ischemic changes in experimental animals after injuries inflicted on them.

Fragments A and B – determination of ischemia and destruction degree of experimental animal limb soft tissues gunshot injuries.

Criteria for assessing changes in microcirculation detected during the experimental study were as follows: the presence and number of hemorrhages, narrowing of the capillary lumen.

The presence of an advantage or equality of one of the two features (hemorrhage or narrowing of the capillary lumen) was sufficient for the interpretation of data and their analysis. Changes in tissue were assessed as minor, moderate and severe depending on the degree of ischemia. Moderate changes were characterized by the presence of multiple hemorrhages and narrowing of the capillary lumen within 0.3-0.5 mm. The expressed changes were characterized by the presence of multiple drainage hemorrhages and narrowing of the capillary lumen less than 0.3 mm.

Our results were calculated statistically using non-parametrical Krushkal-Wallis statistical criterion. $p < 0.05$ was chosen as the minimal statistical probability.

Results

Examination of the affected areas in rabbits of the control group showed no hemorrhage in the unaltered muscle tissue surrounding the wound site, and the diameter of the capillaries was equal to 0.90 ± 0.06 mm (Table 1).

In the group of rabbits inflicted with a gunshot wound using a pneumatic weapon equal to an ambient temperature, 1 day later the diameter of the capillaries was slightly increased compared with the corresponding control index and was equal to 0.88 ± 0.06 mm. There were no signs of hemorrhage in the surrounding muscle tissue, and 16 of 18 animals showed a perforating vessel in the area surrounding the wound. Indexes of rabbit paw temperature in the area of the wound, pulse, blood oxygen tension and respiration rate did not differ significantly before and after the gunshot wound ($p > 0.05$). One of the two animals in which we failed to find the perforating vessel died.

In the group of rabbits 1 day after a gunshot wound with a pneumatic weapon with a temperature of 50 °C the diameter of the capillaries was 5.6 % less compared with the same control index ($p > 0.05$).

There were no signs of hemorrhage in the surrounding muscle tissue, and 15 of 18 animals showed a perforating vessel in the area surrounding the wound. Indicators of rabbit paw temperature in the wound area, blood oxygen tension and respiration rate were comparable before and after gunshot wounds ($p > 0.05$).

Table 1.

Changes of morphological parameters and functional indexes in experimental rabbits 24 hrs after gunshot wounds

Groups (No of animals)	The presence of haemo-rrhages	Vessels diameter, mm	The presence of a perfo-rating vessel	Lethality, %	Temperature, °C		Pulse rate, per minute		□O ₂ mm Hg		Respiration, per minute	
					before	after	before	after	before	after	before	after
Control (n=6)	-	0.91±0.06	Absent	0	36.4±3.5	-	84.4±7.6	-	88.1±6.4	-	86.2±8.0	-
N1 T=env (n=18)	-	0.85±0.06	16/18 88.9 %	1/18 5.6	36.4±3.7	37.7±4.1	85.7±8.4	91.8±8.8	88.1±6.4	89.8±7.3	86.2±8.0	106.9±8.7
N1 T=50 °C (n=18)	-	0.83±0.04	15/18 83.3 %	2/18 11.1	36.1±3.6	38.6±3.7	82.9±7.6	106.9±8.9*	88.1±6.4	91.2±8.1	86.2±8.0	109.3±8.6
N1 T=100 °C (n=18)	+	0.79±0.08	13/18 72.2 %	3/18 16.7	35.9±3.4	38.8±3.9	83.3±7.7	109.0±8.9*	88.1±6.4	91.6±7.9	86.2±8.0	113.1±8.9*
N2 (n=18)	-	0.76±0.07	12/18 66.7 %	5/18 27.8	36.2±3.4	37.6±3.8	83.5±8.1	108.7±8.6*	88.1±6.4	94.2±8.3	86.2±8.0	112.7±8.6*
N3 (n=32)	+	0.72±0.08#	26/32 81.3 %	7/32 21.9	36.0±3.6	38.6±3.6	84.1±8.3	111.6±9.1*	88.1±6.4	96.1±8.6	86.2±8.0	113.6±8.9*

Notes: # – p<0.05 – significant differences of the studied parameters in comparison with those in the control group of animals; * – p<0.05 – significant differences of the studied parameters in comparison with those obtained before the gunshot wounds (in both cases – Krushkal-Wallis statistical criterion)

The heart rate of the animals after injury was 29 % higher than the same index before injury ($p < 0.05$). Two rabbits died out of the three in which we found no perforating vessel.

1 day after a gunshot wound in rabbits with a pneumatic weapon with a temperature of 100 °C the diameter of the capillaries was 13.3 % less pertaining the same index in the control observations ($p > 0.05$). Signs of hemorrhage in the surrounding muscle tissue were observed in 14 of 18 animals, and 13 rabbits were found to have a perforating vessel in the area surrounding the wound area. Pulse and respiration indices differed significantly (by 30.9 % and 31.2 %, respectively, $p < 0.05$) before and after gunshot wounds. Three of the five rabbits in which we found no perforating vessel died.

1 day in rabbits of the 2nd group after a gunshot wound modeling the diameter of the capillaries was 20 % less compared with the same control data ($p < 0.05$). Signs of hemorrhage in the surrounding muscle tissue were observed in only 5 of 18 animals, and 12 rabbits (66.7 %) had a perforating vessel in the area surrounding the wound area. Pulse and respiration rates of animals before and after the gunshot wound differed significantly (by 30.2 % and 30.7 %, respectively, $p < 0.05$). Five rabbits died out of the six in which we did not detect the presence of a perforating vessel.

Observations of group 3 rabbits one day after injury revealed signs of hemorrhage in 23 animals out of 32. The diameter of capillaries in muscle tissue was 0.75 ± 0.05 mm, which was 25.6 % less compared to that in the control ($p < 0.05$). In 26 rabbits (81.3 %) the presence of a perforating vessel was found in the area surrounding the wound area. Indicators of rabbit paw temperature in the area of injury and blood oxygen tension did not differ significantly before and after the gunshot wound ($p > 0.05$). Pulse and respiration rates of animals before and after gunshot wounds differed by 32.7 % and 31.8 %, respectively ($p < 0.05$). 7 rabbits died, including 4 animals were among the six in which we did not detect the presence of a perforating vessel.

The actual results obtained on the 3rd day of the trial did not differ from those received 24 hrs after injury. Thus, 3 days after the application of gunshot injuries to rabbits, the size of the vessels in animals of all groups differed by an average of 3.3%-6.7%, which did not differ significantly from that in the control group of animals ($p > 0.05$, Table 2).

We revealed the perforating vessel in the vast majority of observations in each of the experimental groups of animals, however, our efforts were ineffective in 2 animals out of 15 of the 1st group after being wounded by a pneumatic weapon at a temperature of 100 °C. There was no lethality of animals in this time interval.

Table 2.

Changes of morphological parameters and functional indexes in experimental rabbits 3 days after gunshot wounds

Groups (No of animals)	The presence of haemo-rrhages	Vessels diameter, mm	The presence of a perfo-rating vessel	Lethality, %	Temperature, °C		Pulse rate, per minute		□O ₂ mm Hg		Respiration, per minute	
					before	after	before	after	before	after	before	after
Control (n=6)	-	0.90±0.08	Absent	0	36.4±3.5	-	84.4±7.6	-	88.1±6.4	-	86.2±8.0	-
N1 T=env (n=17)	-	0.86±0.08	16/17 94.1%	0	36.4±3.7	37.2±3.7	85.7±8.4	93.2±8.7	88.1±6.4	86.6±7.1	86.2±8.0	86.0±8.0
N1 T=50 °C (n=16)	-	0.84±0.08	15/16 93.8%	0	36.1±3.6	37.8±3.8	82.9±7.6	91.7±8.6	88.1±6.4	87.4±8.3	86.2±8.0	85.5±7.8
N1 T=100 °C (n=15)	-	0.84±0.07	13/15 86.7%	0	35.9±3.4	37.9±3.7	83.3±7.7	92.7±8.8	88.1±6.4	86.3±8.5	86.2±8.0	86.0±8.0
N2 (n=13)	-	0.86±0.07	12/13 92.3%	0	36.2±3.4	37.1±3.6	83.5±8.1	91.9±8.9	88.1±6.4	83.9±7.9	86.2±8.0	83.0±7.5
N3 (n=25)	+	0.87±0.08	24/25 96.0%	0	36.0±3.6	37.9±3.8	84.1±8.3	93.1±9.0	88.1±6.4	85.6±7.9	86.2±8.0	84.0±8.0

Table 3.

Changes of morphological parameters and functional indexes in experimental rabbits 5 days after gunshot wounds

Groups (No of animals)	The presence of haemo-rrhages	Vessels diameter, mm	The presence of a perfo-rating vessel	Letha- lity, %	Temperature, °C		Pulse rate, per minute		□O ₂ mm Hg		Respiration, per minute	
					before	after	before	after	before	after	before	after
Control (n=6)	-	0.88±0.06	Absent	0	36.4±3.5	-	84.4±7.6	-	88.1±6.4	-	86.2±8.0	-
N1 T=env (n=17)	-	0.84±0.07	17/17 100%	0	36.4±3.7	36.9±3.6	85.7±8.4	88.9±8.5	88.1±6.4	85.9±7.3	86.2±8.0	84.0±7.6
N1 T=50 °C (n=16)	-	0.86±0.06	16/16 100%	0	36.1±3.6	36.8±3.5	82.9±7.6	87.7±8.7	88.1±6.4	86.8±8.1	86.2±8.0	84.0±7.4
N1 T=100 °C (n=15)	-	0.86±0.07	14/15 93.3%	1/15 6.7	35.9±3.4	36.7±3.9	83.3±7.7	90.6±8.5	88.1±6.4	85.7±8.2	86.2±8.0	85.5±6.8
N2 (n=13)	-	0.82±0.08	13/13 100%	0	36.2±3.4	37.0±3.6	83.5±8.1	89.4±8.7	88.1±6.4	81.8±8.4	86.2±8.0	84.5±6.5
N3 (n=25)	-	0.84±0.08	24/25 96.0%	2/25 8.0	36.0±3.6	37.4±3.7	84.1±8.3	91.1±8.9	88.1±6.4	84.3±8.1	86.2±8.0	86.5±6.0

Our studies of the main vital functions of rabbits - temperature, pulse, blood tension and respiratory rate - revealed indicators that turned out to be identical to those before the moment of infliction of gunshot wounds (in all cases $p > 0.05$, Table 2).

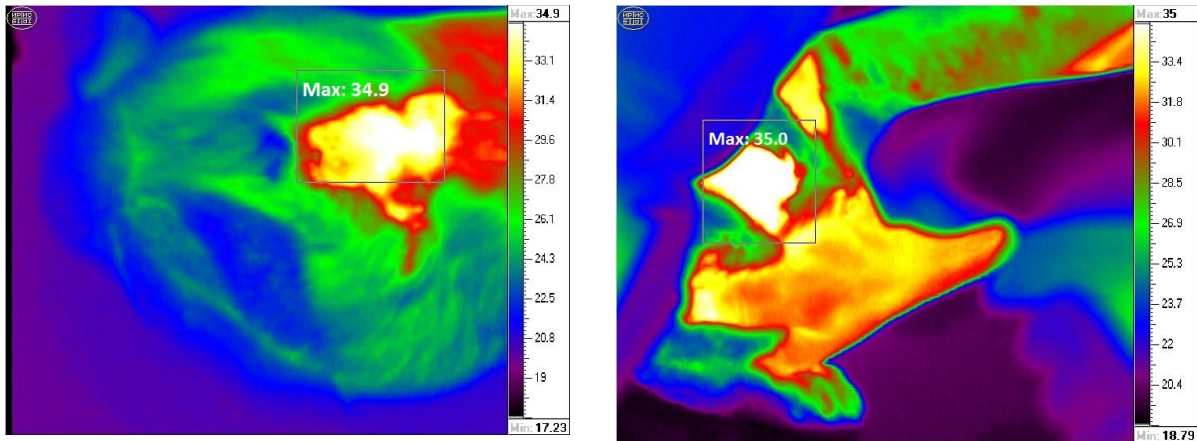
Similarly, the analysis of the statistical indicators obtained by us did not reveal significant differences 5 days after the infliction of gunshot injuries to rabbits in the experimental groups. In this time interval, the size of the vessels in animals of all groups differed by an average of 2.3%-6.8%, which did not differ significantly from that in the control group of animals (in all cases $p > 0.05$, Table 3).

On the 5th day of the trial 1 more rabbit died in group N1 with a gunshot wound with a pneumatic weapon with a temperature of 100 °C as well as 2 rabbits from group N3. Lethality appeared and slightly increased in this time interval, however, we associate this with the main vital indicators dysfunction during the 5-day period of the experiment. It is clearly seen that there are no statistically proven changes in the studied parameters in rabbits compared with those before the infliction of gunshot injuries (in all cases $p > 0.05$, Table 3).

Analysis of primary data big mass obtained allowed us to conclude that a critical time interval under these original experimental conditions is 24 hours after the infliction of a gunshot wound. It is during this time interval, we believe, that it is extremely important to carry out the most effective set of diagnostic measures to assess the severity of gunshot injury and its subsequent effective treatment.

The greatest validity were those rabbits that survived after a variety of gunshot wounds modeling We appreciated the results of their thermometric measurements in the dynamics of experimental gunshot wounds. Fig. 5 (fragments A and B) shows the thermometric study results of rabbit B paw 1 day after the gunshot wound. Its temperature increased from 34.9 °C to 35.0 °C. Morphological examination of muscle tissue surrounding the wound area identified a perforating vessel, which provided a favorable prognosis for this animal survival.

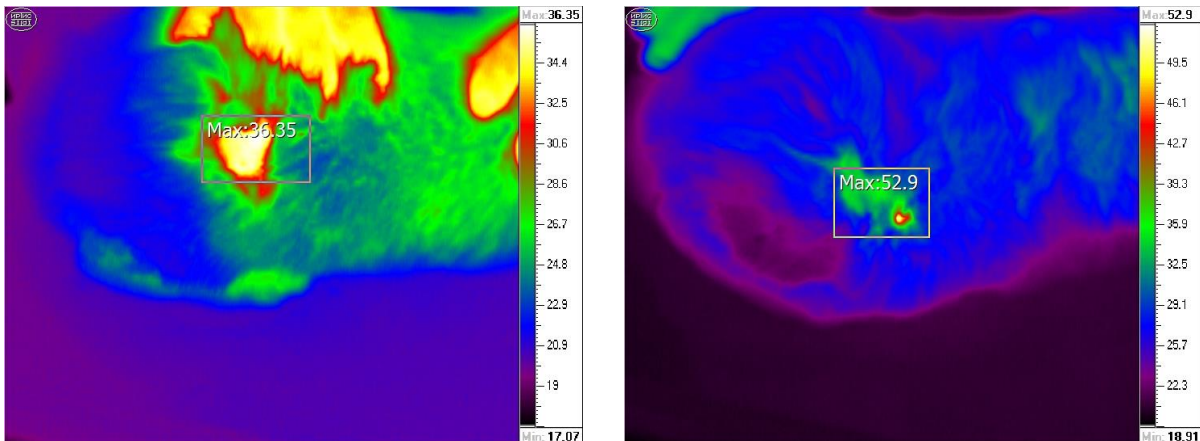
1 day after rabbit V wounding using pneumatic weapon with a temperature of 50 °C the temperature of his paw being equal to 36.4 °C reached 52.9 °C (Fig. 6). The animal survived and we found a perforating vessel during its morphological examination.



A

B

Fig. 5. Rabbit B paw temperature according to thermal imager data before (fragment A) and after (fragment B) gunshot wounds.



A

B

Fig. 6. Rabbit V paw temperature according to thermal imager data before (fragment A) and after (fragment B) gunshot wounds.

During the rabbit's K paw thermometric examination one day after the pneumatic weapon wound with a temperature of 100 °C an increase in temperature from 35.2 °C to 99.0 °C was registered (Fig. 7). Morphological examination of the area of muscle tissue surrounding the wound area did not reveal a perforating vessel. This rabbit died during the 1st day of the experiment.

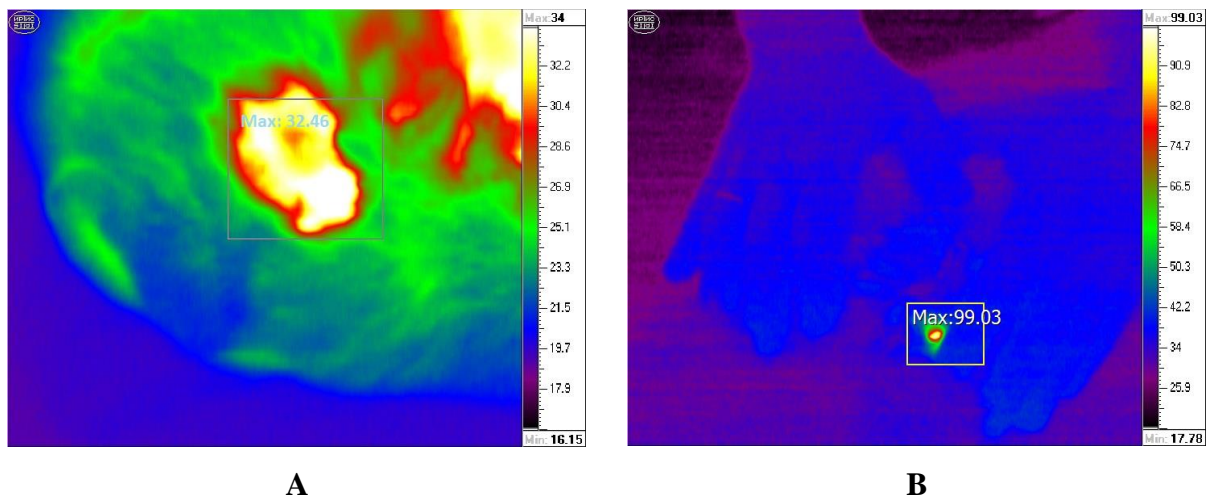


Fig. 7. Rabbit K paw temperature according to thermal imager data before (fragment A) and after (fragment B) gunshot wounds.

One day after rabbit F wounding with a firearm the temperature of his paw increased from 35.2 °C to 37.4 °C (Fig. 8). The animal survived and we found a perforating vessel during its morphological examination.

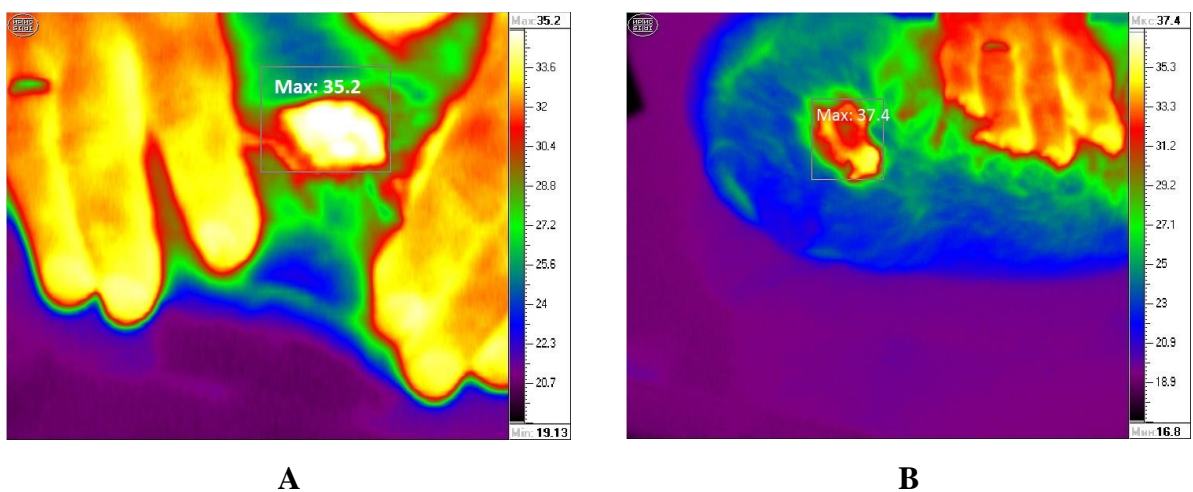



Fig. 8. Rabbit F paw temperature according to thermal imager data before (fragment A) and after (fragment B) gunshot wounds.

The thermometric data of the rest animals that survived 1 day after the gunshot wound on the 3rd and 5th days of the trial did not differ significantly from such temperatures before the experiment. This we can demonstrate on the example of rabbit M which paw temperature after the gunshot wound was equal to 35.8 °C on the 3rd day of the trial and was equal to 33.9 °C on the 5th day of the trial (Fig. 9).



A

B

Fig. 9. Rabbit M paw temperature according to thermal imager data 3 day (fragment A) and 5 days (fragment B) after the gunshot wounds.

A similar result with a slight change in paw temperature from 31.2 °C to 29.2 °C was recorded by us when examining rabbit D during 5 days of the experiment on inflicting a gunshot wound (Fig. 10).



A

B

Fig. 10. Rabbit D paw temperature according to thermal imager data 3 day (fragment A) and 5 days (fragment B) after the gunshot wounds.

In the prevailing amount of experimental observations one could proposed the following leading criteria in favor of animals further survival after gunshot wounds - the presence of a perforating vessel in the area surrounding the affected space; the size of the diameter of the vessels in the adjacent area; no hemorrhage in the muscle tissue located near the affected area; comparable with normal data of the functional parameters of the animal's body - heart rate, blood oxygen pressure and respiration; thermometry results. Moreover, the latter in the vast majority of cases correlated with experimental animals mortality and/or survival.

Discussion

Therefore, our experimental research and the results obtained are of direct importance in terms of their practical implementation. First, a large amount of factual biological and statistical material has established and defined criteria that most effectively contribute to animals survival under different types of experimental gunshot wounds. It is proved that both morphological and functional indicators have a positive effect on the survival of animals after a gunshot wound. The first include: (a) the presence of a perforating vessel in the area surrounding the affected area; (b) the diameter of the vessels in the adjacent area and (c) the absence of hemorrhage in the muscle tissue adjacent to the affected area. Functional criteria that determine the animals' survival include the temperature of the injured limb, blood oxygen tension, pulse and respiratory rates.

Secondly, we emphasize the limb thermometry important prognostic value after their gunshot wound in terms of experimental animals survival. The correspondence of high thermometry indexes after a gunshot wound vs the higher risk of an animal death is statistically reliable and, accordingly, insignificant thermometric dynamics throughout the experiment is in favor of a positive outcome after injury. We have chosen this fact for everyday clinical use in surgical practice because in the case of thermometry, based on the results of experimental studies, we are confident to determine the prognosis of gunshot wounds in each case [16]. Basing on the results of thermometric studies when patients come to the clinic, we also determine the tactics of their comprehensive treatment and subsequent rehabilitation and rehabilitation activities [8].

Our data and the reasonability of their clinical use have some consistency with clinical data, in which the presence of a perforated vessel (vessels) and determining the blood flow velocity in it (in them) is the key for the damaged area rapid and highly effective recovery [12]. The use of thermometric devices allows, in addition to detecting a complete

thermometric picture of the damaged area, to assess the ability of deep vessels to provide perfusion to the specified area with impaired morpho-functional properties as the result of the gunshot damage.

Resuming, it should be noted that thermometry for diagnostic purposes use in soft tissues gunshot wounds allows to justify the temperature response over the anatomical area of the gunshot defect and/or lesion and its dependence on the severity and/or prevalence of the lesion. All this, with adequate clinical testing and verification, has the most important medical prospects, aimed primarily at saving time for diagnostic measures and procedures. And in the future, we have the opportunity to significantly modify the stages of medical evacuation for military personnel who received soft tissue injuries in order to provide them with the most effective medical care as soon as possible and implement the most effective rehabilitation measures.

The resulting mass of experimental material has all the prospects for clinical use, which can be a prerequisite for improving and detailing the diagnosis, early prediction of possible serious purulent-inflammatory and septic complications and the choice of adequate therapeutic surgical tactics, choice of complex therapy or prevention of this type of fire.

Thermometry allows to judge the activity and severity of connective tissue inflammation or sclerosis in the lesions of each wound and provides the possibility of clinical application of remote thermography as a non-invasive method of diagnosis and prediction of complications in wounded with gunshot and explosives in various wounds.

Conclusions

1. There are the following leading criteria in favor of animals further survival after gunshot wounds - the presence of a perforating vessel in the area surrounding the affected space; the size of the diameter of the vessels in the adjacent area; no hemorrhage in the muscle tissue located near the affected area; comparable with normal data of the functional parameters of the animal's body – heart rate, blood oxygen pressure and respiration; thermometry results.

2. The limb thermometry has the important prognostic value after their gunshot wound in terms of experimental animals survival. The correspondence of high thermometry indexes after a gunshot wound vs the higher risk of an animal death is statistically reliable and, accordingly, insignificant thermometric dynamics throughout the experiment is in favor of a positive outcome after injury.

3. It is extremely important to evaluate thermometry data during the first 24 hours after receiving gunshot wounds, since we found out the maximum validity of this method in the early time intervals. All this, with adequate clinical testing and verification, has the most important medical prospects, aimed primarily at saving time for diagnostic measures and procedures.

4. The resulting mass of experimental material has all the prospects for clinical use, which can be a prerequisite for improving and detailing the diagnosis, early prediction of possible serious purulent-inflammatory and septic complications and the choice of adequate therapeutic surgical tactics, choice of complex therapy or prevention of this type of fire.

5. Thermometry allows to judge the activity and severity of connective tissue inflammation or sclerosis in the lesions of each wound and provides the possibility of clinical application of remote thermography as a non-invasive method of diagnosis and prediction of complications in wounded with gunshot and explosives in various wounds.

6. Basing on the results of thermometric studies when patients come to the clinic, we also determine the tactics of their comprehensive treatment and subsequent rehabilitation and rehabilitation activities.

References

1. Boyko V.V., Lisovyi V.M., Makarov V.V. Selected lectures on military field surgery. Kharkiv, 2018: 211. [In Ukrainian].
2. Bykov I.Yu., Efimenko N.A., Humanenko E.K., Samokhvalov I.M. Modern combat surgical pathology. The size and structure of sanitary losses of the surgical profile / Military field surgery: national guidance / Eds. I.Yu. Bykova, N.A. Efimenko, E.K. Humanenko. – M : GEOTAR-Media, 2009: 40-50. [In Russian].
3. Military field surgery: a textbook /Ya.L. Zarutskyi, V.Ya. Bily, V.M. Denysenko et al. Eds. Ya.L. Zarutskyi, V.Ya. Bily. Kyiv : PHOENIX, 2018: 203-211; 369-401. [In Ukrainian].
4. Bily V.Ya., Verba A.V., Badyuk M.I. Modern approaches to building a system of medical and evacuation support as the basis of medical support for troops in a special period. Science and Defense. 2016; 2: 34–41. [In Ukrainian].
5. Bulavin V.V., Zhdanko I.M., Vorona A.A. et al. Peculiarities of providing medical care to the wounded during the counter-terrorist operation in the Republic of Dagestan (1999). Military Medical Journal. 2012; 7: 50–52. [In Russian].

6. Gerasimenko O.S., Yenin R.V., Shepitko K.V., Gerasimenko S.D. Optimizing the diagnosis of gunshot wounds to the abdomen in combat conditions. *The World of Medicine and Biology*. 2019; 1(67): 38-42 [In Ukrainian].
7. Lurin I.A., Galushka A.M. Strategic defense bulletin of Ukraine: military medicine. Medical support of an anti-terrorist operation - scientific-practical and medical-social aspects. – Kyiv: SE “NVC “Priority”, 2016: 35-41 [In Ukrainian].
8. Gunshot wounds of soft tissues (Experience of anti-terrorist operation / Operation of the United Forces). Ed. by V.I. Tsybalyuk. Kharkiv : Collegium, 2020: 400 [In Ukrainian].
9. Bily V.Ya., Verba A.V., Badyuk M.I. The relevance of the “platinum minute” and "golden hour" for the modern system of medical and evacuation measures. *Ukraine. Health of the Nation*. 2016; 40 (4): 19–26. [In Ukrainian].
10. Mishalov V.D., Mykhailenko O.V., Khokholeva T.V., Petroshak O.Y. Forensic examination of gunshot wounds: monograph (updated edition). Kyiv, 2019: 303. [in Ukrainian]
11. Hutchinson A.J., Kusnezov N.A., Dunn J.C. et al. Epidemiology of gunshot wounds to the hand. *Hand Surg Rehabil*. 2019; 38(1): 14-19.
12. Kehrer A., Lonic D., Heidekrueger P. et al. Feasibility study of preoperative microvessel evaluation and characterization in perforator flaps using various modes of color-coded duplex sonography (CCDS). *Microsurgery*. 2020; 40(7): 750-759.
13. Korol' S.O. Analysis of the surgical treatment of the wounded with fractures of the leg bones during an anti-terrorist operation. *Orthopedia, traumatology and prosthetics*. 2016; 2: 10-14 [In Ukrainian].
14. Thatcher J.E., Squiers J.J., Kanick S.C. et al. Imaging Techniques for Clinical Burn Assessment with a Focus on Multispectral Imaging. *Adv Wound Care (New Rochelle)*. 2016; 5(8): 360-378.
15. Kolacz S., Moderhak M., Jankau J. New perspective on the in vivo use of cold stress dynamic thermography in integumental reconstruction with the use of skin-muscle flaps. *J Surg Res*. 2017; 212: 68-76.
16. Khomenko I.P., Tertyshnyi S.V., Vastyanov R.S., Talalayev K.O. Soft tissues gunshot defects ultrasound investigation use in reconstructive-restorative surgery. *World of Medicine and Biology*. 2021; 3(77): 169-174.