

Kryzhevskiy Yevhenii, Bilyayeva Olga, Rykov Sergiy, Shargorodska Iryna, Osadchaya Oksana, Barinov Yurii, Petrovsky Mykola. Study of new pathogenetic mechanisms of diabetic retinopathy development in patients with diabetic foot syndrome. Journal of Education, Health and Sport. 2021;11(04): 233-246. eISSN 2391-8306. DOI <http://dx.doi.org/10.12775/JEHS.2021.11.04.024> <https://apcz.umk.pl/czasopisma/index.php/JEHS/article/view/JEHS.2021.11.04.024> <https://zenodo.org/record/5338550>

The journal has had 5 points in Ministry of Science and Higher Education parametric evaluation. § 8. 2) and § 12. 1. 2) 22.02.2019.
© The Authors 2021;

This article is published with open access at Licensee Open Journal Systems of Nicolaus Copernicus University in Torun, Poland
Open Access. This article is distributed under the terms of the Creative Commons Attribution Noncommercial License which permits any noncommercial use, distribution, and reproduction in any medium, provided the original author (s) and source are credited. This is an open access article licensed under the terms of the Creative Commons Attribution Non commercial license Share alike. (<http://creativecommons.org/licenses/by-nc-sa/4.0/>) which permits unrestricted, non commercial use, distribution and reproduction in any medium, provided the work is properly cited.
The authors declare that there is no conflict of interests regarding the publication of this paper.

Received: 26.02.2021. Revised: 31.03.2021. Accepted: 30.04.2021.

Study of new pathogenetic mechanisms of diabetic retinopathy development in patients with diabetic foot syndrome

Yevhenii Kryzhevskiy¹, Olga Bilyayeva¹, Sergiy Rykov¹, Iryna Shargorodska¹, Oksana Osadchaya², Yurii Barinov¹, Mykola Petrovsky³

¹Shupyk National Healthcare University of Ukraine, Kyiv, Ukraine

²National University of Physical Education and Sports of Ukraine, Kyiv, Ukraine

³Taras Shevchenko National University of Kyiv, Ukraine

Yevhenii Kryzhevskiy ORCID: 0000-0003-1403-1476
Olga Bilyayeva ORCID: 0000-0003-2862-0423
Sergiy Rykov ORCID: 0000-0002-3495-7471
Iryna Shargorodska ORCID: 0000-0001-8958-1849
Oksana Osadchaya ORCID: 0000-0001-5883-425X
Yurii Barinov ORCID: 0000-0001-6562-0428
Mykola Petrovsky ORCID: 0000-0003-3267-7123

Abstract

Introduction and purpose. Diabetes is one of the underlying causes of blindness and other long-term negative consequences that significantly affect patients' quality of life. The study aimed to determine the indicators characterizing the pathogenetic mechanisms of the development of vascular dysfunction, in particular diabetic retinopathy (DR), and the relationship of these changes with nitric oxide. **Material and methods.** There were 2114 patients with various surgical diseases under observation (including 1073 patients with purulent-septic soft tissue diseases), among them there were 193 patients with type 2 diabetes mellitus (DM) and 134 patients with Wagner stage 2-5 diabetic foot syndrome (DFS) and diabetic retinopathy in the main group (268 eyes). The comparison group included 59 patients

(118 eyes) of the corresponding age with DM without DFS and DR. Both groups were the same in age and gender. **Results.** The level of the end products of nitric oxide metabolism in peripheral blood was found to be 1.78 times ($p<0.01$) higher compared with patients without DR. A decrease in the activity of superoxide dismutase (SOD) in patients with DR was by 1.56 times ($p<0.01$) lower relative to the comparison group. The content of thiobarbituric acid (TBA)-active products in the peripheral blood of patients of the main group exceeded by 1.58 times ($p <0.01$) the reference values of patients without DR. When determining the content of S-nitrosithiols, an increase in these indicators in the main group was found to be 2.38 times ($p<0.01$). Patients in the main group with DR also showed a 5.13-fold ($p<0.001$) increase in peripheral blood homocysteine concentration. NO is known to have both positive and harmful effects depending on its concentration. On the one hand, NO causes relaxation of blood vessels by reducing blood pressure, prevents platelet aggregation and adhesion, limits LDL cholesterol oxidation, suppresses smooth muscle cell proliferation, and reduces the expression of proinflammatory genes that are associated with atherogenesis. It is known that NO can have both positive and harmful effects, depending on its concentration. On the one hand, NO causes relaxation of blood vessels, reducing blood pressure, prevents platelet aggregation and adhesion, limits the oxidation of LDL cholesterol, suppresses the proliferation of smooth muscle cells, and reduces the expression of pro-inflammatory genes that are associated with atherogenesis. On the other hand, NO interacts with O_2^- , leading to the inactivation of NO and the production of peroxynitrite, which post-transcriptionally modifies proteins and negatively affects their function. This can contribute to endothelial dysfunction by stimulating the production of inflammatory mediators and lipid peroxidation and thus increasing cell permeability. **Conclusions.** The findings show that the patients with diabetes mellitus complicated by retinopathy and DFS had a significant increase in the content of nitric oxide in the peripheral blood, the cause of which is hyperglycemia. The use of an intercellular mediator (nitric oxide), which contributes to the physiological regulation of the hemodynamics of the eye, protects vascular endothelial cells from pathogenic factors of ischemia, will help clinicians choose an effective pharmacological therapy appropriate for a particular patient and a particular eye.

Keywords: diabetes mellitus; diabetic retinopathy; diabetic foot syndrome; nitric oxide; thiobarbituric acid; diabetic maculopathy; diabetic macular edema.

Introduction

There are over 480 million patients with diabetes worldwide, and experts predict that their number will almost double by 2030. Diabetes mellitus is considered a pandemic of the 21st century [1] being one of the most chronic and dangerous diseases. Its prevalence among the adult population is about 9.2% and is steadily increasing, especially in middle- and low-income countries [2]. One cannot overlook that advances in the study and especially the treatment of diabetes mellitus are often exaggerated. This problem is far from its ultimate solution. According to the WHO (2018), diabetes is an important cause of blindness, kidney failure, lower limb amputation, and other long-term negative consequences that significantly affect patients' quality of life [3].

As a result of the development of ophthalmic complications, patients become disabled in a shorter period of time [4]. As a rule, the main cause of disability due to diabetic lesions of the visual organ in this category of patients is the development of diabetic retinopathy (DR) and diabetic maculopathy (DM), and vision loss occurs as a result of the development of diabetic macular edema (DOM) [5]. Patients with DM show signs of diabetic retinopathy within 10-15 years, and after 30 years, more than 90% of diabetics acquire this visual pathology [6].

Diabetic foot syndrome (DFS) accounts for 10-30% in the structure of surgical diseases in patients with diabetes [7]. DFS often ends in incapacitating surgical interventions, with severe socio-economic consequences [8]. Even with successful treatment, the recurrence rate of DFS is 66% [7].

Research findings of foreign and native scientists show that diabetic retinopathy is one of the most widespread and serious complications of vision in diabetes mellitus. It occurs from 25.3% to 56.3% of diabetic patients and is the main cause of blindness among people of working age [9, 10, 11, 12, 13].

As far back as 150 years ago MacKenzie (1879) first described diabetic retinopathy. However, today there are no perfect methods of DR treatment, the problem of solving this pathology remains acute [14]. Studies show that in 2010 there were 126,600,000 patients with DR, and the number of cases of diabetes mellitus is predicted to increase to 642 million (every 10 people) and with DR to 200 million by 2040 [15].

Diabetic retinopathy is a nonspecific microvascular pathology that affects the retinal vessels with subsequent formation of microaneurysms, hemorrhages, and as a consequence, patients have reduced visual acuity and develop blindness [16]. Patients with insulin-dependent diabetes have a higher risk of vascular diseases, such as hypertension,

nephropathy, and DR. It is the vascular disease that is the most frequent cause of morbidity and mortality in patients with insulin-dependent diabetes. The frequency of DR has a direct correlation with the severity of diabetes mellitus and is the main cause of blindness and visual impairment in patients of this profile [15].

The pathogenesis of vascular disease in diabetes is still unclear. In recent years, the attention of many researchers turned to the study of the role of endothelial nitric oxide relaxing factor in the development of severe conditions and complications of diabetes [5, 7, 9]. There is evidence regarding changes contributing to oxidative and nitrosative stress, including the increased formation of nitric oxide (NO) and superoxide, overexpression of various nitric oxide synthase (NOS) isoforms, nitrous oxide fields (ADP-ribose) proteins, and inhibition of antioxidant enzymes in the pathogenesis of this disease [3, 5, 9]. Besides, the possible role of these components in the development of diabetic retinopathy is considered, their importance as therapeutic components for reducing the risks of its development is emphasized [1, 15].

Nitric oxide (NO) is widely regarded in international studies as an important intercellular mediator in the cardiovascular and nervous systems, in immunological reactions, including in the eye. It is well known that nitric oxide (NO) is produced by three isoforms of nitric oxide synthase (NOS), which are expressed in varying degrees in the retina [17, 18]: endothelial (eNOS), neuronal (nNOS), and inducible (iNOS) (macrophage, immunological). A functional feature of iNOS is its role in activating the function of activated macrophages, which produce significantly more NO compared to the cellular vascular endothelium. It should be noted that NO produced by macrophages has a cytotoxic effect against target cells (tumors, bacteria, viruses, etc.) [17, 18]. A string of studies indicates that NO is sometimes found in bipolar cells [19].

At physiological levels, endothelial NO causes vasodilation, increases blood flow, decreases vascular resistance, inhibits platelet aggregation and adhesion, inhibits leukocyte adhesion and transmigration, and reduces smooth muscle proliferation. Also, nNOS-derived NO acts as a neuromodulator or neurotransmitter in neural activities such as light/dark adaptation. NO generated by iNOS is known to regulate immune responses. eNOS and nNOS are constitutive enzymes. At the same time, iNOS expression is induced by proinflammatory stimuli [17].

NO isoforms are mainly expressed in endothelial cells, brain and peripheral nerves, and macrophages, respectively [17]. It has been established [19] that NO can be produced by any type of retinal cell, and it is an important signaling molecule that regulates the release of

neurotransmitters and modulates the processes going on in the retina. In addition, constitutive NOS, eNOS, and nNOS are produced in the retina, which contributes to the regulation of normal hemodynamics and viability, and to the protection of retinal cells from oxidative stresses [20].

However, the existing literature data, successes in the study of DR pathogenesis do not answer all the questions of ophthalmologists about the possibilities of prognosing DR development, its complicated forms, and their prevention. An appropriate combination of all conditions leading to the development of DR is traced [9]. Therefore, early diagnosis of diabetic retinopathy, both in children and adults, plays a special role. It should be noted that the questions of pathogenesis and development of some ophthalmological diseases, including DR, concern a borderline area of knowledge and so far remain difficult and poorly studied.

Thus, the study of the possible role of nitric oxide in the development of diabetic retinopathy in patients with diabetic foot syndrome is of great clinical, practical, and scientific importance.

The purpose

The study is to improve the efficiency of diagnosis and treatment of diabetes complications by determining the indicators characterizing pathogenetic mechanisms of vascular dysfunction, in particular diabetic retinopathy, and the relationship of these changes with nitric oxide.

Materials and methods

The studies were conducted in 2019 – 2020 by the Department of General and Emergency Surgery and the Department of Ophthalmology of the Shupyk National Healthcare University of Ukraine of the Healthcare Ministry of Ukraine at the clinical bases of the university.

There were 2,114 patients with various surgical diseases under observation (including 1,073 patients with purulent-septic soft tissue diseases), 193 patients with type 2 diabetes, and 134 patients with 2–5 grades of diabetic foot syndrome by Wagner classification system.

The main study group consisted of 134 patients (268 eyes) with DFS. Gender and age characteristics of the main group: 85 men – 63.4%, 49 women – 36.6%, with a mean age of 64.7±7.3 years. The comparison group of appropriate age consisted of 59 patients (118 eyes) with diabetes mellitus without DFS and DR. Both groups were similar in age and gender.

All patients in the main group had concomitant pathology: coronary heart disease in 108 (80.6%) cases, hypertension in 97 (72.4%), diabetic retinopathy in 53 (39.6%), history of acute cerebral circulation disorder in 17 (12.7%), history of myocardial infarction in 23

(17.2%), encephalopathy in 29 (21.6%), chronic renal failure in 16 (11.9%), varicose lower limb disease in 14 (10.5%). The neuropathic form of DFS was diagnosed in 73 (54.5%) patients and the neuroischemic form of DFS in 61 patients (45.5%).

All patients were informed about the study. Informed consent to participate in the study was obtained in each case. The period of dynamic observation of the patients in the main group was four years. The study was approved by the Ethics Committee of the Shupyk National Healthcare University of Ukraine.

The level of metabolites of reactive oxygen species was assessed by the content of TBA-active products in blood plasma [21]. The state of the antioxidant defense system reflected the activity of superoxide dismutase (SOD) [22]. The production of nitric oxide was determined from the total content of nitrites/nitrates in blood plasma using the Griess reagent [23]. The content of active metabolites of nitric oxide was estimated by the content of S-nitrosothiols [24]. The homocysteine content was determined immunochemically with Abbott Architect i2000 Analyzer using Chemiflex chemiluminescence technology.

All patients underwent a comprehensive ophthalmological examination, including anamnesis study, visometry, tonometry (Topcon ST-80), refractometry (Humphrey-597, Hartinger), ophthalmometry (Topcon), echobiometry (Bio-meter AL-1000-Tomey), pachymetry (OCT-Vizante, Carl Zeiss), keratometry (Topcon), keratotopography (Pentacam, Oculus), biomicroscopy (Topcon), gonioscopy (Topcon, Goldmann, van Beuningen), retinal biomicroscopy with aspherical lenses (Topcon, Volk, Ocular), direct ophthalmoscopy with the evaluation of DZN and macula parameters (Carl Zeiss), perimetry (Humphrey HFA II-I, HFA II-750, and Zeiss Visual Field Analyzer), optical coherence tomography including Angio mode (Copernicus REVO, Retina3D protocol, RetinaRaster), fundus photography (Topcon TRS-NW7SF), fluorescence angiography (Topcon TRS-NW7SF).

Depending on the nature of the distribution, appropriate methods of statistical analysis were used: a statistical observation, variation statistics, multiple comparisons, mathematical expectation, correlation analysis, method of construction and analysis of logistic regression models, method of stepwise exclusion, method of construction of curves of diagnostic characteristics (ROC). Statistical material was coded and a database of results was formed for their computer processing using modern methods of statistics SPSS (Statistical Package for the Social Sciences), PASW Statistics (Predictive Analytics SoftWare) (SPSS: An IBM Company, Inc.), Statistica 10.0 software package (StatSoft, Inc., USA), as well as MedCalc statistical package (MedCalc Software's).

Results

The study showed that the risk of developing DR in patients with diabetes mellitus and DFS was higher when the duration of diabetes exceeded 10 years, the glycosylated hemoglobin was over 8.5, and the body mass index was more than 35.8. These patients also had ischemic heart disease in 91.4% of cases, hypertension in 85.2%, encephalopathy in 27.5%, chronic renal failure in 12.2%, varicose lower limb disease in 13.6%, and 39.7% of these DR patients already had secondary ophthalmohypertension. Figure 1 shows an analysis of patients with SDS and DR in the main group according to the severity of DR.

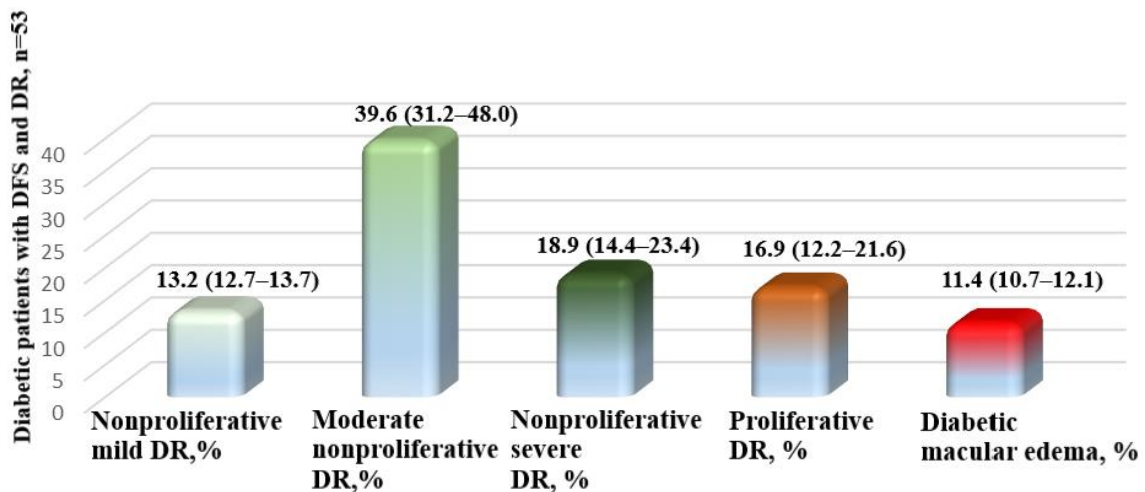


Figure 1. Characteristics of the main group patients in with DFS and DR as to the severity of DR, n=53

Of the 53 patients with diabetes mellitus (106 eyes), DFS, and DR, 13.2% of patients (14 eyes) had mild nonproliferative DR, 39.6% of patients (42 eyes) had moderate nonproliferative DR, 18.9% (20 eyes) had severe nonproliferative DR, 16.3% (18 eyes) had proliferative DR and 11.8% (12 eyes) had diabetic macular edema (DME).

Throughout the study, the content of end products of nitric oxide metabolism in peripheral blood was recorded in the patients of the main and comparison groups. As shown in Figure 2, patients with DR had a 1.78-fold ($p < 0.01$) increase in the level of end products of nitric oxide metabolism in peripheral blood compared to patients without DR.

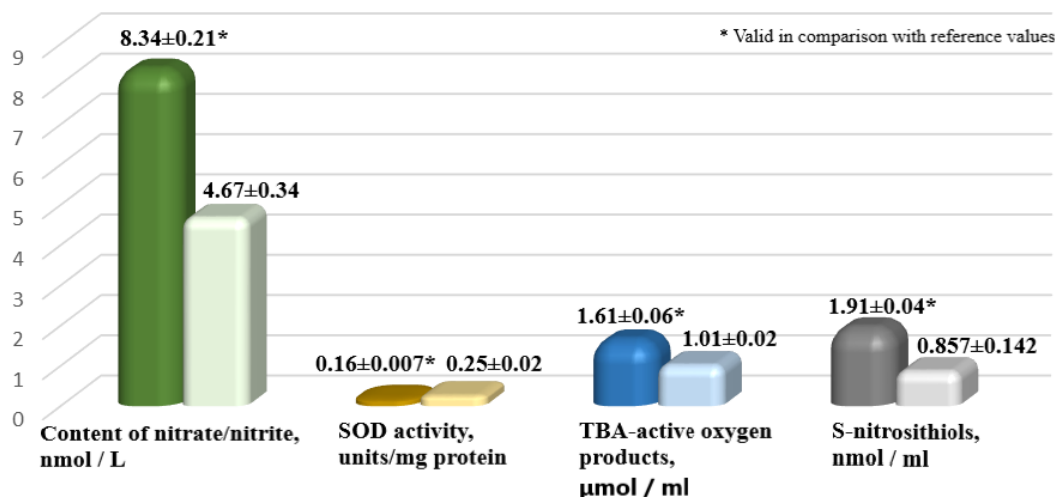


Figure 2. Content of end products of nitric oxide metabolism in peripheral blood of patients of the main and comparison groups, n=193

We determined the activity of peripheral blood SOD and found a 1.56-fold ($p<0.01$) decrease of its activity in DR patients compared to the comparison group (Figure 2).

Analysis of the content of TBC-active products in peripheral blood showed a 1.58-fold increase ($p<0.01$) in the main group relative to the reference values of patients without diabetic retinopathy (Figure 2).

We also found a 2.38-fold ($p<0.01$) increase in these indices in the main group when determining the content of S-nitrosityols (Figure 2).

The results of our studies prove that patients with diabetes mellitus complicated by retinopathy have an increased content of end products of nitric oxide metabolism in peripheral blood (Figure 2). The results obtained are consistent with the opinion of foreign colleagues who have established through experimental studies that hyperglycemia can increase the production of NO or reduce its bioactivity, which leads to an increase in superoxide formation [25]. The results of our studies demonstrate this fact - an increase in peripheral blood SOD activity (Figure 2) in diabetic patients with DR.

We also found that in the examined patients with DR there is an increase in the blood plasma of S-nitrosithiols and TBA-reactive oxygen species against the background of a significant decrease in the activity of the SOD antioxidant system (Figure 2).

It should be remembered that NO can have both positive and harmful effects, depending on its concentration [15]. On the one hand, NO induces relaxation of blood vessels, lowering blood pressure, preventing platelet aggregation and adhesion, restricting oxidation of

LDL cholesterol, inhibiting smooth muscle cell proliferation, and decreasing the expression of pro-inflammatory genes that are associated with atherogenesis.

On the other hand, NO interacts with O_2^- , leading to NO inactivation and production of peroxynitrite, which post-transcriptionally modifies proteins and negatively affects their function [10, 14]. This may contribute to endothelial dysfunction by stimulating the production of inflammatory mediators and lipid peroxidation, and thus increasing cell permeability [24].

It is known [26] that hyperglycemia and other stressful stimuli induce the formation of superoxide, which in excess quickly reacts with NO, producing strong oxidant peroxynitrite. Besides reducing the bioavailability of NO, peroxynitrite can react with modified tyrosine residues in proteins to form nitrotyrosine (protein nitration), a stable end product that leads to tissue damage through protein inactivation, lipid peroxidation, and DNA damage, leading to cell death and tissue dysfunction [26]. Since the retina is rich in polyunsaturated lipid membranes, it is especially sensitive to the action of reactive oxygen and nitrogen species [27]. Under pathological conditions, disorders of eNOS- and nNOS-derived NO or excessive NO production under the action of iNOS can lead to retinal damage, such as decreased cell viability, increased cell death, leukostasis, increased vascular permeability, and neurodegeneration [17]. It should be noted that oxidative stress also converts eNOS from a NO-generating enzyme to a superoxide producer, a process that occurs through depletion of the eNOS cofactor or substrate and other mechanisms involving post-translational modifications of eNOS [28].

Moreover, on the other hand, both chronic and acute hyperglycemia is associated with decreased NO bioavailability and impaired endothelium-dependent vasodilation in patients with diabetic retinopathy.

Therefore, we also examined the patients of the main group for homocysteine content in peripheral blood. The results disclosed a 5.13-fold ($p < 0.001$) increase in its concentration in patients in the main group with DR relative to the comparison group (Figure 3).

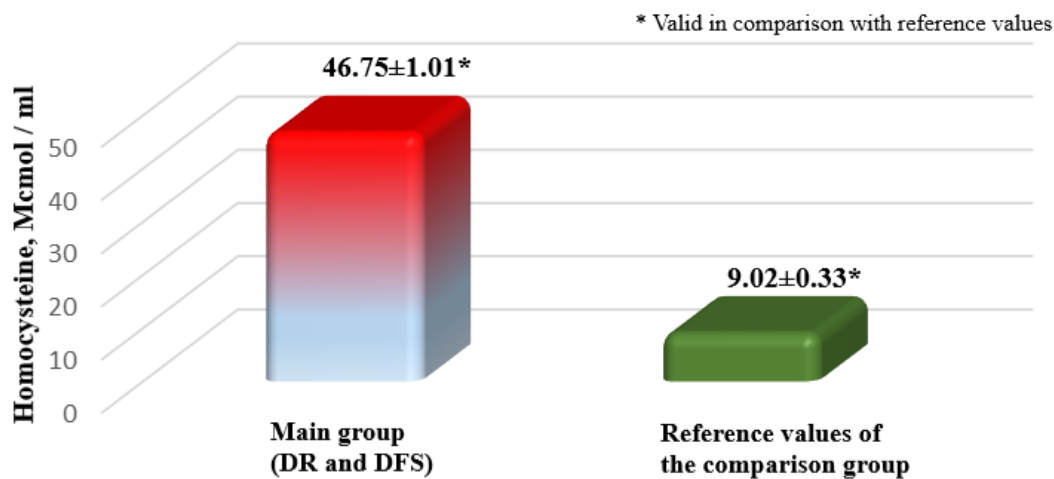


Figure 3. Analysis of homocysteine content in peripheral blood of patients in the main and comparison groups, n=193

Homocysteine is a sulfur-containing amino acid, and its high blood levels are considered a risk factor for many diseases, including heart disease and ophthalmic complications of diabetes mellitus [6, 8]. Moderate increases in circulating homocysteine are thought to play a key role in the development of retinal abnormalities, including endothelial cell dysfunction, ischemia, thinning of nerve fiber layers, development of neovascularization and hemoretinal barrier disorders. Numerous clinical studies have proven the importance of these factors in the mechanisms of diabetic retinopathy development [14, 18, 25].

Moreover, foreign studies [17, 18] using experimental models have shown mechanisms of action of homocysteine leading to retinal neurodegeneration. It was proved in works in vivo and in vitro that homocysteine induces apoptosis in retinal ganglion cells and induces loss of ganglion cells due to disruption of mitochondrial dynamics regulation [17, 18]. Activation of N-methyl-D-aspartate (NMDA) receptors has also been suggested as a possible mechanism of homocysteine-induced retinal ganglion cell death [25, 26, 28]. Some studies have shown that homocysteine exhibits its toxic effect through the activation of inflammatory and oxidative stress mechanisms, which leads to the activation of mitogen-activated protein kinases (MAPK), macrophage infiltration, and increased proinflammatory cytokine production [29]. In addition, homocysteine causes oxidative stress and decreases nitric oxide bioactivity, ultimately leading to vascular dysfunction [29].

As a result of our studies in patients with diabetes mellitus complicated by retinopathy, we found that a significant increase is determined in the content of nitric oxide in the peripheral blood, the cause of which is hyperglycemia. This situation occurs against the

background of an increase in the activation of the production of reactive oxygen species (TBA-active products) and peroxynitrite (S-nitrosithiols) and significant inhibition of the activity of antioxidant blood systems (SOD). These trends lead, on the one hand, to the development of oxidative stress and direct damage to the retina, and, on the other, to a decrease in the bioavailability of nitric oxide in the implementation of vasodilation reactions.

At the same time, the excessive production of nitric oxide in the examined patients, which had negative consequences, proceeds together with an increase in the content of homocysteine in the peripheral blood of diabetic patients, which is also a powerful vasoconstrictor. Thus a pathological circle is formed, which leads to the development of vascular dysfunction of vessels in the retina and causes significant complications of diabetes mellitus, and correlates with the severity of diabetic retinopathy.

Many different therapeutic strategies are currently used to treat DR: nonsteroidal, steroidal anti-inflammatory drugs, anticoagulants; monoclonal antibodies to specific mediators, factors, molecules; panretinal laser retinal photocoagulation [9]. In recent years, targeted therapy has demonstrated its undeniable advantages, allowing to obtain the most positive effect with minimal side effects. However, at the current stage of scientific development, a promising approach is the treatment and prevention of DR, which provides an opportunity to study and modulate inflammation at the molecular level.

The use of an intercellular mediator (nitric oxide NO), which contributes to the physiological regulation of ocular hemodynamics and protects vascular endothelial cells from pathogenic ischemic factors, is therefore relevant and timely for clinicians to choose an effective pharmacological therapy suitable for a particular patient and a particular eye.

Conclusions

The results of our research evidence that retinal vascular lesion and the development of diabetic retinopathy, caused by hyperglycemia, is associated with an increase in the content of nitrogen oxide and homocysteine in the peripheral blood and correlates with the severity of DR. Further study of the possibility of using nitric oxide as pathogenetic therapy in the treatment of diabetes complications, in particular, diabetic retinopathy and diabetic foot syndrome is promising and of relevance for modern medicine.

References

1. Owyong M, Schwartz SG, Scott IU. An Update on the Genetics of Diabetic Retinopathy. *Retina Today* [Internet]. 2017. Available from: <http://retinatoday.com/2017/03/an-update-on-the-genetics-of-diabetic-retinopathy>.

2. Yau JW. Global prevalence and major risk factors of diabetic retinopathy. *Diabetes Care*. 2012; 35 (3):556-64.
3. Coucha M, Elshaer SL, Eldahshan WS, Mysona BA, El-Remessy AB. Molecular mechanisms of diabetic retinopathy: potential therapeutic targets. *Middle. East. Afr. J. Ophthalmol*. 2015 Apr-Jun; 22 (2):135-44.
4. Pshenichnov MV. Risk factors and patterns of manifestation of macular edema in patients with type II diabetes mellitus. *Avtoreferat. Krasnoyarsk*. 2010: 22.
5. Veselovskaya N.N., Veselovskaya Z.F. Basic research in ophthalmology - a modern perspective of new approaches to primary and secondary prevention of vascular diseases of the visual organ. *Ophthalmology*. 2015; 1(01): 11-17.
6. Polovina MM, Potpara TS. Endothelial dysfunction in metabolic and vascular disorders. *Postgrad Med*. 2014; 126 (2):38-53.
7. Bilyaeva O.A., Krizhevsky V.V., Rybyanets L.I., Ulanovich L.I., Ivanchenko R.V. Optimization of complex treatment of purulent necrotic processes in patients with diabetic foot syndrome and financial aspects. *Klinicheskaya hirurgiya*. 2014; 11(3): 3-7.
8. Pokydjko A.A., Zhmur T.P., Zarezanko A.V., Funikov A.V., Yarmak O.A., Osadchiy A.V. Features of the wound process in patients with hospital wounds and in patients with diabetic foot syndrome. *Harkivska hirurgichna shkola*. 2019; 2(95): 214-218.
9. Bezditko P.A., Klimenko V.V. Molecular mechanisms of pathogenesis of diabetic retinopathy. *Archiv ophthalmology*. 2017; 5 (3): 92-96.
10. Kertes P.J., Johnson T.M. *Evidence Based Eye Care*. Lippincott Williams & Wilkins. 2007; 6964-6967.
11. Rahimi Z, Moradi M, Nasri H. A systemic review of the role of rennin angiotensin aldosterone system genes in diabetes mellitus, diabetic retinopathy and diabetic neuropathy. *J. Res. Med. Sci*. 2014; 19 (11):1090-8.
12. Krushinskaya Z.G., Uyzvenko T.U., Marchenko O.V. The influence of etiological and social factors on the development and course of diabetic foot syndrome. *Endocrinology*. 2019; 24 (1): 17-23.
13. Marchenko O.V. Analysis of negative results of treatment of diabetic foot syndrome in an outpatient setting. *Meghdunarodmiy endokrinologicheskiy zhurnal*. 2017; 13(2): 181-185.
14. Forstermann U. Oxidative stress in vascular disease: causes, defense mechanisms and potential therapies. *Nat. Clin. Pract. Cardiovasc. Med*. 2008; 5:338-49.

15. Rangasamy S, McGuire PG, Das A. Diabetic retinopathy and inflammation: Novel therapeutic targets. *Middle East Afr J Ophthalmol.* 2012; 19:52-9.
16. Rubenstein DA, Yin W. Platelet-activation mechanisms and vascular remodeling. *Compr. Physiol.* 2018; 8(3):1117-56.
17. Babik B, Peták F, Agócs S, Blaskovics I, Alács E, Bodó K, et al. Diabetes mellitus: endothelial dysfunction and changes in hemostasis. *OrvHetil.* 2018; 159 (33):1335-45.
18. Sivaprasad S, Gupta B, Crosby-Nwaobi R, Evans J. Prevalence of diabetic retinopathy in various ethnic groups: a worldwide perspective. *Surv. Ophthalmol.* 2012; 57 (4):347-70.
19. Mammadzada P., Gudmundsson J., Kvanta F., Andre H. Differential hypoxic response of human choroidal and retinal endothelial cells proposes tissue heterogeneity of ocular angiogenesis. *Acta Ophthalmologica.* 2016; 94 (8): 805-814.
20. Stem MS, Gardner TW. Neurodegeneration in the pathogenesis of diabetic retinopathy: molecular mechanisms and therapeutic implications. *Curr. Med. Chem.* 2013; 20 (26):3241-50.
21. Seluytina S.N., Seluytin A.Yu., Palj A.I. Modification of the determination of the concentration of TBK-active products of blood serum. *Klin.lab.diagnostica.* 2000; 2: 8-11.
22. Kostyuk V.A., Potapovich A.I., Kovakeva Zh.V. A simple and sensitive method for determining the activity of superoxide dismutase, based on the oxidation reaction of quercetin. *Voprosi med. Himii.* 1990; 36 (2): 88-91.
23. Grishem M.B., Dghonson G.G., Lankaster Dg.P. Quantification of nitrates and nitrites in extracellular fluids. *Metodi Enzimol.* 1996; 268: 237-246.
24. Stamler J.S. S-nitrosothiols in blood: role, amount and methods of analysis], S-нитрозотиолы в крови: роль, количество и методы анализа. *Circ Res.* 2004; 94 (4): 414-417.
25. Adela P., Nethi C.K., Bagul P.K., Barui A.K., Mattapally C., Kuncha M., [et al.] Hyperglycemia Increases Nitric Oxide Production in Diabetes: A PLoS One Study of South Indian Patients. *Plos One.* 2015; 10 (4): 25-27.
26. Pacher, P. et al. The endocannabinoid system as an emerging target of pharmacotherapy. *Pharmacol. Rev.* 2006; 58: 389-462.
27. Straznický NE, Grima MT, Lambert EA. Arterial norepinephrine concentration is inversely and independently associated with insulin clearance in obese individuals with metabolic syndrome. *J. Clin. Endocrinol. Metab.* 2015; 100 (4):1544-50.

28. Vindeirinho J, Santiago AR, Cavadas C, Ambrósio AF, Santos PF. The Adenosinergic System in Diabetic Retinopathy. *J Diabetes Res.* 2016; 2016:4270301.
29. Zheng Y, He M, Congdon N. The worldwide epidemic of diabetic retinopathy. *Indian J. Ophthalmol.* 2012; 60 (5):428-31.