



# Easy Flow with a MiniFlo? An External Distraction Device to Overcome Joint Flexion Contractions

Fuest L\*, Haug L and Vögelin E

Department of Hand and Peripheral Nerve Surgery, University Hospital Bern, Switzerland

## Abstract

**Background:** Flexion contractions of the PIP or the MCP joint are common in Dupuytren's disease or after trauma. Several techniques and devices have been developed to treat this functionally impairing condition. One option for treatment is the "MiniFlo" device, an external distraction fixator positioned dorsally over the involved contracted joint with four bone screws.

**Methods:** Between October 2019 and August 2020, nine patients with flexion contractures of the PIP or MCP joint were treated with eleven MiniFlo fixators. The patients are instructed to extend the involved finger joints by increasing the angle of the distraction device daily. After achieving the best possible extension, the MiniFlo fixator is dismantled, a splint applied or further surgeries planned.

**Results:** After application of the MiniFlo device, an average of 29 days was required to correct a median flexion-contraction of 50°. Immediately after removal of the MiniFlo fixator, all patients showed an improvement of the passive and active extension of the involved joint. During regular follow-up examinations the maximum achieved improvement of the extension with the MiniFlo fixator could not be permanently maintained. In five of the cases, the flexion-contraction stabilized at 50% to 75% improvement compared to the maximum improvement gained at dismantling; in two cases each ~25% and ~12% improvement was achieved and could be maintained up to one year, respectively. In two joints, no permanent improvement could be demonstrated.

**Conclusion:** The use of the fixator in severe Dupuytren's disease or posttraumatic flexion contractures is a good option for slow stretching of the soft tissue. It allows a less aggressive option in preparation for further surgery in severe flexion contractures of 90°. However, based on the results of this study, the MiniFlo fixator cannot be considered as a stand-alone instrument to treat flexion contractures.

## OPEN ACCESS

### \*Correspondence:

Lena Fuest, Department of Hand and Peripheral Nerve Surgery, University Hospital Bern, Inselspital Freiburgstrasse 18, 3010 Bern, Switzerland,

E-mail: [lena.fuest@googlemail.com](mailto:lena.fuest@googlemail.com)

Received Date: 07 Nov 2022

Accepted Date: 29 Nov 2022

Published Date: 03 Dec 2022

### Citation:

Fuest L, Haug L, Vögelin E. Easy Flow with a MiniFlo? An External Distraction Device to Overcome Joint Flexion Contractions. *Clin Surg.* 2022; 7: 3598.

**Copyright** © 2022 Fuest L. This is an open access article distributed under the Creative Commons Attribution License, which permits unrestricted use, distribution, and reproduction in any medium, provided the original work is properly cited.

## Introduction

Surgical treatment of severe flexion contractures is a challenge especially when performing one stage surgery including arthrolysis, tenolysis and or reconstruction with a flap. Several complications are possible. Severe angulation of joints reduces the size of the surgical field and prohibits an anatomical overview, which complicates treatment. Ligaments, the volar plate, pulleys and soft tissues are shortened requiring transposition of soft tissue after attempted extension of joints [1]. Additionally, severe flexion contracture may lead to displacement of the vascular and nerve bundles and in case of long-lasting joint contractures, the sudden stretch may cause ischemia and neuropathy. To minimize above-mentioned risks, an external distraction device applied for multiple days and gradually stretching contracted tissue may minimize the risk of nerve and vascular injuries or skin lesions. With the MiniFlo fixator, it is possible to adjust the distraction speed according to the patient's soft tissue condition. This treatment may enable to address Dupuytren's as well as post-traumatic flexion contractures in a more physiologic way.

## Materials and Methods

Nine patients with Dupuytren's disease (n=2) or post-traumatic (n=7) flexion contractures of the PIP or MCP joint were treated with a MiniFlo distraction fixator between October 2019 and August 2020. Two patients suffer from a Dupuytren's contracture 4 according to the Tubiana classification [2], seven patients demonstrate severe joint contractures after different traumatic injuries or sequelae (Table 1). One trauma and one Dupuytren's patient of the cohort were treated with two MiniFlo distraction devices for 2 joints, resulting in a total of eleven analyzed cases.

In all of the eleven cases, a MiniFlo distraction fixator, developed by Citieffe (Bologna, Italy), is implanted and adjusted to the relevant PIP or MCP finger joint. The surgery is performed under

**Table 1:** Population.

|                         |  |
|-------------------------|--|
| Cohort                  | n=9<br>77% male<br>Median Age 51 years (range 28-69)   |
| Duration of distraction | Average 29 days  |
| Number of fixators      | 11 in total:<br>- 2x index finger<br>- 1x long finger<br>- 4x ring finger<br>- 4x small finger |
| Nature of contracture   | 2x Dupuytren's disease<br>7x Posttraumatic   |
| Joints involved         | 10x PIP<br>1x MCP  |

plexus anesthesia or local anesthesia according to the WALANT technique depending on the patient's and surgeon's preference. A template is placed over the corresponding joint at a 90° angle to choose the right size of the fixator. Markings on the template show the entry points of the K-wires into the bone and define the right size of the fixator: In most of the cases the size R25 fits for PIP joints and size R30 for MCP joints. Under fluoroscopic control, in a lateral view, a laser-marked 1.5 mm K-wire is positioned at the joint center in the middle of the head of the proximal phalanx or metacarpal. Four self-drilling pins are inserted through small skin incisions percutaneously in the adjacent bones bicortically. The clamps allow an angulation of 40° of the inserted pins. After opening the telescopic units and removal of the laser-marked K-wire, the distraction is tested during surgery using a special key. Figure 1 shows the postoperative result by photography and X-ray.

The suggested distraction rate is 1 turn of the screw or approximately 3° reduction of contraction per day. The degree of traction acting on the joint is chosen by the patient starting from the first postoperative day. The distraction rate, possible discomfort level of the patient, control of the soft tissue and a fluoroscopic control of the pins and joint position are checked weekly by the surgeon. In case of over distraction or subluxation of the joint, the distraction unit of the fixator is readjusted. As soon 0° extension of the contracted joint has been achieved or the level of improvement stagnates, the final phase of an additional 1 to 3 weeks of wearing the distraction fixator statically in the best possible extension of the joint is added. The MiniFlo distraction device is removed in the outpatient clinic without anesthesia and finally, an extension splint is fitted or further surgery such as pulley reconstruction, z-plasties or soft tissue flap transposition is performed. After removal of the fixator, the progress is checked at 6, 12, 26 and 52 weeks after dismantling.

**Table 2:** Joints F, G, K: Dupuytren Disease; A-E and H-J: Posttraumatic. Measurement data of flexion contracture before and after treatment.

| Case | Flexion Contracture before Treatment [°] | Improvement at Dismantling [%] | Improvement after Treatment [%] | Improvement Rate [°/day] |
|------|--|--------------------------------|---------------------------------|--------------------------|
| A    | 80                                       | 63%                            | 13%                             | 1.56                     |
| B    | 72                                       | 79%                            | 24%                             | 2.19                     |
| C    | 90                                       | 100%                           | 11%                             | 3.21                     |
| D    | 45                                       | 100%                           | 62%                             | 1.55                     |
| E    | 80                                       | 100%                           | 56%                             | 4                        |
| F    | 80                                       | 31%                            | 0%                              | 1.79                     |
| G    | 70                                       | 21%                            | -7%                             | 1.07                     |
| H    | 50                                       | 100%                           | 70%                             | 1.79                     |
| I    | 60                                       | 83%                            | 50%                             | 1.28                     |
| J    | 40                                       | 100%                           | 75%                             | 1.03                     |
| K    | 95                                       | 84%                            | 26%                             | 1.63                     |

## Results

### Population

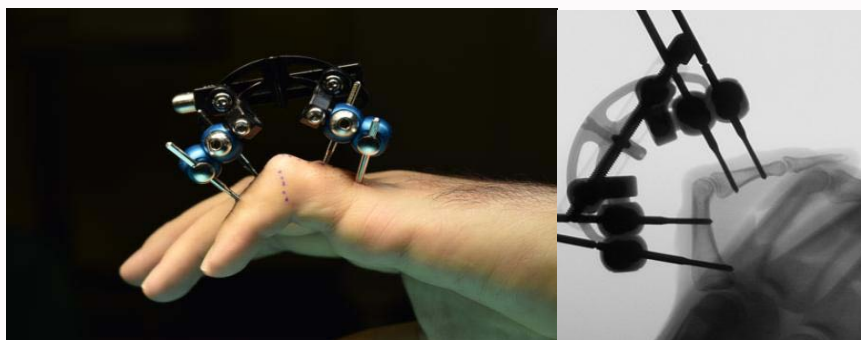
A 77% of the included 9 patients are male and the median age is 51 years (range 28-69). Two index fingers, one long finger, four ring and four small fingers were treated, corresponding to 10 PIP joints and one MCP joint, as well as six fingers of the left hand and 5 fingers of the right hand. Three patients have a severe Dupuytren's contracture and the remaining patients have a contracture after a severe trauma, Table 1.

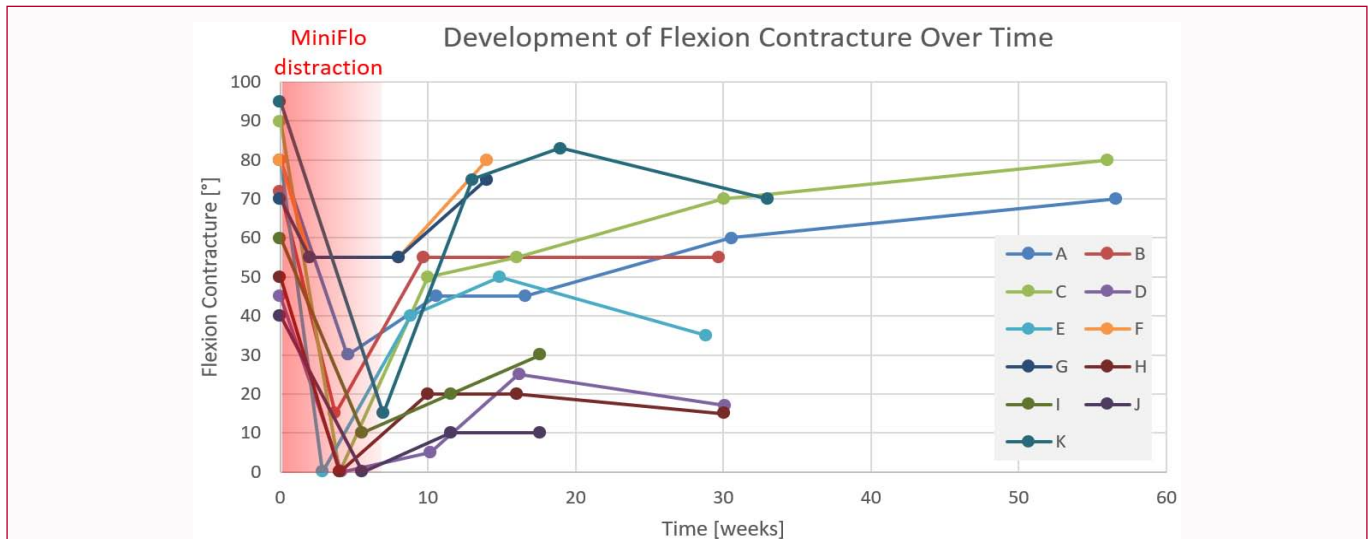
### Course of contracture

The preoperative range of flexion contracture was between 40° and 95°, median 72°. The duration of distraction with the MiniFlo fixator range from 14 to 49 days (median 28 days). After dismantling the fixator, the median improvement of flexion-contracture was 50° (range 15° to 90°). The improvement rate is 1.9° per day on average (range 1°/day to 4°/day), Table 2.

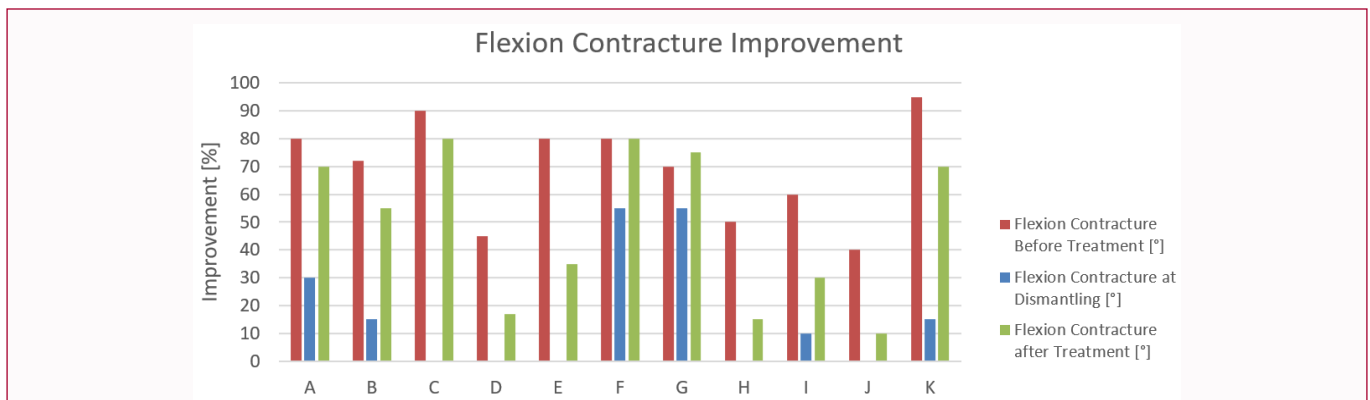
The follow up of the flexion contracture is checked at 6, 12, 26 and 52 weeks after dismantling, Figure 2, 3. In contrast to an average of 53° improvement of flexion contracture at dismantling, a deterioration of 30° at six weeks after removal of the MiniFlo fixator was observed. This correlates to an average extension loss of 23° within the first six weeks.

Twelve weeks after removal 10 of the 11 joints demonstrate an average of 22° (range 5°-35°) improvement of contraction compared

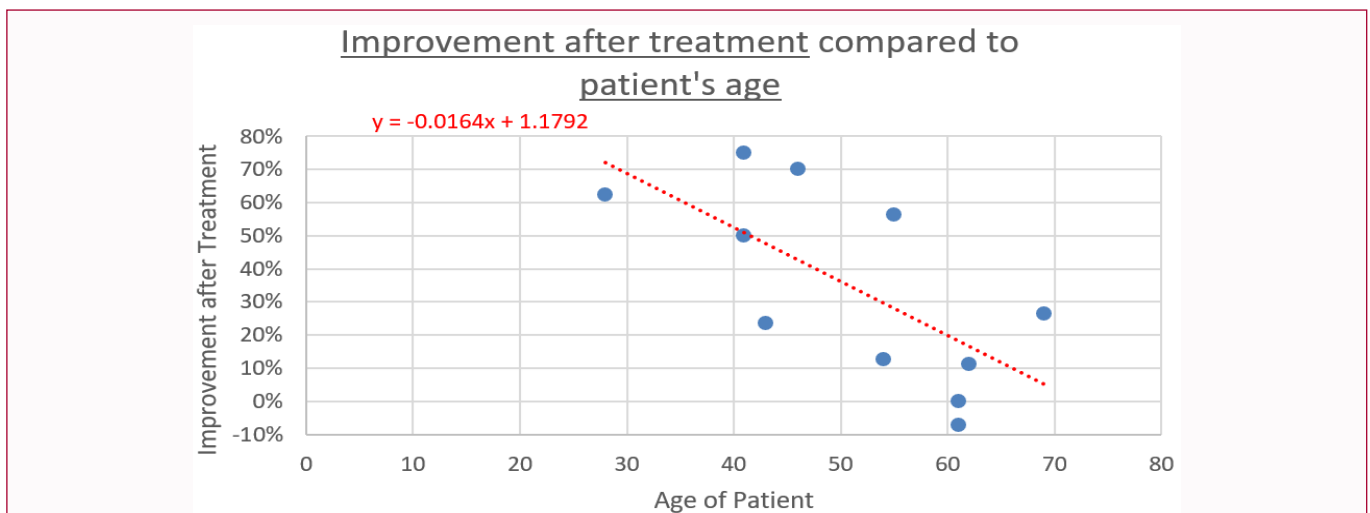
**Figure 1:** Postoperative findings and x-ray control I after application of the distraction fixator.



**Figure 2:** Development of flexion contracture over time: Time period highlighted in red shows the distraction period of 2-7 weeks with the MiniFlo fixator. Examination intervals at 6, 12, 26 and 52 weeks after dismantling represented by each marker on the line.



**Figure 3:** Flexion contracture improvement for all 11 cases (A-K) visualized with red, blue and green bars.



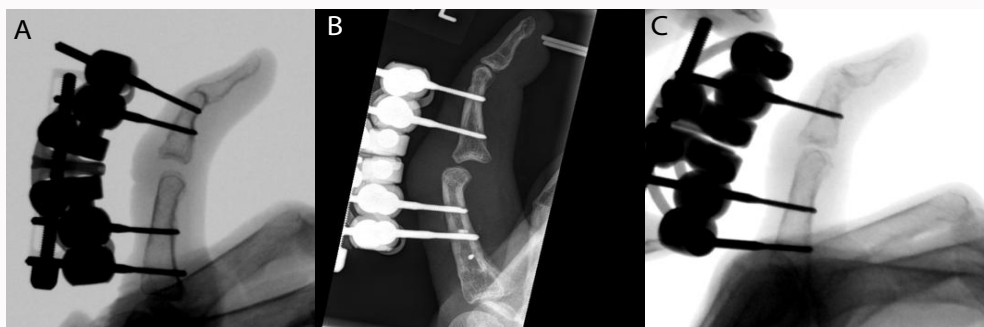
**Figure 4:** Correlation of contraction improvement after treatment and patient's age.

to the preoperative contracture of 72° (range 40°-90°). The average extension loss of the initially gained 53° appears to be 31° over 12 weeks (loss of 22° extension).

Twenty-six weeks after removal 7 of the 11 joints are investigated

and five joints show a stabilized or an improved contraction up to 15° compared to the 12 weeks examination interval. Two joints (A and C) show further deterioration with a similar trend (Figure 2).

The analyzed data indicates a linear correlation between the



**Figure 5:** A) Over distraction of the PIP joint. B) Subluxation of PIP joint. C) Loosening of a K wire.

achieved flexion contracture improvement after treatment in percent and the patient's age: The younger the patient, the higher the rate of contraction improvement (Figure 4).

### Complications

A total of five patients (55%) developed one or more complications (range 1-3). In 33% of the cases (3 patients) an over-distraction of the PIP joint occurred (Figure 5A) and in one case (11%) a subluxation (Figure 5B). These complications are caused by a not correctly aligned center of the axis to the rotation center of the MiniFlo fixator. And in one case a non-opened telescopic unit caused a deformity of the axis over time. Another complication included loosening of a K-wire caused by a too big angulation of the placed K-wires, requiring its removal (Figure 5C).

### Discussion

Contracted finger joints are challenging and need a comprehensive clinical, radiological and, if available, sonographic examination. Contracted finger joints are often caused by Dupuytren's disease [3] causing disability in activities of daily life [4]. Treatment options for Dupuytren's disease are diverse and have varied degrees of invasiveness. Two minimally invasive techniques are the percutaneous needle fasciotomy and the injection of *Clostridium histolyticum* collagenase. Both methods may rarely cause flexor tendon ruptures, nerve damage and skin lesions [5]. More invasive treatment options include partial or complete fasciectomy and in severe cases some patients need to undergo amputation [6]. Bailey et al. [7] showed that continuous extension of the Dupuytren cords leads to an increased level of degradative enzymes and therefore weakening of the fibers by degradation and the increase in newly synthesized collagen. This stretching mechanism of the contracted soft tissue is part of the MiniFlo treatment strategy. In 1998, Cirton [8] used a skeletal distraction device in the treatment of severe primary Dupuytren's disease and in 2019, Corain et al. [9] used the MiniFlo fixator in a two-step approach in order to treat Dupuytren's disease. The MiniFlo is an adjustable distraction fixator on which the patient can gradually increase the traction. This feature of patient self-tailored traction makes the MiniFlo attractive for a wide range of patients.

In this study, the indication for MiniFlo application was extended from Dupuytren disease to trauma patients. In the cohort of this study, the causes of contraction after trauma are diverse: One patient (case A) had no more Intrinsic muscles and others had no A2 or A4 pulley (case E and I), which leads to massive bowstringing. In these cases, the fixator is used to stretch the tissue, in order to minimize the risk for vascular and skin problems. The MiniFlo fixator does not solve the original problem causing the contracture, and the patients

are subject to a pulley reconstruction shortly after dismantling of the fixator. This is the reason for some cases in the cohort not being available for a total follow-up period of 52 weeks. These patients required further surgical therapy before 52 weeks.

Using a MiniFlo fixator reduces the flexion contracture under gentle stretching of the tissue in 100% of the evaluated cases at the point of dismantling. The use of the fixator proves to be a good first step for potential subsequent surgery. Among other advantages of the presented technique, is that no skin problems were observed. Most of the complications are caused by misalignment of the K-wires and could be corrected after surgery with minor effort. After we identified the potential pitfalls, the surgeons had a quick learning curve and this leads to a significant reduction of complications. A 75% of the complications occurred in the first three patients we operated on. The described results indicate that the maximum achieved improvement of flexion-contracture with the MiniFlo fixator after dismantling cannot be maintained without further conservative or surgical treatment. Therefore, it is recommended to have a treatment strategy after removal of the fixator in order to maintain the gained extension, for example pulley-reconstruction or variants of aponeurotomy.

Further examinations shall be performed to investigate the influence of the fixator on different tissue changes, especially with respect to trauma patients.

### References

1. Walle L, Hohendorff B. [The lateral-dorsal transposition flap for closure of a palmar soft tissue defect of the proximal phalanx on the little finger after limited fasciectomy in recurrent Dupuytren's contracture]. *Oper Orthop Traumatol.* 2016;28(1):38-45.
2. Tubiana R. Evaluation of deformities in Dupuytren's disease. *Ann Chir Main.* 1986;5(1):5-11.
3. Elliot D. The early history of contracture of the palmar fascia. Part 1: The origin of the disease: The curse of the MacCrimmons: the hand of benediction: Cline's contracture. *J Hand Surg Br.* 1988;13(3):246-53.
4. Wilburn J, McKenna SP, Perry-Hinsley D, Bayat A. The impact of Dupuytren disease on patient activity and quality of life. *J Hand Surg Am.* 2013;38(6):1209-14.
5. Therkelsen LH, Skov TS, Laursen M, Lange J. Percutaneous needle fasciotomy in Dupuytren contracture: A register-based, observational cohort study on complications in 3,331 treated fingers in 2,257 patients. *Acta Orthop.* 2020;91(3):326-30.
6. Eiriksdottir A, Atroshi I. A new finger-preserving procedure as an alternative to amputation in recurrent severe Dupuytren contracture of the small finger. *BMC Musculoskelet Disord.* 2019;20(1):323.
7. Bailey AJ, Tarlton JF, der Stappen JV, Sims TJ, Messina A. The continuous

- elongation technique for severe Dupuytren's disease: A biochemical mechanism. *J Hand Surg Br.* 1994;19(4):522-7.
8. Citron N, Messina JC. The use of skeletal traction in the treatment of severe primary Dupuytren's disease. *J Bone Joint Surg Br.* 1998;80(1):126-9
  9. Corain M, Zanotti F. Proposal for treatment of severe Dupuytren disease in 2 steps: Progressive distraction with external fixator and collagenase - A preliminary case series. *Hand (N Y).* 2020;15(5):631-7.