



Dual-Energy Computed Tomography Can Replace the Standard Triphasic Protocol in Follow-Up Imaging of Endovascular Aneurysm Repair: A Review

Minh Chau

Division of Health Sciences, School of Health Sciences, University of South Australia, Adelaide, Australia

This review aims to evaluate diagnostic performance of dual-energy computed tomography (DECT) in follow-up examinations after endovascular aneurysm repair (EVAR) and its radiation dose estimates compared to the standard triphasic protocol. A systematic search was conducted on 20th May 2018 on the following databases: MEDLINE, PubMed, and Scopus. Articles were screened against the inclusion and exclusion criteria. A narrative review of the literature was performed. A summary statistic table of the calculated mean effective dose (ED), percentages in dose reduction and diagnostic performance of DECT were pooled. Five original articles were included. Compared to the triphasic protocol being the reference standard, data from the DECT acquisitions were observed to have 98–100% overall accuracy for the detection of type I and II endoleaks. The cumulative EDs were significantly different ($p < 0.001$) between the protocols. The ED delivered in the DECT protocol was approximately 61% lower than that delivered to the patient by the standard triphasic protocol (11.1 mSv compared with 27.8 mSv). A DECT protocol can replace the standard triphasic protocol in follow-up imaging after EVAR for the detection of type I and II endoleaks. This acquisition protocol also significantly reduces the ED to the patients.

Key words Computed tomography · Dual-energy · Endovascular procedures · Aneurysm.

Received: January 17, 2019

Revised: April 25, 2019

Accepted: July 8, 2019

Corresponding author

Minh Chau, BMRS (MI)

Division of Health Sciences,

School of Health Sciences,

University of South

Australia, Adelaide, Australia

Tel: 61-8-830-22905

Fax: 61-8-830-22810

E-mail: chamt010@mymail.unisa.edu.au

INTRODUCTION

Since the introduction of endovascular aneurysm repair (EVAR) by Parodi and his colleagues in 1991, this treatment has become widely accepted for thoracic and abdominal aortic aneurysms. It is also a more viable alternative to open surgical repair with significant reductions in complications and mortality [1-3]. Nevertheless, after this procedure, continuous imaging surveillance is required to evaluate for potential complications such as occlusion, stent migration, arteriovenous fistula formation and endoleaks [4,5]. It is important to note that endoleaks are the most common acute and delayed complication after EVAR which occurs in up to 45% of all patients [6,7]. As this complica-

tion might cause an enlargement of the aneurysm and hence exacerbate the rupture risk, early detection and treatment are essential [8].

Multiple imaging techniques have been proposed and utilised for the detection and classification of endoleaks for the surveillance of patients who have undergone EVAR. These include CT, MRI, and ultrasonography [9]. Contrast-enhanced CT is the modality of choice [10]. Endoleak detection using CT is simply assessing a peri-graft flow that reflects the flow of contrast out of the stent-graft and into the aneurysmal sac [11]. The optimal contrast-enhanced CT imaging protocol, however, is still in discussion. The literature has suggested that triphasic protocol is most commonly used, including a non-contrast phase, an arterial phase during contrast administration and a delayed phase to optimize the detection of endoleaks [12,13]. Although this protocol is efficient, after EVAR, patients are required to attend

© This is an Open Access article distributed under the terms of the Creative Commons Attribution Non-Commercial License (<https://creativecommons.org/licenses/by-nc/4.0>) which permits unrestricted non-commercial use, distribution, and reproduction in any medium, provided the original work is properly cited.

indefinite follow-ups and are exposed to substantial accumulative radiation dose and hence, increased lifelong risk of developing cancers [14]. Therefore, considerable effort and research have been made to examine the possibility of decreasing CT acquisition phases without compromising diagnostic performance of the scan [10]. As such, a study by Macari et al. [15], has reported a comparable diagnostic accuracy for endoleak detection by merely using the non-contrast and delayed phases and ultimately suggested an elimination of the arterial phase.

In the past decade, the use of dual-energy CT (DECT) has been profoundly investigated and represents a promising advantage in this field. With DECT, it is possible to simultaneously acquire CT data with two different photon energy levels (typically at 80 kVp and 140 kVp), resulting in different degrees of X-ray attenuation, measured in Housefield units [16]. As a result, the difference in energy spectra allows the software to characterise iodine, calcium and other materials at low and high photon energies [17,18]. DECT has therefore been proposed as a preferable CT technique because it has potential clinical implications in follow-up imaging of patients after EVAR. The acquisition of dual-energy data enables the generation of virtual non-contrast data which might remove the need for a routine acquisition of true non-contrast phase [17]. In effect, the use of this approach could reduce the radiation burden to patients. To date, there has been no literature review on the use of DECT protocol in patients undergoing follow-up examinations after EVAR, especially with the radiation dose associated with this protocol and the diagnostic accuracy of this protocol compared to the standard triphasic protocol.

OBJECTIVES

The purpose of this literature review is to evaluate the following hypothesis and research questions.

DECT protocol can replace the standard triphasic protocol in

patients undergoing follow-up examinations after EVAR.

Research question 1: Does DECT protocol provide a significant dose reduction relative to the standard triphasic protocol for these patients?

Research question 2: What is the diagnostic accuracy of DECT protocol in follow-up examinations after EVAR, and how does its diagnostic accuracy compare the standard triphasic protocol?

METHODS AND MATERIALS

Selection criteria

A systematic search was conducted on 20th May 2018 on the following databases: MEDLINE, PubMed, and Scopus. We used the following combinations of keywords: [(Dual-energy computed tomography OR DECT) AND (Diagnostic performance OR accuracy OR radiation OR dose) AND (endovascular aneurysm repair OR EVAR)] (Table 1). At the completion of the database searches, results were pooled, and all duplicates were removed.

Search strategy

The inclusion criteria include articles published between 2006 and 2018. The rationale of excluding articles published prior to 2006 is because DECT technology was introduced in 2006 [17]. The articles must be original, peer-reviewed and reported quantitative measurements of the diagnostic accuracy of DECT in imaging follow-up of EVAR. The exclusion criteria include articles published in languages other than English. The articles were excluded from the search if it was conducted on non-human participants and/or was a narrative review.

The titles and abstracts of the original articles were initially screened. Abstracts that were found to match the inclusion criteria were obtained in full text to confirm their suitability for inclusion. Articles not matching the eligibility were then excluded. All articles meeting the above eligibility criteria were then

Table 1. Search terms for systematic review

Search string	Search number	Search term	Search type	Search conditions
1	1	Dual-energy computed tomography OR DECT	MeSH major topic	Focus
2	2	Diagnostic performance	MeSH heading keyword	Focus
	3	Accuracy		
	4	Radiation		
	5	Dose		
	6	2 OR 3 OR 4 OR 5		
3	7	Endovascular aneurysm repair		
	8	EVAR		
	9	7 OR 8		

OR: results must include either of the terms connected by OR

included in the literature review.

Results of the literature search

The literature search yielded 25 potential relevant articles which were exported to EndNote X6 reference management tool (Thomson Reuters, New York, NY, USA). After the removal of duplicates, eight articles remained. Screening of abstracts and titles resulted in the exclusion of one article. Screening of the full texts of the remaining articles led to the exclusion of a further two articles. A summary of the search and screening process is provided in Fig. 1.

RESULTS

This literature review identified five original studies assessing

the potential radiation dose reduction in using a DECT protocol and reporting the diagnostic accuracy of this protocol in follow-up imaging after EVAR compared to standard triphasic protocol [19-23]. Ascenti and colleagues [21], however, only compare diagnostic performance and radiation dose between the DECT protocol and the biphasic protocol (no arterial phase was performed).

CT acquisition protocol

All examinations in five studies were performed using a dual-source DECT scanner (Somatom Definition, Siemens Medical Solutions, Munich, Germany) [19-23]. A triphasic protocol was performed and comprised of a non-contrast, an arterial and a delayed phase. Besides the delayed phase being acquired in the dual-energy mode, other phases were performed using the

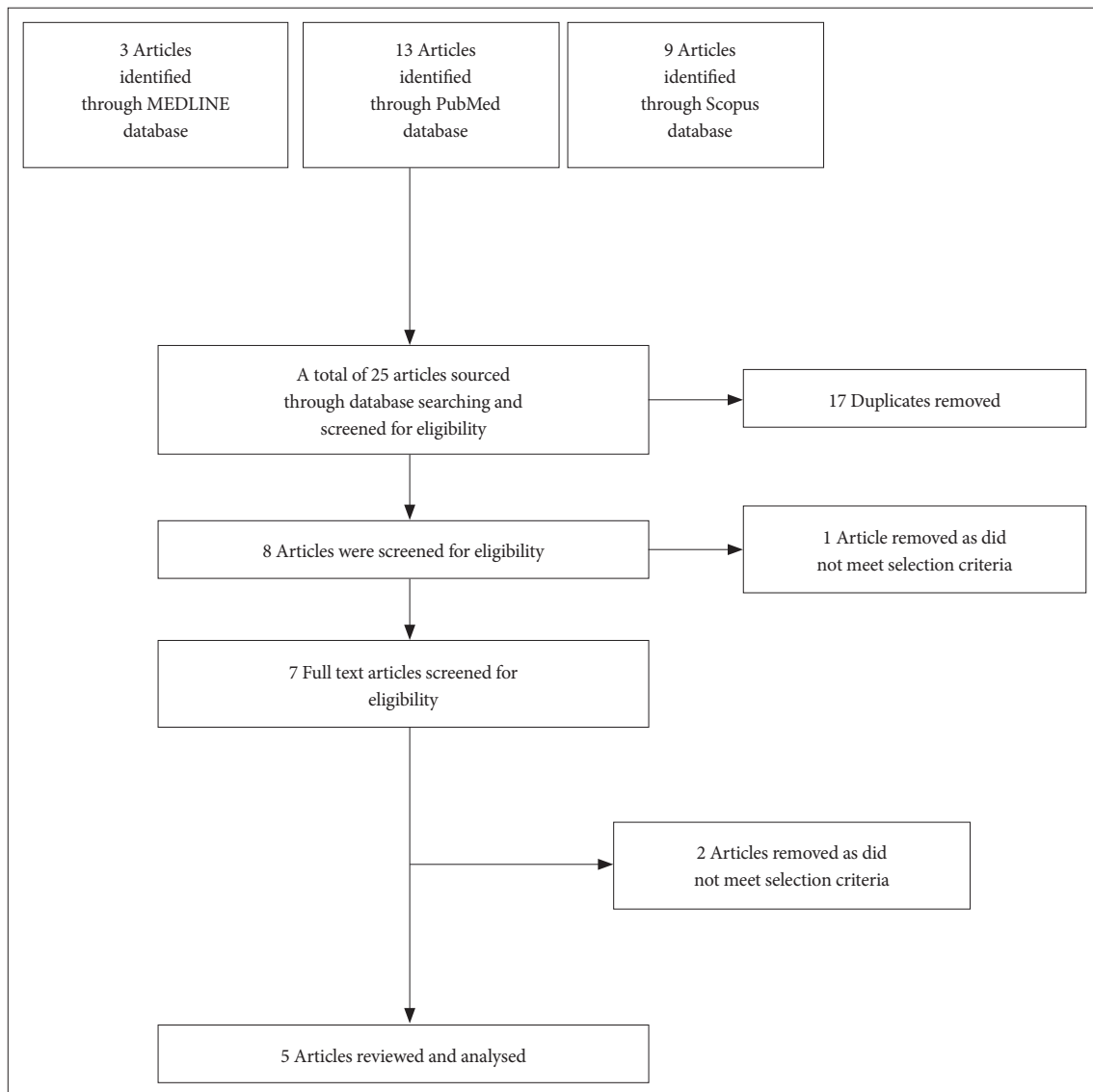


Fig. 1. A summary of the search and screening process using the modified PRISMA flow diagram. Twenty-five articles were sourced through database searching and screened for eligibility. Five articles were included for review and analysis.

single-energy mode. The dual-energy delayed phase was acquired 60 seconds after the arterial phase because the timing has been reported to be optimal for the detection and classification of low-flow endoleaks which is often missed during the arterial phase [15,16]. The area of coverage was the same as the coverage range for the non-contrast acquisition.

Radiation dose estimates

Due to a frequency of complications after EVAR, patients need a lifelong follow-up imaging which is undertaken every 1–3 months after the procedure and every 6–12 months if the aneurysm is stable or decreases in size [24]. As a result, to decrease the radiation dose to patients having surveillance scans, the number of acquisitions can be reduced [14]. For each of the CT acquisitions, patient effective dose (ED) (mSv) was calculated from the dose-length products (mGy×cm) recorded from the CT console. A normalised conversion factor (k) for the chest or abdomen was used to calculate ED (k was 0.014 and 0.017 mSv/mGy×cm, respectively) [16]. The calculated mean ED and percentages in dose reduction was pooled from five studies (Table 2).

The use of the DECT protocol resulted in a reduction in radiation exposure of 61–64.1% compared with the exposure from standard triphasic acquisition [19,20,22,23]. The study by Ascenti and colleagues [21] only examined the dose differences between the DECT protocol and the biphasic protocol (no arterial phase was performed) which resulted in a reduction of 28% in dose. This is particularly important in patients after EVAR as they will undergo lifelong follow-up imaging examinations. Besides the marked reduction in radiation dose using DECT, no studies reported the effect of this protocol on contrast media administration to the patients.

As stated previously, imaging during arterial phase is not essential in diagnosing endoleaks [15]. However, if imaging is performed immediately after EVAR, arterial phase is required to evaluate arterial injuries such as arteriovenous fistulas and pseudoaneurysms [19]. True non-contrast CT images may also be beneficial after stent deployment for assessing type IV endoleaks. This is because the isolated contrast material in type IV endoleaks could be eliminated on virtual non-contrast CT images [15]. Therefore, the use of a triphasic protocol is still critical for immediate imaging after EVAR, but DECT protocol should be then utilised in follow-up examinations to reduce the patient’s radiation burden [15].

Diagnostic performance

Five studies tested the feasibility of a single-phase DECT protocol for endoleak detection using a dual-energy mode during a delayed phase, without reducing diagnostic accuracy [19–23]. The inter-rater agreement in the detection of endoleaks was approximately 100% between the triple phase and DECT protocols among all studies. Virtual non-contrast images were enough to determine whether the high-attenuating material within the aneurysm was a calcified thrombus or an endoleak. All endoleaks were depicted during the delayed phase [19–23]. All studies have confirmed that DECT protocol has a potential to replace the standard protocol in follow-up imaging after EVAR with 98–100% overall accuracy for the detection of type I and II endoleaks (Table 3). It is not feasible to specify the diagnostic accuracy of DECT protocol according to each type of endoleaks as no studies reported such information.

In-line with the literature [19,22], the authors reported results comparing between DECT protocol and biphasic protocol (non-contrast and delayed phases) and demonstrated that eliminat-

Table 2. Mean radiation dose for the DECT protocol versus the triphasic protocol

Study	DECT protocol (mSv)	Triphasic protocol (mSv)	Dose reduction (%)
Chandarana et al., 2008 [19]	11.1	27.8	61.0
Flors et al., 2013 [20]	9.8±3.2	22.4±6.5	64.1
Ascenti et al., 2011 [21]	7.27	10.08*	28.0
Stolzmann et al., 2008 [22]	10.9	27.4	61.0
Buffa et al., 2014 [23]	10.5±1.8	27.4±2.6	61.7

*this study compared the DECT with a biphasic protocol. DECT: dual-energy CT

Table 3. Diagnostic accuracy for the detection of type I and II endoleaks

Study	Sensitivity (%)	Specificity (%)	Negative-predictive value (%)	Positive-predictive value (%)	Accuracy (%)
Chandarana et al., 2008 [19]	100	100	-	-	100
Flors et al., 2013 [20]	100	100	100	100	100
Ascenti et al., 2011 [21]	100	100	100	100	100
Stolzmann et al., 2008 [22]	100	97	100	96	98
Buffa et al., 2014 [23]	-	-	-	-	100

ing the arterial phase does not significantly decrease the diagnostic accuracy [15]. Interestingly, Buffa and colleagues [23] also found that all endoleaks were detected during the delayed phases and in only five cases (out of 32 cases), type II endoleak was not perceived during the arterial phase.

No studies evaluated the value of metal artifact reduction (MAR) post-processing using DECT in patients after EVAR. Boos and colleagues [24] reported that the use of MAR impaired endoleak visualization in 60% of cases. However, when coils were present, DECT with metal artefact reduction techniques, reduced artifacts and improved endoleak detection in 10% of cases.

Limitations

There were some limitations found in these studies. First, each study examined a relatively small number of participants/patients (n=24, 48, 74, 118, 148 respectively) [19-23]. However, all studies have significantly demonstrated that true non-contrast CT may not be necessary for the surveillance of patients after EVAR. Secondly, only type I and II endoleaks were included in all studies. Therefore, it is not possible to assess the diagnostic performance of DECT in detecting type III, IV or V endoleaks.

However, these classifications are rarely observed [22]. It is also important to note that due to the inherent limitation in the DECT scanner, authors noticed a minimal over-subtraction of the calcification in the virtual non-contrast images compared to the calcification subtraction in the true non-contrast images [19]. This could potentially result in a false-positive diagnosis of endoleaks. A larger population might be able to demonstrate this downside of DECT.

CONCLUSION

In summary, a virtual non-contrast and delayed phase dataset reconstructed from a single DECT acquisition can replace the standard triphasic protocol in follow-up imaging after EVAR for the detection of type I and II endoleaks. Further technical refinements and studies with larger population are required to accurately validate the diagnostic performance of this application. This protocol also significantly reduces the ED to the patients.

Conflicts of Interest

The author has no potential conflicts of interest to disclose.

REFERENCES

- Parodi JC, Palmaz JC, Barone HD. Transfemoral intraluminal graft implantation for abdominal aortic aneurysms. *Ann Vasc Surg* 1991;5:491-499.
- Prinssen M, Verhoeven EL, Buth J, Cuypers PW, van Sambeek MR, Balm R, et al. A randomized trial comparing conventional and endovascular repair of abdominal aortic aneurysms. *N Engl J Med* 2004;351:1607-1618.
- Bosch JL, Beinfeld MT, Halpern EF, Lester JS, Gazelle GS. Endovascular versus open surgical elective repair of infrarenal abdominal aortic aneurysm: predictors of patient discharge destination. *Radiology* 2001;220:576-580.
- Parmer SS, Carpenter JP, Stavropoulos SW, Fairman RM, Pochettino A, Woo EY, et al. Endoleaks after endovascular repair of thoracic aortic aneurysms. *J Vasc Surg* 2006;44:447-452.
- Buth J, Laheij RJ. Early complications and endoleaks after endovascular abdominal aortic aneurysm repair: report of a multicenter study. *J Vasc Surg* 2000;31:134-146.
- Zarins CK, White RA, Hodgson KJ, Schwarten D, Fogarty TJ. Endoleak as a predictor of outcome after endovascular aneurysm repair: AneuRx multicenter clinical trial. *J Vasc Surg* 2000;32:90-107.
- Görlich J, Rilinger N, Sokiranski R, Söldner J, Kaiser W, Krämer S, et al. Endoleaks after endovascular repair of aortic aneurysm: are they predictable?-initial results. *Radiology* 2001;218:477-480.
- Blum U, Voshage G, Lammer J, Beyersdorf F, Töllner D, Kretschmer G, et al. Endoluminal stent-grafts for infrarenal abdominal aortic aneurysms. *N Engl J Med* 1997;336:13-20.
- Görlich J, Rilinger N, Sokiranski R, Orend KH, Ermis C, Krämer SC, et al. Leakages after endovascular repair of aortic aneurysms: classification based on findings at CT, angiography, and radiography. *Radiology* 1999; 213:767-772.
- Iezzi R, Cotroneo AR, Filippone A, Di Fabio F, Quinto F, Colosimo C, et al. Multidetector CT in abdominal aortic aneurysm treated with endovascular repair: are unenhanced and delayed phase enhanced images effective for endoleak detection? *Radiology* 2006;241:915-921.
- Cassagnes L, Pérignon R, Amokrane F, Petermann A, Bécaud T, Saint-Lebes B, et al. Aortic stent-grafts: endoleak surveillance. *Diagn Interv Imaging* 2016;97:19-27.
- Rozenblit AM, Patlas M, Rosenbaum AT, Okhi T, Veith FJ, Laks MP, et al. Detection of endoleaks after endovascular repair of abdominal aortic aneurysm: value of unenhanced and delayed helical CT acquisitions. *Radiology* 2003;227:426-433.
- Stavropoulos SW, Charagundla SR. Imaging techniques for detection and management of endoleaks after endovascular aortic aneurysm repair. *Radiology* 2007;243:641-655.
- Tolia AJ, Landis R, Lamparello P, Rosen R, Macari M. Type II endoleaks after endovascular repair of abdominal aortic aneurysms: natural history. *Radiology* 2005;235:683-686.
- Macari M, Chandarana H, Schmidt B, Lee J, Lamparello P, Babb J. Abdominal aortic aneurysm: can the arterial phase at CT evaluation after endovascular repair be eliminated to reduce radiation dose? *Radiology* 2006;241:908-914.
- Iezzi R, Cotroneo AR, Marano R, Filippone A, Storto ML. Endovascular treatment of thoracic aortic diseases: follow-up and complications with multi-detector computed tomography angiography. *Eur J Radiol* 2008; 65:365-376.
- Johnson TR, Krauss B, Sedlmair M, Grasruck M, Bruder H, Morhard D, et al. Material differentiation by dual energy CT: initial experience. *Eur Radiol* 2007;17:1510-1517.
- Remy-Jardin M, Faivre JB, Pontana F, Hachulla AL, Tacelli N, Santangelo T, et al. Thoracic applications of dual energy. *Radiol Clin North Am* 2010; 48:193-205.
- Chandarana H, Godoy MC, Vlahos I, Graser A, Babb J, Leidecker C, et al. Abdominal aorta: evaluation with dual-source dual-energy multidetector CT after endovascular repair of aneurysms--initial observations. *Radiology* 2008;249:692-700.
- Flors L, Leiva-Salinas C, Norton PT, Patrie JT, Hagspiel KD. Endoleak detection after endovascular repair of thoracic aortic aneurysm using dual-source dual-energy CT: suitable scanning protocols and potential radiation dose reduction. *AJR Am J Roentgenol* 2013;200:451-460.
- Ascenti G, Mazziotti S, Lamberto S, Bottari A, Caloggero S, Racchiusa S, et al. Dual-energy CT for detection of endoleaks after endovascular abdominal aneurysm repair: usefulness of colored iodine overlay. *AJR Am J Roentgenol* 2011;196:1408-1414.

22. Stolzmann P, Frauenfelder T, Pfammatter T, Peter N, Scheffel H, Lachat M, et al. Endoleaks after endovascular abdominal aortic aneurysm repair: detection with dual-energy dual-source CT. *Radiology* 2008;249:682-691.
23. Buffa V, Solazzo A, D'Auria V, Del Prete A, Vallone A, Luzietti M, et al. Dual-source dual-energy CT: dose reduction after endovascular abdominal aortic aneurysm repair. *Radiol Med* 2014;119:934-941.
24. Boos J, Fang J, Heidinger BH, Raptopoulos V, Brook OR. Dual energy CT angiography: pros and cons of dual-energy metal artifact reduction algorithm in patients after endovascular aortic repair. *Abdom Radiol (NY)* 2017;42:749-758.