



**Universiteit
Leiden**
The Netherlands

Neoadjuvant ipilimumab plus nivolumab in synchronous clinical stage III melanoma

Versluis, J.M.; Reijers, I.L.M.; Rozeman, E.A.; Menzies, A.M.; Akkooi, A.C.J. van; Wouters, M.W.; ... ; Blank, C.U.

Citation

Versluis, J. M., Reijers, I. L. M., Rozeman, E. A., Menzies, A. M., Akkooi, A. C. J. van, Wouters, M. W., ... Blank, C. U. (2021). Neoadjuvant ipilimumab plus nivolumab in synchronous clinical stage III melanoma. *European Journal Of Cancer*, 148, 51-57. doi:10.1016/j.ejca.2021.02.012

Version: Publisher's Version

License: [Creative Commons CC BY 4.0 license](https://creativecommons.org/licenses/by/4.0/)

Downloaded from: <https://hdl.handle.net/1887/3638881>

Note: To cite this publication please use the final published version (if applicable).



Original Research

Neoadjuvant ipilimumab plus nivolumab in synchronous clinical stage III melanoma



Judith M. Versluis^a, Irene L.M. Reijers^a, Elisa A. Rozeman^a,
Alexander M. Menzies^{b,c}, Alexander C.J. van Akkooi^d,
Michel W. Wouters^d, Sydney Ch'ng^{b,e}, Robyn P.M. Saw^{b,e},
Richard A. Scolyer^{b,f,g}, Bart A. van de Wiel^h, Bastian Schillingⁱ,
Georgina V. Long^{b,c}, Christian U. Blank^{a,j,k,*}

^a Department of Medical Oncology, Netherlands Cancer Institute, Plesmanlaan 121, 1066 CX Amsterdam, the Netherlands

^b Melanoma Institute Australia, The University of Sydney, 40 Rocklands Rd, Wollstonecraft NSW 2065, Australia

^c Royal North Shore and Mater Hospitals, 25 Rocklands Rd, North Sydney NSW 2060, Australia

^d Department of Surgical Oncology, Netherlands Cancer Institute, Plesmanlaan 121, 1066 CX Amsterdam, the Netherlands

^e Royal Prince Alfred Hospital, 50 Missenden Rd, Camperdown NSW 2050, Australia

^f Faculty of Medicine and Health, The University of Sydney, Sydney NSW 2006, Australia

^g Tissue Pathology and Diagnostic Oncology, Royal Prince Alfred Hospital, 50 Missenden Rd, Camperdown NSW 2050, Australia

^h Department of Pathology, Netherlands Cancer Institute, Plesmanlaan 121, 1066 CX Amsterdam, the Netherlands

ⁱ Department of Dermatology, Venereology and Allergology, University Hospital Würzburg, Josef-Schneider-Straße 2, 97080 Würzburg, Germany

^j Division of Molecular Oncology and Immunology, Netherlands Cancer Institute, Plesmanlaan 121, 1066 CX Amsterdam, the Netherlands

^k Department of Internal Medicine, Leiden University Medical Center, Albinusdreef 2, 2333 Leiden, the Netherlands

Received 18 September 2020; received in revised form 18 December 2020; accepted 3 February 2021

Available online 15 March 2021

KEYWORDS

Neoadjuvant therapy;
Pathologic response;
Melanoma;
Immunotherapy

Abstract Background: Patients with synchronous clinical stage III melanoma can present with primary melanoma lesions, locally recurrent melanoma or in-transit metastases. Neoadjuvant ipilimumab plus nivolumab induces high pathologic response rates and an impressive relapse-free survival in patients with nodal macroscopic stage III melanoma. Whether primary site melanoma and in-transit metastases respond similarly to lymph node metastases with neoadjuvant immunotherapy is largely unknown. Such data would clarify whether surgical excision of these melanoma lesions should be performed before neoadjuvant therapy or whether it could be deferred and performed in conjunction with lymphadenectomy following

* Corresponding author: Department of Medical Oncology, Netherlands Cancer Institute, Plesmanlaan 121, 1066CX Amsterdam, the Netherlands.

E-mail address: c.blank@nki.nl (C.U. Blank).

neoadjuvant immunotherapy.

Patients: Patients with synchronous clinical stage III melanoma were identified from the OpACIN, OpACIN-neo and PRADO neoadjuvant trials, where all patients were treated with ipilimumab plus nivolumab. An additional case treated outside those clinical trials was included.

Results: Seven patients were identified; six patients had a concordant response in primary site melanoma lesions or in-transit metastasis and the lymph node metastases. One patient had concordant progression in both the primary and nodal tumour lesions and developed stage IV disease during neoadjuvant treatment, and thus, no resection was performed.

Conclusion: Pathologic response following neoadjuvant ipilimumab plus nivolumab in primary site melanoma lesions or in-transit metastasis is concordant with a response in the lymph node metastases, indicating that there may be no need to perform upfront surgery to these melanoma lesions prior to neoadjuvant treatment.

© 2021 Elsevier Ltd. All rights reserved.

1. Introduction

Prior to the introduction of modern systemic therapy, the prognosis of patients with very high-risk resectable melanoma was poor, with a 5-year melanoma-specific survival of 69% for AJCC (8th edition) stage IIIC and 32% for IIID patients [1]. Relapse-free survival (RFS) has been significantly improved by adjuvant administration of anti-PD-1 therapy (nivolumab or pembrolizumab) or BRAF plus MEK inhibition (dabrafenib plus trametinib for BRAFV600 E/K mutation-positive patients only) [2–4]. Nevertheless, more than 30% of patients relapse within two years despite adjuvant treatment, indicating that alternative approaches are required, such as neoadjuvant therapy.

Neoadjuvant combination blockade of PD-1 and CTLA-4 with nivolumab and ipilimumab in nodal stage III melanoma demonstrated high pathologic response rates (74–78%) and a very low rate of relapse (1.4%) in those who respond to neoadjuvant immunotherapy [5–8]. Early therapy can improve systemic control in patients with a high risk of microscopic distant metastases, as seen with these impressive RFS rates [7,8]. Furthermore, neoadjuvant therapy can reduce tumour burden, thereby minimising the extent of surgery and decreasing the morbidity of surgery, as exemplified in other malignancies, as well as guide prognosis and enable tailored adjuvant therapy [9–11].

Patients who present with synchronous lymph node metastases with primary melanoma have inferior survival compared to those with metachronous lymph node metastases or with lymph node metastases and unknown primary [12]. Furthermore, recent neoadjuvant trials have often excluded patients who present with synchronous non-nodal locoregional melanoma lesions, such as primary melanoma, locally recurrent melanoma or in-transit metastases or have required surgery to these melanoma lesions before neoadjuvant therapy.

It remains largely unknown whether primary melanoma lesions, locally recurrent melanoma or in-transit

metastases respond similarly to neoadjuvant immunotherapy as lymph node metastases. As such, standard care is to resect melanoma lesions at the primary site and in-transit metastases before neoadjuvant therapy, rather than delaying definitive treatment of these lesions until the time of the regional lymphadenectomy following neoadjuvant immunotherapy. A single study has shown that in four patients with synchronous lymph node metastases with primary melanoma or in-transit metastases all achieved a pathologic response in both sites after neoadjuvant ipilimumab plus nivolumab [13]. We sought to examine this further by examining patients presenting with synchronous clinical stage III melanoma with lesions at the primary site and in-transit metastases along with lymph node metastases, who were treated in neoadjuvant immunotherapy clinical trials without prior surgery.

2. Patients

Patients that were treated in the neoadjuvant immunotherapy trials OpACIN [5], OpACIN-neo [6] and its PRADO extension cohort [14] at Melanoma Institute Australia (MIA) or at The Netherlands Cancer Institute (NKI) were selected. An additional patient treated at University Hospital Würzburg according to the schedule of OpACIN-neo arm B was also included.

The OpACIN trial tested two cycles of ipilimumab 3 mg/kg plus nivolumab 1 mg/kg before surgery, followed by two cycles after surgery [5]. In the subsequent OpACIN-neo trial, patients were randomised to receive either two cycles ipilimumab 3 mg/kg plus nivolumab 1 mg/kg (arm A), two cycles ipilimumab 1 mg/kg plus nivolumab 3 mg/kg (arm B), or 2 cycles ipilimumab 3 mg/kg directly followed by two cycles nivolumab 3 mg/kg (arm C), all without any adjuvant treatment [6]. Patients in the PRADO extension cohort received two cycles of ipilimumab 1 mg/kg plus nivolumab 3 mg/kg,

according to the schedule of arm B in the OpACIN-neo trial [14].

Following neoadjuvant treatment, all patients underwent preoperative radiologic evaluation by computed tomography (CT). The overall radiologic response was assessed according to RECIST 1.1. Pathologic assessment of resection specimens for all patients was based on the International Neoadjuvant Melanoma Consortium (INMC) guidelines [15], defining complete response as the absence of viable tumour cells, partial response as 50% or less viable tumour cells and non-response as more than 50% viable tumour cells present in the tumour bed area.

3. Results

Seven patients with synchronous clinical stage III melanoma were identified, of which six had melanoma lesions at the primary site and one patient in-transit metastasis along with lymph node metastases (Table 1). All patients commenced neoadjuvant therapy without initial surgery and had stage IIIC disease, except for patient 1, who was stage IIIB (AJCC 8th edition) [1].

Patient 1, 3, 4, 5, 6 and 7 were treated with two cycles of ipilimumab 1 mg/kg plus nivolumab 3 mg/kg every three weeks (q3w), patient 2 received two cycles of ipilimumab 3 mg/kg q3w, directly followed by 2 cycles of nivolumab 3 mg/kg q3w. Patients 1–6 were treated within either the OpACIN-neo trial or its PRADO extension cohort; patient 7 was treated at University Hospital Würzburg in line with the OpACIN-neo

scheme arm B (2 cycles ipilimumab 1 mg/kg plus nivolumab 3 mg/kg q3w) protocol.

Patient 1 was a 52-year-old female with an in-scar recurrence of cutaneous primary melanoma on the lower leg and inguinal lymph node metastases (Fig. 1). Patient 2, a 34-year-old male, presented with an in-scar recurrence of cutaneous primary melanoma on the lower arm and axillary lymph node metastasis at recruitment. Patient 3 was a 55-year-old male who presented with primary acral melanoma on the finger and axillary lymph node metastasis (Fig. 1), and patient 4 was a 66-year-old male, with primary cutaneous melanoma on the shoulder and axillary lymph node metastases. Patient 5, a 53-year-old male, presented with an acral primary melanoma on the foot and synchronous inguinal metastasis. Patient 6 was a 72-year-old male with a cutaneous primary melanoma on the right temple and synchronous preauricular lymph node metastases. Patient 7 was a 55-year-old male who presented with an in-transit metastasis at his cutaneous primary melanoma site on the trunk and axillary lymph node metastases.

The overall radiologic response and pathologic response of both the synchronous presenting melanoma lesion at the primary site or in-transit metastasis and the lymph node metastases were concordant (Table 2). Four patients (patients 1, 3, 6 and 7) achieved a partial or complete pathologic response of both the lesion at the primary site or in-transit metastasis and the lymph node metastases; two patients (patients 2 and 4) had no pathologic response in either location (Table 3). One patient (patient 5) had disease progression in both the primary melanoma and lymph nodes and developed stage IV disease during neoadjuvant treatment, resulting in no surgical resection of the tumour lesions. His primary acral lesion was treated with radiotherapy for symptomatic control, and subsequent targeted therapy was commenced to treat the other melanoma sites. After a median follow-up of 51 weeks after surgery of the six operated patients, only patient 2, who had no pathologic response, experienced a locoregional recurrence, which was resected.

Table 1
Baseline characteristics of included patients.

	Patients (N = 7)
Age at start neoadjuvant therapy in years (median, IQR)	55.0 (52.0–66.0)
Sex	
Male	6
Female	1
Subtype primary melanoma	
Cutaneous	5
Acral	2
Synchronous presented non-nodal locoregional melanoma lesion	
Primary melanoma	4
In-scar recurrence	2
In-transit metastases	1
Site of lymph node metastasis	
Axilla	4
Inguinal	2
Pre-auricular	1
LDH level < ULN at start neoadjuvant therapy	7
Centre	
Melanoma Institute Australia	2
Netherlands Cancer Institute	4
University Hospital Würzburg	1

IQR: interquartile range; LDH: lactate dehydrogenase; ULN: upper limit of normal.

4. Discussion

In our series, pathologic response to neoadjuvant ipilimumab plus nivolumab was concordant in both the lymph node metastases and synchronous melanoma lesions at the primary site and in-transit metastasis. No patient with a pathologic response has relapsed after a median follow-up of 51 weeks. Our findings are in line with the smaller series of Weber *et al.* [13], in which all four patients had a pathologic response to neoadjuvant ipilimumab plus nivolumab in both the lymph node metastasis and synchronous primary melanoma or in-transit metastasis. Furthermore, none of these patients

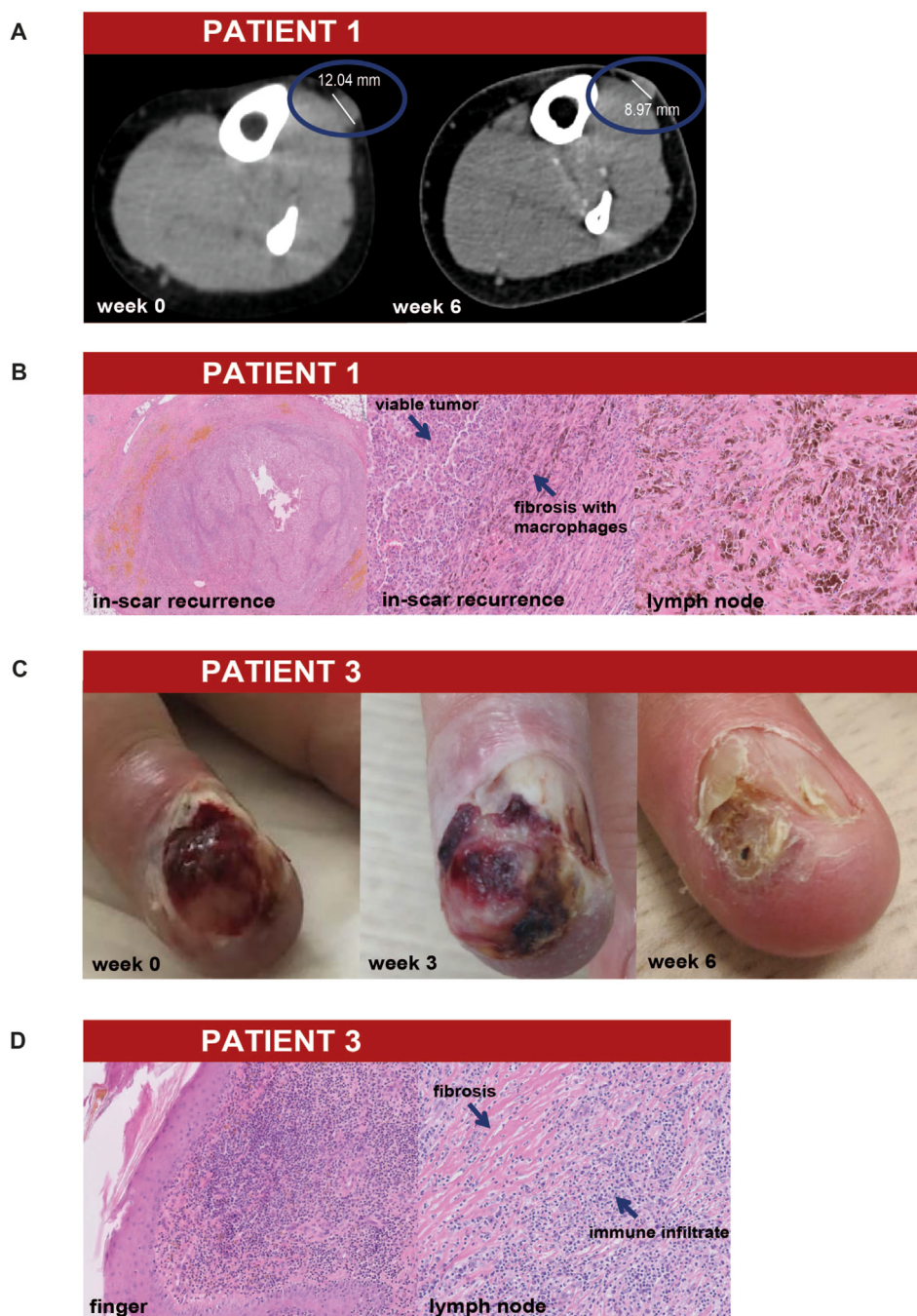


Fig. 1. CT images, photos and histopathologic details of two patients. A. In-scar recurrence on CT at week 0 and week 6 of patient 1, after two cycles of ipilimumab 1 mg/kg + nivolumab 3 mg/kg a decrease on CT was seen. B. Histopathologic patterns after two cycles of ipilimumab 1 mg/kg + nivolumab 3 mg/kg of the in-scar recurrence of patient 1, both an overview (left) and detail (middle) of the partial response. At the right a detail of the lymph node with a complete response. C. The primary melanoma at baseline of patient 3, showing an initial increase of the tumour after one cycle of ipilimumab 1 mg/kg + nivolumab 3 mg/kg at week 3. However, after two cycles at week 6 the tumour showed regression. D. Histopathologic patterns after two cycles ipilimumab 1 mg/kg + nivolumab 3 mg/kg of the finger and resected lymph node of patient 3, both with a complete response.

have relapsed with a follow-up ranging from 3.6 to 8.2 months.

Given the high pathologic response rates upon neoadjuvant ipilimumab plus nivolumab in nodal stage III melanoma and the comparable pathologic response in the primary site melanoma and in-transit metastasis, it

can be considered to postpone resection of these lesions. As neoadjuvant therapy is no standard-of-care therapy, this can be further explored in upcoming trials investigating neoadjuvant immunotherapy in stage III melanoma. These trials should not exclude patients with synchronous primary melanoma or in-transit metastases

Table 2
Treatment and clinicopathological outcome.

	Patients (N = 7)
Neoadjuvant regimen	
2x IPI 1 mg/kg + NIVO 3 mg/kg	6
2x IPI 3 mg/kg + 2x NIVO 3 mg/kg	1
Pathologic response synchronous presented non-nodal locoregional melanoma lesion	
Complete response	3
Partial response	1
No response	2
Unknown	1
Pathologic response lymph node metastasis	
Complete response	4
No response	2
Unknown	1
Radiologic response	
Complete response	1
Partial response	2
Stable disease	2
Progressive disease	2
Relapse	1

IPI: ipilimumab; NIVO: nivolumab.

and can consider within the trial design to postpone resection of these lesions until after neoadjuvant treatment to be carried out along with the lymph node dissection.

Neoadjuvant therapy might improve the survival of patients with synchronous stage III melanoma. These patients are at especially high risk of microscopic distant metastases given the simultaneous presentation of lesions at the primary site or in-transit metastases and lymph node metastases, which may reflect the aggressive biologic behaviour with a high risk of early disease recurrence [12,16]. The presence of tumour can serve as

an antigenic reservoir for T cell priming, resulting in a more diverse T cell repertoire than when immunotherapy is administered after surgery [5,17]. The presence of the primary melanoma could even broaden the T cell response further, as this has the original clones of tumour cells besides the clones that have emerged to the lymph node. In addition, neoadjuvant therapy allows an early assessment of response, which can guide prognosis and subsequent therapy choices. The first neoadjuvant trials in nodal stage III melanoma have shown promising response rates of 71–78% for combination therapy [5,6,18] and 19–25% for anti-PD-1 monotherapy [19,20].

A limitation to this study is the small number of patients, therefore requiring a larger patient cohort with longer follow-up to validate our findings. It is also a retrospective analysis, although almost all data were collected prospectively within trials. Despite the fact that patients were treated in different centres, the pathologic response assessments were standardised according to recommendations of the International Neoadjuvant Melanoma Consortium (INMC) [15], and thus are comparable.

In conclusion, pathologic response for melanoma lesions at the primary site and in-transit metastases to neoadjuvant ipilimumab plus nivolumab is concordant with the response within synchronous lymph node metastases. Considering the high response rates previously shown in lymph nodes of stage III melanoma, one may consider postponing the resection of the primary site melanoma lesion until lymph node dissection following neoadjuvant treatment. Future trials investigating neoadjuvant immunotherapy in stage III melanoma should

Table 3
Patient characteristics and their outcome.

Patient	1	2	3	4	5	6	7
Age in years	52	34	55	66	53	72	55
Sex	Female	Male	Male	Male	Male	Male	Male
Treatment scheme	2x IPI 1 mg/kg + NIVO 3 mg/kg	2x IPI 3 mg/kg + 2x NIVO 3 mg/kg	2x IPI 1 mg/kg + NIVO 3 mg/kg	2x IPI 1 mg/kg + NIVO 3 mg/kg	2x IPI 1 mg/kg + NIVO 3 mg/kg	2x IPI 1 mg/kg + NIVO 3 mg/kg	2x IPI 1 mg/kg + NIVO 3 mg/kg
Overall radiologic response	PR	PD	PR	SD	PD	CR	SD
Synchronous presented non-nodal locoregional melanoma lesion and site	In-scar recurrence lower leg	In-scar recurrence lower arm	Primary melanoma finger	Primary melanoma shoulder	Primary melanoma foot	Primary melanoma temple	In-transit trunk
Pathologic response synchronous presented non-nodal locoregional melanoma lesion	pPR (33% viable tumour cells)	pNR (60% viable tumour cells)	pCR	pNR (95% viable tumour cells)	–	pCR	pCR
Site of lymph node metastasis	Inguinal	Axillar	Axillar	Axillar	Inguinal	Preauricular	Axillar
Pathologic response lymph node metastasis	pCR	pNR (59% viable tumour cells)	pCR	pNR (90% viable tumour cells)	–	pCR	pCR
Follow-up since surgery (in weeks)	140	72	55	51	–	27	17
Relapse during follow-up	No	Yes	No	No	–	No	No

IPI: ipilimumab; NIVO: nivolumab; PR: partial response; PD: progressive disease; SD: stable disease; pPR: partial response (>10–50% viable tumour cells); pCR: complete response (0% viable tumour cells); pNR: no response (>50% viable tumour cells).

not exclude patients with synchronous primary melanoma or in-transit metastases.

Author contributions

Study concepts: JMV, ILMR, EAR, CUB. **Study design:** JMV, CUB. **Data acquisition:** JMV, AMM, BS. **Quality control of data:** JMV. **Data analysis and interpretation:** JMV performed the data analysis, all authors interpreted the data. **Manuscript preparation:** JMV and CUB co-wrote the draft manuscript. **Manuscript editing:** All authors. **Manuscript review:** All authors reviewed the manuscript and approved the final version.

Funding

This work did not receive funding; the OpACIN (NCT02437279) and OpACIN-neo trials (NCT02977052) were both investigator-initiated trials with the Netherlands Cancer Institute as the sponsor, financial support for the trials was provided by Bristol-Myers Squibb.

AMM is supported by a Cancer Institute NSW Fellowship and Melanoma Institute Australia. RAS and GVL are supported by Australian National Health and Medical Research Council Practitioner Fellowships, and were supported by an Australian National Health and Medical Research Council (NHMRC) Program Grant. GVL is supported by the Medical Foundation, The University of Sydney.

Conflict of interest statements

The authors declare the following financial interests/personal relationships that may be considered as potential competing interests: All authors declare no direct conflicts with this work. For unrelated conflicts, AMM reports an advisory role for Bristol-Myers Squibb, MSD Oncology, Novartis, Pierre Fabre and Roche. ACJvA has received advisory board and consultancy honoraria from Amgen, Bristol-Myers Squibb, Novartis, MSD-Merck, Merck-Pfizer, Sanofi and 4SC, all paid to the institute; and research grants received from Amgen, Bristol-Myers Squibb, Merck-Pfizer and Novartis, all paid to the institute. RPMS has received honoraria for advisory board participation from Merck, Sharpe & Dome, Novartis and Qbiotics and speaking honoraria from Bristol-Myers Squibb. RAS has received fees for professional services from Qbiotics Group Limited, Novartis, NeraCare, AMGEN Inc., Bristol-Myers Squibb, Myriad Genetics GmbH, GlaxoSmithKline Australia and Merck Sharp & Dohme. BS has received personal honoraria from Bristol-Myers Squibb, Merck Sharpe & Dome, Novartis, Pfizer/EMD Serono, Pierre Fabre and Roche; has an advisory role for Bristol-Myers Squibb, Merck Sharpe & Dome, Novartis, Pierre

Fabre and Roche; and has received research funding from Bristol-Myers Squibb, Merck Sharpe & Dome, and Pierre Fabre, all paid to the institute. GVL is consultant advisor for Aduro, Amgen, Bristol-Myers Squibb, Highlight Therapeutics S.L., Mass-Array, Merck, MSD, Novartis, OncoSec Medical, Pierre Fabre, Roche, Qbiotics, Skyline DX and Sandoz. CUB has received research funding from Bristol-Myers Squibb, Novartis and NanoString, all paid to the institute; has an advisory role for Bristol-Myers Squibb, Merck Sharpe & Dome, Roche, Novartis, GlaxoSmithKline, AstraZeneca, Pfizer, Lilly, GenMab and Pierre Fabre; and is stockowner of Uniti Cars.

Acknowledgements

We thank all patients and their families for their participation in the trials. The authors acknowledge support from colleagues at their respective institutions, and support from the Ainsworth Foundation is also gratefully acknowledged.

References

- [1] Gershenwald JE, Scolyer RA, Hess KR, et al. Melanoma staging: evidence-based changes in the American Joint Committee on Cancer eighth edition cancer staging manual. *CA – Cancer J Clin* 2017;67:472–92.
- [2] Eggermont AMM, Blank CU, Mandalá M, et al. Adjuvant pembrolizumab versus placebo in resected stage III melanoma. *N Engl J Med* 2018;378:1789–801.
- [3] Weber J, Mandalá M, Del Vecchio M, et al. Adjuvant nivolumab versus ipilimumab in resected stage III or IV melanoma. *N Engl J Med* 2017;377:1824–35.
- [4] Long GV, Hauschild A, Santinami M, et al. Adjuvant dabrafenib plus trametinib in stage III BRAF-mutated melanoma. *N Engl J Med* 2017;377:1813–23.
- [5] Blank CU, Rozeman EA, Fanchi LF, et al. Neoadjuvant versus adjuvant ipilimumab plus nivolumab in macroscopic stage III melanoma. *Nat Med* 2018;24:1655–61.
- [6] Rozeman EA, Menzies AM, van Akkooi ACJ, et al. Identification of the optimal combination dosing schedule of neoadjuvant ipilimumab plus nivolumab in macroscopic stage III melanoma (OpACIN-neo): a multicentre, phase 2, randomised, controlled trial. *Lancet Oncol* 2019;20:948–60.
- [7] Blank CU, Versluis JM, Reijers ILM, et al. 1313PD 3-year relapse-free survival (RFS), overall survival (OS) and long-term toxicity of (neo)adjuvant ipilimumab (IPI) + nivolumab (NIVO) in macroscopic stage III melanoma (OpACIN trial). *Ann Oncol* 2019;30:v535.
- [8] Rozeman EA, Menzies AM, Krijgsman O, et al. LBA75 18-months relapse-free survival (RFS) and biomarker analyses of OpACIN-neo: a study to identify the optimal dosing schedule of neoadjuvant (neoadj) ipilimumab (IPI) + nivolumab (NIVO) in stage III melanoma. *Ann Oncol* 2019;30:v910.
- [9] Grossman HB, Natale RB, Tangen CM, et al. Neoadjuvant chemotherapy plus cystectomy compared with cystectomy alone for locally advanced bladder cancer. *N Engl J Med* 2003;349:859–66.
- [10] Minckwitz G, Eidtmann H, Rezai M, et al. Neoadjuvant chemotherapy and bevacizumab for HER2-negative breast cancer. *N Engl J Med* 2012;366:299–309.

- [11] van Hagen P, Hulshof MC, van Lanschot JJ, et al. Preoperative chemoradiotherapy for esophageal or junctional cancer. *N Engl J Med* 2012;366:2074–84.
- [12] Weide B, Faller C, Elsässer M, et al. Melanoma patients with unknown primary site or nodal recurrence after initial diagnosis have a favourable survival compared to those with synchronous lymph node metastasis and primary tumour. *PLoS One* 2013;8:e66953.
- [13] Weber J, Glutsch V, Geissinger E, et al. Neoadjuvant immunotherapy with combined ipilimumab and nivolumab in patients with melanoma with primary or in transit disease. *Br J Dermatol* 2020 Sep;183:559–63.
- [14] Reijers I, Rozeman EA, Menzies AM, et al. Personalized response-driven adjuvant therapy after combination ipilimumab and nivolumab in high-risk resectable stage III melanoma: PRADO trial. *J Clin Oncol* 2019;37. TPS9605-TPS9605.
- [15] Tetzlaff MT, Messina JL, Stein JE, et al. Pathological assessment of resection specimens after neoadjuvant therapy for metastatic melanoma. *Ann Oncol* 2018;29:1861–8.
- [16] Messeguer F, Agustí-Mejías A, Traves V, et al. Mitotic rate and subcutaneous involvement are prognostic factors for survival after recurrence in patients with only locoregional skin metastasis as the first site of recurrence from cutaneous melanoma. *J Eur Acad Dermatol Venereol* 2013;27:436–41.
- [17] Versluis JM, Long GV, Blank CU. Learning from clinical trials of neoadjuvant checkpoint blockade. *Nat Med* 2020;26:475–84.
- [18] Blank CU, Reijers ILM, Pennington T, et al. First safety and efficacy results of PRADO: a phase II study of personalized response-driven surgery and adjuvant therapy after neoadjuvant ipilimumab (IPI) and nivolumab (NIVO) in resectable stage III melanoma. *J Clin Oncol* 2020;38. 10002–10002.
- [19] Amaria RN, Reddy SM, Tawbi HA, et al. Neoadjuvant immune checkpoint blockade in high-risk resectable melanoma. *Nat Med* 2018;24:1649–54.
- [20] Huang AC, Orlovski RJ, Xu X, et al. A single dose of neoadjuvant PD-1 blockade predicts clinical outcomes in resectable melanoma. *Nat Med* 2019;25:454–61.