

## SHORT COMMUNICATION

# A score that predicts aquaporin-4 IgG positivity in patients with longitudinally extensive transverse myelitis

Lucia Campetella<sup>1</sup>  | Claudia Papi<sup>1</sup> | Gregorio Spagni<sup>1,2</sup> | Eleonora Sabatelli<sup>1</sup> | Sara Mariotto<sup>3</sup>  | Matteo Gastaldi<sup>4,5</sup>  | Gianvito Masi<sup>1</sup> | Sara Carta<sup>3</sup> | Lara Ahmad<sup>5</sup> | Francesca Rossi<sup>6</sup> | Giorgia Teresa Maniscalco<sup>7</sup> | Giovanna De Luca<sup>8</sup> | Raffaele Iorio<sup>1,2</sup> 

<sup>1</sup>Neuroscience Department, Catholic University of the Sacred Heart, Rome, Italy

<sup>2</sup>Neurology Unit, Fondazione Policlinico Universitario "A. Gemelli" IRCCS, Rome, Italy

<sup>3</sup>Neurology Unit, Department of Neuroscience, Biomedicine and Movement Sciences, University of Verona, Verona, Italy

<sup>4</sup>Neuroimmunology Laboratory, IRCCS Mondino Foundation, Pavia, Italy

<sup>5</sup>Department of Brain and Behavioral Sciences, University of Pavia, Pavia, Italy

<sup>6</sup>Neurology Unit, Mater Salutis Hospital, Legnago, Italy

<sup>7</sup>Neurological Clinic and Multiple Sclerosis Center, A. Cardarelli Hospital, Naples, Italy

<sup>8</sup>Multiple Sclerosis Centre, Neurology Unit, SS. Annunziata Hospital, Chieti, Italy

## Correspondence

Raffaele Iorio, Neurology Unit, Fondazione Policlinico Universitario "A. Gemelli" IRCCS, Roma, Italy.  
Email: [raffaele.iorio@policlinicogemelli.it](mailto:raffaele.iorio@policlinicogemelli.it)

## Abstract

**Background and purpose:** Longitudinally extensive transverse myelitis (LETM) associated with aquaporin-4 autoantibodies (AQP4-IgG) can cause severe disability. Early diagnosis and prompt treatment are critical to prevent relapses. A novel score is described based on clinical and neuroimaging characteristics that predicts AQP4-IgG positivity in patients with LETM.

**Methods:** Patients were enrolled both retrospectively and prospectively from multiple Italian centers. Clinical and neuroimaging characteristics of AQP4-IgG positive and negative patients were compared through univariate and multivariate analysis.

**Results:** Sixty-six patients were included. Twenty-seven (41%) were AQP4-IgG positive and median age at onset was 45.5 years (range 19–81, interquartile range 24). Female sex (odds ratio [OR] 17.9, 95% confidence interval [CI] 2.6–381.9;  $p=0.014$ ), tonic spasms (OR 45.6, 95% CI 3.1–2197;  $p=0.017$ ) and lesion hypointensity on T1-weighted images (OR 52.9, 95% CI 6.8–1375;  $p=0.002$ ) were independently associated with AQP4-IgG positivity. The AQP4-IgG positivity in myelitis (AIM) score predicted AQP4-IgG positivity with 85% sensitivity and 95% specificity. Positive and negative likelihood ratios were 16.6 and 0.2 respectively. The inter-rater and intra-rater agreement in the score application were both excellent.

**Conclusions:** The AIM score predicts AQP4-IgG positivity with good sensitivity and specificity in patients with a first episode of LETM. The score may assist clinicians in early diagnosis and treatment of AQP4-IgG positive LETM.

## KEYWORDS

aquaporin 4, myelitis, myelitis, transverse, neuromyelitis optica

## INTRODUCTION

Longitudinally extensive transverse myelitis (LETM) is a characteristic feature of neuromyelitis optica spectrum disorders (NMOSDs) [1]; however, it can also be observed in other inflammatory disorders

and in infectious, vascular, metabolic or neoplastic diseases [2]. An immunoglobulin G (IgG) autoantibody binding the aquaporin-4 channel (AQP4) can be detected in up to 90% of NMOSD patients. Early recognition of AQP4-IgG positive (AQP4-IgG+) LETM and prompt immunotherapy are critical, as longer delay to diagnosis and

This is an open access article under the terms of the [Creative Commons Attribution-NonCommercial-NoDerivs](https://creativecommons.org/licenses/by-nc-nd/4.0/) License, which permits use and distribution in any medium, provided the original work is properly cited, the use is non-commercial and no modifications or adaptations are made.

© 2023 The Authors. *European Journal of Neurology* published by John Wiley & Sons Ltd on behalf of European Academy of Neurology.

treatment leads to higher disability [3]. However, AQP4-IgG testing is not always readily available, and a long turnaround time for the assay results may delay NMOSD diagnosis. In this study, our objective was to develop a score to predict AQP4-IgG positivity in patients with LETM.

## METHODS

### Study subjects

The study was approved by the Ethics Committee of the Fondazione Policlinico Universitario A. Gemelli (FPUG) (protocol #5293/15). All patients gave their informed consent to participate and the study was conducted in conformity with the World Medical Association Declaration of Helsinki.

Patients referred to the Neurology Unit of the FPUG (2012–2020) and the Fondazione Mondino Istituto Neurologico Nazionale (Pavia) (2015–2020) were retrospectively recruited. Additionally, patients were prospectively enrolled from 2020 to 2022 from the Neurology Unit of FPUG, Verona and other Italian centers (Naples, Chieti and Legnago). Demographic and clinical data were collected from the medical charts at patient admission.

Patients with the following criteria were included: (i)  $\geq 18$  years of age; (ii) first episode of isolated LETM, defined as an intramedullary hyperintense lesion on T2-weighted (T2W) magnetic resonance imaging (MRI) spanning three or more complete vertebral segments; (iii) acute/subacute onset of symptoms (nadir within 15 days); (iv) spinal cord MRI performed within 15 days from onset and before immunotherapy. Patients with compressive myelopathy, previous history of optic neuritis and hyperacute onset (nadir  $< 4$  h) were excluded [1].

Neuromyelitis optica spectrum disorder was diagnosed according to the 2015 International Consensus Diagnostic Criteria [1]. Intractable nausea and/or vomiting was defined as acute/subacute onset of nausea, vomiting and/or hiccups lasting  $\geq 48$  h [4]. Autoimmune comorbidity identified patients with a diagnosis of systemic lupus erythematosus, Sjögren syndrome and/or myasthenia gravis [1].

### AQP4-IgG testing

Patients' serum was tested for AQP4-IgG with a commercially available cell-based assay (Euroimmun, Leipzig) [5] and for myelin oligodendrocyte protein (MOG)-IgG, as previously described [6].

### Neuroimaging

All patients underwent brain and spinal cord MRI with a scanner of at least 1.5 T. Spinal cord imaging included sagittal and axial T1-weighted (T1W) and T2W sequences, and T1W contrast-enhanced imaging after gadolinium administration. Bright spotty lesions (BSLs)

were defined as small spotty lesions with intensity in T2W images equal or superior to that of cerebrospinal fluid [7].

In the prospective cohort, two raters (R.I., L.C.) independently applied the AQP4-IgG positivity in myelitis (AIM) score whilst blinded to the results of AQP4-IgG and MOG-IgG testing and the definitive diagnosis. The score was applied at time zero ( $t=0$ ), and then after 2 weeks ( $t=15$ ) to explore intra-rater reliability. Available axial T2W MRI images were independently reviewed by two raters (R. I. and L.C. in Rome, M.G. and L.A. in Pavia) for identification of BSLs, both at  $t=0$  and  $t=15$ . In the case of discordance the images were revised and discussed until a consensus was reached.

### Statistical analysis

Univariate analysis comparing AQP4-IgG+ and negative (AQP4-IgG-) patients was performed with Fisher's exact test and the non-parametric Mann-Whitney *U* test. Significance was set at  $p < 0.05$ . A multivariable logistic regression model was built to identify covariates independently associated with AQP4-IgG positivity. All covariates with  $p < 0.20$  at univariate analysis were initially inserted, and then a backward stepwise selection approach was applied to find the best fitting reduced model. The analysis was performed with JMP 13.0 (SAS Institute). Reliability was assessed through the intra-class correlation coefficient (ICC) for continuous variables and Cohen's *K* index for categorical variables.

## RESULTS

### Clinical and neuroimaging characteristics of patients with LETM and AQP4-IgG

Forty-four patients with a first episode of LETM were retrospectively identified, whilst 22 patients were prospectively enrolled, for a final cohort of 66 patients. Demographic, clinical and paraclinical features of AQP4-IgG+ and AQP4-IgG- patients are summarized in Table S1.

Twenty-seven patients (41%) tested positive for AQP4-IgG. Median age at onset was 45.5 years (range 19–81, interquartile range 24). Tonic spasms manifested early in the disease course (within the first 2 weeks from onset) in all patients. On univariate analysis, the female-to-male ratio was significantly higher in the AQP4-IgG+ group ( $p=0.002$ ). AQP4-IgG+ patients more frequently experienced intractable nausea and/or vomiting ( $p=0.002$ ), tonic spasms ( $p < 0.001$ ) and autoimmune comorbidity ( $p=0.003$ ). Conversely, history of prodromal fever or flu-like symptoms associated significantly with AQP4-IgG negativity ( $p=0.018$ ).

In AQP4-IgG+ patients the lesion more often involved the cervical cord or area postrema ( $p=0.004$  and  $p=0.003$  respectively). Additionally, involvement of central gray matter ( $p=0.038$ ) and hypointensity in T1W images (T1WI) ( $p < 0.001$ ) were significantly associated with AQP4-IgG positivity.

Final diagnoses of AQP4-IgG<sup>-</sup> patients were 15/39 (38%) idiopathic LETM, 10/39 (26%) MOG-IgG associated disease, 5/39 (13%) ischaemic myelopathy, 4/39 (10%) seronegative NMOSD, 2/39 (5%) post-infectious myelitis, 2/39 (5%) granulomatous central nervous system disorder, 1/39 (3%) acute disseminated encephalomyelitis.

On multivariate analysis, female sex (odds ratio [OR] 17.9, 95% confidence interval [CI] 2.6–381.9;  $p=0.014$ ), tonic spasms (OR 45.6, 95% CI 3.1–2197;  $p=0.017$ ) and lesion hypointensity on T1WI (OR 52.9, 95% CI 6.8–1375;  $p=0.002$ ) were independently associated with AQP4-IgG positivity.

**TABLE 1** The aquaporin-4 IgG positivity in myelitis (AIM) score.

Items	Points
Female sex	2
Intractable nausea and vomiting <sup>a</sup>	2
Tonic spasms	2
Neurogenic pruritus	2
Autoimmune comorbidity <sup>b</sup>	1
Lesion site—medulla	1
Lesion site—cervical cord	2
Hypointense lesions on T1WI	1
Absence of central gray matter involvement	-1

Abbreviations: IgG, immunoglobulin G; T1WI, T1-weighted images.

<sup>a</sup>Presence or history of.

<sup>b</sup>Diagnosis of systemic lupus erythematosus, Sjögren syndrome or myasthenia gravis.

## Bright spotty lesions

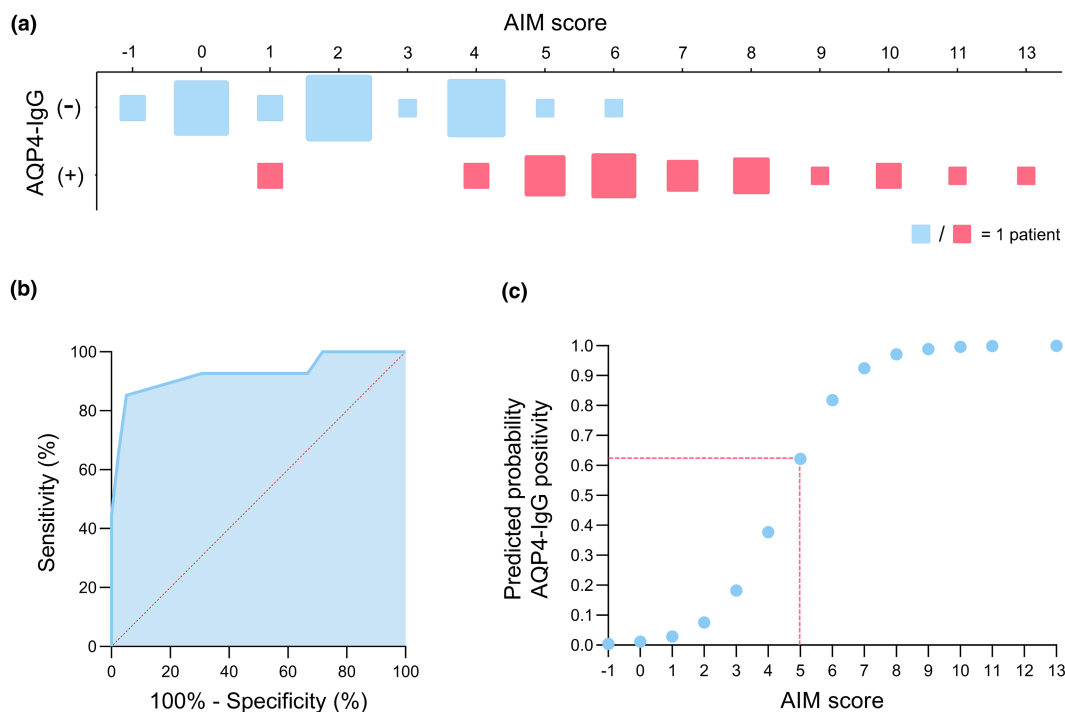
Axial T2W MR images were available for 38 patients, of whom 15 (39%) were AQP4-IgG<sup>+</sup>. BSLs were observed in 9/15 (60%) AQP4-IgG<sup>+</sup> versus 4/23 (17%) AQP4-IgG<sup>-</sup> patients ( $p=0.013$ ) and were 60% sensitive and 83% specific in detecting seropositivity. The inter-observer agreement was good at  $t=0$  (K index=0.74) and moderate at  $t=15$  (K index=0.54). Intra-observer agreement was good for both raters (K index=0.74 and 0.79).

## Score development and application

Based on the previously illustrated results, the AIM score was created featuring nine items (range -1 to 13 points) (Table 1). A score  $\geq 5$  is considered positive.

In the retrospective cohort ( $n=44$ ), sensitivity was 87% and specificity 90%. Among the prospectively enrolled patients ( $n=22$ ), four (18%) were AQP4-IgG<sup>+</sup>; the AIM score had 75% sensitivity and 100% specificity, since none of the AQP4-IgG<sup>-</sup> patients had a score  $\geq 5$  but one of the four seropositive patients had a score of 4.

Applied to the whole population, the AIM score was 85% sensitive and 95% specific in predicting AQP4-IgG positivity, with 91% accuracy (95% CI 81.3%–96.6%) and area under the curve of 93% (95% CI 85%–99%) (Figure 1a,b). The positive likelihood ratio and the negative likelihood ratio were 16.6 and 0.2 respectively. Estimating a



**FIGURE 1** Sensitivity and specificity of the aquaporin-4 IgG positivity in myelitis (AIM) score. (a) Distribution of the AIM score in the whole population according to aquaporin-4 IgG positivity. (b) Receiver operating characteristic curve for the AIM score. The score yields a sensitivity of 85%, specificity of 95% and accuracy of 91%. (c) Simple logistic regression analysis showing predicted fraction of aquaporin-4 IgG positivity in patients with a first episode of LETM, according to different values of the AIM score. The red dotted line indicates the AIM score cut-off of 5.

pre-test probability of 40% of detecting AQP4-IgG in LETM patients, the positive and negative post-test probabilities were 92% and 10%.

An increasing score correlated directly with increasing risk of AQP4-IgG positivity (Figure 1c): with a score of 5, the risk is 62%, reaching a probability of 82% with a score of 6 and of 92% with 7. A score equal or superior to 8 identifies AQP4-IgG positivity with a high level of probability (97%–100%). Conversely, a score ranging between –1 and 1 virtually excludes seropositivity, with a risk between 0% and 3%. Inter-observer and intra-observer agreement in the application of the score were excellent (ICC = 1).

## DISCUSSION

Herein, a novel clinical score is described to predict AQP4-IgG positivity in patients with a first episode of LETM. The AIM score has a high sensitivity and specificity, strengthened by its significant reliability. It is a short, easy and practical score, meant to be applied by the neurologist after a thorough clinical evaluation and when the spinal cord MRI results are available.

Our results are in line with previous studies aiming at differentiating AQP4-IgG+ myelitis from seronegative NMOSD and other etiologies. It was confirmed that AQP4-IgG+ patients are predominantly female [8–12] and are often affected by tonic spasms [9], intractable nausea/vomiting [9, 11] and systemic autoimmunity [10–12]. Cervico-medullary involvement and T1 hypointensity were characteristic of AQP4-IgG+ patients, as previously reported [8, 9, 13]. It was also observed that BSLs were highly specific for AQP4-IgG+ LETM, and the relative intra-rater and inter-rater agreement ranged from moderate to good [8, 14]. Nonetheless, despite being a valuable aid in the differential diagnosis, BSL recognition remains operator-dependent and requires specific expertise.

The majority of NMOSD attacks are treated with high-dose steroids as first-line therapy; however, recovery is frequently incomplete [15]. Adjunction of a second treatment course improves outcome, and plasma exchange appears especially effective in isolated spinal attacks [15]. In this regard, the AIM score could provide clues for rapid and targeted therapeutical decisions, allowing for both a shorter delay to immunotherapy and the timely implementation of combined treatment regimens.

Study limitations include its small sample size and the retrospective collection of data with the related possible observer bias; moreover, information on some clinical features was not systematically collected for the whole cohort.

In conclusion, the AIM score is highly sensitive and specific, emerging as a useful tool for the early detection of AQP4-IgG+ NMOSD. It is proposed that patients with a positive score should be treated early with plasma exchange to limit disability and improve outcome. Further studies on larger populations are needed to validate the score.

## AUTHOR CONTRIBUTIONS

**Lucia Campetella:** Conceptualization; data curation; formal analysis; investigation; methodology; visualization; writing – original draft.

**Claudia Papi:** Investigation. **Gregorio Spagni:** Formal analysis; investigation. **eleonora Sabatelli:** Investigation. **Sara Mariotto:** Investigation. **Matteo Gastaldi:** Investigation. **Gianvito Masi:** Investigation. **Sara Carta:** Investigation. **Lara Ahmad:** Investigation. **Francesca Rossi:** Investigation. **Giorgia Teresa Maniscalco:** Investigation. **Raffaele Iorio:** Conceptualization; data curation; formal analysis; investigation; methodology; supervision; visualization.

## ACKNOWLEDGEMENTS

None.

## FUNDING INFORMATION

None.

## CONFLICT OF INTEREST STATEMENT

The authors have no conflict of interest to declare.

## DATA AVAILABILITY STATEMENT

The data that support the findings of this study are available from the corresponding author upon reasonable request.

## ORCID

Lucia Campetella  <https://orcid.org/0000-0003-3415-6428>

Sara Mariotto  <https://orcid.org/0000-0002-7806-3103>

Matteo Gastaldi  <https://orcid.org/0000-0003-2288-2000>

Raffaele Iorio  <https://orcid.org/0000-0002-6270-0956>

## REFERENCES

1. Wingerchuk DM, Banwell B, Bennett JL, et al. International consensus diagnostic criteria for neuromyelitis optica spectrum disorders. *Neurology*. 2015;85(2):177-189. doi:10.1212/WNL.0000000000001729
2. Trebst C, Raab P, Voss EV, et al. Longitudinal extensive transverse myelitis—it's not all neuromyelitis optica. *Nat Rev Neurol*. 2011;7(12):688-698. doi:10.1038/nrneurol.2011.176
3. Mealy MA, Mossburg SE, Kim SH, et al. Long-term disability in neuromyelitis optica spectrum disorder with a history of myelitis is associated with age at onset, delay in diagnosis/preventive treatment, MRI lesion length and presence of symptomatic brain lesions. *Mult Scler Relat Disord*. 2019;28:64-68. doi:10.1016/j.msard.2018.12.011
4. Shosha E, Dubey D, Palace J, et al. Area postrema syndrome: frequency, criteria, and severity in AQP4-IgG-positive NMOSD. *Neurology*. 2018;91(17):e1642-e1651. doi:10.1212/WNL.0000000000006392
5. Waters PJ, McKeon A, Leite MI, et al. Serologic diagnosis of NMO: a multicenter comparison of aquaporin-4-IgG assays. *Neurology*. 2012;78(9):665-671; discussion 669. doi:10.1212/WNL.0b013e318248dec1
6. Ferilli MAN, Valeriani M, Papi C, et al. Clinical and neuroimaging characteristics of MOG autoimmunity in children with acquired demyelinating syndromes. *Mult Scler Relat Disord*. 2021;50:102837. doi:10.1016/j.msard.2021.102837
7. Hyun JW, Kim SH, Jeong IH, Lee SH, Kim HJ. Bright spotty lesions on the spinal cord: an additional MRI indicator of neuromyelitis optica spectrum disorder? *J Neurol Neurosurg Psychiatry*. 2015;86(11):1280-1282. doi:10.1136/jnnp-2014-309761
8. Chee CG, Park KS, Lee JW, et al. MRI features of aquaporin-4 antibody-positive longitudinally extensive transverse myelitis: insights

- into the diagnosis of neuromyelitis optica spectrum disorders. *AJNR Am J Neuroradiol*. 2018;39(4):782-787. doi:10.3174/ajnr.A5551
9. Iorio R, Damato V, Mirabella M, et al. Distinctive clinical and neuroimaging characteristics of longitudinally extensive transverse myelitis associated with aquaporin-4 autoantibodies. *J Neurol*. 2013;260(9):2396-2402. doi:10.1007/s00415-013-6997-9
  10. Kitley J, Leite MI, Kuker W, et al. Longitudinally extensive transverse myelitis with and without aquaporin 4 antibodies. *JAMA Neurol*. 2013;70(11):1375-1381. doi:10.1001/jamaneurol.2013.3890
  11. Flanagan EP, Kaufmann TJ, Krecke KN, et al. Discriminating long myelitis of neuromyelitis optica from sarcoidosis. *Ann Neurol*. 2016;79(3):437-447. doi:10.1002/ana.24582
  12. Jarius S, Ruprecht K, Wildemann B, et al. Contrasting disease patterns in seropositive and seronegative neuromyelitis optica: a multicentre study of 175 patients. *J Neuroinflammation*. 2012;9:14. doi:10.1186/1742-2094-9-14
  13. Pekcevik Y, Mitchell CH, Mealy MA, et al. Differentiating neuromyelitis optica from other causes of longitudinally extensive transverse myelitis on spinal magnetic resonance imaging. *Mult Scler*. 2016;22(3):302-311. doi:10.1177/1352458515591069
  14. Rabaste S, Cobo-Calvo A, Nistiriuc-Muntean V, et al. Diagnostic value of bright spotty lesions on MRI after a first episode of acute myelopathy. *J Neuroradiol*. 2021;48(1):28-36. doi:10.1016/j.neurad.2020.04.006
  15. Kleiter I, Gahlen A, Borisow N, et al. Neuromyelitis optica: evaluation of 871 attacks and 1,153 treatment courses. *Ann Neurol*. 2016;79(2):206-216. doi:10.1002/ana.24554

## SUPPORTING INFORMATION

Additional supporting information can be found online in the Supporting Information section at the end of this article.

**How to cite this article:** Competella L, Papi C, Spagni G, et al. A score that predicts aquaporin-4 IgG positivity in patients with longitudinally extensive transverse myelitis. *Eur J Neurol*. 2023;00:1-5. doi:10.1111/ene.15863