



## Case report

## A pediatric case of ureterolithiasis due to cystinuria accompanied by acute appendicitis; a case report

Tomohiro Hiraoka<sup>a,b,\*</sup>, Mai Kawamura<sup>a</sup>, Keisuke Takada<sup>a</sup>, Tadashi Moriwake<sup>a</sup><sup>a</sup> Department of Pediatrics, Iwakuni Clinical Center, Yamaguchi, Japan<sup>b</sup> Department of Emergency, Critical Care, and Disaster Medicine, Okayama University Graduate School of Medicine, Dentistry, and Pharmaceutical Sciences, Okayama, Japan

## ARTICLE INFO

## Keywords:

Cystinuria  
 Ureterolithiasis  
 Cystine  
 Acute appendicitis  
 Case report

## ABSTRACT

**Introduction:** Acute abdominal pain, a chief complaint frequently seen in the emergency department, can be triggered by a vast range of conditions. Although ureterolithiasis is a less common cause in children, renal colic can be caused by calculi due to hereditary metabolic diseases among patients in those age groups.

**Presentation of case:** We report a 12-year-old girl with abdominal pain who was diagnosed with concurrent acute appendicitis and ureterolithiasis due to cystinuria. Acute appendicitis was successfully treated with cefmetazole, and the calculus was eliminated after adequate fluid loading.

**Discussion:** Synchronous acute appendicitis and ureterolithiasis is reported to be rare. Cystinuria is a hereditary metabolic stone-forming disease, and the first calculi can be detected in childhood. Increasing the solubility of cystine in the urine is required to prevent recurrent stone formation and accompanying complications. Urinalysis, ultrasound, and computed tomography coincidentally demonstrated two different acute pathological processes of ureterolithiasis and appendicitis.

**Conclusion:** Careful physical and laboratory examination can help clinicians find coexisting etiologies of acute abdominal pain. Ureterolithiasis can be seen in children with hereditary disorders such as cystinuria. Early diagnosis of cystinuria and close monitoring may lead to a better long-term outcome.

## 1. Introduction

Acute abdominal pain is a common symptom evaluated in emergency department visits. Etiologies range from clinically non-significant pathologies to severe and life-threatening conditions [1]. Pediatric patients presenting with acute abdominal pain account for 5.1 % of nonscheduled visits, and the symptoms subsequently proceed to more serious conditions in approximately 1–2 % of children, although most cases were self-limited conditions [2]. Differential diagnoses of acute pain in the right lower quadrant of the abdomen in the pediatric population include ovarian or testicular torsion, acute appendicitis, musculoskeletal pain referred from the lower extremities, and enteritis. Although rare, ureterolithiasis may manifest similar to acute appendicitis, exhibiting peritoneal signs, intractable pain, and acute onset of nausea and vomiting.

Cystinuria is a genetic disorder that causes recurrent ureterolithiasis. Its diagnosis may be challenging for emergency health providers since it

presents with a variety of abdominal manifestations. However, awareness of the epidemiology of its onset in children will allow early detection and potentially better outcomes. We report a case of a successfully treated 12-year-old girl with ureterolithiasis due to cystinuria accompanied by acute appendicitis. Our experience is a reminder that ureterolithiasis, particularly in children, may arise from rare inherited metabolic disorders. Obstructive ureteric stones are linked to a high risk of renal impairment and infectious complications, warranting fast and appropriate treatment by pediatric/metabolic specialists for life-long treatment.

This case report has been reported in accordance with the SCARE guidelines [3].

## 2. Case presentation

A 12-year-old girl presented with a four-day history of vomiting and worsening pain in the right flank and periumbilical region. Physical

\* Corresponding author at: Department of Emergency, Critical Care, and Disaster Medicine, Okayama University Graduate School of Medicine, Dentistry, and Pharmaceutical Sciences, 2-5-1 Shikata-cho, Kita-Ku, Okayama 700-8558, Japan.

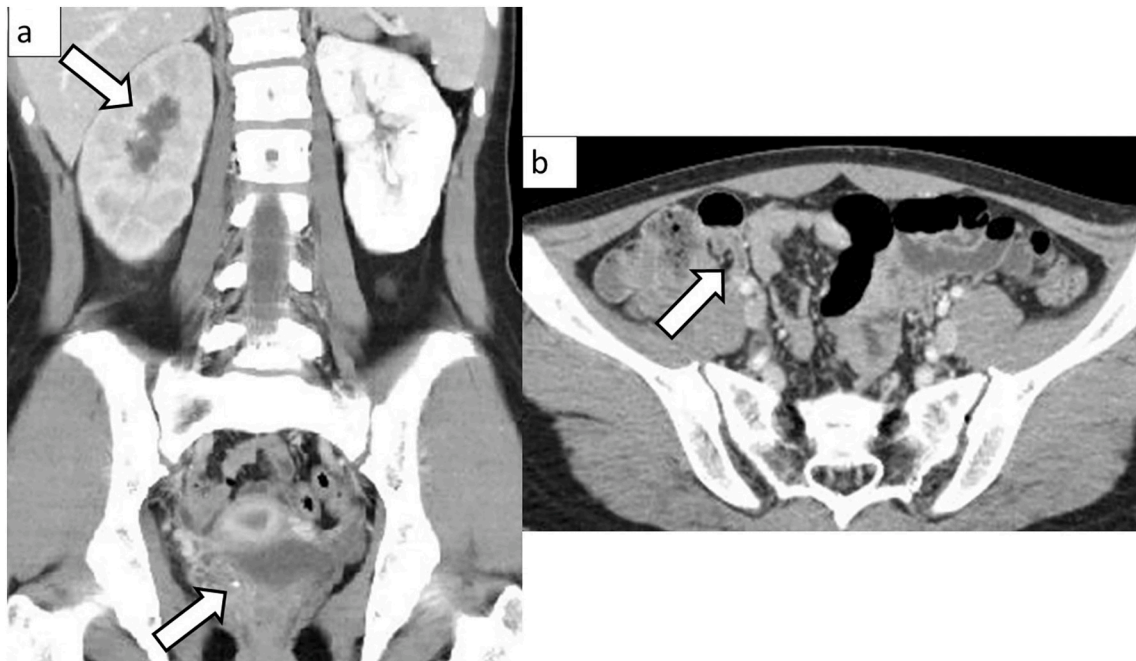
E-mail address: [tomohiro.hiraoka@gmail.com](mailto:tomohiro.hiraoka@gmail.com) (T. Hiraoka).

<https://doi.org/10.1016/j.ijscr.2022.107596>

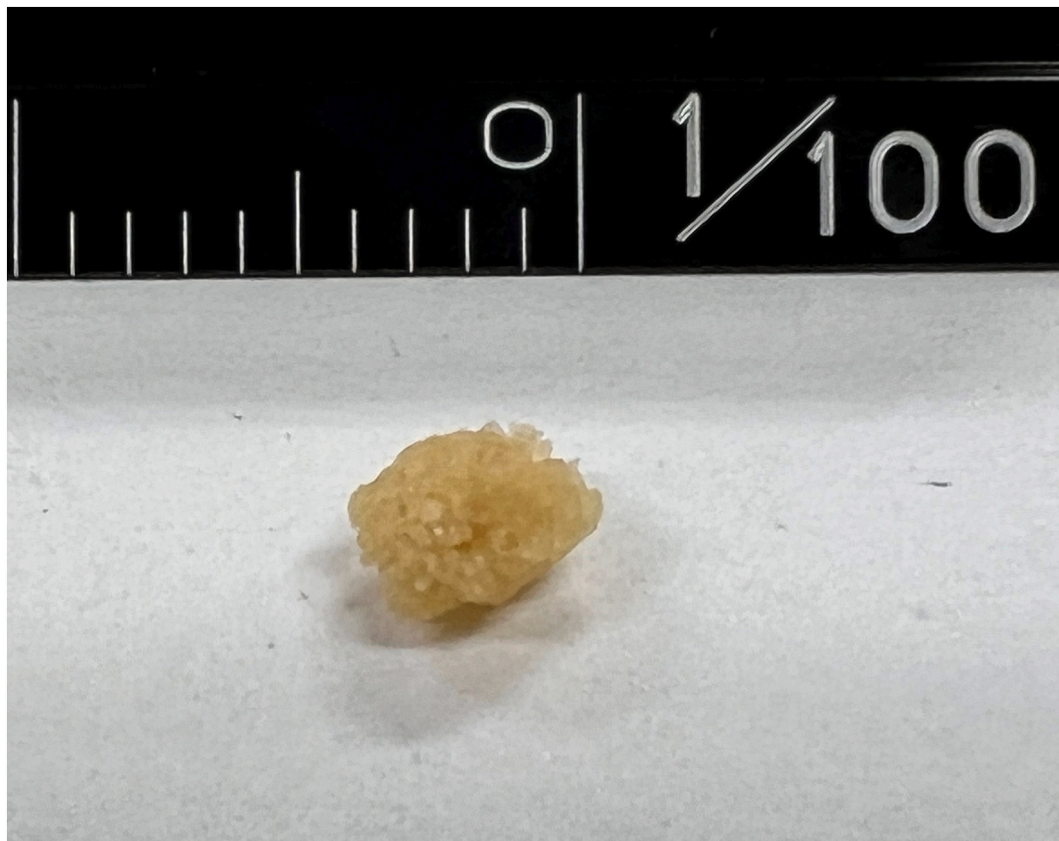Received 18 August 2022; Received in revised form 31 August 2022; Accepted 31 August 2022

Available online 5 September 2022

2210-2612/© 2022 The Authors. Published by Elsevier Ltd on behalf of IJS Publishing Group Ltd. This is an open access article under the CC BY-NC-ND license (<http://creativecommons.org/licenses/by-nc-nd/4.0/>).



**Fig. 1.** a) Ureterolithiasis (4.2 mm) at the right vesicoureteral junction with moderate hydronephrosis. b) Acute appendicitis (8.0 mm) without perforation and abscess formation.



**Fig. 2.** Eliminated ureteric calculi consists of cystine.

examination demonstrated a body temperature of 37.6 °C and right lower quadrant tenderness with slight guarding and rebound, as well as costovertebral angle tenderness. Blood test results revealed normal white blood cell count of  $8.37 \times 10^3/\mu\text{L}$  (normal range for children of

this age,  $4.5\text{--}13.0 \times 10^3/\mu\text{L}$ ) with neutrophilia of 77.8 %, normal urinary function, and slightly elevated C-reactive protein of 0.36 mg/dL ( $<0.14$  mg/dL). Urinalysis results indicated dipstick hematuria of 3+ and microscopic erythrocytes of 1–4 /high-powered field. Enhanced

abdominal computed tomography (CT) depicted a thickened appendix measuring 8.0 mm and a calculus measuring 4.2 mm at the right vesicoureteral junction with moderate hydronephrosis (Fig. 1). A clinical diagnosis of acute appendicitis associated with obstructive ureterolithiasis was made. The patient was successfully treated with intravenous cefmetazole and hydration with the resolution of abdominal pain and hydronephrosis after spontaneous ureteric stone passage on day 4 (Fig. 2). Amino acid analysis of the urine specimen collected at admission showed an elevated cystine level of 3021.1 nmol/mgCr (<76 nmol/mgCr). Cystinuria was diagnosed based on stone analysis and increased urinary secretion of cystine.

An interval appendectomy was scheduled two months later. Adequate fluid intake and administration of potassium citrate were recommended for the prevention of recurrent stone formation, and continued regular urological check-ups and genetic consultations were planned.

### 3. Clinical discussion

Pediatric cases with concurrent acute appendicitis and ureterolithiasis with hydronephrosis like our patient are rarely reported [4–6], although each disease is quite common in adults. Acute appendicitis accounts for 1 to 8 % of children who present to pediatric emergency departments with abdominal pain [7]. Ureterolithiasis is also a well-known culprit that can provoke colicky abdominal pain, while its incidence in children is reported to be 5 to 10 % of that in adults [8]. If the patient is initially diagnosed with acute appendicitis, ureterolithiasis may be overlooked in the emergency medicine setting.

Patients with cystinuria have a hereditary impairment of reabsorption of cystine in the renal proximal tubule, resulting in the formation of urinary cystine stones. The overall prevalence is 1 in 7000 births. The first experience of stone formation happens between 11 and 20 years of age, but it can be seen before three years old [9,10]. The diagnosis of cystinuria is established by stone composition analysis, presence of the typical hexagonal cystine crystals on microscopic examination, and urinary cystine excretion quantified in a 24-hour urine collection. Genetic testing is not required for the diagnosis but is useful for atypical cases or genetic counseling. Treatment in the acute symptomatic phase includes adequate fluid acquisition and urinary alkalization with potassium citrate to maintain cystine in the urine under the soluble level. Restriction of sodium and animal proteins can reduce cystine excretion and production. Response to therapy should be initially monitored every three to six months until patients are stabilized on therapy [9]. Surgical indications in children do not differ from those in adults, although general anesthesia is necessary for children. The upper limit for stone diameter allowing spontaneous elimination during medical treatment is 5 mm. Extracorporeal shock wave lithotripsy (ESWL) is the appropriate treatment for ureteric stones larger than 5 mm in diameter, particularly in the pelvic ureter. Since cystine stones are relatively resistant to ESWL, flexible ureteroscopy and percutaneous nephrolithotomy are preferred for stones larger than 15 mm [8,9]. Close follow-up to the stone formation and associated complications is the key to achieving the best long-term outcomes in cystinuria; consultation with pediatric urologists or experts in metabolic disorders is warranted.

Ultrasound is a widely-used technique to evaluate the presence of stones and hydronephrosis in patients with ureterolithiasis, but it is less sensitive for smaller or multiple stones [11]. Abdominal CT is the appropriate imaging modality choice due to its high sensitivity and specificity for the assessment of acute appendicitis, ureterolithiasis, and concomitant complications [5,7,8], except for the radiologic burden on children [12]. Therefore, the first screening and follow-up should be performed using ultrasound, and CT should be reserved for missed stones on ultrasound or complicated cases requiring detailed information about pathologies and anatomies.

### 4. Conclusion

Ureterolithiasis is less common in children but can be encountered due to hereditary metabolic disorders. Early diagnosis and prevention of recurrent stone formation can lead to a better prognosis for patients with cystinuria. A careful physical and laboratory examination can help clinicians consider the probability of different coexisting diagnoses that may be overlooked.

### Provenance and peer review

Not commissioned, externally peer-reviewed.

### Funding

None.

### Ethical approval

Not applicable.

### Consent

Written informed consent was obtained from the patient and the patient's parents for publication of this case report and accompanying images. A copy of the written consent is available for review by the Editor-in-Chief of this journal on request.

### Author contribution

TH wrote the manuscript.  
MK and KT were involved in managing the patient.  
TM supervised and approved the manuscript.

### Registration of research studies

None.

### Guarantor

Tomohiro Hiraoka.

### Declaration of competing interest

None.

### References

- [1] W.H. Lee, S. O'Brien, D. Skarin, J.A. Cheek, J. Deitch, R. Nataraja, et al., Pediatric abdominal pain in children presenting to the emergency department, *Pediatr. Emerg. Care* 37 (12) (2021) 593–598.
- [2] S.J. Scholer, K. Pituch, D.P. Orr, R.S. Dittus, Clinical outcomes of children with acute abdominal pain, *Pediatrics* 98 (4 Pt 1) (1996) 680–685.
- [3] R.A. Agha, T. Franchi, C. Sohrabi, G. Mathew, for the SCARE Group, The SCARE 2020 guideline: updating consensus Surgical Case Report (SCARE) guidelines, *Int. J. Surg.* 84 (2020) 226–230.
- [4] E.K. Lang, E. Castle, J. Trecek, Computerized tomography diagnosis of right ureteral calculus and coexisting acute appendicitis, *J. Urol.* 173 (6) (2005) 2148.
- [5] A. Spiel, W. Cowden, Synchronous obstructive ureterolithiasis and acute appendicitis, *J. Surg. Case Rep.* 2012 (9) (2012) 16.
- [6] S.C. Daniel, A. Bernstein, S.A. Ramirez, B.L. Morel, B. Khurana, Acute synchronous appendicitis and obstructing ureterolithiasis, *Radiol. Case Rep.* 13 (5) (2018) 952–954.
- [7] S.G. Rothrock, J. Pagane, Acute appendicitis in children: emergency department diagnosis and management, *Ann. Emerg. Med.* 36 (1) (2000) 39–51.
- [8] G. Marra, F. Taroni, A. Berrettini, E. Montanari, G. Manzoni, G. Montini, Pediatric nephrolithiasis: a systematic approach from diagnosis to treatment, *J. Nephrol.* 32 (2) (2019) 199–210.
- [9] V. D'Ambrosio, G. Capolongo, D. Goldfarb, G. Gambaro, P.M. Ferraro, Cystinuria: an update on pathophysiology, genetics, and clinical management, *Pediatr. Nephrol.* 37 (8) (2022) 1705–1711.

- [10] J. Chillarón, M. Font-Llitjós, J. Fort, A. Zorzano, D.S. Goldfarb, V. Nunes, et al., Pathophysiology and treatment of cystinuria, *Nat. Rev. Nephrol.* 6 (7) (2010) 424–434.
- [11] C. Moş, G. Holt, S. Iuhasz, D. Moş, I. Teodor, M. Hälbac, The sensitivity of transabdominal ultrasound in the diagnosis of ureterolithiasis, *Med. Ultrason.* 12 (3) (2010) 188–197.
- [12] D.B. Larson, L.W. Johnson, B.M. Schnell, M.J. Goske, S.R. Salisbury, H.P. Forman, Rising use of CT in child visits to the emergency department in the United States, 1995–2008, *Radiology* 259 (3) (2011) 793–801.