

[CASE REPORT]

Co-occurrence of Three Systemic Diseases: ANCA-associated Vasculitis, Sjögren's syndrome and Sarcoidosis

Kenji Tsuji, Yuka Okuyama, Yosuke Asano, Kimitomo Yamaoka, Shinji Kitamura and Jun Wada

Abstract:

Anti-neutrophil cytoplasmic antibody (ANCA)-associated vasculitis (AAV), Sjögren's syndrome (SjS), and sarcoidosis are systemic diseases targeting multiple organs. While a careful differential diagnosis of these diseases is often required, their co-occurrence in the same patient has been previously reported. We herein report a 58-year-old Japanese man diagnosed with the co-occurrence of three systemic diseases (AAV, SjS, and sarcoidosis) in addition to monoclonal gammopathy of undetermined significance (MGUS), which emphasizes the importance of considering the possible co-occurrence of these diseases as well as their differentiation.

Key words: ANCA-associated vasculitis, Sjögren's syndrome, sarcoidosis, monoclonal gammopathy of undetermined significance

(Intern Med 62: 2215-2221, 2023)

(DOI: 10.2169/internalmedicine.0966-22)

Introduction

Anti-neutrophil cytoplasmic antibody (ANCA)-associated vasculitis (AAV) is a systemic disease characterized as the inflammation of small vessels in various organs (1). Sjögren's syndrome (SjS) is also a systemic disease characterized by symptoms of dry eyes and dry mouth and sometimes involves other organs, including the lung, kidney, and skin (2). Although the detailed mechanism underlying sarcoidosis is unclear, it is also a systemic granulomatous disease, typically involving the lung, lymph nodes, eye, skin, and kidney (3).

Generally, a careful differentiation of these diseases is required. However, their co-occurrence in the same patient has been reported. For example, there have been reports of the co-occurrence of SjS and sarcoidosis (4, 5) as well as the co-occurrence of AAV and SjS (6, 7).

We herein report a patient with the co-occurrence of three systemic diseases (AAV, SjS, and sarcoidosis) in addition to monoclonal gammopathy of undetermined significance (MGUS).

Case Report

A 58-year-old man without any remarkable medical history was referred to our department because of an increase in serum creatinine (s-Cr) levels (from 0.7 to 1.32 mg/dL within 1 year), in addition to urinary protein and occult blood findings at medical examinations. He had experienced general malaise from six months prior to admission and a low-grade fever at night from one month before admission. He had no symptoms of rash, weight loss, blurry vision, or photophobia, was not taking any medications, and had no family history of kidney or rheumatological diseases.

On admission, the patient's body temperature was 36.4°C, pulse rate was 76 per minute, and blood pressure was 124/74 mmHg. His laboratory data on admission are shown in Table, indicating elevated levels of s-Cr (1.60 mg/dL), serum immunoglobulin G (IgG, 2,590.3 mg/dL), immunoglobulin M (IgM, 454.8 mg/dL), soluble interleukin-2 receptor (sIL-2R, 2,764 U/mL), and angiotensin converting enzyme (ACE, 22.9 U/L) as well as positive myeloperoxidase anti-neutrophil cytoplasmic antibodies (MPO-ANCA) and anti-SS-A antibodies. A urinalysis revealed mild proteinuria

Department of Nephrology, Rheumatology, Endocrinology and Metabolism, Okayama University Academic Field of Medicine, Dentistry, and Pharmaceutical Sciences, Japan

Received: September 5, 2022; Accepted: October 20, 2022; Advance Publication by J-STAGE: November 30, 2022

Correspondence to Dr. Kenji Tsuji, gmd422036@s.okayama-u.ac.jp

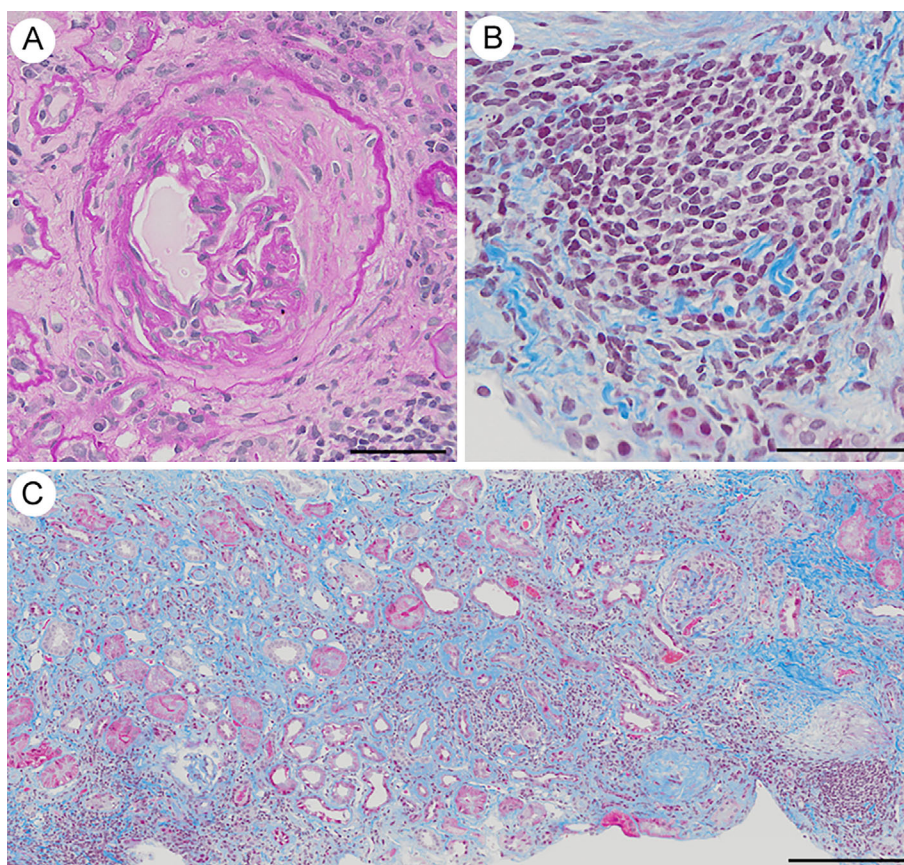


Figure 1. Pathological findings of a renal biopsy by light microscopy. (A) Representative image with Periodic acid-Schiff staining, showing a fibrocellular crescent in a glomerulus. Scale bar: 50 μm . (B, C) Representative images of Masson's trichrome staining, showing massive inflammatory cell infiltration in the renal tubulointerstitium. Scale bars: (B) 50 μm and (C) 200 μm .

(EBUS-TBNA) from the mediastinal lymph node (#4R), which revealed noncaseating granuloma (Fig. 2E). Transthoracic echocardiography and electrocardiogram (ECG) analyses revealed no apparent abnormal findings. Ga scintigraphy showed no abnormal ^{67}Ga uptake.

Because of positive anti-SS-A antibodies, further analyses were performed to differentiate SjS. The patient showed no signs of dry mouth or eyes. An ophthalmological examination revealed no evidence of uveitis or vasculitis, Schirmer's test was 15 mm/5 mm, and the fluorescein clearance test was negative. While Saxon's test and gum test were not conducted, as he had no mandibular dentures to chew, a further examination involving a labial salivary gland biopsy revealed interstitial infiltration of lymphocytes (>1 focus/ 4 mm^2) (Fig. 3).

In addition, serum protein electrophoresis was positive for lambda light chain-restricted monoclonal protein (IgM), and urine protein electrophoresis was positive for free lambda light chains. The count on the bone marrow aspirate smear showed 2.8% plasma cells. A bone marrow biopsy revealed no evidence of malignant lymphoma or malignant myeloma. Finally, he was diagnosed with MGUS.

Based on the combined positivity for MPO-ANCA and pauci-immune crescentic glomerulonephritis, the patient was diagnosed with AAV. It was initially suspected that non-

caseating granuloma in a mediastinal lymph node by EBUS-TBNA might have been caused by granulomatosis with polyangiitis (GPA); however, mediastinal or hilar lymph node involvement by GPA is reported to be very rare ($<2\%$ of cases) (8). In addition, the patient also showed lymphocytosis and an elevated CD4/CD8 ratio on a BAL analysis. Given these findings and the elevated levels of ACE and sIL-2R, we decided it was reasonable to diagnose him with sarcoidosis according to the diagnostic criteria for sarcoidosis in Japan (9). Consequently, the AAV of the patient was classified as renal-limited vasculitis, a subset of microscopic polyangiitis (MPA), according to the classification algorithm proposed by Watts et al. (10). In addition, given the positive findings for anti-SS-A antibodies and interstitial infiltration of lymphocytes (>1 focus/ 4 mm^2) observed on a labial salivary gland biopsy, he was diagnosed with SjS according to the revised Japanese criteria for SjS (11).

Consequently, he was diagnosed with co-occurrence of the three systemic diseases, AAV, sarcoidosis, and SjS, in addition to MGUS. In addition to the pauci-immune crescentic glomerulonephritis caused by AAV, the renal biopsy findings also revealed severe interstitial nephritis. Because AAV, sarcoidosis, and SjS are all significant causes of interstitial nephritis, it was difficult to determine the cause of interstitial nephritis as AAV or SjS.

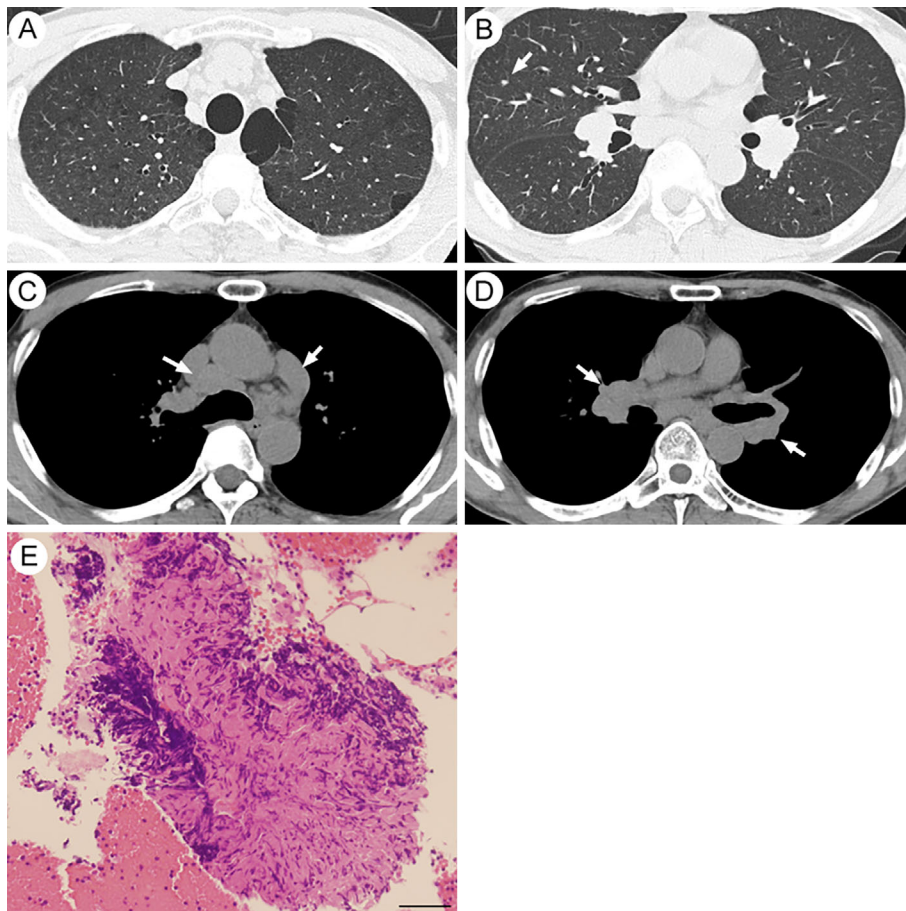


Figure 2. Computed tomography and pathological findings of a lymph node by EBUS-TBNA. (A)-(D) Chest computed tomography (CT) findings showing slight ground-glass opacity in the centrilobular regions (A), a small nodule (B, arrow), and hilar and mediastinal lymphadenopathies (C-D, arrows). (E) Representative light microscopic image of a lymph node (#4R: right lower paratracheal lymph node) by EBUS-TBNA with Hematoxylin and Eosin staining, showing noncaseating granuloma with the accumulation of inflammatory cells. Scale bar: 50 μ m. EBUS-TBNA: endobronchial ultrasound-guided transbronchial needle aspiration

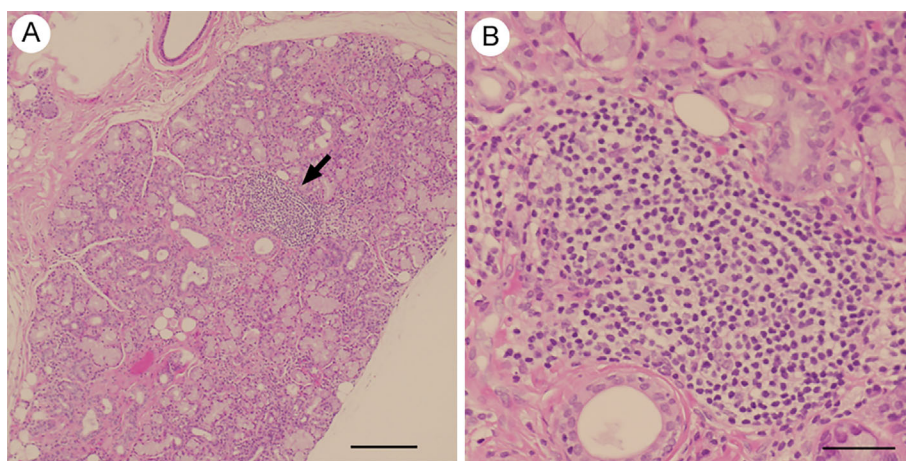


Figure 3. Pathological findings of a salivary gland biopsy. (A) and (B) Representative light microscopic images of a salivary gland biopsy with Hematoxylin and Eosin staining, showing lymphocytic infiltration (arrows) around the salivary gland (>1 focus/4 mm²). Scale bars: (A) 200 μ m and (B) 50 μ m.

To treat the AAV-induced crescentic glomerulonephritis and tubulointerstitial nephritis, the patient was administered prednisolone [60 mg/day (1 mg/kg/day)] and monthly intravenous cyclophosphamide pulse therapy a total of 6 times

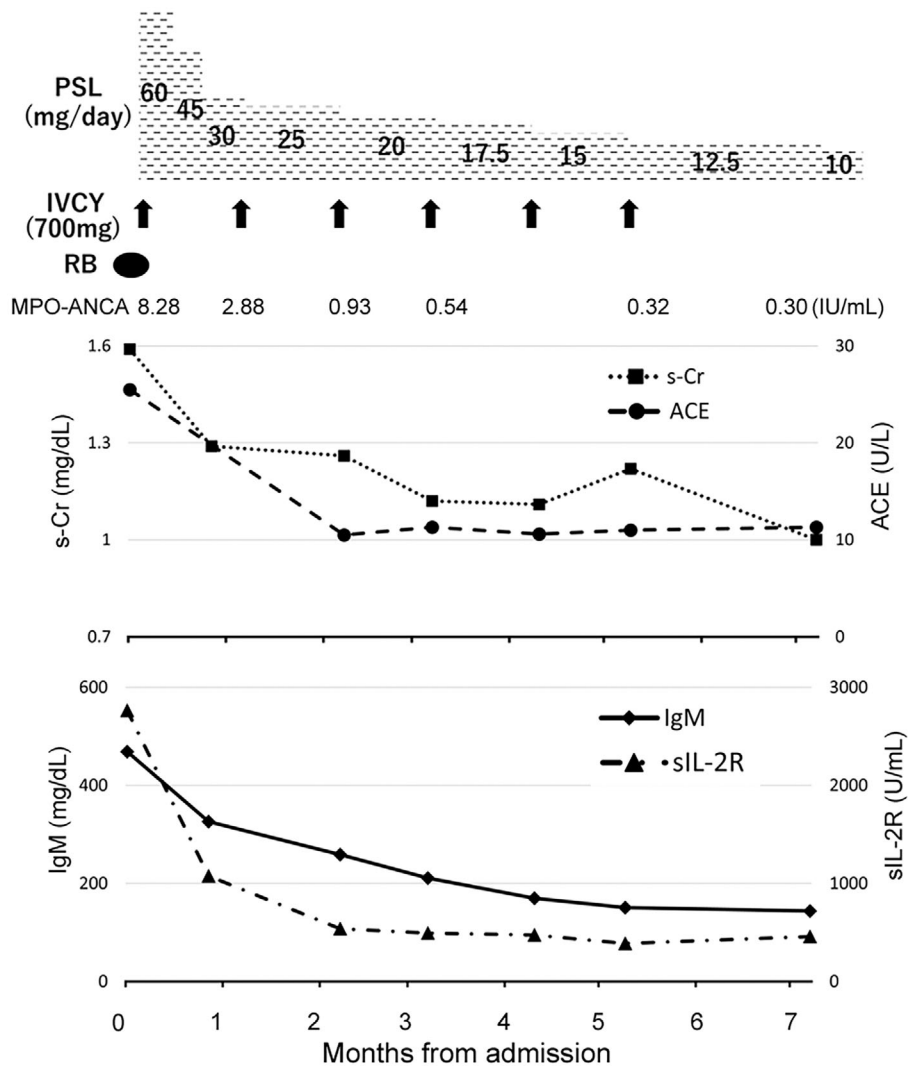


Figure 4. Patient's clinical course. PSL: prednisolone, IVCY: intravenous cyclophosphamide, RB: renal biopsy, MPO-ANCA: myeloperoxidase anti-neutrophil cytoplasmic antibodies, s-Cr: serum creatinine, ACE: angiotensin-converting enzyme, sIL-2R: soluble interleukin-2 receptor

(Fig. 4). These treatments for AAV were expected to be also effective for sarcoidosis, SjS, and MGUS.

Consequently, his s-Cr levels gradually decreased to 1.0 mg/dL after 7 months, and microscopic hematuria and MPO-ANCA became undetectable after 2 months. In addition, the serum levels of ACE, sIL-2R, and IgM gradually decreased to the normal ranges, and hilar and mediastinal lymphadenopathy, as well as ground-glass opacity in the centrilobular regions detected by chest CT, were improved. Prednisolone was tapered to less than 10 mg/day within 8 months.

Discussion

AAV, sarcoidosis, and SjS are all systemic diseases targeting multiple organs. Because each systemic disease may show similar or common clinical features, a careful differential diagnosis of these diseases is often required. However, the co-occurrence of these systemic diseases in the same patient has been previously reported. A nationwide case-

control study found that sarcoidosis patients showed a higher risk of SjS than the age- and sex-matched control group (adjusted odds ratio 11.6) (12). In contrast, the prevalence of sarcoidosis with SjS ranges from 1-2%, comparing the estimated prevalence of sarcoidosis with 1-40 cases/100,000 population (13). Regarding concurrent AAV and SjS, the overall prevalence of ANCA positivity in SjS was reported to be around 9% (7), with some cases presenting with AAV, and no cases of AAV prior to SjS being identified (7). These findings suggest that AAV is a rare but possible complication of SjS.

However, to our knowledge, only one case with the co-occurrence of AAV and sarcoidosis has been previously reported (14). Since AAV and sarcoidosis are sometimes associated with cancers and are considered to be associated with autoimmune mechanisms against intrinsic or extrinsic antigens (14-16), it was concluded that there may have been some overlapping immune response for tumor antigens and/or antigens provoked by tumors. We therefore herein present the first case of the co-occurrence of these three systemic

diseases, which emphasizes the importance of considering the possible co-occurrence of these diseases, as well as showing the importance of differentiating these diseases.

Since there is no reported systematic analysis of cases with the co-occurrence of systemic diseases, characteristics of pathology, points for differentiation, and ideal treatments in cases with the co-occurrence of systemic diseases remain unclear. Nevertheless, in cases with the co-occurrence of sarcoidosis and connective tissue diseases, it is reported that lymphoid follicular hyperplasia and follicular bronchiolitis, which are not usually seen in patients with sarcoidosis alone, are often observed, as well as granuloma (17). These findings therefore suggest the presence of connective tissue diseases in addition to sarcoidosis.

While a detailed analysis of findings may help differentiate systemic diseases, the limitations of the differential diagnosis should also be recognized. For example, in the present case, it was hard to conclude the cause of interstitial nephritis, since AAV, sarcoidosis, and SjS may all cause interstitial nephritis. Referencing the points for treating cases with the co-occurrence of systemic diseases, immunosuppressive treatments, including steroids, might be effective in cases of multiple co-occurring diseases. For example, in the present case, treatment with prednisolone and cyclophosphamide (targeting AAV) were also effective against the other systemic diseases of SjS and sarcoidosis as well as MGUS.

Although there are no established treatment guidelines for the co-occurrence of systemic diseases, treatment should target the systemic disease requiring the strongest immunosuppressive therapy, as this treatment may cover the other systemic diseases as well. Another important point to consider in cases of the co-occurrence of systemic diseases is the need to monitor multiple markers for multiple diseases. For example, in the present case, we monitored levels of MPO-ANCA, serum IgM, ACE, and sIL-2R as well as urinary analyses in addition to s-Cr. These findings suggest that a careful differential diagnosis, treatment decision, and careful follow-up are required in cases with the co-occurrence of multiple systemic diseases.

In addition, the present case also showed MGUS, which is reported to be associated with autoimmune diseases (18). For example, it has been reported that 11% of samples from patients with monoclonal gammopathy showed positive ANCA findings (19), while 6% of SjS patients were reported to have concomitant MGUS (20). Co-occurrence of sarcoidosis and MGUS has also been reported (21). Although there are no epidemiologic data to support the increased risk of MGUS in these systemic diseases, it has been suggested that dysregulation of the immune system may cause autonomous plasma cell clones and MGUS, while the dysregulation of cytokines, such as IL-1, IL-6, and TNF- α , may cause continuous stimulation of B cells (18). Regarding renal complications, patients with MGUS may develop kidney diseases characterized by amyloidosis, cryoglobulinemic glomerulonephritis, monoclonal immunoglobulin deposition disease, or light chain proximal tubulopa-

thy (22). Although the present patient did not have any kidney diseases associated with MGUS, it is important to consider MGUS-associated kidney disease as a differential diagnosis in patients with kidney disorders with MGUS.

In conclusion, we experienced a rare case of concurrent AAV, SjS, sarcoidosis, and MGUS that was successfully treated with steroids and cyclophosphamide. While a careful differential diagnosis of these systemic diseases is generally required, the possibility of their co-occurrence should also be considered.

The authors state that they have no Conflict of Interest (COI).

References

- Vazquez V, Fayad A, Gonzalez G, Smuclir Quevedo A, Robaina Sindin J; Consejo de Glomerulopatias de la Asociacion Nefrologica de Buenos Aires SAdN. [Clinical practice guideline for ANCA-associated vasculitis with renal involvement]. *Medicina (B Aires)* **75**: 1-38, 2015.
- Brito-Zeron P, Baldini C, Bootsma H, et al. Sjogren syndrome. *Nat Rev Dis Primers* **2**: 16047, 2016.
- Oqueka T, Galow S, Simon M, et al. [Sarcoidosis as prime example of a granulomatous disease]. *Z Rheumatol* **81**: 535-548, 2022.
- Tokuyasu H, Harada T, Touge H, et al. Primary Sjögren's syndrome complicated by sarcoidosis. *Intern Med* **47**: 2049-2052, 2008.
- Miyata M, Takase Y, Kobayashi H, et al. Primary Sjögren's syndrome complicated by sarcoidosis. *Intern Med* **37**: 174-178, 1998.
- Fuchs PS, Lotscher J, Berkemeier CM, et al. Co-occurrence of ANCA-associated vasculitis and Sjögren's syndrome in a patient with acromegaly: a case report and retrospective single-center review of acromegaly patients. *Front Immunol* **11**: 613130, 2020.
- Guellec D, Cornec-Le Gall E, Groh M, et al. ANCA-associated vasculitis in patients with primary Sjögren's syndrome: detailed analysis of 7 new cases and systematic literature review. *Autoimmun Rev* **14**: 742-750, 2015.
- George TM, Cash JM, Farver C, et al. Mediastinal mass and hilar adenopathy: rare thoracic manifestations of Wegener's granulomatosis. *Arthritis Rheum* **40**: 1992-1997, 1997.
- Shijubo N, Yamaguchi T. Diagnosis criteria and classification of disease severity for sarcoidosis in Japan. *Nihon Sarcoidosis/Nikugesyu Shikkan Gakkai Zasshi (Jpn J Sarcoidosis Other Granulomatous Disord)* **35**: 3-8, 2015 (in Japanese).
- Watts R, Lane S, Hanslik T, et al. Development and validation of a consensus methodology for the classification of the ANCA-associated vasculitides and polyarteritis nodosa for epidemiological studies. *Ann Rheum Dis* **66**: 222-227, 2007.
- Fujibayashi T, Sugai S, Miyasaka N, Hayashi Y, Tsubota K. Revised Japanese criteria for Sjögren's syndrome (1999): availability and validity. *Mod Rheumatol* **14**: 425-434, 2004.
- Wu CH, Chung PI, Wu CY, et al. Comorbid autoimmune diseases in patients with sarcoidosis: a nationwide case-control study in Taiwan. *J Dermatol* **44**: 423-430, 2017.
- Ramos-Casals M, Brito-Zeron P, Garcia-Carrasco M, Font J. Sarcoidosis or Sjogren syndrome? Clues to defining mimicry or coexistence in 59 cases. *Medicine (Baltimore)* **83**: 85-95, 2004.
- Tsuchiya K, Karayama M, Sato T, et al. Simultaneous occurrence of sarcoidosis and anti-neutrophil cytoplasmic antibody-associated vasculitis in a patient with lung cancer. *Intern Med* **58**: 3299-3304, 2019.
- Tana C, Drent M, Nunes H, et al. Comorbidities of sarcoidosis. *Ann Med* **54**: 1014-1035, 2022.

16. Diez-Porres L, Rios-Blanco JJ, Robles-Marhuenda A, Gutierrez-Molina M, Gil-Aguado A, Vazquez-Rodriguez JJ. ANCA-associated vasculitis as paraneoplastic syndrome with colon cancer: a case report. *Lupus* **14**: 632-634, 2005.
17. Takemoto M. Differential diagnosis of sarcoidosis of the lung: from the viewpoint of pathology. *Nihon Sarcoidosis/Nikugesyu Shikkan Gakkai Zasshi (Jpn J Sarcoidosis Other Granulomatous Disord)* **36**: 45-51, 2016 (in Japanese).
18. Cho SY, Yang HS, Jeon YL, et al. A case series of autoimmune diseases accompanied by incidentally diagnosed monoclonal gammopathy: is there a link between the two diseases? *Int J Rheum Dis* **17**: 635-639, 2014.
19. Esnault VL, Jayne DR, Keogan MT, et al. Anti-neutrophil cytoplasm antibodies in patients with monoclonal gammopathies. *J Clin Lab Immunol* **32**: 153-159, 1990.
20. Brogini M, Cavallo A, Baratelli E, et al. [Monoclonal gammopathy of uncertain significance in rheumatic disease]. *Recenti Prog Med* **81**: 306-309, 1990.
21. Hassanein M, Karapetyan L, Khan A, Rayamajhi S. Sarcoidosis and monoclonal gammopathy of undetermined significance (MGUS): a true association or just a coincidence? *Case Rep Hematol* **2018**: 3790760, 2018.
22. Bridoux F, Leung N, Hutchison CA, et al. Diagnosis of monoclonal gammopathy of renal significance. *Kidney Int* **87**: 698-711, 2015.

The Internal Medicine is an Open Access journal distributed under the Creative Commons Attribution-NonCommercial-NoDerivatives 4.0 International License. To view the details of this license, please visit (<https://creativecommons.org/licenses/by-nc-nd/4.0/>).