



■ SHOULDER & ELBOW

Outcome of unlinked total elbow arthroplasty for rheumatoid arthritis in patients younger than 50 years old

**K. Nishida,
Y. Nasu,
K. Hashizume,
S. Okita,
R. Nakahara,
T. Saito,
T. Ozaki,
H. Inoue**

From Okayama
University, Okayama,
Japan

Aims

There are concerns regarding complications and longevity of total elbow arthroplasty (TEA) in young patients, and the few previous publications are mainly limited to reports on linked elbow devices. We investigated the clinical outcome of unlinked TEA for patients aged less than 50 years with rheumatoid arthritis (RA).

Methods

We retrospectively reviewed the records of 26 elbows of 21 patients with RA who were aged less than 50 years who underwent primary TEA with an unlinked elbow prosthesis. The mean patient age was 46 years (35 to 49), and the mean follow-up period was 13.6 years (6 to 27). Outcome measures included pain, range of motion, Mayo Elbow Performance Score (MEPS), radiological evaluation for radiolucent line and loosening, complications, and revision surgery with or without implant removal.

Results

The mean MEPS significantly improved from 47 (15 to 70) points preoperatively to 95 (70 to 100) points at final follow-up ($p < 0.001$). Complications were noted in six elbows (23%) in six patients, and of these, four with an ulnar neuropathy and one elbow with postoperative traumatic fracture required additional surgeries. There was no revision with implant removal, and there was no radiological evidence of loosening around the components. With any revision surgery as the endpoint, the survival rates up to 25 years were 78.1% (95% confidence interval 52.8 to 90.6) as determined by Kaplan-Meier analysis.

Conclusion

The clinical outcome of primary unlinked TEA for young patients with RA was satisfactory and comparable with that for elderly patients. A favourable survival rate without implant removal might support the use of unlinked devices for young patients with this disease entity, with a caution of a relatively high complication rate regarding ulnar neuropathy.

Level of Evidence: Therapeutic Level IV

Cite this article: *Bone Jt Open* 2023;4-1:19–26.

Keywords: Total elbow arthroplasty, Rheumatoid arthritis, Unlinked elbow, Less than fifty years old

Introduction

Total elbow arthroplasty (TEA) is a well-recognized treatment choice for the end-stage arthritic elbow providing pain-free functional improvements. Rheumatoid arthritis (RA) has been the commonest indication for TEA; however, its annual proportion reduced from 77% to 50% between 1980 and 2008,¹ probably due to recent advances in pharmacological treatment. Another

systematic search using data compiled from six registries during the period between 2000 and 2017 also found that TEA to treat inflammatory arthritis decreased,² while TEA for fracture and osteoarthritis (OA) increased. However, inflammatory arthritis remains the most common indication, followed by acute fracture and OA in recent years.

Recent systematic reviews showed satisfactory clinical outcomes of TEA at long-term

Correspondence should be sent to Keiichiro Nishida; email: knishida@md.okayama-u.ac.jp

doi: 10.1302/2633-1462.41.BJO-2022-0151.R1

Bone Jt Open 2023;4-1:19–26.

Table 1. Pre- and postoperative clinical assessment of elbows replaced by three unlinked implants used in the current study.

Variable	JACE (13 elbows)		SKC-I (9 elbows)		Kudo type-5 (4 elbows)	
	Preoperative	Postoperative	Preoperative	Postoperative	Preoperative	Postoperative
Pain, n (%)						
None	0	12 (92)	0	8 (89)	0	4 (100)
Mild	2 (15)	1 (8)	1 (11)	1 (11)	4 (100)	0
Moderate	5 (38)	0	4 (44)	0	0	0
Severe	6 (46)	0	4 (44)	0	0	0
Mean range of motion, ° (SD)						
Flexion	111 (28)	138 (16)	106 (12)	148 (6)	136 (18)	149 (3)
Extension	-38 (27)	-20 (17)	-44 (28)	-14 (15)	-18 (13)	-30 (8)
Pronation	61 (25)	82 (20)	37 (26)	77 (10)	66 (22)	85 (10)
Supination	47 (36)	87 (8)	33 (25)	81 (13)	85 (10)	90 (0)
Stability, n (%)						
Stable	5 (38)	11 (85)	4 (44)	7 (78)	0	4 (100)
Mildly or moderately unstable	8 (62)	2 (15)	4 (44)	2 (22)	2 (50)	0
Grossly unstable	0	0	1 (11)	0	2 (50)	0
Mean score for daily activities, points (range)						
	12 (0 to 25)	23 (10 to 25)	16 (0 to 25)	23 (10 to 25)	16 (15 to 20)	21 (15 to 25)
Mean MEPS, points (range)						
	43 (15 to 65)	94 (70 to 100)	44 (25 to 60)	96 (80 to 100)	68 (65 to 70)	96 (90 to 100)
Final outcome, n (%)						
Excellent (\geq 90 points)	0	11 (85)	0	7 (78)	0	4 (100)
Good (75 to 89 points)	0	1 (8)	0	2 (22)	0	0
Fair (60 to 74 points)	4 (31)	1 (8)	2 (22)	0	5 (100)	0
Poor (\leq 59 points)	9 (69)	0	7 (78)	0	0	0

MEPS, Mayo Elbow Performance Score; SKC-I, stemmed Kyocera type I.

follow-up after a minimum ten years' mean follow-up,³ and the weighted mean survival rate of TEA implants in RA patients was 72.6% after 12.9 years.⁴ However, the reported complication and revision rates after TEA in RA range from 5.2% to 30.9% and 11% to 13%, respectively. As younger age at the time of surgery is a known risk factor for complications after TEA,⁵ there are still concerns regarding complications and longevity of TEA in young patients.

There are a few reports describing the clinical outcomes of TEA in RA patients below a certain age, but they also include cases of juvenile idiopathic arthritis, post-traumatic arthritis, or haemophilic arthritis. In addition, these studies are limited to reports on linked elbow devices. Unlinked devices require sufficient bone stock and soft-tissue stabilization for implantation, and have greater potential for instability or dislocation when compared with linked TEA; however, they are theoretically at less risk of loosening and mechanical failure. These implants include Capiteltocondylar,⁶ Souter–Strathclyde,⁷ and Kudo elbows.^{8,9} We have previously reported favourable mid- to long-term clinical results of alumina ceramic unlinked TEA for patients with RA.^{10,11} To date, few papers have examined the results of unlinked TEA in young RA patients. The current study aimed to investigate the clinical and radiological outcomes of unlinked TEA in Japanese patients with RA who are less than 50 years, with a minimum follow-up of six years.

Methods

With approval from the Ethics Committee of our institute, we retrospectively reviewed the medical records of all patients who underwent TEA in our institute. Among the records of 353 elbows treated by primary TEA for RA between 1986 and 2019, 298 elbows were replaced by unlinked prostheses. The unlinked implants used in our institution for the reconstruction of RA elbows were the stemmed Kyocera type I (SKC-I; Kyocera, Japan),¹⁰ the J-alumina ceramic elbow (JACE; Kyocera),¹¹ and Kudo (type-5; Zimmer Biomet, USA).^{8,9} There were 105 elbows by SKC-I, 177 elbows by JACE, and 16 elbows by Kudo type-5. One patient with juvenile idiopathic arthritis (JIA) was excluded from the study, leaving 26 elbows in 21 RA patients aged less than 50 years who were included in the current study. They were all women, with a mean age of 46 years (35 to 49) at the time of the surgery.

All RA patients met the American Rheumatism Association 1987 revised criteria for RA.¹² Biological disease-modifying antirheumatic drugs were used in five patients with seven elbows. The preoperative radiological condition of all the elbows was Larsen grade IV,¹³ including five cases of stiff or ankylosed elbows with a range of motion of 30° or less. Two patients had a history of open synovectomy of the affected elbows, but the other 24 elbows had no history of previous surgical intervention.

Clinical follow-up was carried out by three authors (KN, KH, YN) at three, six, and 12 months after surgery,

Table II. Complications noted in six elbows of 26 elbows and their management.

Patient	Age at TEA, yrs	Sex	Operated side	Implant	Preoperative arc, ^o	Preoperative range of motion, ^o			Complication	Period before revision surgery, yrs	Management	Outcome
						Flexion	Extension	Arc				
1	44	F	L	SKC-I	85 extension deficit to 90 flexion	90	-85	5	Ulnar neuropathy	-	-	Persistent sensory disturbance
2	49	F	R	JACE	60 extension deficit to 90 flexion	90	-60	30	Ulnar neuropathy, joint contracture	4.3	Ulnar nerve release + anterior transposition, soft-tissue release	Recovered
3	41	F	R	JACE	50 extension deficit to 50 flexion	50	-50	0	Ulnar neuropathy, joint contracture	1.8	Ulnar nerve release + anterior transposition, soft-tissue release	Recovered
4	49	F	L	JACE	80 extension deficit to 110 flexion	110	-80	30	Ulnar neuropathy	0.9	Ulnar nerve release + anterior transposition	Persistent sensory disturbance
5	39	F	R	JACE	60 extension deficit to 60 flexion	145	-5	140	Postoperative humeral fracture	13.3	Open reduction and internal fixation	Recovered
6	45	F	L	Kudo type-5	25 extension deficit to 140 flexion	140	-25	115	Ulnar neuropathy	0.4	Ulnar nerve release + anterior transposition	Persistent sensory disturbance

JIA, juvenile idiopathic arthritis; RA, rheumatoid arthritis; TEA, total elbow arthroplasty.

and annually thereafter. The mean follow-up period was 13.5 years (6 to 28). The condition of each elbow before and after surgery was assessed using the Mayo Elbow Performance Score (MEPS, 0 to 100 points),¹⁴ which assesses pain (0 to 45 points), range of motion (ROM; 0 to 20 points), stability (0 to 10 points) and function (0 to 25 points). The ROM was measured using a goniometer and expressed as follows; 0° being normal extension, and > 0° measuring the flexion arc and < 0° reflecting hyperextension (flexion contracture). The elbow joint stability was graded as stable (10 points), mildly unstable (5 points), or unstable (0 points). Based on this system, the overall evaluation was defined as excellent (> 89 points), good (75 to 89), fair (60 to 74), or poor (< 60).

Radiological evaluation. Postoperative radiographs taken at the final follow-up were digitized at 12-bit pixel depth (4,096 shades of grey) with a pixel size of 148 µm and transferred to a workstation. The bone-cement interface was evaluated by two authors (KN, YN) by reviewing the images independently for the presence and characteristics of radiolucent lines in periprosthetic areas, and in case of differences of opinion, agreement was reached by consensus. Radiological loosening was defined as a progressive radiolucent line of > 1 mm that was completely circumferential around a component.

Implant selection. We indicated the use of unlinked prostheses solely for elbows with inflammatory arthritis with painful flexion contracture of less than 100° of flexion/extension arc or painful instability causing unacceptable limitation of daily function. Joint destruction should be advanced beyond Larsen's grade III on radiographs.

SKC-I (Supplementary Figure a, Part A) was used between 1987 and 1999, then was succeeded by the

JACE (Supplementary Figure a, Part B) after changes in the implant design and material of the humeral and ulnar stem. Mid- to long-term clinical results of the above two alumina ceramic implants with cement fixation have been reported separately.^{10,11} Of these, nine elbows of seven patients and 13 elbows of 12 patients, who underwent TEA using SKC-I and JACE, respectively, were included in the current study. One patient with SKC-I was lost to follow-up at 13 years after surgery due to moving to another prefecture. Four patients (six elbows) with SKC-I died during follow-up unrelated to the surgery, and the records at the final follow-up visit were used for analysis. The data of the remaining 14 elbows were updated from 2019 to 2022 by direct evaluation at our outpatient clinic. In patients with a severe bony or fibrous contracture of the elbow, the Kudo elbow was indicated when ossification of the medial collateral ligament (MCL) was anticipated. In this study, four elbows of two patients were replaced with a Kudo type-5 prosthesis (Supplementary Figure a, Part C). For the elbows with Larsen's grade V with gross instability and severe bone loss, TEA with a linked prosthesis was indicated. During the same study period, three elbows of three patients less than 50 years of age were replaced with a PROSNAP elbow prosthesis (Kyocera),¹⁵ but these were not included in this study.

Surgical technique. The patient was placed in the lateral position, and a posterior longitudinal approach was used. The ulnar nerve was identified, and meticulous dissection was carried out proximally and distally. The routine anterior transposition of the ulnar nerve was carried out when Kudo type-5 TEA was performed, but not for SKC-I or JACE prostheses. The U-shaped posterior aponeurosis of the triceps tendon was reflected

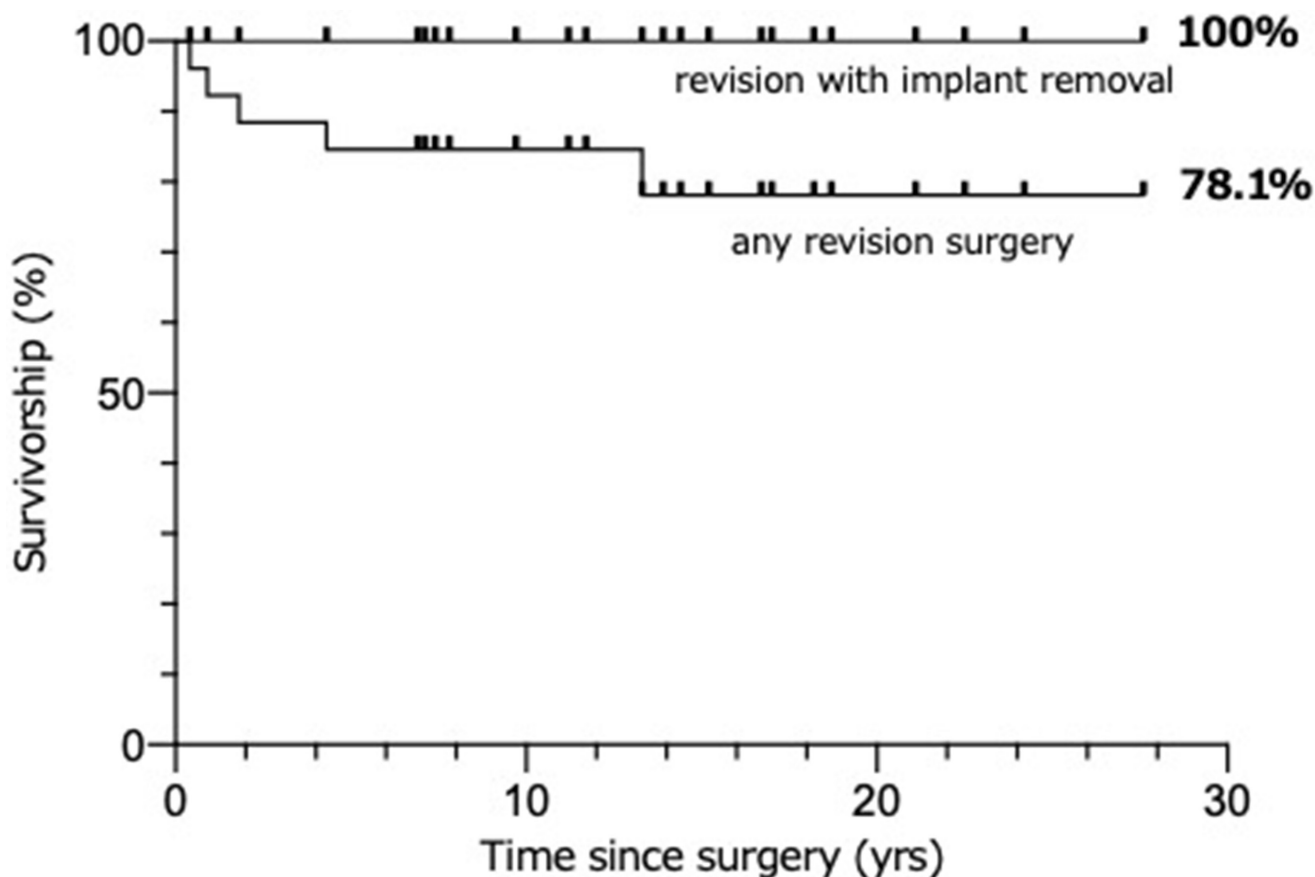


Fig. 1

Kaplan-Meier survivorship curves for unlinked total elbow arthroplasty in rheumatoid arthritis patients aged less than 50 years, with any revision surgery and revision with implant removal as the endpoints.

distally. The distal part of the thick tendinous portion of the long head was separated into two layers, and the musculotendinous insertion was released from the tip of the olecranon in a reverse T manner, as previously described.¹¹ For SKC-I and JACE, anterior fibres of the MCL were preserved,^{10,11} and for the Kudo type-5 elbow, the MCL was transected as a routine procedure.^{9,16,17} After cutting the bone and removal of the damaged trochlea and ulnar surface using a guide instrument, both humeral and ulnar components were cement fixed for SKC-I and JACE. For the Kudo type-5 implant, bone cement was used only between the implant and the distal surface of the humerus, and for the metal-backed ulnar component. To improve forearm rotation, Darrach's¹⁸ procedure was combined with TEA in one patient, and a Sauvé-Kapandji¹⁹ procedure in two (two wrists).

Statistical analysis. Statistical analysis was performed by paired *t*-test and Wilcoxon's signed-rank test to compare pre- and postoperative data. Fisher's exact test was used for between-group comparisons. Survival involving revision surgery with or without implant removal and reintroduction of new components, and the time when revision surgery was undertaken, was performed

using the Kaplan-Meier method. All analyses were conducted using Prism software v. 5.0 a (GraphPad, USA) with $p < 0.05$ regarded as significant.

Results

Clinical assessment. Mean pain scores were significantly improved from 13 (0 to 30) points preoperatively to 44 (30 to 45) postoperatively ($p < 0.001$, paired *t*-test). All three implants provided reliable pain relief. The mean range of extension/flexion was -37° (standard deviation (SD) 26°)/ 113° (SD 24°) preoperatively and -20° (SD 16°)/ 143° (SD 13°) at the final follow-up. The mean range of pronation/supination was 54° (SD 27°)/ 48° (SD 34°) preoperatively and 82° (SD 15°)/ 85° (SD 10°) at final follow-up. The mean pre- and postoperative extension/flexion arcs were 74° (0° to 150°) and 124° (55° to 153°) in flexion/extension, and 102° (10° to 180°) and 167° (110° to 180°) in pronation/supination, respectively. The mean ROM scores were 13.9 (5 to 20) points preoperatively which significantly improved to 19.2 (15 to 20) points postoperatively ($p < 0.001$, paired *t*-test). The mean stability scores were significantly improved from 6.2 (0 to 10) points preoperatively to 9.2

Table III. Summary of previous literature and current study, which evaluated the clinical outcomes of total elbow arthroplasty in young patients.

Variable	Celli et al, ²³ 2009	Park et al, ²⁴ 2015	Schoch et al, ²⁵ 2017	Siala et al, ²⁶ 2019	Current study
Number of elbows (patients)	55 (49)	23 (23)	11 (11)	19 (17)	26 (21)
Diagnosis (no. of elbows)	RA (15), JIA (21), PT (19)	RA (9), PT (9), HA (4), Other (1)	RA (5), JIA (2), PT (3), HA (1)	IA (15), PT (4)	RA (26)
Mean age at surgery, yrs (range)	32 (24 to 40)	33 (20 to 40)	37 (22 to 47)	46 (29 to 54)	46 (35 to 49)
Mean follow-up period, yrs (range)	7.6 (2 to 20)	10.8 (7.1 to 18.9)	3.2 (1.8 to 5.5)	10 (2 to 16)	13.6 (6.2 to 27.6)
Implant (no. of elbows)	Coonrad-Morrey (55)	Coonrad-Morrey (12) Pritchard-Walker Mark II (11)	Coonrad-Morrey (3) Discovery (8) Nexel (1)	Coonrad-Morrey (19)	JACE (13) SKC-I (9), Kudo type-5 (4)
Mean flexion-extension arc, ° (range)					
Preoperative	72 (0 to 145)	30 (0 to 80)	79 (N/A)	90 (30 to 140)	76 (0 to 150)
Postoperative	115 (10 to 145)	106 (65 to 135)	106 (N/A)	120 (50 to 150)	124 (55 to 153)
Improvement in ROM, °	43	76	27	30	48
Mean MEPS, points (range)					
Preoperative	37 (N/A)	31 (10 to 50)	N/A	36 (15 to 55)	47 (15 to 70)
Postoperative	91 (N/A)	81 (55 to 100)	82 (65 to 100)	85 (55 to 100)	95 (70 to 100)
Improvement in MEPS (points)	54	50	N/A	49	48
Final outcome (E/G/F/P)*	36/15/3/1	9/8/5/1	2/1/2/0†	8/5/1/3	22/3/1/0
Radiolucent line, n (%)	6 (11)	11 (48)	7 (64)	9 (47)	0
Loosening, n (%)	5 (9)	3 (13)	6 (55)	5 (26)	0
Revision surgery, n (%)	12 (22)	5 (22)	9 (82)	8 (42)	5 (19)

*The results of Mayo Elbow Performance Score were categorized as excellent (E, ≥ 90 points), good (G, 75 to 89 points), fair (F, 60 to 74 points), or poor (P, < 60 points).

†Six elbows with mechanical failure were excluded.

HA, haemophilic arthritis; IA, inflammatory arthritis; JIA, juvenile idiopathic arthritis; MEPS, Mayo Elbow Performance Score; N/A, not available; PT, post-traumatic arthritis; RA, rheumatoid arthritis; ROM, range of motion; SKC-I, stemmed Kyocera type-I.

(5 to 10) postoperatively ($p < 0.001$, paired t -test). The mean function scores were also significantly improved from 13.9 (0 to 25) points preoperatively to 22.7 (10 to 25) postoperatively ($p < 0.001$, paired t -test). The mean Mayo Elbow Performance Score (MEPS) significantly improved from 47 (15 to 70) points preoperatively to 95 (70 to 100) points at final follow-up ($p < 0.001$, paired t -test). Preoperatively, ten elbows were rated as fair, and 16 as poor, while postoperatively the ratings were excellent in 22, good in three, and fair in one. The pre- and postoperative clinical data of all three implants are provided in Table I.

Complications and implant survival. Complications were noted in six elbows (23%) in six patients (Table II). One patient complained of persistent postoperative paresthesia in the distribution of the ulnar nerve after TEA with SKC-I, but she refused revision surgery (Table II). Additional surgeries were required for five elbows (19%). Three patients after JACE TEA and one patient after Kudo type-5 TEA showed ulnar neuropathy without motor dysfunction and underwent ulnar nerve release and anterior transposition at an average of 1.9 years postoperatively. Of these, two patients underwent subsequent soft-tissue contracture release to improve the ROM. The other two patients had recurrent symptoms necessitating a further neurolysis. When a stiff or contracted elbow is defined as any loss of movement that

is greater than 30° in extension and less than 120° in flexion, four of five elbows with ulnar neuropathy and five of 21 elbows without ulnar neuropathy were stiff elbows. Stiff or contracted elbows tended to have significantly more postoperative ulnar neuropathy (odds ratio (OR) 12.8 (95% confidence interval (CI) 1.15 to 142.58); $p = 0.035$, Fisher's exact test).

One patient required open reduction and internal fixation with iliac bone grafting for a medial humeral condyle fracture due to a fall 13 years after TEA. There was no necessity for revision with implant removal, and there was no radiological evidence of loosening around the components. With any initial revision surgery or revision with implant removal as the endpoint, the survival rates up to 25 years were 78.1% (95% CI 52.8 to 90.6), and 100%, respectively, as determined by Kaplan-Meier analysis (Figure 1).

Discussion

Despite recent advances in the targeted treatment of RA, it is estimated that around 6% of RA patients still have difficulty in controlling disease activity.²⁰ Young patients with RA may experience persistent synovitis and progressive cartilage destruction at the elbow joint, resulting in pain and restricted ROM if disease activity is not well controlled by drug treatment. The question of whether TEA should be indicated in younger patients with severe

pain and functional disability due to end-stage arthritis presents a difficult dilemma. As TEA in a younger patient might require one or more revision surgeries within the patient's lifetime,²¹ surgeons generally tend to reserve TEA for low-demand patients over the age of 60 years.²² In our institute, selection of the surgical option was discussed by shared decision-making; TEA as well as other alternative therapies such as resection or interposition arthroplasty were considered. For all patients involved in the current study, we considered TEA to be a more acceptable, consistent, and reliable option. All three unlinked implants provided reliable pain relief and contributed to achieving a functional ROM postoperatively, resulting in a favourable overall outcome as evaluated by MEPS. The difference in the indication, group sizes, follow-up period, and the retrospective nature of the current study makes comparison of the outcome of the three implants difficult.

There are few reported studies of the clinical outcomes of TEA in young patients. Previous reports of TEA in relatively young patients (under 55) used linked devices,²³⁻²⁶ and showed that radiolucent lines occurred in 11% to 64% and loosening in 9% to 55% of patients, requiring revision surgery in 22% to 82% of patients (Table III). However, these studies included relatively high-demand patients with post-traumatic arthritis in 23.5% to 39.1% of patients, possibly related to prosthesis loosening. There are very few studies reporting the results of unlinked TEA in young patients with inflammatory arthritis. Of these, a few reports of TEA performed for damaged elbows with JIA dealt with relatively young patients. Ibrahim et al²⁷ reported the results of 14 implantations of a Kudo type-5 prosthesis in nine patients with JIA aged 37.6 years on average (26 to 52). Although the MEPS was improved from 24.3 preoperatively to 86.4 at the last follow-up, a secondary procedure was needed in seven elbows (50%), including six implant exchanges (four for pain and two for instability), resulting in a ten-year survival rate of 70% (95% CI 40 to 89%).

The current study is the first to show that the mid- to long-term clinical outcome of primary unlinked TEA for young patients with RA is satisfactory and comparable to those for elderly patients. There were no cases of radiological loosening, and no revision surgery with implant removal was needed during the follow-up. Although the current study was conducted in younger patients, the favourable outcome is partly because RA patients are a less demanding group compared to the general population, with less stress on the elbow joint due to polyarticular involvement of the upper limb. Celli and Morrey²³ compared the clinical results of Coonrad-Morrey TEA (Zimmer Biomet) between an inflammatory arthritis group and a post-traumatic group in patients aged 40 years or less. They showed that the mean MEPS was superior in the inflammatory arthritis group, and the rate of

radiological loosening and reoperation was greater in the post-traumatic group. The low rate of implant loosening on radiographs may be attributed to the clinical characteristics of RA patients, but they are also a suitable population for patient selection.

The rates of complications after TEA have decreased due to improvements in prosthetic design and operative technique,^{28,29} but are still not as favourable as those following hip or knee arthroplasties.⁴ The results of a systematic review demonstrated that the overall complication rates were not significantly different between linked and unlinked TEAs.²⁹ Toulemonde et al⁵ suggested that younger age, post-traumatic conditions, and revision aetiologies were risk factors for occurrence of complications. In patients aged less than 50 years, Schoch et al²⁵ investigated the results of 11 elbows, including five with RA and two with JIA replaced by linked TEAs, and found a very high rate of complication (82%) with six mechanical failures and nine requiring reoperation. They emphasized that TEA in patients aged under 50 years should be approached with caution, and patients should be informed about the high risk of complications and mechanical failure. Siala et al²⁶ also suggested that TEA should be considered with caution in young patients following their results of 19 Coonrad-Morrey TEAs, with 58% experiencing complications and a 42% revision rate.

In contrast, in the current study, a 23% rate of complications was noted, which mostly related to ulnar nerve neuropathy after unlinked TEAs. Persistent ulnar neuropathy is a significant complication after TEA.^{4,29,30} One systematic review showed that the incidence of nerve injury is significantly ($p = 0.09$) lower in unlinked devices (4/474, 0.8%) than in linked devices (24/762, 3.2%).³ Our incidence of ulnar nerve neuropathy is much higher than ever reported, however it is unclear why ulnar neuropathy is more likely to occur after TEA in younger patients.

In a report of 14 elbows treated with unlinked Kudo type-5 (Biomet UK, UK) prostheses in nine patients with JIA, Ibrahim et al²⁷ noted four cases of ulnar neuritis, and one case required neurolysis at nine months combined with arthrolysis for significant stiffness of the elbow. This was partly because the joint line tends to shift distally after implantation of a Kudo prosthesis.⁸ Peden and Morrey³¹ reported the development of ulnar symptoms in six elbows in 13 patients after TEA with Coonrad-Morrey, and symptoms of two had not resolved at the final assessment. In the current study, four of the five patients with ulnar neuropathy required neurolysis 0.9 to 4.3 years after surgery. These patients had a flexion-extension arc of 30° or less, and three of them had flexion of less than 100°. These results suggest that surgeons should pay special attention to the treatment of the ulnar nerve during TEA for stiff or ankylosed elbows.

Potential disadvantages of ulnar nerve transposition are disturbance of blood supply to the nerve and

mechanical injury during nerve release.²⁹ Toulemonde et al⁵ reported that ulnar nerve involvement was the most frequent complication, with a 9% rate mainly seen in RA and associated with anterior transposition of the nerve in all cases. Dachs et al³² suggested that ulnar nerve transposition is not routinely indicated, and should be reserved for patients who have marked preoperative flexion contracture or in cases when intraoperative assessment by the surgeon deems it necessary. In our analysis, stiff or contracted elbows tended to have significantly more postoperative ulnar neuropathy. Considering the result of the current study and our reflection, these stiff elbows might require anterior transposition of the ulnar nerve at the primary TEA even with unlinked devices.

In this study, two of five patients with ulnar neuropathy also showed postoperative joint contracture, and required arthrolysis as well as neurolysis. Mansat and Morrey³³ reported that four elbows among 14 ankylosed or stiff elbows replaced by Coonrad-Morrey TEA did not achieve adequate motion within the first month after the surgery and needed a manipulation, but the mean arc of motion of these elbows had again decreased. Generally, a stiff or ankylosed elbow often requires extensive release of the circumferential capsule and ligaments.²⁸ The predisposition to ulnar neuropathy in the stiff elbow may include excessive fibrosis around the released nerve during postoperative tissue repair.

There are some limitations to our study. First, this is a retrospective study in our institute. However, all patients were able to be followed up for more than five years postoperatively, resulting in a relatively longer average follow-up period. Second, the number of patients is small because the target group is limited to RA patients with an age at surgery of less than 50 years, in addition to TEA being performed in much smaller numbers than total hip or knee arthroplasty. Third, three different implants were used without randomization. There was bias in the selection of unlinked devices due to historical reason for the choice of SKC-I and JACE, and due to soft-tissue and structural condition of the elbows for Kudo TEA. Lastly, all surgeries using SKC-I and JACE were performed at the institution of a designer by HI and his successor (KN), who were familiar with the procedure for alumina ceramic devices, which may lack generalizability. The surgical approach was not changed between the three implants, but surgical procedures are not uniform between Kudo and alumina ceramic TEA. Routine anterior transposition of the ulnar nerve and MCL transection were performed in Kudo TEA, but not in SKC-I and JACE TEA.

In conclusion, mid- to long-term clinical results of unlinked TEA for patients with RA younger than 50 years old were satisfactory and did not require implant removal, results which were comparable with those of elderly patients. A diligent selection of appropriate patients is crucial for the use of unlinked devices. The relatively high

complication rate was mainly caused by ulnar neuropathy, and four of five elbows with this problem required reoperation. Thus, stiff or ankylosed RA elbows might routinely require anterior transposition of the ulnar nerve at the primary TEA even with unlinked devices.



Take home message

- The current study investigated the clinical outcome of 26 unlinked total elbow arthroplasty (TEA) for patients aged less than fifty years with rheumatoid arthritis.
- The mean Mayo Elbow Performance Score significantly improved and the survival rates up to 25 years were 78.1% with any revision surgery as the endpoint.
- Complications were noted in 23% of the elbows, mainly caused by ulnar neuropathy. The stiff or ankylosed rheumatoid arthritis elbows might routinely require anterior transposition of the ulnar nerve at the primary TEA even with unlinked devices.

Supplementary material



Pre- and postoperative anteroposterior and lateral radiographs of the elbows after total elbow arthroplasty.

References

1. Samdanis V, Manoharan G, Jordan RW, et al. Indications and outcome in total elbow arthroplasty: A systematic review. *Shoulder Elbow*. 2020;12(5):353–361.
2. Macken AA, Prkic A, Kodde IF, Lans J, Chen NC, Eygendaal D. Global trends in indications for total elbow arthroplasty: a systematic review of national registries. *EFORT Open Rev*. 2020;5(4):215–220.
3. Davey MS, Hurley ET, Gaafar M, Molony D, Mullett H, Pauzenberger L. Long-term outcomes of total elbow arthroplasty: a systematic review of studies at 10-year follow-up. *J Shoulder Elbow Surg*. 2021;30(6):1423–1430.
4. Welsink CL, Lamberts KTA, van Deurzen DFP, Eygendaal D, van den Bekerom MPJ. Total elbow arthroplasty: A systematic review. *JBJS Rev*. 2017;5(7):e4.
5. Toulemonde J, Ancelin D, Azoulay V, Bonneville N, Rongièrès M, Mansat P. Complications and revisions after semi-constrained total elbow arthroplasty: a mono-centre analysis of one hundred cases. *Int Orthop*. 2016;40(1):73–80.
6. Ewald FC, Simmons ED, Sullivan JA, et al. Capitellocondylar total elbow replacement in rheumatoid arthritis. Long-term results. *J Bone Joint Surg Am*. 1993;75-A(4):498–507.
7. Landor I, Vavrik P, Jahoda D, Guttler K, Sosna A. Total elbow replacement with the Souter-Strathclyde prosthesis in rheumatoid arthritis. Long-term follow-up. *J Bone Joint Surg Br*. 2006;88-B(11):1460–1463.
8. Tanaka N, Kudo H, Iwano K, Sakahashi H, Sato E, Ishii S. Kudo total elbow arthroplasty in patients with rheumatoid arthritis: a long-term follow-up study. *J Bone Joint Surg Am*. 2001;83-A(10):1506–1513.
9. Kudo H, Iwano K, Nishino J. Total elbow arthroplasty with use of a nonconstrained humeral component inserted without cement in patients who have rheumatoid arthritis. *J Bone Joint Surg Am*. 1999;81-A(9):1268–1280.
10. Nishida K, Hashizume K, Nasu Y, Kishimoto M, Ozaki T, Inoue H. A 5-22-year follow-up study of stemmed alumina ceramic total elbow arthroplasties with cement fixation for patients with rheumatoid arthritis. *J Orthop Sci*. 2014;19(1):55–63.
11. Nishida K, Hashizume K, Nasu Y, et al. Mid-term results of alumina ceramic unlinked total elbow arthroplasty with cement fixation for patients with rheumatoid arthritis. *Bone Joint J*. 2018;100-B(8):1066–1073.
12. Arnett FC, Edworthy SM, Bloch DA, et al. The American Rheumatism Association 1987 revised criteria for the classification of rheumatoid arthritis. *Arthritis Rheum*. 1988;31(3):315–324.
13. Larsen A. How to apply larsen score in evaluating radiographs of rheumatoid arthritis in long-term studies. *J Rheumatol*. 1975;22:1974–1975.
14. Morrey BF, Adams RA. Semiconstrained arthroplasty for the treatment of rheumatoid arthritis of the elbow. *J Bone Joint Surg Am*. 1992;74-A(4):479–490.
15. Nishida K, Hashizume K, Nakahara R, et al. Short-term results of the PROSNAP linked elbow prosthesis with a snap-in structure and modular flange for the reconstruction of severely damaged rheumatoid elbows. *J Shoulder Elbow Surg*. 2014;23(6):837–842.

16. **Tanaka N, Sakahashi H, Ishii S, Kudo H.** Comparison of two types of ulnar component in type-5 Kudo total elbow arthroplasty in patients with rheumatoid arthritis: a long-term follow-up. *J Bone Joint Surg Br.* 2006;88-B(3):341–344.
17. **Brinkman J-M, de Vos MJ, Eygendaal D.** Failure mechanisms in uncemented Kudo type 5 elbow prosthesis in patients with rheumatoid arthritis: 7 of 49 ulnar components revised because of loosening after 2-10 years. *Acta Orthop.* 2007;78(2):263–270.
18. **Darrach W.** Anterior dislocation of the head of the ulna. *Ann Surg.* 1912;56:802–803.
19. **Sauvé L, Kapandji M.** New technique for surgical treatment of isolated recurrent dislocation of the distal ulna. *J Chir (Paris).* 1936;47:589–594.
20. **Kearsley-Fleet L, Davies R, De Cock D, et al.** Biologic refractory disease in rheumatoid arthritis: results from the British Society for Rheumatology Biologics Register for Rheumatoid Arthritis. *Ann Rheum Dis.* 2018;77(10):1405–1412.
21. **Zhang D, Chen N.** Total Elbow Arthroplasty. *J Hand Surg Am.* 2019;44(6):487–495.
22. **McAuliffe JA.** Surgical alternatives for elbow arthritis in the young adult. *Hand Clin.* 2002;18(1):99–111.
23. **Celli A, Morrey BF.** Total elbow arthroplasty in patients forty years of age or less. *J Bone Joint Surg Am.* 2009;91-A(6):1414–1418.
24. **Park JG, Cho NS, Song JH, Lee DS, Rhee YG.** Clinical outcomes of semiconstrained total elbow arthroplasty in patients who were forty years of age or younger. *J Bone Joint Surg Am.* 2015;97-A(21):1781–1791.
25. **Schoch B, Wong J, Abboud J, Lazarus M, Getz C, Ramsey M.** Results of total elbow arthroplasty in patients less than 50 years old. *J Hand Surg Am.* 2017;42(10):797–802.
26. **Siala M, Laumonerie P, Hedjoudje A, Delclaux S, Bonneville N, Mansat P.** Outcomes of semiconstrained total elbow arthroplasty performed for arthritis in patients under 55 years old. *J Shoulder Elbow Surg.* 2020;29(4):859–866.
27. **Ibrahim EF, Rashid A, Thomas M.** Linked semiconstrained and unlinked total elbow replacement in juvenile idiopathic arthritis: a case comparison series with mean 11.7-year follow-up. *J Shoulder Elbow Surg.* 2017;26(2):305–313.
28. **Connor PM, Morrey BF.** Total elbow arthroplasty in patients who have juvenile rheumatoid arthritis. *J Bone Joint Surg Am.* 1998;80-A(5):678–688.
29. **Voloshin I, Schippert DW, Kakar S, Kaye EK, Morrey BF.** Complications of total elbow replacement: a systematic review. *J Shoulder Elbow Surg.* 2011;20(1):158–168.
30. **van der Lugt JCT, Rozing PM.** Systematic review of primary total elbow prostheses used for the rheumatoid elbow. *Clin Rheumatol.* 2004;23(4):291–298.
31. **Peden JP, Morrey BF.** Total elbow replacement for the management of the ankylosed or fused elbow. *J Bone Joint Surg Br.* 2008;90-B(9):1198–1204.
32. **Dachs RP, Vrettos BC, Chivers DA, Du Plessis J-P, Roche SJ.** Outcomes after ulnar nerve in situ release during total elbow arthroplasty. *J Hand Surg Am.* 2015;40(9):1832–1837.
33. **Mansat P, Morrey BF.** Semiconstrained total elbow arthroplasty for ankylosed and stiff elbows. *J Bone Joint Surg Am.* 2000;82(9):1260–1268.

Author information:

- K. Nishida, MD, PhD, Associate Professor
- T. Ozaki, MD, PhD, Professor
- H. Inoue, MD, PhD, Emeritus Professor
Department of Orthopaedic Surgery, Science of Functional Recovery and Reconstruction, Faculty of Medicine, Dentistry and Pharmaceutical Sciences, Okayama University, Okayama, Japan.
- Y. Nasu, MD, PhD, Assistant Professor
- R. Nakahara, MD, PhD, Assistant Professor
Department of Orthopaedic Surgery, Okayama University Hospital, Okayama, Japan.
- K. Hashizume, MD, PhD, Chief Physician, Department of Orthopaedic Surgery, Chugoku Central Hospital, Fukuyama, Japan.
- S. Okita, MD, PhD, Chief Physician, Department of Orthopaedic Surgery, Okayama Saiseikai General Hospital, Okayama, Japan.
- T. Saito, MD, PhD, Assistant Professor, Department of Intelligent Orthopaedic System, Okayama University Graduate School of Medicine, Dentistry and Pharmaceutical Sciences, Okayama University, Okayama, Japan.

Author contributions:

- K. Nishida: Data curation, Formal analysis, Investigation, Methodology, Project administration, Writing – original draft.
- Y. Nasu: Data curation, Investigation.
- K. Hashizume: Data curation, Investigation.
- S. Okita: Data curation, Formal analysis.
- R. Nakahara: Formal analysis, Investigation.
- T. Saito: Formal analysis, Investigation.
- T. Ozaki: Supervision, Writing – review & editing.
- H. Inoue: Conceptualization, Investigation, Writing – review & editing.

Funding statement:

- The authors received no financial or material support for the research, authorship, and/or publication of this article.

ICMJE COI statement:

- H. Inoue is one of the designers of and a clinical advisor for the SKC-I and JACE elbow prosthesis. T. Ozaki is Okayama University's Head of the Department of Medical Materials for Musculoskeletal Reconstruction, which is funded by Kyocera. K. Nishida is a vice-chairman of the Japanese Society for Hand Surgery, a board member of the Japanese Society for Joint Disease, and a board member of the Japanese Society for Clinical Rheumatology and Related Research.

Ethical review statement:

- The current study was approved by the Ethics Committee of our institute (No. Eki576).

Open access funding

- The open access funding for this work was provided by the donation account of Okayama University.

© 2023 Author(s) et al. This is an open-access article distributed under the terms of the Creative Commons Attribution Non-Commercial No Derivatives (CC BY-NC-ND 4.0) licence, which permits the copying and redistribution of the work only, and provided the original author and source are credited. See <https://creativecommons.org/licenses/by-nc-nd/4.0/>