






# Overcoming perioperative inflammation as a hurdle for successful preclinical orthotopic cardiac xenogeneic transplantations – particular in regard of the mandatory use of heart-lung machines

Martin Bender<sup>1</sup> | Matthias Längin<sup>1</sup>  | Bruno Reichart<sup>2</sup>  | Maren Mokolke<sup>2</sup> | Julia Radan<sup>2</sup> | Elisabeth Neumann<sup>2</sup> | Sebastian Michel<sup>3</sup> | Reinhard Ellgass<sup>3</sup> | Peter J. Cowan<sup>4,5</sup>  | Eckhard Wolf<sup>6</sup>  | Jan-Michael Abicht<sup>1</sup>  | Paolo Brenner<sup>3</sup>

<sup>1</sup>Department of Anaesthesiology, University Hospital, LMU Munich, Munich, Germany

<sup>2</sup>Transregional Collaborative Research Center 127, Walter Brendel Centre of Experimental Medicine, LMU Munich, Munich, Germany

<sup>3</sup>Department of Cardiac Surgery, University Hospital, LMU Munich, Munich, Germany

<sup>4</sup>Immunology Research Centre, St. Vincent's Hospital, Melbourne, Victoria, Australia

<sup>5</sup>Department of Medicine, University of Melbourne, Melbourne, Victoria, Australia

<sup>6</sup>Institute of Molecular Animal Breeding and Biotechnology, Gene Center, LMU Munich, Munich, Germany

## Correspondence

Bruno Reichart, Walter Brendel Centre of Experimental Medicine, LMU Munich, Marchioninstrasse 27, 81377 Munich, Germany.  
Email: [bruno.reichart@med.uni-muenchen.de](mailto:bruno.reichart@med.uni-muenchen.de)

Martin Bender, Matthias Längin, Jan-Michael Abicht, Paolo Brenner contributed equally to this work.

## Abstract

**Introduction:** After orthotopic cardiac xenotransplantation, the combination of both the inflammatory responses to the exposure of a recipient to the xenogeneic organ and the use of cardiopulmonary bypass has been assumed to cause detrimental side effects. These have been described not only to affect the transplanted organ (heart) itself, but also the recipient's lungs. In this article, we summarize how these possible detrimental processes can be minimized or even avoided.

**Methods:** Data from eight pig-to-baboon orthotopic cardiac xenotransplantation experiments were analyzed with a special focus on early (within the first week) postoperative organ dysfunction and systemic inflammatory responses. Non-ischemic heart preservation and the careful management of the heart-lung machine were deemed essential to guarantee not only the immediate function of the transplanted xenogeneic organ but also the prompt recovery of the recipient.

**Results:** After weaning from cardiopulmonary bypass, very low catecholamine amounts were needed to ensure an adequate pump function and cardiac output. Central venous oxygen saturation and serum lactate levels remained within normal ranges. All animals were successfully weaned from ventilation within the first postoperative hours. Serum parameters of the transplants and native kidneys and livers were initially slightly elevated or always normal, as were hemoglobin, LDH, and platelet measurements. Markers of systemic inflammation, C-reactive protein, and IL-6 were slightly elevated, but the reactions caused no lasting damage.

**Conclusion:** Consistent short-term and long-term results were achieved after orthotopic cardiac pig-to-baboon transplantation without detrimental inflammatory responses or signs of multiorgan failure. In comparison to allogeneic procedures,

This is an open access article under the terms of the [Creative Commons Attribution-NonCommercial-NoDerivs](https://creativecommons.org/licenses/by-nc-nd/4.0/) License, which permits use and distribution in any medium, provided the original work is properly cited, the use is non-commercial and no modifications or adaptations are made.

© 2022 The Authors. *Xenotransplantation* published by John Wiley & Sons Ltd.

non-ischemic heart preservation was important for successful immediate organ function, as was the management of the heart-lung machine. Thus, we believe that genetically modified porcine hearts are ready for use in the clinical setting.

#### KEYWORDS

heart-lung machine, orthotopic heart transplantation, perioperative inflammation, xenotransplantation

## 1 | INTRODUCTION

In the July 2021 issue of this journal, C.P. Thompson et al.<sup>1</sup> discussed the “potential detrimental role of inflammation in pig orthotopic heart xenotransplantation.” After dealing with common reactions to porcine tissues, the authors focused on severe pathological responses due to the cardiopulmonary bypass that is necessary to keep the baboon recipients alive during heart replacement, emphasizing the susceptibility of the lungs to injury in this setting. In the concluding section of the commentary, various treatment options were suggested, including anti-inflammatory therapy and genetic engineering of the donor pig.

We are of the opinion, however, that minimizing or even avoiding possible detrimental processes associated with the use of a heart-lung machine must be preferable. Consequently, the following article will focus on improved cardiosurgical techniques. It is written not only for experts in our field, but also those (including possible investors) who are not necessarily familiar with these surgical issues.

## 2 | PAST AND PRESENT OF HEART-LUNG MACHINE TECHNOLOGIES IN HUMANS

Experimental work on whole-body perfusion was conducted in the late 1930s by John and Mary Gibbon at the Massachusetts General Hospital, Boston. In their device, which was a huge apparatus twice the size of a refrigerator, a roller-pump replaced the heart and a grid/screen oxygenator the lungs. The latter part was placed within an oxygen chamber in which a thin layer of blood flowed down the large surface of a metal grid or screen.<sup>2</sup>

Interrupted by World War II, the Gibbons applied their technique in humans in 1954, unfortunately without success.<sup>3</sup>

A year later, John Kirklin, then at the Mayo Clinic in Rochester, USA, reported on the first successful cases using his modified apparatus, the Mayo-Gibbon heart-lung machine<sup>4</sup> (it should be mentioned in this context that Kirklin left the Mayo Clinic in 1967 to join the University of Alabama at Birmingham, the place where Thompson and colleagues<sup>1</sup> are now working).

It needed the genius of DeWall and Lillehei of the University of Minneapolis, just 80 kilometers away from Rochester, to simplify the oxygenator by introducing a disposable bubble technique in which oxygen was added to a patient's blood in the form of small bubbles.<sup>5,6</sup>

Today, the simple principles of a heart-lung machine are still more or less the same. There is one major difference: the blood is now oxygenated in a less damaging hollow-fiber membrane oxygenator, con-

sisting of many tiny polymer tubes separating the surrounding patient's blood.<sup>7</sup> The tubing is semipermeable for oxygen and carbon dioxide, but not for blood components. The two gases exchange in between the two compartments according to their partial pressure gradients: oxygen into the desaturated blood, carbon dioxide away into the gaseous part.

Since its very first application, the pathophysiologic effects of whole-body perfusions were realized and studied intensively.<sup>8–11</sup> Whenever a patient's blood enters the non-endothelialised surfaces of the tubings and the oxygenator, damaging reactions are immediately initiated on all cellular components:

- erythrocytes hemolyze due to abnormal shear stresses,
- platelets are activated and adhere to foreign plastic materials, especially within the oxygenator,
- monocytes, NK-cells, leukocytes, and their cytokines cause whole-body inflammations now called systemic inflammatory response syndrome (SIRS).

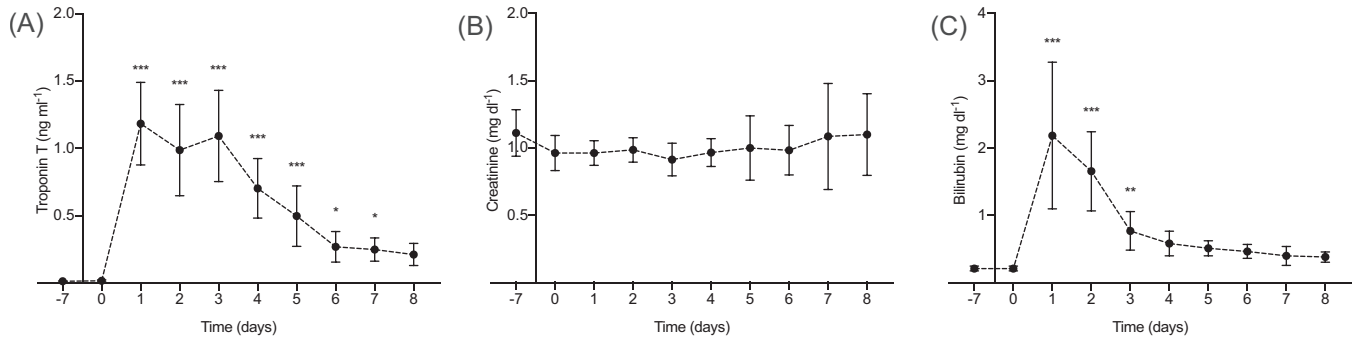
There are also damaging processes involving non-cellular blood components, such as complement and kallikrein activation, stimulation of the coagulation cascade, and hyperfibrinolysis. Concomitantly, the endothelial cells of the organs, especially of the lungs, are also affected.

Although this brief summary of possible detrimental reactions triggered by the use of a heart-lung machine might indeed sound frightening to a non-cardiac surgeon (as is the description of Thompson and colleagues<sup>1</sup>), it is a fact that most sick patients, some of them in end-stage heart disease, survive the operations and improve after a relatively short course of postoperative care.

One must however consider that there exist important differences if one compares clinical allogeneic and preclinic xenogeneic heart transplantation procedures: porcine donor organs originate from healthy animals with no previous brain damage, including the necrosis of the pituitary gland and the corresponding hormonal deficits.<sup>12</sup>

## 3 | PRECONDITIONS AND IMMEDIATE PRECLINICAL RESULTS AFTER SUCCESSFUL PORCINE ORTHOTOPIC CARDIAC XENOTRANSPLANTATION

So, why are the results after orthotopic porcine heart-xenotransplantations “mixed and largely poor” as Thompson and colleagues<sup>1</sup> write? Theoretically, one would expect rather the



**FIGURE 1** Heart [troponin (Figure 1A)], kidney [creatinine (Figure 1B)], and liver [bilirubin (Figure 1C)] function

opposite. The question may be tackled by remembering John Kirklin's old axiom: "Cardiosurgical interventions fail due to errors or/and lack of knowledge."<sup>10</sup>

Due to genetic differences between pigs and primates/humans, there are not only immunologic but also physiologic barriers to overcome: sure, stable genetic modifications are a prerequisite, but so are adjustments to address certain porcine pathophysiologic responses. Porcine hearts are obviously more vulnerable to prolonged ischemia times, even if cooling is added.

Consequently, our group adopted several new strategies for orthotopic cardiac xenotransplantation experiments to avoid perioperative cardiac xenograft dysfunction (PCXD),<sup>13</sup> as reported in greater detail elsewhere.<sup>14–16</sup> One very important step was the implementation of a non-ischemic heart preservation technique, which was introduced in co-operation with the group of S. Steen from Lund University.<sup>17</sup> In brief, the explanted porcine hearts were immediately perfused in a small heart-lung machine (now Xvivo, Gothenburg, Sweden) using low-pressure and flow-controlled 8°C oxygenated, hyperoncotic cardioplegic nutrition solution with hormones and erythrocytes of porcine or primate origin (Steen solution).

For heart replacement, the preclinical/clinical use of a heart-lung machine must cause as little damage as possible: We found that normal roller pumps were sufficient and used the Terumo Capiox FX05 oxygenator (Terumo Europe) made of microporous polypropylene hollow fibers coated with an anti-thrombotic polymer. The priming volume consisted of 190 mL 5% albumin; the flow rate for a 15 kg baboon was 1.5 L/min.

The donor organ perfusion was continued intermittently during surgery. Since the heart remained at 8°C, the recipient's body was only lowered to 34°C. After finishing the implantation, an orthotopic technique by Shumway and Lower<sup>18</sup> was applied and only a short rewarming to normal body temperatures was necessary.

Care was taken to keep the recipient's hemoglobin levels always above 10 g/dl. If below, primate blood was transfused. Urinary output was maintained above 1–2 ml/kg/h. The color remained clear without signs of hemolysis.

During weaning from cardiopulmonary bypass, and shortly thereafter, catecholamine support (Noradrenalin, Adrenalin) was low and decreasing till it was completely stopped.<sup>13,15</sup> The choice of cate-

cholamines was secondary if the need was reduced to a minimum. Echocardiographically, right and left ventricles performed normally,<sup>15</sup> and there were no fluids within the pericardial or pleural cavities. When compared to the baboon's own heart function, the porcine cardiac index after surgery was slightly inferior ( $3.88 \pm 0.65$  vs.  $4.97 \pm 0.75$  L/min/m<sup>2</sup>) but improved after closing the chest.<sup>16</sup>

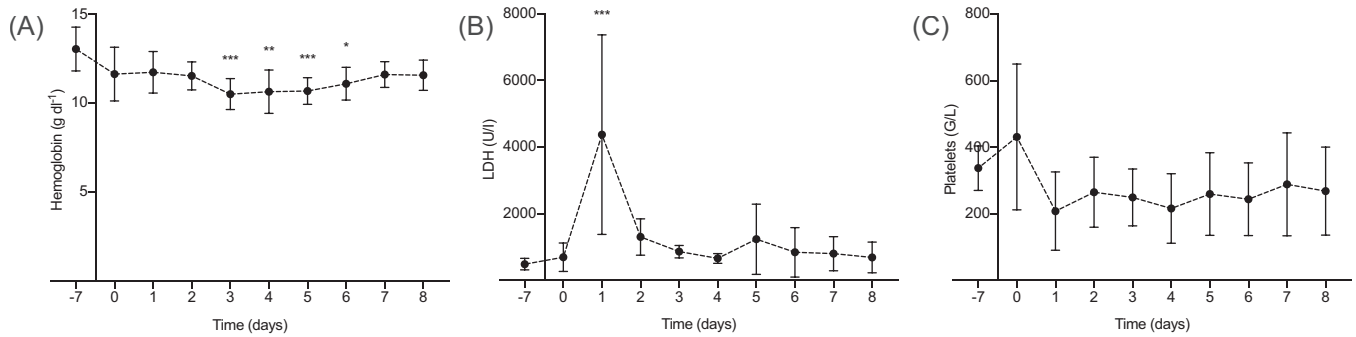
Central venous oxygen saturation decreases when tissue (oxygen-) contents are insufficient and are compensated with an increased arterial extraction. When compared to preoperative data, the baboon measurements were slightly inferior postoperatively but remained within normal ranges. Serum lactate levels always remained normal within the 12 postoperative hours.<sup>15</sup> According to these measurements, graft ischemia was avoided at all times.

Consequently, all animals were successfully weaned from ventilation and the time between closure of the skin and extubation measured on average 296 minutes. Shortly thereafter, the baboons were transferred to their cages, breathing normally on continuous pain medication. Three intensivists/anesthetists and three primatologists/veterinarians, all experts in their field, shared the responsibility of the postoperative care.

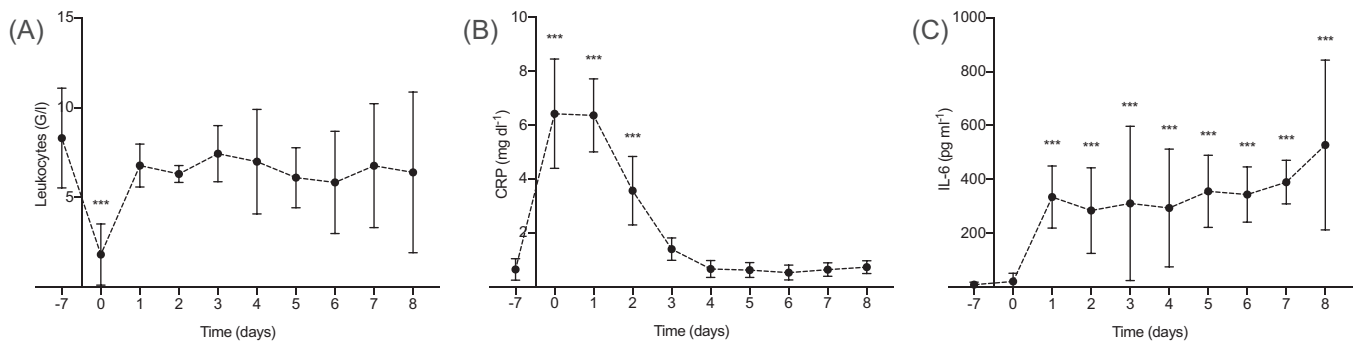
The following three graphs summarize our serum measurements during and after surgery:

- Figure 1 depicts heart [troponin (Figure 1A)], kidney [creatinine (Figure 1B)], and liver [bilirubin (Figure 1C)] function,
- Figure 2 shows hemoglobin levels (Figure 2A), serum LDH [(Figure 2B) a measure of hemolysis], and platelet counts (Figure 2C),
- Figure 3 shows markers of whole-body inflammation: leukocyte counts (Figure 3A), C-reactive protein [CRP (Figure 3B)], and Interleukin (IL) 6 (Figure 3C).

Remarkably, IL-6 serum levels did not return to baseline within the first postoperative week, which was probably caused by the treatment with the anti-IL-6 receptor antibody tocilizumab.<sup>19</sup> In contrast to Thompson and colleagues,<sup>1</sup> however, we did not observe any signs of severe organ dysfunction despite these elevated levels of IL-6; the slightly abnormal changes disappeared within the first postoperative week, and creatinine levels stayed normal throughout the full observation time.



**FIGURE 2** Hemoglobin levels (Figure 2A), serum LDH [(Figure 2B) a measure of hemolysis], and platelet counts (Figure 2C)



**FIGURE 3** Markers of whole-body inflammation: leukocyte counts (Figure 3A), C-reactive protein [CRP (Figure 3B)], and Interleukin (IL) 6 (Figure 3C)

## 4 | COMMENTS

In summary, short-term and long-term results were and will be possible after orthotopic cardiac pig-to-baboon transplantation. The unavoidable use of the heart-lung machine had no overt detrimental influence: there were no signs of lasting end-organ failures, and especially remarkable was that lung function was normal and that cardiac function recovered rapidly, thus minimizing the potentially harmful catecholamine therapy and providing optimal graft oxygenation. When compared to allogeneic procedures, however, several preconditions had to be met: stable genetic modifications were of course a necessity, but also the non-ischemic organ preservation and the handling of the recipient during and immediately after the use of the heart-lung machine.

Hearts are simple organs, much simpler than kidneys. Genetically modified hearts are easy to handle in the postoperative course, obviously easier when compared to kidneys.<sup>20</sup> Therefore, it could be argued that porcine hearts should be first in the clinical arena.

## ACKNOWLEDGEMENTS

The authors thank the Walter Brendel Centre of Experimental Medicine, Munich, for support and provision of facilities, especially D. Merkus, M. Shakarami, and all animal caretakers. No funding information was applicable.

## ORCID

Matthias Längin <https://orcid.org/0000-0003-0996-4941>

Bruno Reichart <https://orcid.org/0000-0003-2859-3664>

Peter J. Cowan <https://orcid.org/0000-0001-9016-4954>

Eckhard Wolf <https://orcid.org/0000-0002-0430-9510>

Jan-Michael Abicht <https://orcid.org/0000-0001-7361-1249>

## REFERENCES

1. Thompson CP, Jagdale A, Walcott G, et al. A perspective on the potential detrimental role of inflammation in pig orthotopic heart xenotransplantation. *Xenotransplantation*. 2021;28(4):e12687.
2. Gibbon JH Jr. The maintenance of life during experimental occlusion of the pulmonary artery followed by survival. *Surg Gynec Obst*. 1939;69:602-614.
3. Gibbon JH Jr. Application of a mechanical heart and lung apparatus to cardiac surgery. *Minn Med*. 1954;37(3):171-185.
4. Kirklin JW, Dushane JW, Patrick RT, et al. Intracardiac surgery with the aid of a mechanical pump-oxygenator system (gibbon type): report of eight cases. *Proc Staff Meet Mayo Clin*. 1955;30(10):201-206.
5. Dewall RA, Gott VL, Lillehei CW, et al. A simple, expendable, artificial oxygenator for open heart surgery. *Surg Clin North Am*. 1956:1025-1034.
6. Lillehei CW, Dewall RA, Read RC, Warden HE, Varco RL. Direct vision intracardiac surgery in man using a simple, disposable artificial oxygenator. *Dis Chest*. 1956;29(1):1-8.
7. Iwahashi H, Yuri K, Nosé Y. Development of the oxygenator: past, present, and future. *J Artif Organs*. 2004;7(3):111-120.
8. Kirklin JW, Barrat-Boyes G. *Cardiac Surgery*. 1st ed. Wiley and Sons; 1986: 44-74.

9. Kirklin JW, Barrat-Boyes G. *Cardiac Surgery*. 2 ed. Churchill Livingstone; 1993: 73-128.
10. Kouchoukos NT, Kirklin JW, Barrat-Boyes G. *Kirklin/Barrat-Boyes - Cardiac Surgery*. 4 ed. Churchill Livingstone; 2003: 79-130.
11. Mavroudis C, Backer CL. *Pediatr Cardiac Surg*. 2003: 171-222.
12. Novitzky D, Cooper DK, Human PA, Reichart B, Zuhdi N. Triiodothyronine therapy for heart donor and recipient. *J Heart Transplant*. 1988;7(5):370-376.
13. Mohiuddin MM, Reichart B, Byrne GW, McGregor CGA. Current status of pig heart xenotransplantation. *Int J Surg*. 2015;23(Pt B):234-239.
14. Längin M, Mayr T, Reichart B, et al. Consistent success in life-supporting porcine cardiac xenotransplantation. *Nature*. 2018;564(7736):430-433.
15. Reichart B, Längin M, Radan J, et al. Pig-to-non-human primate heart transplantation: the final step toward clinical xenotransplantation?. *J Heart Lung Transplant*. 2020;39(8):751-757.
16. Längin M, Reichart B, Steen S, et al. Cold non-ischemic heart preservation with continuous perfusion prevents early graft failure in orthotopic pig-to-baboon xenotransplantation. *Xenotransplantation*. 2021;28(1):e12636.
17. Steen S, Paskevicius A, Liao Q, Sjöberg T. Safe orthotopic transplantation of hearts harvested 24 hours after brain death and preserved for 24 hours. *Scand Cardiovasc J*. 2016;50(3):193-200.
18. Lower RR, Shumway NE. Studies on orthotopic homotransplantation of the canine heart. *Surg Forum*. 1960;11:18-19.
19. Nishimoto N, Terao K, Mima T, Nakahara H, Takagi N, Kakehi T. Mechanisms and pathologic significances in increase in serum interleukin-6 (IL-6) and soluble IL-6 receptor after administration of an anti-IL-6 receptor antibody, tocilizumab, in patients with rheumatoid arthritis and Castleman disease. *Blood*. 2008;112(10):3959-3964.
20. Iwase H, Yamamoto T, Cooper DKC. Episodes of hypovolemia/dehydration in baboons with pig kidney transplants: a new syndrome of clinical importance?. *Xenotransplantation*. 2019;26(2):e12472.

**How to cite this article:** Bender M, Längin M, Reichart B, et al. Overcoming perioperative inflammation as a hurdle for successful preclinical orthotopic cardiac xenogeneic transplantations – particular in regard of the mandatory use of heart-lung machines. *Xenotransplantation*. 2022;29:e12749. <https://doi.org/10.1111/xen.12749>