

Structural Neuroimaging of Hippocampus and Amygdala Subregions in Posttraumatic Stress Disorder: A Scoping Review

Ziv Ben-Zion, Nachshon Korem, Naomi B. Fine, Sophia Katz, Megha Siddhanta, Melissa C. Funaro, Or Duek, Tobias R. Spiller, Sarah K. Danböck, Ifat Levy, and Ilan Harpaz-Rotem

ABSTRACT

Numerous studies have explored the relationship between posttraumatic stress disorder (PTSD) and the hippocampus and the amygdala because both regions are implicated in the disorder's pathogenesis and pathophysiology. Nevertheless, those key limbic regions consist of functionally and cytoarchitecturally distinct substructures that may play different roles in the etiology of PTSD. Spurred by the availability of automatic segmentation software, structural neuroimaging studies of human hippocampal and amygdala subregions have proliferated in recent years. Here, we present a preregistered scoping review of the existing structural neuroimaging studies of the hippocampus and amygdala subregions in adults diagnosed with PTSD. A total of 3513 studies assessing subregion volumes were identified, 1689 of which were screened, and 21 studies were eligible for this review (total $N = 2876$ individuals). Most studies examined hippocampal subregions and reported decreased CA1, CA3, dentate gyrus, and subiculum volumes in PTSD. Fewer studies investigated amygdala subregions and reported altered lateral, basal, and central nuclei volumes in PTSD. This review further highlights the conceptual and methodological limitations of the current literature and identifies future directions to increase understanding of the distinct roles of hippocampal and amygdalar subregions in posttraumatic psychopathology.

<https://doi.org/10.1016/j.bpsgos.2023.07.001>

A substantial body of neuroimaging literature has investigated the relationship between posttraumatic stress disorder (PTSD) and the morphology of the hippocampus and the amygdala (1,2). These limbic regions have prominent roles in neurobiological models of PTSD, including fear learning, threat and salience detection, emotion regulation, and contextual processing (3). Importantly, the hippocampus and the amygdala are not homogeneous structures but rather consist of cytoarchitecturally and functionally distinct subregions (also referred to as hippocampal subfields and amygdala nuclei). In recent years, new automated tools and protocols for subregion segmentation have been introduced into human neuroimaging, allowing a more detailed examination of the different parts of the hippocampus and amygdala (4–7). These methodological advances have opened new avenues for research into the unique roles that different subregions may play in the etiology of posttraumatic psychopathology.

The hippocampal complex is critical for encoding emotional memories and modulating appropriate emotional responses to fearful stimuli, making it a key region in the investigation of posttraumatic psychopathology (8,9). While changes in hippocampal activity in PTSD are not consistent (10), smaller hippocampal volume is the most consistent structural abnormality in PTSD (11,12). However, examining the hippocampus as a whole ignores its heterogeneity (13) and may mask

abnormalities in specific subregions that are differently affected in PTSD (14). The hippocampus is a complex and highly specialized structure composed of multiple subregions with distinct cellular layers, circuitry, and functions (15). Based on histology, the hippocampus proper (cornu ammonis [CA]) is divided into 2 main parts, CA1 and CA3 (often combined with CA2), which are composed of pyramidal neurons organized in a laminar fashion. The dentate gyrus (DG), located at the border of the hippocampus proper and the entorhinal cortex, is densely packed with granule cells. The DG also includes the polymorphic region, referred to as the CA4. The subiculum, located between the CA1 and the entorhinal cortex, is the main output region of the hippocampus.

Animal models of PTSD suggest that the hippocampus mediates the stress response and release of glucocorticoids from the hypothalamic-pituitary-adrenal axis (16) and that chronic activation of the hypothalamic-pituitary-adrenal axis due to stress may in turn cause hippocampal volume loss (17). Animal research further indicates that discrete hippocampal subregions could be relevant to the neurobiology of fear, anxiety, and PTSD. For instance, Snyder *et al.* (18) reported that mice without adult neurogenesis were more susceptible to anxio-depressive-like behavior following acute stress, suggesting that new neurons in the hippocampal DG are critical for the regulation of the hypothalamic-pituitary-adrenal axis

response to stress (18). Another study examining a rat model of PTSD pointed to the ventral CA1 subregion of the hippocampus as a potential key mediator of stress-induced anxiety-like behavior (19). In contrast to animal studies of PTSD, human neuroimaging research has primarily focused on the structure and function of the whole hippocampus until recent years.

The amygdala is another brain structure that is strongly implicated in PTSD pathophysiology (20), with over 30 years of research in the context of threat learning and extinction (21,22). Specifically, it is critically involved in fear response, conditioning, and generalization (23–26) and facilitates the response to stressful traumatic events (8). Patients diagnosed with PTSD typically show a hyperactive amygdala in response to affective and trauma-related stimuli, and this activation was correlated with symptom severity (27,28). Evidence of altered whole amygdala volume in PTSD is equivocal, with findings of no difference, smaller, or larger amygdala volumes in patients relative to control participants (1,2,11,29). Like the hippocampus, rather than being a unitary structure, the amygdala is formed from a collection of interconnected subregions (nuclei) that relay signals from multiple brain areas (i.e., cortical and subcortical subregions) (30). These nuclei can be distinguished on the basis of cytoarchitectonics, histochemistry, and the connections that they make (31,32). Traditionally, the amygdala can be divided into 2 broad complexes, the centrocorticomedial division and the basolateral (BLA) division (33). The centrocorticomedial division includes the central, medial, and cortical amygdala nuclei, whereas the BLA includes the basal, accessory basal, and lateral nuclei (34–36). The centrocorticomedial is densely interconnected with the striatum, brainstem, and the hypothalamus, while the BLA is extensively interconnected with sensory and prefrontal cortical areas, the thalamus, and the hippocampus (37,38).

Animal studies have shown changes in amygdala morphology in relation to chronic stress or unique features of structural plasticity in the amygdala (e.g., traumatic stress leads to trophic changes and synaptogenesis in the amygdala) (10,39). After decades of studying animal models of PTSD, it seems that specific amygdala subnuclei are responsible for alterations in certain fear-, anxiety-, and stress-related behaviors. The BLA appears to be necessary for the formation and/or expression of associative fear memories, with its lateral nucleus serving as a convergence site for sensory and aversive information that is relayed to the central nucleus to drive fear-related behaviors (40–42). Indeed, smaller BLA volumes have been associated with increased levels of fear conditioning and excessive glucocorticoid stress response (43,44). While much progress has been made using animal models of PTSD to understand the involvement of amygdala subregions in fear conditioning and extinction, the knowledge gained has not yet translated into better knowledge or treatments for patients with PTSD (45).

Advances in human neuroimaging techniques, including high-resolution magnetic resonance imaging (MRI) and continuously developing analysis software, enable noninvasive in vivo visualization and quantitative macroanatomical characterization based on differences in tissue properties of specific brain structures (46). However, hippocampal and amygdala segmentation into subregions from MR images is

methodologically challenging, given their small size, anatomical complexity, and cellular morphology (47). In response, studies that combined cyto- and chemoarchitectural analyses with macroscopic landmarks were able to better separate different hippocampal and amygdala subregions in humans using MRI (48). Moreover, recent advances in gradient mapping techniques and in vivo parcellation has allowed characterization of both medial-to-lateral and anterior-to-posterior hippocampal axes, which may allow for a better understanding of human hippocampal organization and function (49). Consistent with the growing emphasis on obtaining larger sample sizes to achieve sufficient statistical power (50), manual delineation of subfields, a process that requires significant time and expertise, is becoming less practical. While manual segmentation has its advantages, it always involves some degree of subjectivity, and such variability poses significant challenges for replication (51,52). Overcoming these barriers, several automated subregion segmentation protocols for the amygdala and hippocampus have been developed in recent years, providing high-resolution, standardized, and relatively reliable segmentation (4–7,53,54).

Among the available automated tools, FreeSurfer (55) (<http://surfer.nmr.mgh.harvard.edu/>) is one of the most widely used. FreeSurfer first introduced hippocampal subfields segmentation in version 5.3 (2009) (7) and added the segmentation of amygdala nuclei in version 6.0 (2017) (5). Importantly, the early version (FreeSurfer 5.3) of hippocampal segmentation has been criticized for underestimating CA1 volumes and overestimating the subiculum in the hippocampal head (where the boundary between the 2 subfields is more difficult to delineate) (56,57). Since then, FreeSurfer has continued developing and improving its segmentation modules, with the recent version at the time of this writing being 7.3.2 (Aug, 2022), which allows cross-sectional and longitudinal segmentation of the hippocampus, amygdala, thalamus, and brainstem (<http://surfer.nmr.mgh.harvard.edu/fswiki/SubregionSegmentation>). The recent segmentation modules of FreeSurfer have demonstrated good reliability for larger amygdalar and hippocampal subregions, even in multisite MRI studies (58).

Given the improvements in recent automatic segmentation algorithms and the growing number of studies focusing on subregions of the hippocampus and amygdala in PTSD, a review of the existing empirical research is not only timely, but also imperative. Because the current MRI literature on subregion volumes in PTSD is still emerging and constrained, there is a need to map out key concepts, identify knowledge gaps, and highlight potential future directions rather than synthesize the results quantitatively or draw definitive conclusions. Therefore, we used a scoping review methodology (59) rather than a systematic review or meta-analysis (60) to evaluate existing MRI studies of hippocampus and amygdala subregion morphology (i.e., volume and shape) in adults diagnosed with PTSD. While others have reviewed neuroimaging studies of hippocampal subfields (but not amygdala nuclei) in schizophrenia and bipolar disorder (46) or in relation to psychosocial factors (14), this is the first study to review the structure of both hippocampal and amygdala subregions in PTSD. We aimed to synthesize findings from a variety of study designs and populations, detect consistent and contradictory results, and determine whether a future systematic review is needed and/or

Hippocampus and Amygdala Subregions in PTSD

feasible. Finally, we discuss important conceptual and methodological limitations and suggest future directions in neuroimaging of hippocampal and amygdala subregions in posttraumatic psychopathology.

METHODS

Protocol and Registration

This scoping review is informed by the framework described by the Joanna Briggs Institute (61,62) and follows the Preferred Reporting Items for Systematic Reviews and Meta-Analysis (PRISMA) Extension for Scoping Reviews guidelines (59). The protocol for this review was publicly preregistered with the Open Science Framework on March 24, 2022 (<http://doi.org/10.17605/OSF.IO/RCG8E>), before the beginning of the actual review process.

Eligibility Criteria

We included peer-reviewed studies using structural neuroimaging (MRI) of adult human subjects diagnosed with PTSD (i.e., patients) and control participants (e.g., trauma-exposed and/or healthy individuals) who had at least one quantitative volumetric measure of hippocampus subfields and/or amygdala nuclei. The term “subregions” usually refers to both the amygdala and hippocampus, while “subfields” is usually used for the hippocampus and “nuclei” for the amygdala. Any work that included animal models, a nonadult population (i.e., participants under 18 years of age), or individuals with traumatic brain injury or head injury, was excluded. Any research that was not peer reviewed, did not have a full text, or assessed only qualitative measures of the subregions, was similarly excluded. For the full list of inclusion and exclusion criteria, see [Box S2](#).

Information Sources and Literature Search

An experienced medical librarian consulted on methodology and ran a medical subject heading analysis of known key articles provided by the research team (63). On March 30, 2022, a comprehensive search of the following databases was performed: MEDLINE, EMBASE, APA PsycInfo, Cochrane CENTRAL, and Web of Science. For more details, see [Supplemental Methods](#) and [Box S2](#).

Selection of Sources of Evidence, Data Charting, and Data Items

Search results were pooled in EndNote version 20 (<http://www.endnote.com>) (64), and duplicates were removed (65). This set was then uploaded to the Covidence platform (<http://www.covidence.org>) (66), in which additional duplicates were identified and removed. The review process included 3 stages: 1) screening of titles and abstracts, 2) full-text screening, and 3) data extraction (for full details, see the [Supplement](#) and [Figure 2](#)).

Synthesis of Results

Upon a preliminary abstraction, the research team decided to group together studies that inspected the volumes of hippocampal subregions, amygdala subregions, or both ([Table 1](#)). The rationale was to group the most similar types of studies

together to ensure that their differences could be adequately compared. The reviewers then extracted the relevant data for each article: first author and year of publication, country of study site, sample size, gender distribution, mean age, study groups, research design, trauma type, PTSD measure, MRI field strength, subfield segmentation technique, the examined subregions, and the main findings regarding the associations between subregions' morphology and PTSD diagnosis and severity ([Table 1](#)).

The main findings of the different studies were summarized separately for studies of hippocampal subfields ($n = 19$) ([Table 1](#)) (12,67–83) and those of amygdala nuclei ($n = 5$) ([Table 1](#)) (12,73,83–85). The main challenge of the results synthesis in this review was the large variability between studies in the number of subregions and the specific subregions that were analyzed ([Table 1](#)). A secondary challenge was the subregions' parcellation because studies differed substantially on which subregions were studied and how the subregions were defined, as well as on whether they were studied bilaterally or unilaterally. To overcome this challenge, we grouped subregions based on: 1) well-established literature regarding their anatomy and function (15,86,87) and 2) their absolute size because larger amygdalar and hippocampal structures have demonstrated better test-retest reliability across different MRI sites and vendors (58). These subregions are described in [Supplemental Methods](#) and illustrated in [Figure 1](#).

RESULTS

Overview of Studies

Finally, 21 studies, published between 2010 and 2022, fulfilled the inclusion/eligibility criteria and were included in this review (12,67–85) (for study selection, see [Supplemental Results](#)). Overall, 16 studies (76%) tested only hippocampal subfields ([Table 1](#)) (67–72,74–82), 2 (10%) tested only amygdala nuclei ([Table 1](#)) (84,85), and 3 (14%) tested both hippocampal and amygdala subregions ([Table 1](#)) (12,73,83). About one half of the studies were conducted in the United States ($n = 11$, 52%), while the others were conducted in China ($n = 4$, 19%), the Netherlands ($n = 2$, 10%), Israel, France, Norway, and South Africa ($n = 1$, 5% each). Sample sizes varied greatly, from the smallest study, which included 36 individuals (17 diagnosed with PTSD) (80), to the largest study, which included 355 subjects (149 diagnosed with PTSD) (84). The average sample size was 137 individuals ($SD = 91$), with one half of the studies having a sample size larger than 100 participants (median = 100). Gender distribution also varied between studies, one of which included only females ($n = 1$, 5%) (70) and others that included only (combat-exposed) males ($n = 3$, 14%) (76,79,80). Overall, there was a balanced gender distribution across all studies (median of 54% females). Participants' average age ranged from 21 to 57 years, with a mean age of 37 ± 9 years. For a detailed overview of the studies that were included, please see [Supplemental Results](#).

Hippocampal Subregions in PTSD

Hippocampal subregions were examined in 19 studies and across 2422 participants. The CA1 was examined in 84% of

Table 1. Characteristics and Main Findings of the Studies Included in This Review (N = 21)

Reference	Country of Study Site	Total N ^a	Gender, Males, %	Mean Age, Years	Study Groups (n)	Research Design ^b	Trauma Type	PTSD Measures	MRI Field Strength	Subfield Segmentation	Examined Subregions	Main Findings
Hippocampal Subregions Only (n = 16)												
Ahmed-Leitao <i>et al.</i> (67)	South Africa	90	53%	34	PTSD (17) SAD with trauma (26) SAD without trauma (22) HC (25)	Cross-sectional	Early childhood trauma	CTQ	3T	FreeSurfer version 6.0	12 Unilateral subregions (CA1, CA3, CA4, FIM, GC/ML/DG, HATA, HF, HT, ML, PaSUB, PrSUB, SUB)	Right PaSUB, left HATA (PTSD < SAD with/without trauma, HC)
Averil <i>et al.</i> (68)	USA	68	90%	35	PTSD (36) TEC (32)	Cross-sectional	Combat-exposed veterans	CAPS-IV	3T	FreeSurfer version 6.0	10 Bilateral subregions (CA1, CA2/3, CA4, DG, PrSUB, SUB, PaSUB, HATA, ML, HT)	More severe PTSD ↔ smaller bilateral HATA volume Only in PTSD group: more severe PTSD ↔ smaller bilateral HATA, CA2/3, CA4 and ML volumes
Bonne <i>et al.</i> (69)	USA	44	14%	36	PTSD (22) Age- and gender-matched HC (22)	Cross-sectional	Sexual or physical/emotional abuse, MVA, assault, or robbery	CAPS-IV	3T	Visual assessment by one rater [described in (69)]	3 Bilateral subregions (anterior HC, posterior HC, SUB)	Bilateral posterior HC (PTSD < HC)
Chalavi <i>et al.</i> (70)	Netherlands	61	0%	42	PTSD-DID (17) PTSD (16) HC (28)	Cross-sectional	Interpersonal traumatizing events (childhood and/or adult life)	CAPS-IV (PTSD group only)	3T	FreeSurfer version 5.1 + Shape analysis [described in (135)]	6 Unilateral subregions (CA1, CA2/3, CA4/DG, PrSUB, SUB, FIM)	Bilateral CA2/3, right CA4/DG, left PreSUB (PTSD-DID + PTSD < HC) Bilateral CA2/3, bilateral CA4/DG, bilateral SUB, right CA1, left PrSUB (PTSD-DID < HC) left CA4/DG, left SUB (PTSD-DID < PTSD)
Chen <i>et al.</i> (71)	USA	282	81%	40	PTSD (142) TEC (140)	Cross-sectional	Combat-exposed veterans	SCID-IV CAPS-IV or DTS	3T	FreeSurfer version 6.0 + Shape analysis [described in (136)]	12 Unilateral subregions (CA1, CA3, CA4, DG, PreSUB, SUB, PaSUB, HATA, ML, FIM, HT, HF)	Bilateral CA3, Left CA1 (PTSD < TEC), only if the ipsilateral whole hippocampal volume was included as a covariate
Hayes <i>et al.</i> (72)	USA	97	94%	30	PTSD (58) TEC (39)	Cross-sectional	Combat-exposed veterans	CAPS-IV or PCL-M	3T	FreeSurfer version 5.1	5 Bilateral subregions (CA1, CA2/3, CA4/DG, PrSUB, SUB)	Bilateral CA4/DG (PTSD < TEC) More severe PTSD ↔ smaller CA4/DG volume
Luo <i>et al.</i> (74)	China	107	42%	57	PTSD (57) TEC (11) HC (39)	Cross-sectional	Parents who lost their only child	CAPS-IV	3T	FreeSurfer version 5.1	6 Unilateral subregions (CA1, CA2/3, CA4/DG, PrSUB, SUB, FIM)	Bilateral CA2/3, bilateral CA4/DG, left SUB (PTSD < HC, TEC < HC)
Luo <i>et al.</i> (75)	China	165	40%	57	PTSD (55) TEC (60) HC (50)	Cross-sectional	Parents who lost their only child	CAPS-IV	3T	VBM using SPM-12 [described in (77)]	1 Unilateral subregion (Right CA3)	No volume differences between groups (PTSD, TEC, HC)

Table 1. Continued

Reference	Country of Study Site	Total N ^a	Gender, Males, %	Mean Age, Years	Study Groups (n)	Research Design ^b	Trauma Type	PTSD Measures	MRI Field Strength	Subfield Segmentation	Examined Subregions	Main Findings
Misaki <i>et al.</i> (76)	USA	72	100%	31	PTSD-NF-amygdala (20) PTSD-NF-control (9) HC (43)	Longitudinal (pre- and posttreatment)	Combat-exposed veterans	CAPS-IV	3T	FreeSurfer version 7.1.1	14 Unilateral subregions (CA1 head, CA1 body, CA3 head, CA3 body, CA4 head, CA4 body, PrSUB head, PrSUB body, GC-ML-DG head, GC-ML-DG body, SUB head, SUB body, PaSUB head, HATA head)	No volume differences between groups at the baseline Left CA1 head volume change (increase in PTSD-NF-amygdala, decreased in PTSD-NF-Control)
Morey <i>et al.</i> (77)	USA	290 ^d	46%	39	PTSD (145) TEC (145)	Cross-sectional	Combat-exposed veterans or interpersonal violence ^e	SCID-IV CAPS-IV or DTS	3T	FreeSurfer version 6.0.0	12 Unilateral subregions (CA1, CA2/3, CA4, GC-DG, HATA, FIM, PaSUB, PrSUB, SUB, ML, HF, HT)	Significant interactions between genetic variants and childhood trauma or lifetime PTSD within the FIM, SUB, CA1, and HATA
Postel <i>et al.</i> (88)	France	148	47%	35	PTSD (53) ^f TEC (39) HC (56)	Cross-sectional	Terrorist attacks (Paris, France, 2015)	SCID-5, PCL-5	3T	ASHS [described in (137)]	4 Bilateral subregions (CA1, CA2/3/DG, HT, SUB)	Bilateral CA2/3/DG, CA1 (PTSD < TEC) Bilateral CA2/3/DG, CA1, SUB (PTSD < HC) Only in PTSD group: smaller bilateral CA1 volume ↔ more severe intrusion symptoms and smaller bilateral CA2/3/DG volume ↔ more severe avoidance and hyperarousal symptoms
Suarez-Jimenez <i>et al.</i> (78)	USA	46	28%	40	PTSD (22) Panic disorder (24)	Cross-sectional	Patients at medical institutes (trauma type not specified)	CAPS-IV, SCID-IV	3T	VBM using SPM-12 [described in (86)]	2 Bilateral subregions (anterior and posterior HC)	Only in PTSD group: for those who received affect-focused treatments, but not exposure-based treatments, smaller anterior HC pretreatment ↔ greater clinical improvement
Szeszko <i>et al.</i> (79)	USA	44	100%	35	PTSD (22) Gender-matched TEC (22)	Cross-sectional	Combat-exposed veterans	CAPS-IV CAPS-5	3T	FreeSurfer version 7.1.1	11 Bilateral subregions (CA1, CA2/3, CA4, GC-DG, ML, HT, FIM, HATA, SUB, PaSUB, PrSUB)	Bilateral CA1, CA2/3, CA4, GC-DG, ML, SUB (PTSD < TEC)

Table 1. Continued

Reference	Country of Study Site	Total N ^a	Gender, Males, %	Mean Age, Years	Study Groups (n)	Research Design ^b	Trauma Type	PTSD Measures	MRI Field Strength	Subfield Segmentation	Examined Subregions	Main Findings
Wang <i>et al.</i> (80)	USA	36	100%	40	PTSD (17) Age-matched TEC (14) Age-matched HC (5)	Cross-sectional	Combat-exposed veterans	CAPS-IV SCID-IV	4T	Visual assessment by two raters [described in (138)]	4 Unilateral subregions (ERC, SUB, CA1, CA3/DG)	Bilateral CA3/DG (PTSD < TEC + HC)
Weis <i>et al.</i> (81)	USA	208 ^c	45%	33	PTSD (208) ^d	Longitudinal (T1, T2 = 2 consecutive days at 2 weeks posttrauma; T3 = 6 mo posttrauma)	ED-admitted trauma survivors (Mostly MVA)	CAPS-5 (at T3) Predicting PTSD Questionnaire (139) (at T1)	3T	FreeSurfer version 6.0	12 Bilateral subregions (CA1, CA3, CA4, PaSUB, PrSUB, SUB, GC-DG, HATA, FIM, ML, HF, HT)	None of the subfield volumes at T1 were prospectively related to PTSD symptoms at T3 None of the subfield volumes at T3 were associated with PTSD symptoms at T3
Yuan <i>et al.</i> (82)	China	142	33%	44	PTSD (69) TEC (73)	Cross-sectional	Earthquake survivors (Wenchuan, China, 2008)	CAPS-IV SCID-IV	3T	FreeSurfer version 6.0	3 Unilateral subregions (CA1, CA3, and DG)	More severe PTSD ↔ smaller left CA3 volume Moderation effect of <i>DRD2</i> Taq1A polymorphism
Amygdala Subregions Only (n = 2)												
Morey <i>et al.</i> (84)	USA	355	78%	39	PTSD (149) TEC (206)	Cross-sectional	Combat-exposed veterans	CAPS-IV CAPS-5 or DTS	3T	FreeSurfer version 6.0 + Shape analysis [described in (140)]	9 Unilateral subregions (BaA, CeA, LaA, AcBa, MedA, PaLaA, CoA, AAA, CATA)	Bilateral LaA, PaLa, AcBa (PTSD < TEC) left CeA, MedA, CoA (PTSD > TEC) Shape analysis: radial distance (anterior amygdala) and Jacobian determinant (posterior amygdala) (PTSD < TEC)
Ousdal <i>et al.</i> (85)	Norway	99	46%	21	PTSD (45) TEC (54)	Cross-sectional	Terrorist attacks (Utøya, Norway, 2011)	MINI 6.0.0 (141) (site 1), PCL-C (142) (site 2), PTSD-RI (143) (site 3)	3T	FreeSurfer version 6.0	6 Unilateral subregions (BaA, CeA, LaA, AcBa, MedA, CoA)	More severe PTSD ↔ Smaller volumes of right LaA, BaA, AcBa, MedA, CeA. Greater symptom reduction ↔ Larger right LaA volume
Both Hippocampus and Amygdala Subregions (n = 3)												
Ben-Zion <i>et al.</i> (12)	Israel	100	44%	33	PTSD Remission (71) Nonremission (29)	Longitudinal (T1, T2, and T3 = 1, 6, and 14 mo posttrauma)	ED-admitted trauma survivors (Mostly MVA)	CAPS-IV CAPS-5	3T	FreeSurfer version 7.1.0	Hippocampus: 4 unilateral subregions (CA1, CA3, DG, SUB) Amygdala: 3 unilateral subregions (LaA, BaA, CeA)	Smaller bilateral SUB and right CA1 at T1 (PTSD Remission > Nonremission) No time-dependent longitudinal changes (T1 to T2 to T3) in of the subregions

Table 1. Continued

Reference	Country of Study Site	Total N ^f	Gender, Males, %	Mean Age, Years	Study Groups (n)	Research Design ^g	Trauma Type	PTSD Measures	MRI Field Strength	Subfield Segmentation	Examined Subregions	Main Findings
Koch <i>et al.</i> (73)	Netherlands	221	73%	24	Symptom increase (35) Symptom decrease (46) No change (140) ^e	Longitudinal (baseline and 16-months follow-up) ^g	Police recruits exposed to potentially traumatic events	PCL-5 CAPS-5 (only at follow-up)	3T	FreeSurfer version 6.0	Hippocampus: 3 unilateral subregions (CA1, CA3, DG) Amygdala: 4 unilateral subregions (BaA, CeA, LaA, MedA)	Smaller left DG volume at baseline ↔ more severe PTSD at follow-up More police-related traumatic events ↔ increase in left BaA volume from baseline to follow-up
Zhang <i>et al.</i> [(83)]	China	201	32%	42	PTSD (69) TEC (76) HC (56)	Cross-sectional	Earthquake survivors (Wenchuan, China, 2008)	CAPS-IV, SCID-IV	3T	FreeSurfer version 6.0	Hippocampus: 12 unilateral subregions (CA1, CA3, CA4, FIM, GC/ML/DG, HATA, HF, HT, ML, PaSUB, PrSUB, SUB; divided to hippocampal head and body when applicable) Amygdala: 9 unilateral subregions (BaA, CeA, LaA, AcBa, MedA, PaLaA, CoA, AAA, CATA)	Right PrSUB, Left MedA (PTSD > TEC) Left CA3, CA4, GC/ML/DG, PrSUB, FIM, HATA, HT, AcBa, CeA, CoA, CATA; right HT, CA3, CA4, GC/ML/DG, ML, SUB, HT, HF, BaA, AcBa, CeA, MedA, CoA (PTSD = TEC < HC) More severe PTSD ↔ Smaller right AcBa, ML Only in PTSD group: More severe PTSD ↔ Smaller right CoA Only in TEC group: More severe PTSD ↔ Larger right CoA

AAA, anterior amygdaloid area; AcBa, accessory basal amygdala; ASHS, automatic segmentation of hippocampal subfields; BaA, basal amygdala; CA, cornu ammonis; CAPS, Clinician-Administered PTSD Scale; CATA, cortico-amygdaloid transition area; CeA, central amygdala; CoA, cortical amygdala; DG, dentate gyrus; DTS, Davidson Trauma Scale; ED, emergency department; ERC, entorhinal cortex; FIM, fimbria; GC-DG, granule cell layer of dentate gyrus; HATA, hippocampal-amygdala transition area; HC, healthy control; HF, hippocampal fissure; HT, hippocampus tail; LaA, lateral amygdala; MedA, medial amygdala; ML, molecular layer; MRI, magnetic resonance imaging; MVA, motor-vehicle accident; NF, neurofeedback; PaLaA, paralaminar amygdala; PaSUB, para-subiculum; PCL, PTSD Checklist; PrSUB, pre-subiculum; PTSD, posttraumatic stress disorder; PTSD-DID, PTSD with dissociative identity disorder; PTSD-NF, PTSD patients who underwent neurofeedback targeting the amygdala (PTSD-NF-amygdala) or a control region (PTSD-NF-Control); SAD, social anxiety disorder; SCID, Structured Clinical Interview for DSM; SUB, subiculum; T, time; TEC, trauma-exposed control; VBM, voxel-based morphometry.

^aRefers to the total number of subjects examined, before exclusion (e.g., dropouts, missing data, poor quality data).

^bRefers to the number of MRI assessments (and not clinical assessments). All studies with a single MRI scan are considered cross-sectional, and those with more than one MRI scan are considered longitudinal.

^cThe authors combined full PTSD and partial PTSD (re-experiencing + one other cluster) into one PTSD group.

^dAll individuals met criterion A of DSM-5 and scored a minimum of 3 on the Predicting PTSD Questionnaire.

^eAnalysis of symptom change was conducted based on the PCL scores (follow-up compared with baseline), dividing participants into 3 groups: symptom increase, symptom decrease, and no symptom change.

^fHalf of the subjects ($n = 11$) experienced prolonged prepubertal trauma: sexual or physical/emotional abuse. The other half ($n = 11$) underwent a single trauma in adulthood: sexual assault, MVA, or assault/robbery.

^gBaseline assessment took place while recruits were in a safe school environment at the police academy. A follow-up assessment took place 16 months later, after the emergency aid services training, which included exposure to potentially traumatic events.

^hIncluded 2 independent samples: Mental Illness Research Education and Clinical Centre and Grady Trauma Project.

ⁱMental Illness Research Education and Clinical Centre sample: military veterans with high levels of trauma in the military (in some cases during childhood/adolescence). Grady Trauma Project sample: civilian women with high rates of sustained trauma and interpersonal violence (in some cases during childhood/adolescence).

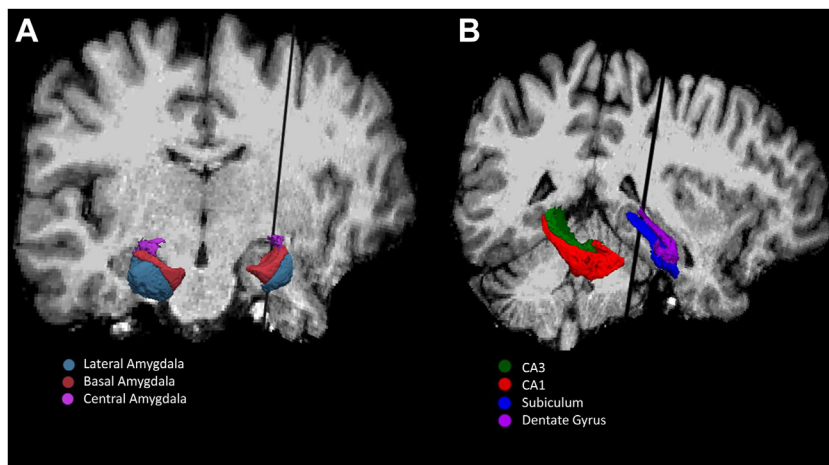


Figure 1. The hippocampus and amygdala subregions were grouped across all reviewed studies ($n = 21$) based on the well-established literature of their anatomy and function and on their absolute size because larger subregions showed greater test-retest reliability across different magnetic resonance imaging sites and vendors. These results were generated with FreeSurfer 7.1.0 and are overlaid on an anatomical scan of a single subject. Amygdala nuclei (A) and hippocampal subfields (B) are displayed in 3 dimensions on coronal and sagittal planes, with a black line separating the two. The amygdala subregions are presented bilaterally, whereas the hippocampal subregions are presented unilaterally. CA, cornu ammonis.

studies (i.e., $n = 16$ of 19) and 89% of participants (i.e., $n = 2167$ of 2422). The majority of these studies ($n = 9$ of 16, 66%) found no association between the CA1 morphology and PTSD diagnosis or symptom severity ($n = 1170$ participants). The remaining 7 studies (44%) found CA1 to be significantly associated with PTSD (12,70,71,76,77,79,88). Of these, 5 studies ($n = 635$ participants) found smaller CA1 volumes in patients with PTSD (than in trauma-exposed control [TEC] or healthy control [HC] participants) or in individuals who developed nonremitting PTSD (compared with those who remitted) (12,70,71,79,88). Two of the 5 studies were referring to the bilateral CA1, 2 studies to the right CA1, and 1 study to the left CA1. Additionally, a genetic study found significant interactions between genetic variants and childhood trauma/lifetime PTSD within the CA1 subregion (77). A neurofeedback study found increased volume in the left CA1 head in the experimental group and decreased volume in the same region in the control group (76).

The CA3 was investigated in 89% of the studies ($n = 17$) and in 96% of participants ($n = 2332$). About one half of studies ($n = 8$, 47%) found no significant association between CA3 volume and PTSD ($n = 1243$ individuals). The others ($n = 9$, 53%) found lower bilateral CA3 volume in patients with PTSD (than in control participants) and/or linked it to more severe symptoms ($n = 1089$ individuals) (68,70,71,74,79,80,82,83,88). Lower CA3 volume in PTSD than in TEC was found in 4 studies (71,79,80,88), while 4 others observed similar volumes in both groups (68,74,82,83) [and 1 study did not have a TEC group (70)]. Interestingly, 2 studies found an association between CA3 volume and PTSD severity only among the PTSD group and not across all subjects (68,88).

The DG was examined in 84% of the studies ($n = 16$) and in 89% of participants ($n = 2167$). One half of them ($n = 8$, 50%), including 1252 individuals, reported no significant associations between DG volume and PTSD. The other half ($n = 8$, 50%) found lower DG volume in patients with PTSD (than in control participants) and/or found lower DG volume to be associated with more severe symptoms across 915 participants (70,72–74,79,80,83,88). This reduced volume was observed

bilaterally in most studies ($n = 6$), with 2 reporting significant results for one, but not the other, hemisphere (70,73). Specifically, a longitudinal study of police recruits found that smaller left DG at baseline was associated with more severe PTSD symptoms at 16-month follow-up (73). A recent study that combined the CA2, CA3, and DG into a single subregion found it to be specifically associated with more avoidance and hyperarousal PTSD symptoms (88).

The subiculum was examined in 79% of the studies ($n = 15$) and 76% of participants ($n = 1848$). Seven of the studies (47%) found similar volumes of the subiculum in patients with PTSD and control participants ($n = 807$ individuals). The others ($n = 8$, 53%) found a significant link between subiculum volume and PTSD ($n = 1041$ individuals) (12,67,70,74,77,79,83,88). Most of the evidence ($n = 5$) supports smaller subiculum volumes in patients with PTSD compared with TEC and/or HC participants. However, a study of earthquake survivors that compared 3 groups (PTSD, TEC, and HC) observed larger right presubiculum in patients with PTSD than in TEC participants (but smaller than in HC participants) (83). A longitudinal study of recent trauma survivors observed smaller bilateral subiculum volume in individuals who still met criteria for a PTSD diagnosis at 14 months posttrauma (i.e., nonremission) compared with those who recovered from initial symptoms (i.e., remission) (12). While 4 studies reported an association with volumes of the bilateral subiculum, 5 others found this association with volumes of the unilateral subiculum (3 studies in the left hemisphere and 2 in the right hemisphere).

Finally, the 2 (of 19) studies that performed additional shape analysis of hippocampal subfields did not find significant differences between individuals with PTSD and control participants in a total sample of 343 individuals (70,71). For results of additional hippocampal subregions, see Supplemental Results and Table 1.

Amygdala Subregions in PTSD

The main amygdalar subnuclei—the lateral, basal, and central amygdala—were examined in all 5 studies and across 967 participants. The lateral amygdala (LaA) was not associated

Hippocampus and Amygdala Subregions in PTSD

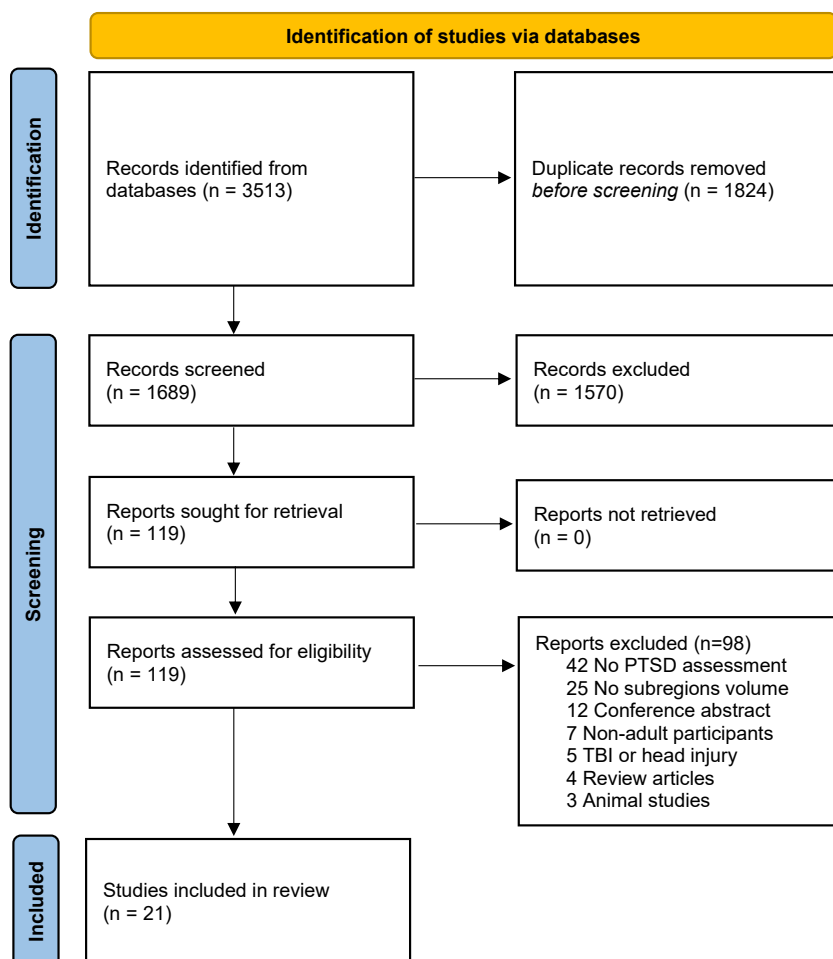


Figure 2. Flow of information through different phases of the review according to the Preferred Reporting Items for Systematic Reviews and Meta-Analysis (PRISMA) guidelines. PTSD, posttraumatic stress disorder; TBI, traumatic brain injury.

with PTSD in 3 (60%) of those studies and in 522 individuals (12,73,83). Two investigations reported altered LaA volumes in PTSD ($n = 454$ participants) (84,85). Specifically, smaller bilateral LaA volume was observed in patients with PTSD than TEC participants (84), and smaller right LaA was associated with less PTSD symptom reduction (from 4–5 to 24–36 months posttrauma) (85).

Basal amygdala (BaA) volume was correlated with PTSD in 3 (60%) of the studies ($n = 521$ individuals) (73,83,85). Of these, 2 research papers that examined survivors of single traumatic events (i.e., an earthquake and a terror attack) reported smaller right BaA volumes in PTSD (than HC) (83), and smaller right BaA volumes in PTSD were correlated with more severe symptoms (85). In contrast, a longitudinal study in which police recruits were tracked found that a greater amount of trauma exposure was associated with increased left BaA volume (during a 16-month period) (73). Two other studies (40%) found no association between BaA morphology and PTSD diagnosis or severity in a total of 455 participants (12,84).

The central amygdala (CeA) subregion was linked to PTSD in 3 (60%) of the 5 studies ($n = 655$ participants) (77,83,85), with mixed results. While one research group reported larger left CeA in PTSD than in TEC (77), a second one found similar

bilateral CeA volumes in PTSD and TEC, both of them significantly smaller than that which was found in HC (83). A third study led the investigators to conclude that smaller right CeA volumes were related to more severe PTSD symptoms (85). The other 2 studies (40%) found similar BaA volumes in patients with PTSD and control participants in a total of 321 individuals (12,73).

Finally, the single paper testing amygdala subregion shape analysis found that both radial distance (in the anterior amygdala) and Jacobian determinant (in the posterior amygdala) were lower in 149 patients with PTSD (than in 206 TEC participants) (84). For results of additional amygdalar subregions, see [Supplemental Results](#) and [Table 1](#).

DISCUSSION

This scoping review aimed to summarize findings from existing structural neuroimaging studies of hippocampal subfields and/or amygdala nuclei in adults diagnosed with PTSD. Following PRISMA Extension for Scoping Reviews guidelines (59), we identified 21 structural MRI studies examining the morphology of these limbic subregions across 2876 individuals ($n = 1354$

patients with PTSD and 1522 control participants). While a significant body of literature has documented structural alterations of hippocampal subregions in PTSD ($n = 19$ studies), there is a relative dearth of research examining amygdalar subregions volumes in this disorder ($n = 5$ studies). Currently, a systematic review or meta-analysis of the amygdala and hippocampal subregion volumes in PTSD is premature, mainly due to the insufficient data and the lack of standardization across studies.

While most studies of hippocampal subregions report decreased volumes in patients with PTSD, the exact subregions that were affected are inconsistent across studies. Despite the heterogeneity in the methods and results of the reviewed studies (discussed below), we found that the CA1, CA3, DG, and subiculum were the most-investigated subfields. Results indicated that they were significantly associated with PTSD in 44%, 53%, 50%, and 53% of the studies and across 29%, 47%, 42%, and 56% of the participants, respectively. Fewer studies examined amygdala subregions in PTSD ($n = 5$), and these yielded mixed findings of decreased, increased, or similar volumes in patients with PTSD and control participants. The lateral, basal, and central nuclei of the amygdala were examined across all 5 studies. Results revealed that they were significantly associated with PTSD in 40%, 60%, and 60% of the studies and across 47%, 53%, and 67% of the participants, respectively. There is a pressing need for more research on amygdala subregion morphology in relation to PTSD.

Future research is needed to better understand the relationship between specific hippocampal and amygdalar subregions and clinical manifestations of PTSD and specifically the hypothesis that these subregions may be differentially associated with distinct PTSD symptom clusters. For example, the hippocampal DG is involved in memory encoding and retrieval by separation of overlapping (perceptually similar) sensory inputs through pattern separation (89). Thus, if the DG is impaired, it could lead to an inability to distinguish between different cues, which can be manifested as fear generalization in the context of PTSD (90,91). Within the amygdala, the basolateral nucleus plays a role in fear learning, while the centromedial nucleus is important for fear expression through its projections to the brainstem and hypothalamus (42). Dysfunction of these nuclei may result in greater fear response, re-experiencing, and hyperarousal symptoms (43,92). Disentangling which subregions are linked to which impaired processes in PTSD (e.g., memory, learning) may enhance our mechanistic understanding of the disorder's pathophysiology because these subregions show structural and functional heterogeneity. If different subregions are involved in unique processes that contribute to specific behavioral manifestations, examining the structure and function of the whole hippocampus or amygdala may yield null results or bias results toward more robust processes.

Conceptual and Methodological Challenges

This review highlights several shortcomings in conceptualization and methodology of the current literature on hippocampal and amygdala subregions in PTSD. One main issue that was identified was the large variability across studies in which subregions were examined and the number of subregions that

were examined, ranging from 1 to 28 different subregions (see Results). This problem is rooted in the large variability of the subfield segmentation methods (e.g., FreeSurfer, voxel-based morphometry using SPM, automatic segmentation of hippocampal subfields, visual assessment) (see Table 1). Even among studies using the same segmentation method (FreeSurfer), at least 3 different software versions (version 5.1, version 6.0, version 7.1) were used. Notably, FreeSurfer version 5.1 has been criticized for its low construct validity and consequently deprecated (93,94), questioning the generalizability of findings based on this segmentation method (70,72,74). Regarding visual assessment/segmentation of the subregions, while it has some clear advantages, it is time-consuming and thus is not feasible for large studies (95) and also requires some subjectivity and is thus vulnerable to error (50). Finally, while most studies (66%) chose to analyze subregions separately for each hemisphere, one-third (33%) analyzed bilateral volumes, further contributing to the variability in the number of examined subregions.

Another methodological choice that influenced the results was the subjective decision about how to group different subregions. For example, while most studies separated the DG and CA3 subregions, 1 study (88) combined CA2, CA3, and DG into a single subregion, and 2 others separated the CA3 and the DG subregions into head and body (76,83). Moreover, some studies divided the hippocampus into only 2 (e.g., anterior and posterior) (78) or 3 parts (e.g., anterior, posterior, and subiculum) (69). Another subjective decision that increased the differences in the type and number of subregions examined was the authors' decision on testing specific subregions a priori and/or testing all subregions in an exploratory post hoc manner. To conclude, methodological differences and shortcomings may explain the contradictory and often inconsistent findings, highlighting the pressing need for standardization and methodological improvements in this field.

Several confounding factors might have affected the results of the studies reviewed here (and other results from structural neuroimaging of psychiatric populations). Although beyond the scope of this work, both alcohol (96,97) and cannabis (98) are known to be hippocampal toxins and have been shown to affect hippocampal subregions differently. Alcohol dependence can induce significant and nonreversible hippocampal volume loss (99–101), and regular cannabis use may cause a significant decrease in the amygdala's volume (102,103). Moreover, antidepressant medications (i.e., selective serotonin reuptake inhibitors) have been shown to increase angiogenesis and neurogenesis in the DG (104), and atypical antipsychotic medications (e.g., olanzapine and clozapine) have been associated with increased hippocampal neurogenesis and cell proliferation (105). It is still unclear whether antidepressants and antipsychotic medications influence amygdala subregional volumes (106,107). Furthermore, stressful or traumatic childhood experiences may lead to volumetric changes in hippocampal and amygdala subregions. Changes in the size of both these limbic regions could be mediated through dysregulated glucocorticoid release and increased inflammation following childhood abuse (108,109). Excessive glucocorticoid levels may cause decreased neurogenesis, atrophy of dendritic processes, and even hippocampal neurotoxicity (110). The hippocampus may be vulnerable to early-life stress due to the

Hippocampus and Amygdala Subregions in PTSD

high density of glucocorticoid receptors and persistent neurogenesis (111), with traumatic experiences potentially decreasing overproduction of synapses, thereby leading to smaller volume (112,113). Last but not least, recent work has provided evidence for postnatal neurogenesis in the human amygdala of a similar magnitude as that which has been suggested to exist within the hippocampus (114), suggesting that amygdalar plasticity may be similar to hippocampal plasticity. In conclusion, future neuroimaging studies of PTSD should assess (and if possible control for) other factors that can influence neurogenesis in the hippocampus and amygdala (e.g., alcohol and cannabis use, antidepressant and antipsychotic medications, traumatic stress during childhood, and pregnancy).

Beyond the methodological issues impeding the interpretation of the reported results, there are also questions concerning the underlying causes of hippocampal and amygdala subregion volume alternations in posttraumatic psychopathology (115,116). Most studies reviewed here were cross-sectional (81%) and thus cannot disentangle predisposed from acquired volume abnormalities (117). However, results of the 4 longitudinal studies conducted to date (12,73,76,81) generally suggest that volumetric alterations in the hippocampal and/or amygdala subregions reflect pretrauma vulnerability traits rather than acquired posttrauma consequences. It is also possible that persistent stress symptoms cause gradual subregion volume reduction over longer time periods (e.g., years instead of months). Future longitudinal studies with longer follow-up durations are needed to address this unresolved question.

Limitations

This review has several limitations that should be acknowledged. First, due to its scoping nature, the quality of the data from the different studies was not assessed. Rather, our aim was to present a synthesized, up-to-date overview of MRI volumetric studies of hippocampus and amygdala subregions in PTSD, detect consistent and inconsistent findings, and determine the feasibility of a future systematic review. Second, due to the relatively small number of studies reviewed, and their significant variability with regard to demographic and clinical variables, we were not able to review their impact in the current review. However, we did assess those putative confounders (e.g., age, gender, trauma type, clinical measures) in each study and report them in the results summary and in Table 1.

Future Directions

Future studies should meticulously incorporate unified parameters of segmentation protocols to encourage standardization, reproducibility, and replicability (51). Toward that end, using high field strengths (at least 3T), better spatial resolution ($<1 \text{ mm}^3$), and combining T1-weighted and T2-weighted scans would improve data quality in terms of acquisition (4,118). In terms of data analysis, simultaneous segmentation of both the hippocampus and the amygdala is highly preferred to overcome the issue of their anatomical proximity (i.e., joint segmentation ensures that structures do not overlap or leave gaps in between) (5,30). Studies should preferably use more than 1

version or tool for subregion segmentation to ensure the accuracy and generalizability of the results. In terms of study design, because traumatic events may have an enduring effect on the brain even in the absence of symptoms (119), future work should directly compare patients with PTSD with both trauma-exposed and trauma-naïve control groups. Finally, studies should present all their neuroimaging results, highlighting key ones and not hiding subthreshold ones, to enhance interpretation, reduce biases, and improve reproducibility (120).

Notwithstanding the methodological suggestions for future research, this review also points to several conceptual recommendations. First, research should integrate knowledge about hippocampal and amygdala structure and function in PTSD as tested *in vitro* and *in vivo* in animal models with implications for behavior that could be further investigated in human neuroimaging studies (46,121,122). Translational insights from animal models of PTSD could contribute to clinical human neuroimaging studies, informing theory-driven hypotheses regarding specific subregions that may be associated with specific PTSD symptoms (e.g., hyperarousal, avoidance). Second, as alternations in these limbic subregions have been reported across a variety of psychiatric disorders and consistent with the National Institute of Mental Health Research Domain Criteria (123), studies should study their structure in a transdiagnostic approach. For example, recent work showed that hippocampal volumes varied with transdiagnostic psychopathological dimensions; specifically, increased distress and anxious arousal were associated with reduced hippocampal CA1 and CA4/DG volumes (124). Third, given the inconsistent results found in this review, it is imperative to adhere to good scientific practice. That is, authors should clearly distinguish between hypotheses established before data collection (*a priori*) and those formed after (*posteriori*) and properly correct for multiple comparisons. They should also report negative or null findings, which often go unpublished, leading other investigators to conduct redundant studies. A good way to promote reproducibility and transparency is the use of registered reports, a form of empirical publication in which study proposals are peer reviewed and preaccepted before research is undertaken (125,126). Another recommended practice is sharing the data and the code to increase transparency, reliability, and collaboration between research teams (127).

Several promising recent studies have examined the resting-state functional connectivity of hippocampal (128,129) or amygdalar subregions (130,131) in PTSD. Although beyond the scope of this review, functional neuroimaging studies of hippocampal and amygdala subregions in PTSD hold great potential for advancing our understanding of the disorder. Nevertheless, it is important to recognize the limitations and challenges that are associated with this line of research. Notably, investigating amygdala function and connectivity in humans is prone to imaging artifacts due to its small volume (27), and studying even smaller subregions within the amygdala may be particularly susceptible to such artifacts (130). Furthermore, while functional connectivity analysis estimates the temporal correlation between activations of brain areas, it does not provide information about the direction of these correlations, thus warranting further investigation using structural and effective

connectivity measures. Despite these limitations, future research on the interrelationships within and between hippocampal and amygdala subregions could offer valuable insights into the neurobiological mechanisms underlying PTSD.

CONCLUSIONS

While the results of this review suggest potential structural alternations in hippocampal and amygdala subregions in PTSD, more research is needed to specify which subregions are associated with different processes and symptoms of this chronic disorder. Methodological differences, heterogeneous populations, and publication bias may explain inconsistent results across studies. This review suggests conceptual and methodological ways in which future studies can overcome current barriers and shed light on the specific roles of these limbic subregions in posttraumatic psychopathology. Consequently, these efforts may pave the way for novel therapeutic strategies for PTSD prevention and treatment (132–134).

ACKNOWLEDGMENTS AND DISCLOSURES

This research did not receive any specific grant from funding agencies in the public, commercial, or not-for-profit sectors.

We thank Dorota Peglow and Vermetha Polite of the Cushing/Whitney Medical Library for technical support.

A previous version of this work was published as a preprint on Open Science Framework: <https://osf.io/4rgmc/>.

All data used for this review are available in the article, the [Supplement](#), and upon request from the study group.

The authors report no biomedical financial interests or potential conflicts of interest.

ARTICLE INFORMATION

From the Yale School of Medicine, Yale University, New Haven, Connecticut (ZB-Z, NK, SK, MS, OD, TRS, SKD, IL, IH-R); US Department of Veterans Affairs National Center for PTSD, Clinical Neuroscience Division, VA Connecticut Healthcare System, West Haven, Connecticut (ZB-Z, NK, OD, TRS, IH-R); Wu Tsai Institute, Yale University, New Haven, Connecticut (ZB-Z, IL, IH-R); Department of Psychology, Yale University, New Haven, Connecticut (ZB-Z, IL, IH-R); Sagol Brain Institute Tel-Aviv, Tel Aviv Sourasky Medical Center, Tel Aviv, Israel (NBF); Faculty of Social Sciences, School of Psychological Science, Tel Aviv University, Tel Aviv, Israel (NBF); Harvey Cushing/John Hay Whitney Medical Library, Yale University, New Haven, Connecticut (MCF); Department of Epidemiology, Biostatistics and Community Health Sciences, Ben-Gurion University of the Negev, Beer Sheva, Israel (OD); Department of Consultation-Liaison Psychiatry and Psychosomatic Medicine, University Hospital Zürich, University of Zürich, Zürich, Switzerland (TRS); and Division of Clinical Psychology and Psychopathology, Department of Psychology, Paris Lodron University of Salzburg, Salzburg, Austria (SKD).

Address correspondence to Ziv Ben-Zion, Ph.D., at ziv.ben-zion@yale.edu.

Received Apr 17, 2023; revised Jun 28, 2023; accepted Jul 2, 2023.

Supplementary material cited in this article is available online at <https://doi.org/10.1016/j.bpsgos.2023.07.001>.

REFERENCES

- O'Doherty DCM, Chitty KM, Saddiqui S, Bennett MR, Lagopoulos J (2015): A systematic review and meta-analysis of magnetic resonance imaging measurement of structural volumes in posttraumatic stress disorder. *Psychiatry Res Neuroimaging* 232:1–33.
- Logue MW, van Rooij SJH, Dennis EL, Davis SL, Hayes JP, Stevens JS, *et al.* (2018): Smaller hippocampal volume in posttraumatic stress disorder: A multisite ENIGMA-PGC study: Subcortical volumetry results from posttraumatic stress disorder consortia. *Biol Psychiatry* 83:244–253.
- Shalev A, Liberzon I, Marmar C (2017): Post-traumatic stress disorder. *N Engl J Med* 376:2459–2469.
- Iglesias JE, Augustinack JC, Nguyen K, Player CM, Player A, Wright M, *et al.* (2015): A computational atlas of the hippocampal formation using ex vivo, ultra-high resolution MRI: Application to adaptive segmentation of in vivo MRI. *Neuroimage* 115:117–137.
- Saygin ZM, Kliemann D, Iglesias JE, van der Kouwe AJW, Boyd E, Reuter M, *et al.* (2017): High-resolution magnetic resonance imaging reveals nuclei of the human amygdala: Manual segmentation to automatic atlas. *Neuroimage* 155:370–382.
- Pipitone J, Park MT, Winterburn J, Lett TA, Lerch JP, Pruessner JC, *et al.* (2014): Multi-atlas segmentation of the whole hippocampus and subfields using multiple automatically generated templates. *Neuroimage* 101:494–512.
- Van Leemput K, Bakkour A, Benner T, Wiggins G, Wald LL, Augustinack J, *et al.* (2009): Automated segmentation of hippocampal subfields from ultra-high resolution in vivo MRI. *Hippocampus* 19:549–557.
- McEwen BS (2007): Physiology and neurobiology of stress and adaptation: Central role of the brain. *Physiol Rev* 87:873–904.
- Acheson DT, Gresack JE, Risbrough VB (2012): Hippocampal dysfunction effects on context memory: Possible etiology for post-traumatic stress disorder. *Neuropharmacology* 62:674–685.
- Henigsberg N, Kalember P, Petrović ZK, Sečić A (2019): Neuroimaging research in posttraumatic stress disorder – Focus on amygdala, hippocampus and prefrontal cortex. *Prog Neuro-psychopharmacol Biol Psychiatry* 90:37–42.
- Bromis K, Calem M, Reinders AATS, Williams SCR, Kempton MJ (2018): Meta-Analysis of 89 Structural MRI studies in posttraumatic stress disorder and comparison with major depressive disorder. *Am J Psychiatry* 175:989–998.
- Ben-Zion Z, Korem N, Spiller TR, Duek O, Keynan JN, Admon R, *et al.* (2023): Longitudinal volumetric evaluation of hippocampus and amygdala subregions in recent trauma survivors. *Mol Psychiatry* 28:657–667.
- Canada KL, Botdorf M, Riggins T (2020): Longitudinal development of hippocampal subregions from early- to mid-childhood. *Hippocampus* 30:1098–1111.
- Twait EL, Blom K, Koek HL, Zwartbol MHT, Ghaznawi R, Hendrikse J, *et al.* (2023): Psychosocial factors and hippocampal subfields: The Medea-7T study. *Hum Brain Mapp* 44:1964–1984.
- Fanselow MS, Dong HW (2010): Are the dorsal and ventral hippocampus functionally distinct structures? *Neuron* 65:7–19.
- Szeszko PR, Lehner A, Yehuda R (2018): Glucocorticoids and hippocampal structure and function in PTSD. *Harv Rev Psychiatry* 26:142–157.
- Jurgena MF, Eror F, Cleare AJ, Young AH (2020): The role of early life stress in HPA axis and anxiety. *Adv Exp Med Biol* 1191:141–153.
- Snyder JS, Soumier A, Brewer M, Pickel J, Cameron HA (2011): Adult hippocampal neurogenesis buffers stress responses and depressive behaviour. *Nature* 476:458–461.
- Schoenfeld TJ, Rhee D, Martin L, Smith JA, Sonti AN, Padmanaban V, Cameron HA (2019): New neurons restore structural and behavioral abnormalities in a rat model of PTSD. *Hippocampus* 29:848–861.
- Morey RA, Gold AL, LaBar KS, Beall SK, Brown VM, Haswell CC, *et al.* (2012): Amygdala volume changes in posttraumatic stress disorder in a large case-controlled veterans group. *Arch Gen Psychiatry* 69:1169–1178.
- Falls WA, Davis M (1995): Lesions of the central nucleus of the amygdala block conditioned excitation, but not conditioned inhibition of fear as measured with the fear-potentiated startle effect. *Behav Neurosci* 109:379–387.
- LeDoux JE, Iwata J, Cicchetti P, Reis DJ (1988): Different projections of the central amygdaloid nucleus mediate autonomic and behavioral correlates of conditioned fear. *J Neurosci* 8:2517–2529.
- Hartley CA, Phelps EA (2010): Changing fear: The neurocircuitry of emotion regulation. *Neuropsychopharmacology* 35:136–146.

Hippocampus and Amygdala Subregions in PTSD

24. Godsil BP, Kiss JP, Spedding M, Jay TM (2013): The hippocampal-prefrontal pathway: The weak link in psychiatric disorders? *Eur Neuropsychopharmacol* 23:1165–1181.
25. VanElzakker MB, Dahlgren MK, Davis FC, Dubois S, Shin LM (2014): From Pavlov to PTSD: The extinction of conditioned fear in rodents, humans, and anxiety disorders. *Neurobiol Learn Mem* 113:3–18.
26. Homan P, Levy I, Feltham E, Gordon C, Hu J, Li J, *et al.* (2019): Neural computations of threat in the aftermath of combat trauma. *Nat Neurosci* 22:470–476.
27. Hayes JP, Hayes SM, Mikedis AM (2012): Quantitative meta-analysis of neural activity in posttraumatic stress disorder. *Biol Mood Anxiety Disord* 2:9.
28. Rauch SL, Shin LM, Phelps EA (2006): Neurocircuitry models of posttraumatic stress disorder and extinction: Human neuroimaging research—past, present, and future. *Biol Psychiatry* 60:376–382.
29. Kuo JR, Kaloupek DG, Woodward SH (2012): Amygdala volume in combat-exposed veterans with and without posttraumatic stress disorder: A cross-sectional study. *Arch Gen Psychiatry* 69:1080–1086.
30. Amunts K, Kedo O, Kindler M, Pieperhoff P, Mohlberg H, Shah NJ, *et al.* (2005): Cytoarchitectonic mapping of the human amygdala, hippocampal region and entorhinal cortex: Intersubject variability and probability maps. *Anat Embryol (Berl.)* 210:343–352.
31. LaBar KS, LeDoux JE, Spencer DD, Phelps EA (1995): Impaired fear conditioning following unilateral temporal lobectomy in humans. *J Neurosci* 15:6846–6855.
32. Pitkanen A (2000): Connectivity of the rat amygdaloid complex. In: Aggleton JP, editor. *The Amygdala*. New York: Oxford University Press, 31–115.
33. LeDoux J (2007): The amygdala. *Curr Biol* 17:R868–R874.
34. Heimer L, de Olmos JS, Alheid GF, Pearson J, Sakamoto N, Shinoda K, Marksteiner J, Switzer RC (1999): The human basal forebrain. Part II. In: Bloom FE, Björklund A, Hökfelt T, editors. (1999), *Handbook of Chemical Neuroanatomy*, vol 15. The Netherlands: Elsevier, 57–226.
35. Baxter MG, Murray EA (2002): The amygdala and reward. *Nat Rev Neurosci* 3:563–573.
36. Kalin NH, Shelton SE, Davidson RJ (2004): The role of the central nucleus of the amygdala in mediating fear and anxiety in the primate. *J Neurosci* 24:5506–5515.
37. Sah P, Faber ESL, Lopez De Armentia M, Power J (2003): The amygdaloid complex: Anatomy and physiology. *Physiol Rev* 83:803–834.
38. Amaral DG, Price JL, Pitkanen A, Carmichael ST (1992): Anatomical organization of the primate amygdaloid complex. In: Aggleton JP, editor. *The Amygdala: Neurobiological Aspects of Emotion, Memory and Mental Dysfunction*. New York: Wiley-Liss, 1–66.
39. Popoli M, Yan Z, McEwen BS, Sanacora G (2011): The stressed synapse: The impact of stress and glucocorticoids on glutamate transmission. *Nat Rev Neurosci* 13:22–37.
40. Maren S, Quirk GJ (2004): Neuronal signalling of fear memory. *Nat Rev Neurosci* 5:844–852.
41. Fanselow MS, LeDoux JE (1999): Why we think plasticity underlying Pavlovian fear conditioning occurs in the basolateral amygdala. *Neuron* 23:229–232.
42. Tovote P, Fadok JP, Lüthi A (2015): Neuronal circuits for fear and anxiety [published correction appears in *Nat Rev Neurosci* 2015; 16: 439]. *Nat Rev Neurosci* 16:317–331.
43. Yang RJ, Muzhik K, Karlsson RM, Cameron HA, Williams RW, Holmes A (2008): Variation in mouse basolateral amygdala volume is associated with differences in stress reactivity and fear learning. *Neuropsychopharmacology* 33:2595–2604.
44. Reznikov R, Binko M, Nobrega JN, Hamani C (2016): Deep brain stimulation in animal models of fear, anxiety, and posttraumatic stress disorder. *Neuropsychopharmacology* 41:2810–2817.
45. Richter-Levin G, Stork O, Schmidt MV (2019): Animal models of PTSD: A challenge to be met. *Mol Psychiatry* 24:1135–1156.
46. Haukvik UK, Tamnes CK, Söderman E, Agartz I (2018): Neuroimaging hippocampal subfields in schizophrenia and bipolar disorder: A systematic review and meta-analysis. *J Psychiatr Res* 104:217–226.
47. Kirov II, Hardy CJ, Matsuda K, Messinger J, Cankurtaran CZ, Warren M, *et al.* (2013): In vivo 7 Tesla imaging of the dentate granule cell layer in schizophrenia. *Schizophr Res* 147:362–367.
48. Ding SL, Van Hoesen GW (2015): Organization and detailed parcellation of human hippocampal head and body regions based on a combined analysis of cyto- and chemoarchitecture. *J Comp Neurol* 523:2233–2253.
49. Genou S, Bernhardt BC, La Joie R, Amunts K, Eickhoff SB (2021): The many dimensions of human hippocampal organization and (dys) function. *Trends Neurosci* 44:977–989.
50. Button KS, Ioannidis JP, Mokrysz C, Nosek BA, Flint J, Robinson ES, Munafò MR (2013): Power failure: Why small sample size undermines the reliability of neuroscience. *Nat Rev Neurosci* 14:365–376.
51. Ben-Zion Z, Spiller TR, Keynan JN, Admon R, Levy I, Liberzon I, *et al.* (2023): Evaluating the evidence for brain-based biotypes of psychiatric vulnerability in the acute aftermath of trauma. *Am J Psychiatry* 180:146–154.
52. Esterman M, Stumps A, Jagger-Rickels A, Rothlein D, DeGutis J, Fortenbaugh F, *et al.* (2020): Evaluating the evidence for a neuroimaging subtype of posttraumatic stress disorder. *Sci Transl Med* 12:9343.
53. Yushkevich PA, Wang H, Pluta J, Das SR, Craige C, Avants BB, *et al.* (2010): Nearly automatic segmentation of hippocampal subfields in in vivo focal T2-weighted MRI. *Neuroimage* 53:1208–1224.
54. Yushkevich PA, Amaral RS, Augustinack JC, Bender AR, Bernstein JD, Boccardi M, *et al.* (2015): Quantitative comparison of 21 protocols for labeling hippocampal subfields and parahippocampal subregions in in vivo MRI: Towards a harmonized segmentation protocol. *Neuroimage* 111:526–541.
55. Fischl B (2012). *FreeSurfer*. *Neuroimage* 62:774–781.
56. Lim HK, Hong SC, Jung WS, Ahn KJ, Won WY, Hahn C, *et al.* (2013): Automated segmentation of hippocampal subfields in drug-naïve patients with Alzheimer disease. *AJNR Am J Neuroradiol* 34:747–751.
57. Schoene-Bake JC, Keller SS, Niehusmann P, Volmering E, Elger C, Deppe M, Weber B (2014): In vivo mapping of hippocampal subfields in mesial temporal lobe epilepsy: Relation to histopathology. *Hum Brain Mapp* 35:4718–4728.
58. Quattrini G, Pievani M, Jovicich J, Aiello M, Bargalló N, Barkhof F, *et al.* (2020): Amygdalar nuclei and hippocampal subfields on MRI: Test-retest reliability of automated volumetry across different MRI sites and vendors. *Neuroimage* 218:116932.
59. Tricco AC, Lillie E, Zarin W, O'Brien KK, Colquhoun H, Levac D, *et al.* (2018): PRISMA extension for scoping reviews (PRISMA-ScR): Checklist and explanation. *Ann Intern Med* 169:467–473.
60. Munn Z, Peters MDJ, Stern C, Tufanaru C, McArthur A, Aromataris E (2018): Systematic review or scoping review? Guidance for authors when choosing between a systematic or scoping review approach. *BMC Med Res Methodol* 18:143.
61. Peters MD, Godfrey CM, McInerney P, Soares CB, Khalil H, Parker D (2015): The Joanna Briggs Institute Reviewers' Manual 2015: Methodology for JBI Scoping Reviews. Adelaide, Australia: The Joanna Briggs Institute.
62. Peters MDJ, Godfrey C, McInerney P, Munn Z, Tricco AC, Khalil H (2020): Chapter 11: Scoping reviews. In: Aromataris E, Munn Z, editors. *JBI Manual for Evidence Synthesis*. JBI. Available at: <https://synthesismanual.jbi.global>. Accessed August 22, 2023.
63. Grosseletta Nardini HK, Wang L (2018): The Yale MeSH Analyzer, New Haven, CT: Cushing/Whitney Medical Library. Available at: <https://library.medicine.yale.edu/news/yale-mesh-analyzer>. Accessed August 22, 2023.
64. Gotschall T (2021): EndNote 20 desktop version. *J Med Libr Assoc* 109:520–522.
65. Bramer WM, Giustini D, de Jonge GB, Holland L, Bekhuis T (2016): De-duplication of database search results for systematic reviews in EndNote. *J Med Libr Assoc* 104:240–243.

66. VH (2017): Innovation, Covidence Systematic Review Software Melbourne, Australia.
67. Ahmed-Leitao F, Rosenstein D, Marx M, Young S, Korte K, Seedat S (2019): Posttraumatic stress disorder, social anxiety disorder and childhood trauma: Differences in hippocampal subfield volume. *Psychiatry Res Neuroimaging* 284:45–52.
68. Averill CL, Satodiya RM, Scott JC, Wrocklage KM, Schweinsburg B, Averill LA, *et al.* (2017): Posttraumatic stress disorder and depression symptom severities are differentially associated with hippocampal subfield volume loss in combat veterans. *Chronic Stress (Thousand Oaks)* 1:2470547017744538.
69. Bonne O, Vythilingam M, Inagaki M, Wood S, Neumeister A, Nugent AC, *et al.* (2008): Reduced posterior hippocampal volume in posttraumatic stress disorder. *J Clin Psychiatry* 69:1087–1091.
70. Chalavi S, Vissia EM, Giesen ME, Nijenhuis ER, Draijer N, Cole JH, *et al.* (2015): Abnormal hippocampal morphology in dissociative identity disorder and post-traumatic stress disorder correlates with childhood trauma and dissociative symptoms. *Hum Brain Mapp* 36:1692–1704.
71. Chen LW, Sun D, Davis SL, Haswell CC, Dennis EL, Swanson CA, *et al.* (2018): Smaller hippocampal CA1 subfield volume in post-traumatic stress disorder. *Depress Anxiety* 35:1018–1029.
72. Hayes JP, Hayes S, Miller DR, Lafleche G, Logue MW, Verfaellie M (2017): Automated measurement of hippocampal subfields in PTSD: Evidence for smaller dentate gyrus volume. *J Psychiatr Res* 95:247–252.
73. Koch SBJ, van Ast VA, Kaldewaj R, Hashemi MM, Zhang W, Klumpers F, Roelofs K (2021): Larger dentate gyrus volume as predisposing resilience factor for the development of trauma-related symptoms. *Neuropsychopharmacology* 46:1283–1292.
74. Luo Y, Liu Y, Qin Y, Zhang X, Ma T, Wu W, *et al.* (2017): The atrophy and laterality of the hippocampal subfields in parents with or without posttraumatic stress disorder who lost their only child in China. *Neurol Sci* 38:1241–1247.
75. Luo Y, Liu Y, Qing Z, Zhang L, Weng Y, Zhang X, *et al.* (2021): Sex differences in re-experiencing symptoms between husbands and wives who lost their only child in China: A resting-state functional connectivity study of hippocampal subfields. *Front Hum Neurosci* 15: 655044.
76. Misaki M, Mulyana B, Zotev V, Wurfel BE, Krueger F, Feldner M, Bodurka J (2021): Hippocampal volume recovery with real-time functional MRI amygdala neurofeedback emotional training for posttraumatic stress disorder. *J Affect Disord* 283:229–235.
77. Morey RA, Garrett ME, Stevens JS, Clarke EK, Haswell CC, van Rooij SJH, *et al.* (2020): Genetic predictors of hippocampal subfield volume in PTSD cases and trauma-exposed controls. *Eur J Psychotraumatol* 11:1785994.
78. Suarez-Jimenez B, Zhu X, Lazarov A, Mann JJ, Schneier F, Gerber A, *et al.* (2020): Anterior hippocampal volume predicts affect-focused psychotherapy outcome. *Psychol Med* 50:396–402.
79. Szeszko PR, Bierer LM, Bader HN, Chu KW, Tang CY, Murphy KM, *et al.* (2022): Cingulate and hippocampal subregion abnormalities in combat-exposed veterans with PTSD. *J Affect Disord* 311:432–439.
80. Wang Z, Neylan TC, Mueller SG, Lenoci M, Truran D, Marmar CR, *et al.* (2010): Magnetic resonance imaging of hippocampal subfields in posttraumatic stress disorder. *Arch Gen Psychiatry* 67:296–303.
81. Weis CN, Webb EK, Huggins AA, Kallenbach M, Miskovich TA, Fitzgerald JM, *et al.* (2021): Stability of hippocampal subfield volumes after trauma and relationship to development of PTSD symptoms. *Neuroimage* 236:118076.
82. Yuan G, Shi W, Lowe S, Chang K, Jackson T, Hall BJ (2021): Associations between posttraumatic stress symptoms, perceived social support and psychological distress among disaster-exposed Chinese young adults: A three-wave longitudinal mediation model. *J Psychiatr Res* 137:491–497.
83. Zhang L, Lu L, Bu X, Li H, Tang S, Gao Y, *et al.* (2021): Alterations in hippocampal subfield and amygdala subregion volumes in post-traumatic subjects with and without posttraumatic stress disorder. *Hum Brain Mapp* 42:2147–2158.
84. Morey RA, Clarke EK, Haswell CC, Phillips RD, Clausen AN, Mufford MS, *et al.* (2020): Amygdala nuclei volume and shape in military veterans with posttraumatic stress disorder. *Biol Psychiatry Cogn Neurosci Neuroimaging* 5:281–290.
85. Ousdal OT, Milde AM, Hafstad GS, Hodneland E, Dyb G, Craven AR, *et al.* (2020): The association of PTSD symptom severity with amygdala nuclei volumes in traumatized youths. *Transl Psychiatry* 10:288.
86. Chen AC, Etkin A (2013): Hippocampal network connectivity and activation differentiates post-traumatic stress disorder from generalized anxiety disorder. *Neuropsychopharmacology* 38:1889–1898.
87. Zarei M, Beckmann CF, Binnewijzend MA, Schoonheim MM, Oghabian MA, Sanz-Arigita EJ, *et al.* (2013): Functional segmentation of the hippocampus in the healthy human brain and in Alzheimer's disease. *Neuroimage* 66:28–35.
88. Postel C, Mary A, Dayan J, Fraise F, Vallée T, Guillery-Girard B, *et al.* (2021): Variations in response to trauma and hippocampal subfield changes. *Neurobiol Stress* 15:100346.
89. Knierim JJ, Neunuebel JP (2016): Tracking the flow of hippocampal computation: Pattern separation, pattern completion, and attractor dynamics. *Neurobiol Learn Mem* 129:38–49.
90. Kheirbek MA, Klemenhagen KC, Sahay A, Hen R (2012): Neurogenesis and generalization: A new approach to stratify and treat anxiety disorders. *Nat Neurosci* 15:1613–1620.
91. Leal SL, Yassa MA (2018): Integrating new findings and examining clinical applications of pattern separation. *Nat Neurosci* 21:163–173.
92. Akiki TJ, Averill CL, Wrocklage KM, Schweinsburg B, Scott JC, Martini B, *et al.* (2017): The association of PTSD symptom severity with localized hippocampus and amygdala abnormalities. *Chronic Stress (Thousand Oaks)* 1:2470547017724069.
93. Wisse LEM, Biessels GJ, Geerlings MI (2014): A critical appraisal of the hippocampal subfield segmentation package in FreeSurfer. *Front Aging Neurosci* 6:261.
94. de Flores R, La Joie R, Chételat G (2015): Structural imaging of hippocampal subfields in healthy aging and Alzheimer's disease. *Neuroscience* 309:29–50.
95. Schlichting ML, Mack ML, Guarino KF, Preston AR (2019): Performance of semi-automated hippocampal subfield segmentation methods across ages in a pediatric sample. *Neuroimage* 191:49–67.
96. Hedges DW, Woon FL (2010): Alcohol use and hippocampal volume deficits in adults with posttraumatic stress disorder: A meta-analysis. *Biol Psychol* 84:163–168.
97. Lee J, Im SJ, Lee SG, Stadlin A, Son JW, Shin CJ, *et al.* (2016): Volume of hippocampal subfields in patients with alcohol dependence. *Psychiatry Res Neuroimaging* 258:16–22.
98. Beale C, Broyd SJ, Chye Y, Suo C, Schira M, Galetti P, *et al.* (2018): Prolonged cannabidiol treatment effects on hippocampal subfield volumes in current cannabis users. *Cannabis Cannabinoid Res* 3:94–107.
99. Beresford TP, Arciniegas DB, Alfors J, Clapp L, Martin B, Beresford HF, *et al.* (2006): Hypercortisolism in alcohol dependence and its relation to hippocampal volume loss. *J Stud Alcohol* 67:861–867.
100. Beresford TP, Arciniegas DB, Alfors J, Clapp L, Martin B, Du Y, *et al.* (2006): Hippocampus volume loss due to chronic heavy drinking. *Alcohol Clin Exp Res* 30:1866–1870.
101. Wilhelm J, Frieling H, Hillemecher T, Degner D, Kornhuber J, Bleich S (2008): Hippocampal volume loss in patients with alcoholism is influenced by the consumed type of alcoholic beverage. *Alcohol* 43:296–299.
102. Lorenzetti V, Solowij N, Yücel M (2016): The role of cannabinoids in neuroanatomic alterations in cannabis users. *Biol Psychiatry* 79: e17–e31.
103. Battistella G, Fornari E, Annoni JM, Chtioui H, Dao K, Fabritius M, *et al.* (2014): Long-term effects of cannabis on brain structure. *Neuropsychopharmacology* 39:2041–2048.
104. Boldrini M, Hen R, Underwood MD, Rosoklija GB, Dwork AJ, Mann JJ, Arango V (2012): Hippocampal angiogenesis and progenitor cell proliferation are increased with antidepressant use in major depression. *Biol Psychiatry* 72:562–571.

Hippocampus and Amygdala Subregions in PTSD

105. Balu DT, Lucki I (2009): Adult hippocampal neurogenesis: Regulation, functional implications, and contribution to disease pathology. *Neurosci Biobehav Rev* 33:232–252.
106. Scherk H, Falkai P (2006): Effects of antipsychotics on brain structure. *Curr Opin Psychiatry* 19:145–150.
107. Usher J, Leucht S, Falkai P, Scherk H (2010): Correlation between amygdala volume and age in bipolar disorder — A systematic review and meta-analysis of structural MRI studies. *Psychiatry Res* 182:1–8.
108. Danese A, McEwen BS (2012): Adverse childhood experiences, allostasis, allostatic load, and age-related disease. *Physiol Behav* 106:29–39.
109. Tottenham N, Sheridan MA (2009): A review of adversity, the amygdala and the hippocampus: A consideration of developmental timing. *Front Hum Neurosci* 3:68.
110. Sapolsky RM (2000): Glucocorticoids and hippocampal atrophy in neuropsychiatric disorders. *Arch Gen Psychiatry* 57:925–935.
111. Teicher MH, Samson JA (2013): Childhood maltreatment and psychopathology: A case for ecophenotypic variants as clinically and neurobiologically distinct subtypes. *Am J Psychiatry* 170:1114–1133.
112. Teicher MH, Andersen SL, Polcari A, Anderson CM, Navalta CP, Kim DM (2003): The neurobiological consequences of early stress and childhood maltreatment. *Neurosci Biobehav Rev* 27:33–44.
113. Anda RF, Felitti VJ, Bremner JD, Walker JD, Whitfield C, Perry BD, *et al.* (2006): The enduring effects of abuse and related adverse experiences in childhood. A convergence of evidence from neurobiology and epidemiology. *Eur Arch Psychiatry Clin Neurosci* 256:174–186.
114. Roeder SS, Burkardt P, Rost F, Rode J, Bruschi L, Coras R, *et al.* (2022): Evidence for postnatal neurogenesis in the human amygdala. *Commun Biol* 5:366.
115. Admon R, Milad MR, Hendler T (2013): A causal model of post-traumatic stress disorder: Disentangling predisposed from acquired neural abnormalities. *Trends Cogn Sci* 17:337–347.
116. Ben-Zion Z, Artzi M, Nir D, Keynan NJ, Zeevi Y, Admon R, *et al.* (2020): Neuroanatomical risk factors for posttraumatic stress disorder in recent trauma survivors. *Biol Psychiatry Cogn Neurosci Neuroimaging* 5:311–319.
117. Ben-Zion Z, Fine NB, Keynan NJ, Admon R, Halpern P, Liberzon I, *et al.* (2019): Neurobehavioral moderators of post-traumatic stress disorder (PTSD) trajectories: Study protocol of a prospective MRI study of recent trauma survivors. *Eur J Psychotraumatol* 10:1683941.
118. Wisse LEM, Chételat G, Daugherty AM, de Flores R, la Joie R, Mueller SG, *et al.* (2021): Hippocampal subfield volumetry from structural isotropic 1 mm³ MRI scans: A note of caution. *Hum Brain Mapp* 42:539–550.
119. Stark EA, Parsons CE, Van Hartevelt TJ, Charquero-Ballester M, McManners H, Ehlers A, *et al.* (2015): Post-traumatic stress influences the brain even in the absence of symptoms: A systematic, quantitative meta-analysis of neuroimaging studies. *Neurosci Biobehav Rev* 56:207–221.
120. Taylor PA, Reynolds RC, Calhoun V, Gonzalez-Castillo J, Handwerker DA, Bandettini PA, *et al.* (2023): Highlight results, don't hide them: Enhance interpretation, reduce biases and improve reproducibility. *Neuroimage* 274:120138.
121. Gonçalves JT, Schafer ST, Gage FH (2016): Adult neurogenesis in the hippocampus: From stem cells to behavior. *Cell* 167:897–914.
122. Ihunwo AO, Tembo LH, Dzamalala C (2016): The dynamics of adult neurogenesis in human hippocampus. *Neural Regen Res* 11:1869–1883.
123. Insel T, Cuthbert B, Garvey M, Heinssen R, Pine DS, Quinn K, *et al.* (2010): Research Domain Criteria (RDoC): Toward a new classification framework for research on mental disorders. *Am J Psychiatry* 167:748–751.
124. Sambuco N, Bradley MM, Lang PJ (2023): Hippocampal and amygdala volumes vary with transdiagnostic psychopathological dimensions of distress, anxious arousal, and trauma. *Biol Psychol* 177:108501.
125. Chambers CD, Tzavella L (2022): The past, present and future of Registered Reports. *Nat Hum Behav* 6:29–42.
126. Spiller TR, Olf M (2018): Reducing uncertainty in research: Introducing registered reports. *Eur J Psychotraumatol* 9:1554417.
127. Nichols TE, Das S, Eickhoff SB, Evans AC, Glatard T, Hanke M, *et al.* (2017): Best practices in data analysis and sharing in neuroimaging using MRI. *Nat Neurosci* 20:299–303.
128. Chaposhloo M, Nicholson AA, Becker S, McKinnon MC, Lanius R, Shaw SB, Alzheimer's Disease Neuroimaging Initiative (2023): Altered Resting-State functional connectivity in the anterior and posterior hippocampus in Post-traumatic stress disorder: The central role of the anterior hippocampus. *Neuroimage Clin* 38:103417.
129. Malivoire BL, Girard TA, Patel R, Monson CM (2018): Functional connectivity of hippocampal subregions in PTSD: Relations with symptoms. *BMC Psychiatry* 18:129.
130. Leite L, Esper NB, Junior JRML, Lara DR, Buchweitz A (2022): An exploratory study of resting-state functional connectivity of amygdala subregions in posttraumatic stress disorder following trauma in adulthood. *Sci Rep* 12:9558.
131. Yuan M, Pantazatos SP, Zhu H, Li Y, Miller JM, Rubin-Falcone H, *et al.* (2019): Altered amygdala subregion-related circuits in treatment-naïve post-traumatic stress disorder comorbid with major depressive disorder. *Eur Neuropsychopharmacol* 29:1092–1101.
132. Manthey A, Sierk A, Brakemeier EL, Walter H, Daniels JK (2021): Does trauma-focused psychotherapy change the brain? A systematic review of neural correlates of therapeutic gains in PTSD. *Eur J Psychotraumatol* 12:1929025.
133. Thomaes K, Dorepaal E, Draijer N, Jansma EP, Veltman DJ, van Balkom AJ (2014): Can pharmacological and psychological treatment change brain structure and function in PTSD? A systematic review. *J Psychiatr Res* 50:1–15.
134. Sottile RJ, Vida T (2022): A proposed mechanism for the MDMA-mediated extinction of traumatic memories in PTSD patients treated with MDMA-assisted therapy. *Front Psychiatry* 13:991753.
135. Thompson PM, Hayashi KM, Sowell ER, Gogtay N, Giedd JN, Rapoport JL, *et al.* (2004): Mapping cortical change in Alzheimer's disease, brain development, and schizophrenia. *Neuroimage* 23(suppl 1):S2–S18.
136. Gutman B, Wang Y, Morra J, Toga AW, Thompson PM (2009): Disease classification with hippocampal shape invariants. *Hippocampus* 19:572–578.
137. Yushkevich PA, Pluta JB, Wang H, Xie L, Ding SL, Gertje EC, *et al.* (2015): Automated volumetry and regional thickness analysis of hippocampal subfields and medial temporal cortical structures in mild cognitive impairment. *Hum Brain Mapp* 36:258–287.
138. Mueller SG, Stables L, Du AT, Schuff N, Truran D, Cashdollar N, Weiner MW (2007): Measurement of hippocampal subfields and age-related changes with high resolution MRI at 4T. *Neurobiol Aging* 28:719–726.
139. Rothbaum BO, Kearns MC, Reiser E, Davis JS, Kerley KA, Rothbaum AO, *et al.* (2014): Early intervention following trauma may mitigate genetic risk for PTSD in civilians: A pilot prospective emergency department study. *J Clin Psychiatry* 75:1380–1387.
140. Roshchupkin GV, Gutman BA, Vernooij MW, Jahanshad N, Martin NG, Hofman A, *et al.* (2016): Heritability of the shape of subcortical brain structures in the general population. *Nat Commun* 7:13738.
141. Sheehan DV, Lecrubier Y, Sheehan KH, Amorim P, Janavs J, Weiller E, *et al.* (1998): The Mini-International Neuropsychiatric Interview (M.I.N.I.): The development and validation of a structured diagnostic psychiatric interview for DSM-IV and ICD-10. *J Clin Psychiatry* 59(suppl 20):22–33; quiz 34–57.
142. Blanchard EB, Jones-Alexander J, Buckley TC, Forneris CA (1996): Psychometric properties of the PTSD checklist (PCL). *Behav Res Ther* 34:669–673.
143. Dyb G, Jensen TK, Nygaard E, Ekeberg O, Diseth TH, Wentzel-Larsen T, Thoresen S (2014): Post-traumatic stress reactions in survivors of the 2011 massacre on Utøya Island, Norway. *Br J Psychiatry* 204:361–367.