



See Article page 10.

Commentary: Antegrade cerebral perfusion using a “new” cannula: Keep it simple!

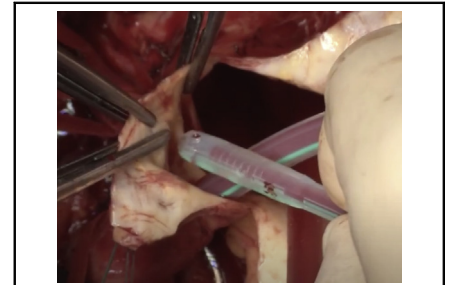
Giacomo Murana, MD, PhD, Alessandro Leone, MD, and Davide Pacini, MD, PhD

The concept of using a cannula to perform a selective cerebral perfusion started together with the Kazui procedure itself. In 1986, he described the well-known technique reporting a direct, bilateral oxygenated blood delivery just inserting a small balloon cannula inside the left common carotid artery after opening of the transverse arch.^{1,2} With the classical technique of cannulating the innominate artery, full flow is maintained until the core temperature is reached. Then, the origin of the innominate artery is crossclamped and only the flow to the cerebrum is maintained at 10 to 15 mL/min and the arch opened.^{2,3} There is therefore absolutely no interruption in the cerebral perfusion.

In the following 3 decades, no other substantial modifications to the techniques have been adopted and the most preferred cannula used to protect the brain is now a specially designed soft silicon catheter with an inflatable balloon on the tip to close the vessel. It has the unique features to be pliable, occlusive, and fast to insert.

In this issue of the *JTCVS Techniques*,⁴ in the article “A New Cannula for Antegrade Selective Cerebral Perfusion,” the authors introduce a new technique of cannulation of the supra-aortic arteries using a standard guidewire technique. They modified a well-known cannula (True Flow RDB; European Medical Supplies, S.r.l, Bologna, Italy) with the possibility of a guidewire introduction using the Seldinger technique.

The major advantages of the AV Flow cannula are complete cerebral protection throughout the hypothermic



Introduction of a cannula in the left common carotid artery for cerebral perfusion.

CENTRAL MESSAGE

Standard cannulation of the supra-aortic vessels remains the easiest way to perform selective cerebral perfusion.

circulatory arrest time (can be inserted any time before the hypothermic circulatory arrest) and easier arch vessel reimplantation or hemiarch operations, as the cannula is out of the anastomotic site.

On the contrary, the proposed technique is open to many criticisms. Direct cannulation of the carotid artery was already described by Bachet and colleagues in 1991,⁵ in their “cold cerebropoplegia,” using a purse string and tourniquet on the carotid arteries; however, they abandoned this approach for being cumbersome. Most of the time epi-aortic vessels are very fragile, and a direct wall lesion could be very dangerous for soft plaque mobilization and increased risk of cerebral embolism. Therefore, this can be considered a limitation of the technique for different pathologies such as acute dissection, chronic dissection with involvement of the supra-aortic vessels, and shaggy aorta, reducing significantly the number of the ideal candidates. Moreover, the risk of arterial wall damage (or shrinkage of the lumen) after removing the cannula and direct purse string closure is another drawback of the new device. The adoption of a guidewire technique could not be very easy, especially in case of small epi-aortic vessels and in aortic dissections for the presence of a false lumen or the risk of progression downstream.

In conclusion, the described technique seems more complicated, time-consuming, and somewhat uncertain than the direct cannulation of the innominate artery with a large arterial cannula used for and during the whole surgical procedure (total cardiopulmonary bypass and selective antegrade perfusion during distal hypothermic circulatory arrest).

From the Cardiac Surgery Department, S. Orsola Hospital, University of Bologna, Bologna, Italy.

Disclosures: The authors reported no conflicts of interest.

The *Journal* policy requires editors and reviewers to disclose conflicts of interest and to decline handling or reviewing manuscripts for which they may have a conflict of interest. The editors and reviewers of this article have no conflicts of interest.

Received for publication Sept 9, 2020; revisions received Sept 9, 2020; accepted for publication Sept 24, 2020; available ahead of print Sept 28, 2020.

Address for reprints: Davide Pacini, MD, PhD, Cardiac Surgery Department, S. Orsola Hospital, University of Bologna, Via Massarenti 9, 40138, Bologna, Italy (E-mail: davide.pacini@unibo.it or davide.pacini@aosp.bo.it).

JTCVS Techniques 2020;4:14-15

2666-2507

Copyright © 2020 The Authors. Published by Elsevier Inc. on behalf of The American Association for Thoracic Surgery. This is an open access article under the CC BY-NC-ND license (<http://creativecommons.org/licenses/by-nc-nd/4.0/>).

<https://doi.org/10.1016/j.jtc.2020.09.035>

Of course, this technique doesn't have the ambition to substitute the currently established techniques, and very strict patient selection is mandatory using such a percutaneous approach. The authors reported many of these limitations and should be encouraged in the way they just wanted to bring attention to a new device that may represent an additional tool in aortic arch surgery. Indeed, it is somewhat difficult to understand why a rather complex system of cannulation and cerebral perfusion is necessary. Never forget the basic concept to "keep things simple," especially in tough situations like in open arch procedures.

References

1. Kazui T, Inoue N, Komatsu S. Surgical treatment of aneurysms of the transverse aortic arch. *J Cardiovasc Surg (Torino)*. 1989;30:402-6.
2. Kazui T, Inoue N, Yamada O, Komatsu S. Selective cerebral perfusion during operation for aneurysms of the aortic arch: a reassessment. *Ann Thorac Surg*. 1992;53:109-14.
3. Pacini D, Murana G, Di Marco L, Berardi M, Mariani C, Coppola G, et al. Cerebral perfusion issues in type A aortic dissection. *J Vis Surg*. 2018;4:77.
4. Venturini A, Galligani A, Asta A, Cannarella AM, Zanchettin C, Zoffoli G, et al. A new cannula for antegrade selective cerebral perfusion. *J Thorac Cardiovasc Surg Tech*. 2020;4:10-3.
5. Bachet J, Guilmet D, Goudot B, Termignon JL, Teodori G, Dreyfus G, et al. Cold cerebroplegia. A new technique of cerebral protection during operations on the transverse aortic arch. *J Thorac Cardiovasc Surg*. 1991;102:85-94.