

Anti-tumour Treatment



Tucatinib's journey from clinical development to clinical practice: New horizons for HER2-positive metastatic disease and promising prospects for brain metastatic spread

Carmen Criscitiello^{a,b,*}, Chiara Corti^{a,b,1}, Michelino De Laurentiis^c, Giampaolo Bianchini^{d,e}, Barbara Pistilli^f, Saverio Cinieri^g, Lucio Castellan^h, Grazia Arpinoⁱ, Pierfranco Conte^{j,k}, Francesco Di Meco^l, Alessandra Gennari^{m,n}, Valentina Guarneri^{j,k}, Luca Visani^{o,p}, Lorenzo Livi^{o,p}, Paolo Marchetti^q, Fabio Puglisi^{r,s}, Giuseppe Viale^{b,t}, Lucia Del Mastro^{u,v}, Sabino De Placidoⁿ, Giuseppe Curigliano^{a,b}

^a Division of New Drugs and Early Drug Development for Innovative Therapies, European Institute of Oncology, IRCCS, Milan, Italy

^b Department of Oncology and Hematology-Oncology (DIPO), University of Milan, Milan, Italy

^c Department of Breast and Thoracic Oncology, Istituto Nazionale Tumori IRCCS 'Fondazione Pascale', Napoli, Italy

^d Department of Medical Oncology, Ospedale San Raffaele, IRCCS, Milan, Italy

^e Vita-Salute San Raffaele University, Milan, Italy

^f Department of Cancer Medicine, Gustave Roussy, Villejuif, France

^g Medical Oncology Unit, Ospedale di Summa A. Perrino, Brindisi, Italy

^h Department of Diagnostic and Interventional Neuroradiology, IRCCS Ospedale Policlinico San Martino, Genoa, Italy

ⁱ Department of Clinical Medicine and Surgery, University of Naples Federico II, Naples, Italy

^j Department of Surgery, Oncology and Gastroenterology (DISCOG), University of Padova, Padova, Italy

^k Medical Oncology 2, Istituto Oncologico Veneto, IRCCS, Padova, Italy

^l Istituto Nazionale Neurologico Carlo Besta, Milan, Italy

^m Medical Oncology, "Maggiore della Carità" University Hospital, Novara, Italy

ⁿ Department of Translational Medicine (DIMET), University of Eastern Piedmont (UPO), Novara, Italy

^o Department of Experimental and Clinical Biomedical Sciences Mario Serio, University of Florence, Florence, Italy

^p Radiation Oncology Unit, Oncology Department, Azienda Ospedaliero Universitaria Careggi, Florence, Italy

^q Department of Clinical and Molecular Medicine, Sapienza University of Rome, Rome, Italy

^r Department of Medical Oncology, National Cancer Institute, IRCCS, Aviano, Italy

^s Department of Medicine, University of Udine, Udine, Italy

^t Division of Pathology, IEO, European Institute of Oncology IRCCS, Milan, Italy

^u Department of Medical Oncology, Breast Unit, IRCCS Ospedale Policlinico San Martino, Genoa, Italy

^v Department of Internal Medicine and Medical Specialties (DIMI), School of Medicine, University of Genoa, Genoa, Italy

ARTICLE INFO

Keywords:

Breast cancer
Tucatinib
Innovation
Drug development
HER2
TKI
Brain metastasis

ABSTRACT

Approximately 20% of breast cancers (BCs) overexpress human epidermal growth factor receptor 2 (HER2), a transmembrane glycoprotein with tyrosine kinase activity, encoded by *ERBB2* gene. Historically, HER2 overexpression has been linked with increased disease recurrence and a worse prognosis. However, the increasing availability of different anti-HER2 compounds and combinations is progressively improving HER2-positive BC outcome, thus requiring expertise to prioritize both overall survival (OS) prolongation and quality of life, without neglecting the accessibility to further treatment lines with a low attrition rate. In this context, tucatinib, an oral tyrosine kinase inhibitor, has recently been granted approval by regulatory agencies based on evidence from the HER2CLIMB, a clinical trial which randomized patients with metastatic BC to receive trastuzumab and capecitabine with either tucatinib or placebo. A distinctive feature of this study was the inclusion of patients with new or active brain metastases (BMs) at study entry, a population traditionally excluded from clinical trials. Thus,

* Corresponding author at: Division of Early Drug Development for Innovative Therapy, European Institute of Oncology, IRCCS, via Ripamonti 435, 20141 Milan, Italy.

E-mail address: carmen.criscitiello@ieo.it (C. Criscitiello).

¹ Co-first author.

HER2CLIMB provides the first solid evidence of an OS benefit in patients with BC and BMs, addressing a long standing unmet medical need, especially given the high incidence of central nervous system metastatic spread in patients with HER2-positive disease.

This review provides an overview of the molecular and clinical landscape of tucatinib for the treatment of advanced BC. It focuses on the technological journey that drove the development of this therapeutic innovation, from preclinical data to clinical practice.

Introduction

Metastatic breast cancer (BC) is the second most common cancer after lung cancer, associated with the development of brain metastases (BMs) [1]. As cancer research breakthroughs considerably improved survival of patients with advanced BC in the last decades, the incidence of BMs has also increased accordingly (Fig. 1) [2]. Hence, new treatment options and therapeutic strategies are needed to ensure a survival advantage for patients with BMs. However, data about the efficacy of anti-cancer agents on BMs are limited. This is primarily due to the scarcity of human tissue samples from BMs for translational research purposes [1]. Consequently, acquiring comprehensive information on the ability of anti-cancer agents to penetrate the central nervous system (CNS) is challenging [1].

In April 2020, the Food and Drug Administration (FDA) approved the anti-human epidermal growth factor receptor 2 (HER2) tyrosine kinase inhibitor (TKI) tucatinib (Tukysa) in combination with trastuzumab and capecitabine for the treatment of adult patients with advanced unresectable or metastatic HER2-positive BC, including patients with BMs, who have received one or more prior anti-HER2-based regimens in the metastatic setting [3]. In December of the same year, the European Medicines Agency's (EMA) Committee for Medicinal Products for Human Use (CHMP) issued a positive opinion, recommending the granting of a marketing authorization for Tukysa in combination with trastuzumab and capecitabine, in patients who have received at least 2 prior anti-HER2 regimens [4,5]. The regulatory recommendations are based on data from the HER2CLIMB trial, which

randomized patients with metastatic BC to receive trastuzumab and capecitabine with either tucatinib or placebo. Tucatinib showed efficacy compared with placebo in terms of both progression-free survival (PFS) and overall survival (OS) [6].

Among the 612 patients originally enrolled in the HER2CLIMB trial, 291 had BMs at baseline [6]. Notably, a distinctive feature of the trial was that 60% of these participants had new or active BMs at study entry, defined as either new lesions or untreated lesions at baseline, or previously treated but progressing lesions (Fig. 1) [6]. Since these patients have hardly ever been included in clinical trials, HER2CLIMB represents the first study displaying an OS benefit in patients with BC and active BMs [5]. Because at least half of patients with HER2-positive metastatic BC develop BMs over the course of their disease, the OS benefit observed meets a critical medical need [5].

This review provides an overview of the molecular and clinical landscape of tucatinib for the treatment of advanced BC. Special emphasis is put on the technological advancements that drove the development of this therapeutic innovation, encompassing the journey from preclinical data to clinical practice.

Role of HER2 as a predictive biomarker for treatment allocation in breast cancer

Approximately 20% of BCs overexpresses HER2, a transmembrane glycoprotein with tyrosine kinase activity, encoded by *ERBB2* gene [2]. Historically, the overexpression of this receptor has been linked with an increased risk of disease recurrence and an overall worse prognosis [2].

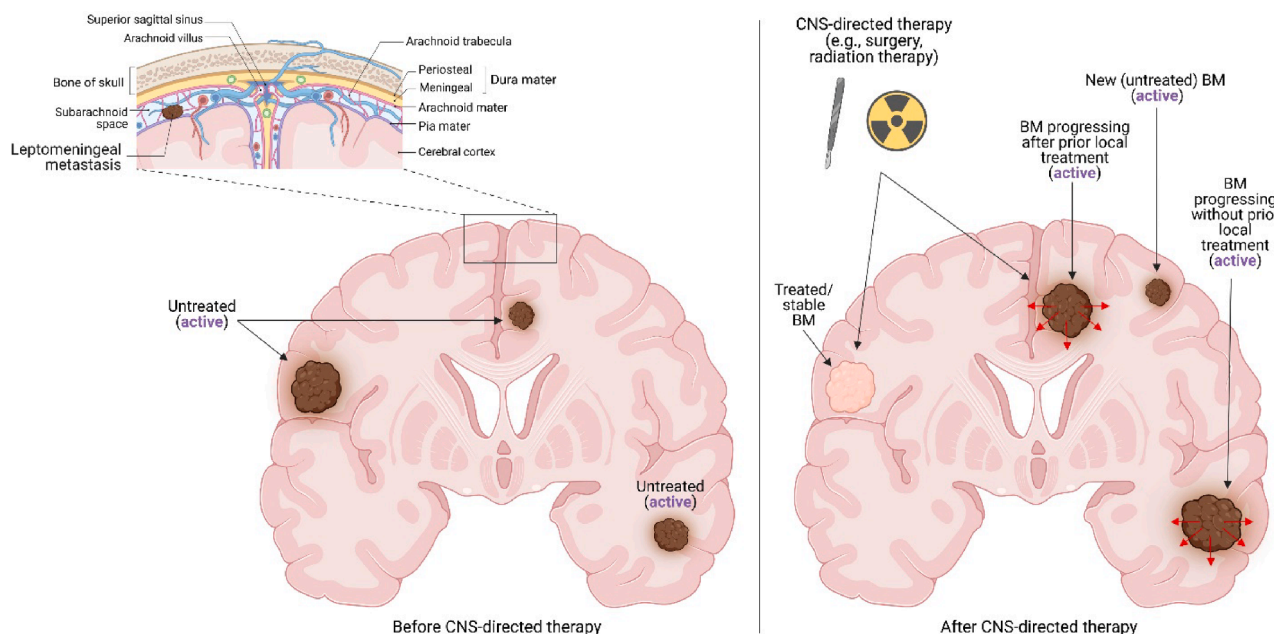


Fig. 1. Different types of CNS metastases. CNS metastases tend to show predilection for localizing at the white–gray matter junction due to the proximity of this region to the vascular border zones. In the context of treatment purposes, CNS metastases are classified into different categories. “Active” metastases, refer to either new (i.e., untreated) lesions or progressive metastases that have not been subjected to CNS-directed therapy since their documented progression. On the other hand, “stable” metastases are lesions that have received prior CNS-directed therapy, without further progression. Additionally, CNS metastases can also involve the leptomeningeal space. In such cases, leptomeningeal disease is confirmed with either positive cerebrospinal fluid cytology or with unequivocal radiologic or clinical evidence of leptomeningeal involvement. Abbreviations: BM, brain metastasis; CNS, central nervous system. Created with [biorender.com](https://www.biorender.com) (2023).

According to the 2018 American Society of Clinical Oncology (ASCO) and College of American Pathologist (CAP) HER2 testing guidelines, HER2-positive BC is defined by HER2 overexpression (score 3+) on an immunohistochemistry (IHC) assay and/or gene amplification on an *in situ* hybridization (ISH) assay [7]. Such a high level of HER2 overexpression is a strong predictive factor for sensitivity to HER2-targeted agents, and these criteria should be used to identify patients who are suitable candidates for treatment with these drugs. Conversely, a HER2 IHC score of 0, 1+ or 2+ and negative ISH results currently define a BC as HER2-negative, and, in such cases, anti-HER2 therapy is not recommended [2]. As a matter of fact, when HER2 inhibition with adjuvant trastuzumab was investigated in high-risk BC that was negative for HER2 by ISH and with IHC score of 1+ or 2+, it failed to provide any clinical benefit [8]. Furthermore, HER2 intra-tumor heterogeneity has been widely described in BCs, being a potentially adverse contributor to biomarker evaluation and treatments response [9–11]. According to the CAP, HER2 heterogeneity exists if HER2 is amplified in >5 % and <50 % of infiltrating tumor cells [12]. Regrettably, the actual incidence of HER2 spatial heterogeneity in BCs is still a subject of controversy among pathologists, with some authors arguing that it is an exceedingly rare event, and others suggesting that up to 40% of cases are HER2-heterogeneous (Fig. 2) [13–16]. Finally, recent advances in the development of antibody-drug conjugates (ADCs) further challenged the

notion of predictive biomarker [17,18]. In fact, while traditional targeted therapies (i.e., monoclonal antibodies or small molecules) typically interfere with a specific biological mechanism needed for tumor growth, the target antigen exploited by ADCs does not necessarily have to play a role as main oncogenic driver [18]. In such perspective, the ADC fam-trastuzumab deruxtecan-nxki (T-DXd) documented activity and efficacy even in BC harboring HER2 IHC score of 1+ or 2+ and ISH-negative, thus paving the way for a remodulation of HER2-related nomenclature [19]. Therefore, only a HER2 IHC score of 0, and/or negative ISH test would define a BC as HER2-negative, while cases with HER2 IHC score of 1+ or 2+ and ISH-negative would be referred to as “HER2-low” [19]. This emerging biomarker includes distinct subtypes, such as hormone receptor (HR)-positive BCs, as well as triple negative BCs (TNBCs) [19]. Although initial attempts to define clinicopathologic characteristics specific to HER2-low BC have led to differing results, after accounting for possible confounding factors, such as HR expression, there were not statistically significant differences between HER2-low and HER2 IHC score 0 tumors in recurrence-free survival (RFS), pathological complete response (pCR), OS, and PAM50 subtypes [20–24].

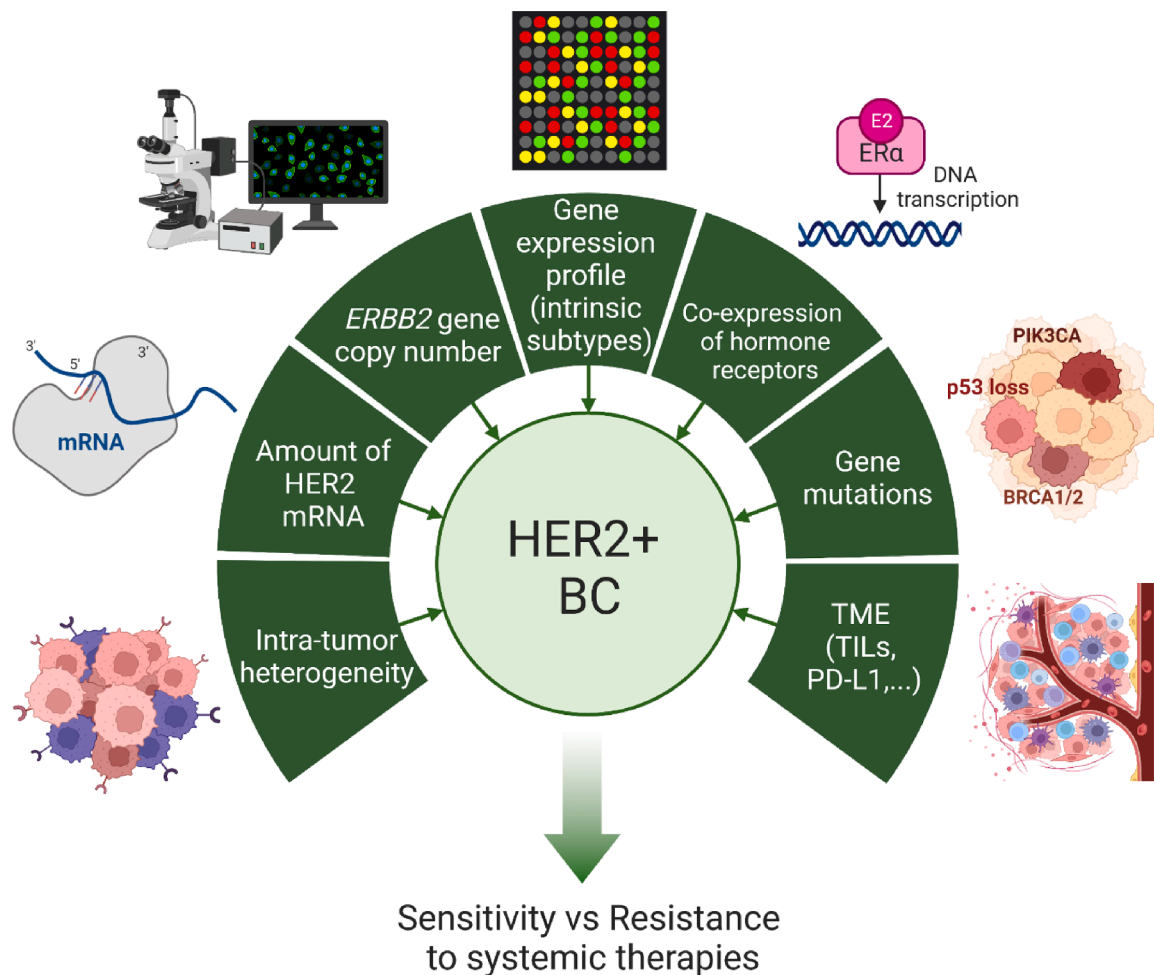


Fig. 2. HER2-positive breast cancer: a lot of different diseases. HER2-positive breast cancer can be defined as a composite group of diseases, that may differ based on intra-tumor heterogeneity, amount of HER2 mRNA, *ERBB2* gene copy number, gene expression profile, co-expression of hormone receptors, specific gene mutations and features of the tumor microenvironment. All these aspects may contribute to the determination of disease prognosis and either sensitivity or resistance to systemic therapies. Abbreviations: BC, breast cancer; BRCA, breast cancer gene; ER α , estrogen receptor alpha; HER2, human epidermal growth factor receptor 2; PD-L1, programmed death-ligand 1; PIK3CA, Phosphatidylinositol-4,5-Bisphosphate 3-Kinase Catalytic Subunit Alpha; mRNA, messenger RNA; TILs, tumor-infiltrating lymphocytes; TME, tumor microenvironment. Created with biorender.com (2023).

Clinical management of HER2-positive metastatic breast cancer

Although there is no unique strategy to treat patients with HER2-positive metastatic BC, patient selection and drug sequencing remain keys to management [2]. In fact, the increasing availability of different anti-HER2 compounds and combinations requires expertise to prioritize both OS prolongation and quality of life, without neglecting access to further treatment lines with a low attrition rate [2].

For previously untreated patients, combination treatment with trastuzumab, pertuzumab and a taxane (docetaxel or paclitaxel) remains standard of care, regardless of HR status (Fig. 3) [2,25]. Adding pertuzumab to docetaxel and trastuzumab increased median PFS by > 6

months (18.5 versus 12.4 months, with and without pertuzumab, respectively, HR 0.62, 95% CI, 0.51–0.75; $P < 0.001$) [25]. At a median follow-up of > 8 years, a 16.3-month improvement in median OS (HR 0.69; 95% CI 0.58–0.82 months) was observed [2]. For patients who progress on HER2-directed therapy, data from DESTINY-Breast-03 clinical trial indicate that T-DXd is associated with a significantly improved PFS (HR, 0.33; $P < 0.000001$), compared with the previous gold standard second-line therapy trastuzumab emtansine (T-DM1) [2,26]. The 12-month PFS rate was 75.8% with T-DXd versus 34.1% with T-DM1, and an OS benefit was also observed (HR 0.64; $P = 0.0037$) [26,27]. Drug-related interstitial lung disease (ILD) of any grade occurred in 15.2% of patients (0.8% grade 3), without fatal events

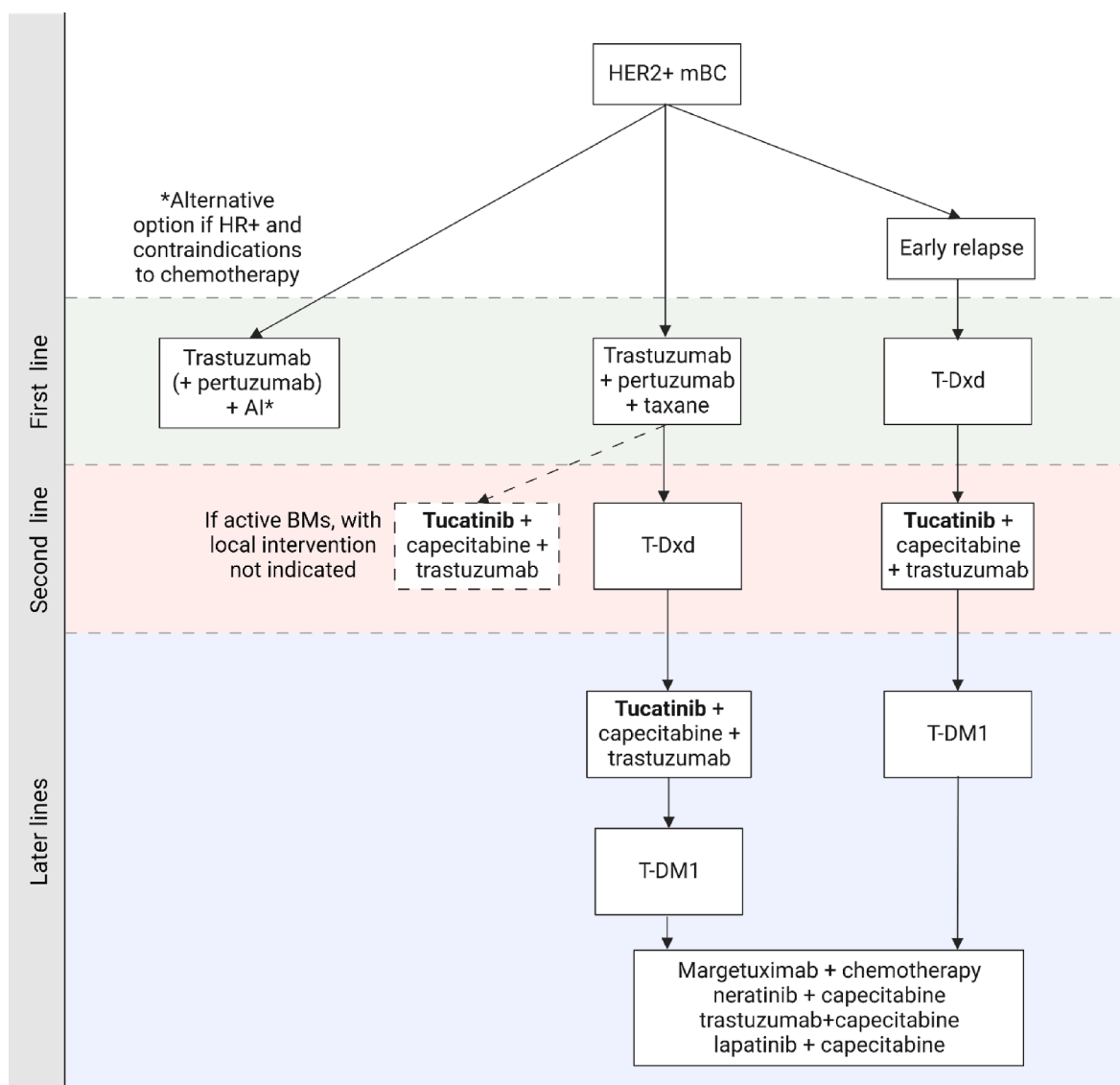


Fig. 3. Proposed algorithm for management of HER2-positive metastatic breast cancer. In third line setting, the combination of tucatinib, capecitabine and trastuzumab appears to be the most active treatment option, beside T-DXd and T-DM1. Specifically for patients with active BMs, considering tucatinib-containing combination treatment in second line setting is justified due to the demonstrated benefit in PFS and OS in this population, as shown in the randomized HER2-CLIMB clinical trial (see paragraph 4) [6]. As for T-DXd, data on intracranial activity are accumulating. The phase 3 Destiny-Breast03 clinical trial compared T-DM1 versus T-DXd in patients with HER2-positive metastatic BC who had experienced progression on a trastuzumab- and taxane-containing regimen [27]. Patients with CNS involvement were eligible if they had clinically stable, previously treated BMs. Among the 114 patients with stable BMs, the hazard ratio for disease progression or death was 0.38, favoring T-DXd (95% CI 0.23–0.64). Interestingly, in the phase 2 DEBBRAH trial, which included 13 patients with advanced HER2-positive BC and either asymptomatic untreated BMs or progressing BMs after local therapy, T-DXd was associated with an intracranial response rate of 46% [43]. Moreover, updated results of the same trial presented at the San Antonio Breast Cancer Symposium 2022 documented first preliminary hints of activity also in the small HER2-low population of patients with active BMs (N = 12, ORR-intracranial (IC) 6/12, 50%). Abbreviations: ADC, antibody-drug conjugate; AI, aromatase inhibitor; BC, breast cancer; BMs, brain metastases; CNS, central nervous system; HER2, human epidermal growth factor receptor; HR, hormone receptor; IC, intracranial; mBC, metastatic breast cancer; ORR, overall response rate; T-DM1, trastuzumab emtansine; T-DXd, trastuzumab deruxtecan. Created with biorender.com (2023).

[2,27]. On May 4th 2022, the FDA approved T-DXd for patients with HER2-positive unresectable or metastatic BC who have received a prior anti-HER2-based regimen either in the metastatic setting, or in the neoadjuvant or adjuvant setting and have developed disease recurrence during or within 6 months of completing therapy [28]. Similarly, on June 23rd 2022, the EMA extended marketing authorization for T-DXd to the second-line setting [29–31].

Henceforth, whilst the clinical scenario for the first and second treatment lines may be distinctly outlined, a consensus is yet to be reached in respect to further lines of therapy. This is due to the lack of current clinical data regarding therapies that can be used beyond progression on T-DXd [32]. Therefore, in such circumstances, decision-making should be guided by patient- and disease-related factors, including overall tolerability, clinical benefit of prior therapies, disease burden, and CNS involvement (*later discussed*).

Based on previous experience with trastuzumab, which has demonstrated clinical efficacy and prolonged survival in the second- and third-line settings by maintaining HER2 blockade beyond progression, it is advisable to maintain HER2-blockade after T-DXd failure [33–35]. Given the lack of comprehensive data on resistance mechanisms, it is advisable to conduct a tumor re-biopsy after T-DXd failure. This approach will facilitate treatment decision-making and enable optimal referral of patients to clinical trials that focus on addressing progression on ADC-based therapies [32,36]. Real-world data on the activity and effectiveness of these treatments following T-DXd failure could further assist in identifying the most effective compounds, as seen with T-DM1 in pertuzumab pre-treated patients [37].

That being said, the preferred treatment option following progression on T-DXd may be tucatinib-capecitabine-trastuzumab (Fig. 3) [6]. In this regard, the HER2CLIMB clinical trial, which included 480 heavily pretreated patients with HER2-positive BC (primary endpoint; total population, 612 patients), was conducted in patients who had previously received trastuzumab and T-DM1. The 1-year PFS rate was 33% among patients in the experimental arm, versus 12% among those receiving placebo-capecitabine-trastuzumab (HR 0.54, 95% CI 0.42–0.71), and the median duration of PFS was 7.8 and 5.6 months, respectively. OS at two years was 45% in the tucatinib-combination group and 27% in the placebo-combination group (HR 0.66, 95% CI 0.50–0.88). Nonetheless, the observed PFS and OS benefits in patients with either active or stable BMs (HRs, 0.32 and 0.58, respectively) warrant consideration of its second-line use for selected patients (Fig. 3, *later discussed*) [2]. T-DM1 may be offered upon progression on tucatinib-containing combination, as its FDA approval was based on the results of the phase 3 EMILIA trial. Although T-DM1 prolonged median OS (from 25.9 to 29.9 months; HR 0.75; 95% CI, 0.64–0.88) and median PFS, the ADC was compared to lapatinib-capecitabine in the pre-T-DXd era [30].

For later treatment lines, several options are available, although no direct evidence supports an optimal treatment sequence [2]. Margetuximab, an Fc-engineered antibody derivative of trastuzumab, was evaluated in the phase 3 SOPHIA trial, which randomised patients who had received ≥ 2 prior lines of anti-HER2 therapy to receive margetuximab plus chemotherapy versus trastuzumab plus chemotherapy. PFS was improved with margetuximab (5.8 versus 4.9 months; HR 0.76, 95% CI 0.59–0.98; $P = 0.03$), with no significant OS improvement [38]. Neratinib and lapatinib, both TKIs, have been investigated in combination with capecitabine and are suitable later-line options for patients who are still eligible for chemotherapy. Neratinib, an irreversible pan-HER TKI, has received FDA approval for its use in combination with capecitabine after two or more anti-HER2 regimens in the metastatic setting, based on data from the NALA clinical trial. In this phase 3 study, which involved 621 patients with advanced HER2-positive BC who had received at least two prior anti-HER2-based regimens in the metastatic setting, the combination of neratinib and capecitabine resulted in an improved median PFS of 8.8 months compared to 6.6 months for lapatinib plus capecitabine (HR 0.76, 95% CI 0.63–0.93). However, there

was no significant difference in median OS (24 versus 22 months; HR 0.88, 95% CI 0.72–1.07), and substantial toxicity was observed [39]. Indeed, diarrhea was the most common adverse event, with grade ≥ 3 events occurring more frequently in patients receiving neratinib with capecitabine (24%) than in those receiving lapatinib with capecitabine (13%). Lapatinib plus capecitabine is another option, especially for patients who prefer an orally administered regimen and do not tolerate neratinib. In a phase 3 trial involving 399 patients who were randomly assigned to receive lapatinib plus capecitabine or capecitabine alone, the treatment was shown to have a systemic benefit [40]. Combination treatment showed a significant benefit in median time to tumor progression (6 vs 4 months; HR 0.57, 95% CI 0.43–0.77; $P < 0.001$) compared to capecitabine monotherapy, with a trend towards improvement in median OS (75 vs 65 weeks; HR 0.78, 95% CI 0.55–1.12, $P = 0.177$), which was not statistically significant [40]. Although the phase 3 randomized CEREBEL clinical trial, which randomized 540 patients with metastatic BC without evidence of BM to receive capecitabine plus either lapatinib or trastuzumab was designed to investigate incidence of CNS metastases as first site of relapse (primary endpoint), the study showed that median PFS and OS were longer with trastuzumab-capecitabine compared with lapatinib-capecitabine (HR for PFS, 1.30; 95% CI, 1.04–1.64; HR for OS, 1.34; 95% CI, 0.95–1.64) [41]. Finally, in TKI-naïve patients, lapatinib-trastuzumab improves PFS (HR 0.73; $P = 0.008$) with a trend towards improved OS (HR 0.75; $P = 0.106$) compared with lapatinib alone [42].

Tucatinib expands options for HER2-positive metastatic breast cancer

Tucatinib is an oral reversible TKI highly selective for the kinase domain of HER2, with minimal inhibition of epidermal growth factor receptor (Table 1) [5]. During its preclinical characterization and in the early-phase clinical settings, tucatinib has demonstrated efficient brain penetration [44,45]. A strong biological rationale supports its use in combination with other anti-HER2 compounds, as tucatinib displayed synergistic activity when combined with either trastuzumab or T-DM1, in preclinical models [44]. Moreover, as trastuzumab may contribute to innate and adaptive immune system engagement, tucatinib may provide further synergistic effect for enhancing this activity [46].

In the phase 1b clinical trial testing the combination of tucatinib, trastuzumab and capecitabine, 60 patients were enrolled and treated [47]. The tucatinib recommended phase 2 dose was determined to be 300 mg orally twice a day, equivalent to single-agent maximum tolerated dose. Pharmacokinetic analysis showed that there was no drug-drug interaction with capecitabine, with an overall good safety profile. In HER2CLIMB, tucatinib demonstrated efficacy compared with placebo in PFS (7.8 months versus 5.6 months; HR: 0.54, 95% CI: 0.42–0.71, $p < 0.001$) and OS (21.9 months versus 17.4 months; HR: 0.66, 95% CI: 0.50–0.87, $p = 0.0048$) in patients pre-treated with both dual blockade and T-DM1 [6]. Of note, risk of developing new CNS lesions was reduced by 48% in all patients with or without BMs in the tucatinib-combination arm (HR 0.52; 95% CI 0.33–0.82), with a prolonged time to development of new BMs or death as compared with the placebo-combination group (median new BMs-free survival, not reached versus 11.7 months) [48]. Active BMs did not represent an exclusion criterion, unless immediate management was needed, in which case enrolment was permitted after local intervention [6]. Indeed, patients with either active or a history of CNS metastases ($N = 291$) accounted for 48% ($N = 198$, tucatinib arm) and 46% ($N = 93$, control arm) of the study population, with median duration of PFS of 7.6 months (95% CI: 6.2–9.5) and 5.4 months (95% CI: 4.1–5.7) for the experimental and control arm, respectively [6]. An exploratory analysis focusing on the BM endpoints in these 291 patients showed improved intracranial PFS by the addition of tucatinib (9.9 months versus 4.2 months, $p < 0.0001$; HR: 0.48, 95% CI: 0.34–0.69, $p < 0.00001$) and OS (18.1 months versus 12 months, $p = 0.005$; OS HR, 0.58; 95% CI: 0.40–0.85; $p = 0.005$) [6]. Intracranial

Table 1

Clinical features and chemical properties of tucatinib. *Information about CNS penetration is based on a whole-body physiologically based pharmacokinetic (PBPK) model integrated with a 4-compartment permeability-limited brain model developed and verified for predicting tucatinib concentration–time profiles in the plasma, cerebrospinal fluid, brain and brain tumors. Abbreviations: AEs, adverse events; ALP, alkaline phosphatase; ALT, alanine aminotransferase; AST, aspartate aminotransferase; CL, clearance; CNS, central nervous system; C_{ss,ave}, Classification System steady-state average concentration; EGFR, epidermal growth factor receptor; HER2, human epidermal growth factor receptor 2; IC₅₀, half maximal inhibitory concentration; K_{p,uu}, unbound brain-to-unbound plasma concentration ratio; MoA, Mechanism of Action; N, nitrogen; P_{app}, passive permeability; PD, Pharmacodynamics; PK, Pharmacokinetics; TER, target engagement ratio; TKI, tyrosine kinase inhibitor; V_d, volume of distribution; †, increased. Adapted from Corti et al 2022. [5,6,45].

Chemical name	N6-(4,4-dimethyl-4,5-dihydrooxazol-2-yl)-N4-[3-methyl-4-([1,2,4]triazolo[1,5-a]pyridin-7-yloxy)phenyl]quinazoline-4,6-diamine
Alternative names	ONT-380, ARRY-380, irbinitinib, 937263-43-9, Tukysa (trade name)
Class	Small molecule, TKI
MoA	Highly selective for the kinase domain of HER2, minimal inhibition of EGFR. Prevention of signal transduction pathways, resulting in growth inhibition and cell death.
Route	Oral administration
PD	HER2 IC ₅₀ 6.9 nmol/L, EGFR IC ₅₀ 449 nmol/L Note: Decrease toxicity avoiding targeting EGFR which is mostly associated with the increase of gastro-intestinal and dermatological toxicity Neratinib: HER2 IC ₅₀ 5.6 nmol/L, EGFR IC ₅₀ 1.8 nmol/L Lapatinib: HER2 IC ₅₀ 109 nmol/L, EGFR IC ₅₀ 48 nmol/L
PK	V _d ≈ 1670 L, plasma protein binding 97%, CL 148 L/h, half-life ≈ 8.5 hCNS penetration*: high passive permeability (P _{app} , 12.6 × 10 ⁻⁶ cm/s). Normal brain: C _{ss,ave} = 5.37 ng/mL (TER, 1.6), (K _{p,uu}) 0.47. Brain tumors: C _{ss,ave} 15.6 ng/mL (TER, 4.7), K _{p,uu} = 1.37 († drug penetration).
AEs	<i>Common:</i> diarrhea, palmar-plantar erythrodysesthesia syndrome, anemia, decreased phosphate, nausea. <i>Sporadic:</i> hepatotoxicity (↑ALT, ↑AST, ↑ALP, ↑ bilirubin), vomiting, stomatitis, decreased appetite, rash, renal impairment (increased creatinine, decreased magnesium, potassium, or sodium).

objective response rate (ORR) was also improved among the 75 patients with active BMs and measurable intracranial disease at baseline (47.3% versus 20%, $p = 0.03$), with a 1-year intracranial PFS of 35% versus 0% in the experimental arm and in the control arm, respectively [6]. A recent update focusing on patients with CNS involvement, confirmed the OS advantage for the tucatinib-including combination (21.6 months in the tucatinib-combination group, 95% CI, 18.1–28.5, versus 12.5 months in the placebo-combination group, 95% CI, 11.2–16.9), while reducing the risk of developing new brain lesions as the site of first progression or death (45.1% reduction in the tucatinib-combination group versus the placebo-combination group, HR 0.55, 95% CI, 0.36–0.85), thus further supporting the clinical relevance of this treatment option for patients with HER2-positive metastatic BC, including those with BMs [49]. Finally, as thirty patients (21, tucatinib arm; 9, control arm) who experienced isolated progression in the brain and underwent local therapy continued study-assigned treatment, second progression could be assessed [50]. In these patients, median time from random assignment to second progression (brain or body) or death was 15.9 months (95% CI, 11.7–28.2 months) in the tucatinib arm and 9.7 months (95% CI, 4.9–12.0 months) in the control arm (HR, 0.29; 95% CI, 0.11–0.77; $P = 0.009$). Median time from progression in the brain to second progression (brain or body) or death in these patients was 7.6 months (95% CI, 3.9–11.3 months) in the tucatinib arm versus 3.1 months (95% CI, 1.2–4.1 months) in the control arm (HR, 0.33; 95% CI, 0.13–0.85; $P = 0.02$) [50].

As for the safety profile, the most common adverse events in the tucatinib arm were diarrhea (any grade: 80% versus 53% in the control

arm; grade ≥ 3 diarrhea: 12.9% versus 8.6% in the control arm), palmar-plantar erythrodysesthesia syndrome, fatigue, nausea, and vomiting. Patients in the tucatinib arm experienced a higher rate of transaminitis, even though typically low-grade, transient, and reversible. Consistently, Health-Related Quality of Life (HRQoL) was maintained throughout treatment and was not different between treatment arms. So, the HER2CLIMB clinical trial provides the highest level of evidence regarding medical treatment of patients with HER2-positive BC with CNS disease, because of its randomized design, the inclusion of individuals with active BMs, as well as the presence of a specific BM endpoint [1]. To summarize, the combination therapy of tucatinib, capecitabine, and trastuzumab is one of the most effective treatment options for third-line management, alongside T-DXd and T-DM1. For patients with active BMs, the tucatinib-containing combination regimen should be considered as a second-line option based on the demonstrated PFS and OS benefits in this patient population (Fig. 3). [6,50].

Targeting BMs in HER2-positive metastatic breast cancer

Although current guidelines for metastatic BC do not support routine BM screening, recent advancements, especially in treatment choices for HER2-positive BC with BMs, are paving the way for a higher probability of clinical benefit from early interventions [51]. Therefore, ongoing clinical trials are investigating the role of brain monitoring, especially for HER2-positive and TNBC subtypes (NCT04030507, NCT03617341, NCT03881605) (Fig. 4) [1].

To date, surgery and stereotactic radiosurgery (SRS) remain the mainstays of treatment of BMs from BC [1]. Individuals who benefit the most from aggressive local treatment are those with a long survival expectancy [55]. SRS is defined as the delivery of high doses of radiation via stereotactic or image guidance with ~ 1 mm targeting accuracy to intracranial targets, and it is usually administered as single fraction with doses ranging between 15 and 24 Gy [51]. Fractionated SRS, typically delivered with 27 Gy in three fractions or 30 Gy in five fractions, is preferred in patients with larger lesions (>3 cm diameter) or for lesions located in proximity of structures at risk, or in case of re-irradiation [56]. The approach to patients with multiple BMs has evolved over the last decade, as SRS has become more widely available. A recent large multi-institutional prospective observational study supports its use in the initial management also for patients with 5–10 lesions from different primary tumors, with comparable survival outcomes to patients with 2–4 BMs and room for use also in case of ≥ 10 BMs [57,58]. Treatment-related toxicity was low, with neurocognitive function assessed by the mini-mental state examination being similar between groups when cumulative tumour volume was < 15 ml [59]. Furthermore, SRS has demonstrated sustained local control rates when used either as primary or salvage treatment for BMs specifically from BC [60,61]. Considering the high local recurrence rates after neurosurgical resection alone, two randomized clinical trials evaluated SRS to surgical cavity and demonstrated no difference in OS with a lower decline in neurocognitive function in respect to whole brain radiotherapy (WBRT) [62,63]. Consequently, WBRT currently represents an alternative especially for symptomatic patients who are not eligible for either surgery or SRS (e.g., high number of BMs, multiple bulky lesions), being associated with a more frequent cognitive decline without an OS benefit [1,62,64].

Systemic anti-HER2 treatment should be considered to delay WBRT in HER2-positive BC patients with asymptomatic or oligosymptomatic BMs [1,2]. In this context, if no adjuvant HER2-directed approaches have historically demonstrated a role in prevention or at least postponement of BMs, the role of systemic therapy at least in patients with metastatic HER2-positive BC is rapidly changing [51,65–69]. Indeed, as previously discussed, tucatinib has demonstrated not only to delay the onset of new BMs, in pretreated patients with metastatic BC, but also the ability to prolong time to second progression (brain or body) after isolated and locally-treated CNS progression followed by continued study-assigned treatment [48–50]. However, as per current clinical practice,

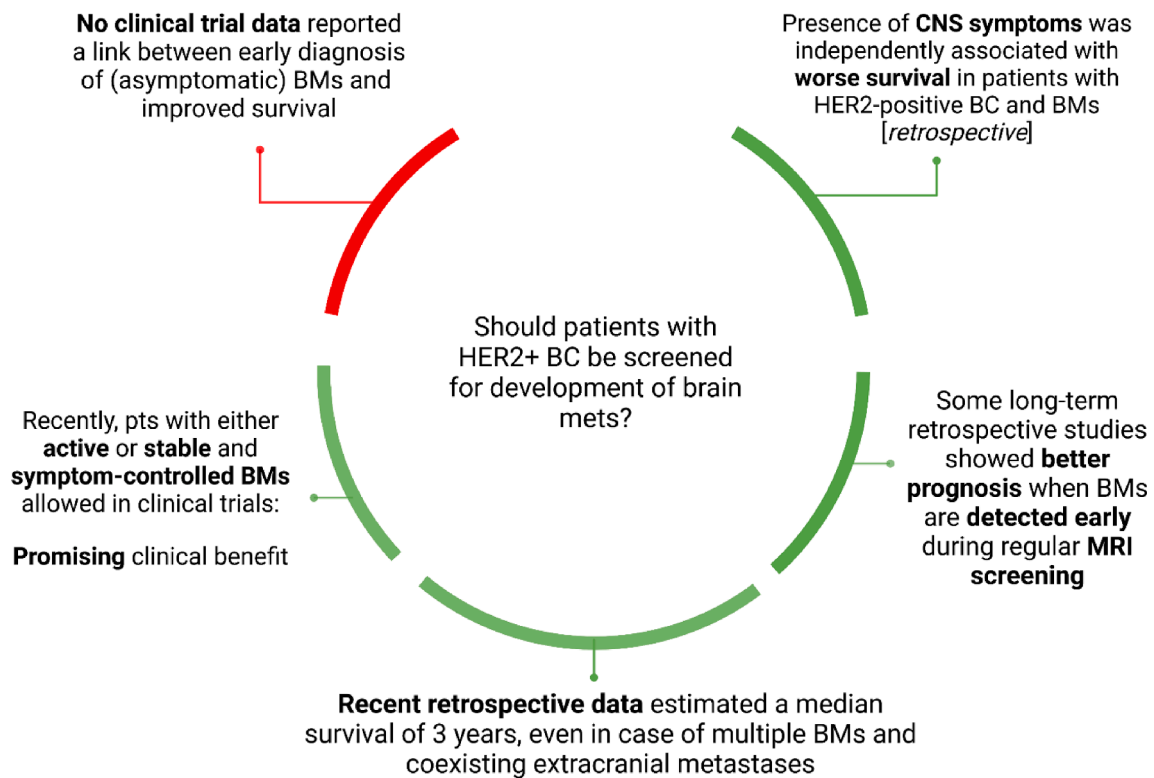


Fig. 4. Evidence in favor and against the routinary screening for development of BMs in patients with HER2-positive metastatic BC. Abbreviations: BC, breast cancer; BMs, brain metastases; CNS, central nervous system; HER2, human epidermal growth factor receptor 2; MRI, magnetic resonance imaging; [52–54]. Created with biorender.com (2023).

upfront systemic anti-HER2 treatment could be considered for minimally symptomatic patients, presenting with a limited number of lesions [66]. Also, systemic therapy can be suggested in case of further CNS progression despite prior local therapy [52,66]. In case of BMs without evidence of extracranial disease, there is a lack of well-conducted prospective studies to support the choice of a systemic approach in addition to local therapy [1]. Hence, local treatment with surgery and/or radiotherapy (RT) may be proposed as first step. Even though CLEO-PATRA did not include patients with BMs at diagnosis, in the specific subgroup analysis focused on patients who developed CNS disease, median time to develop BMs was increased from 12 to 15 months with the addition of pertuzumab to trastuzumab and docetaxel [70].

Therefore, despite acknowledging the lack of prospective data to determine the efficacy of this approach in radically resected brain-only metastatic disease, trastuzumab monotherapy or trastuzumab-pertuzumab therapy may be considered for this subset of HER2-positive patients. Conversely, HER2 TKIs plus capecitabine are not administered in this setting outside clinical trials due to the potential for treatment-related toxicities without clear evidence of clinical benefit [51].

In case of stable extracranial disease and CNS progression manageable with stereotactic RT, local treatment should be offered, continuing systemic treatment with the same anti-HER2 agent, in absence of solid prospective evidence [1,25,66]. Only chemotherapy should be held and resumed 1–2 weeks after completion of RT [66]. If BMs develop over a short period of time, a switch of systemic therapy should be carefully considered [1,51]. In this regard, second-line therapy should take into account the results of DESTINY-Breast-03 clinical trial (Fig. 3) [27]. Indeed, the significant PFS benefit associated with T-DXd treatment was observed across all predefined subgroups, including those defined by presence of visceral disease or BMs [27]. Specifically, among the 114 patients with stable BMs, the hazard ratio for disease progression or death was 0.38, favoring T-DXd (95% CI, 0.23–0.64) [1,27]. More

directly relevant results emerged from the phase 2 TUXEDO-1 trial, which enrolled patients with HER2-positive BC either with newly diagnosed BMs or with BMs showing radiological progression after prior local therapy and/or prior exposure to trastuzumab and pertuzumab and without indication for immediate local therapy. Of 15 patients enrolled in the intention-to-treat population, 2 (13.3%) participants showed a complete intracranial response, 9 (60%) had a partial intracranial response, 3 (20%) had stable disease as the best intracranial response, and an overall intracranial response rate of 73.3% (95% CI, 48.1–89.1) was observed (primary endpoint), with median PFS of 4 months [71]. Of note, in the recently presented phase 2 clinical trial DEBBRAH, which included 13 patients with advanced HER2-positive BC and either asymptomatic untreated BMs or progressive BMs after local therapy, T-DXd was associated with an intracranial response rate of 46% [43]. Although limited, these data add to accumulating evidence supporting T-DXd in patients whose BMs have progressed despite prior local therapy. Moreover, updated results of the same trial presented at the San Antonio Breast Cancer Symposium 2022 documented first preliminary hints of activity also in the small HER2-low population of patients with active BMs (N = 12, ORR-IC 6/12, 50%).

Until recently, T-DM1 was the gold standard second-line therapy for HER2-positive metastatic BC, based on consistent PFS and OS benefit observed in EMILIA and TH3RESA clinical trials [30,31]. In such context, an exploratory retrospective analysis of the EMILIA study, which investigated T-DM1 in metastatic HER2-positive BC patients previously treated with trastuzumab and a taxane, included 95 patients with asymptomatic BMs [72]. OS appeared improved in patients treated with T-DM1 (N = 45) compared to those receiving lapatinib and capecitabine (N = 50) (median OS, 26.8 months versus 12.9 months) [72]. Consistently, the subgroup analysis of 398 patients with metastatic BC and CNS disease, 126 of which with measurable BMs, included in the phase 3b single-arm KAMILLA clinical trial which investigated T-DM1 in pretreated HER2-positive advanced BC, confirmed an ORR of 21%, an

intracranial response rate of 43%, a median PFS of 6 months and a median OS of 19 months [35]. To summarize, T-DM1 appears to have some activity in the context of BMs, with PFS around 5–7 months, although OS remains significantly inferior compared to patients without intracranial disease [73].

As for later treatment lines, some TKIs are commonly considered for the treatment of HER2-positive metastatic BC that has spread to the CNS, due to their ability to cross the blood–brain barrier (BBB) [1,51]. Lapatinib was first demonstrated to cross the BBB in 2015, with a concentration in BMs from BC ranges from 1.0 to 6.5 μM [74]. However, lapatinib monotherapy demonstrated poor efficacy on BMs [75–78]. In the aforementioned CEREBEL study, the incidence of CNS events was low, and comparable between the capecitabine-lapatinib arm (3%) and the capecitabine-trastuzumab arm (5%), indicating that the lapatinib-capecitabine combination did not demonstrate superiority over trastuzumab-based treatment in controlling intracranial disease (primary endpoint, CNS metastases as first site of relapse) [1,41]. Another next-generation TKI, neratinib, was investigated in combination with capecitabine versus lapatinib plus capecitabine in the second and third-line settings, in 130 patients with BC and symptomatic or stable BMs at the study entry (phase 3, NALA trial) [39]. The cumulative incidence of requiring local intervention (e.g., surgery, RT) was lower in the neratinib arm compared with lapatinib (29% versus 23%, $p = 0.04$) [39]. In patients with pre-treated BMs, the neratinib-containing combination demonstrated a control rate of $\sim 50\%$ [79]. Consistently, of the 37 patients enrolled in a phase 2 trial assessing the combination of neratinib and capecitabine, the BM volumetric response was 49%, with a 6-months PFS of 38% and a median time to BM progression of 5.5 months. Of note, most of the patients had received prior RT (i.e., 65% WBRT, 32% stereotactic RT) and 89%, 22% and 14% of patients had been previously treated with trastuzumab, T-DM1 and another investigational HER2-directed agent, respectively [79].

Conclusion and future perspectives

The story of HER2, a gene identified in 1982–1984, evolved with the identification of HER2-positive BC and the search for targeted agents [80]. Years later, tucatinib was developed by Array BioPharma and licensed to Cascadian Therapeutics (subsequently part of Seattle Genetics) [80]. Ultimately, the subsequent FDA's and EMA's registration of tucatinib for HER2-positive advanced BC represents another achievement in a scientific saga lasting for more than three decades. [2]. Although the lack of comparative studies still do not allow for recommendations about any specific sequencing, the development of novel anti-HER2 agents is rapidly shaping clinical practice guidelines [2]. In this regard, the tucatinib-based combination represents a further valid choice, with the added value of its intracranial and extracranial efficacy in patients with BMs. With the evolving therapeutic options in the landscape of HER2-positive advanced BC, management of CNS disease will require a multifaced and interdisciplinary approach. An expert panel of medical professionals, including neurologists, neurosurgeons, radiation oncologists, and medical oncologists, is needed to collaboratively develop individualized treatment strategies that consider the patient's comprehensive medical history and the unique characteristics of the BMs. For example, we will be called to optimally manage and sequence all the available drugs, considering also that some patients will have received T-DM1 in the adjuvant setting, in case of residual invasive disease after completion of neoadjuvant therapy, and that new drugs are enriching the therapeutic armamentarium (Table 2) [81,82]. Additionally, psychological and palliative care teams are also essential components of the multidisciplinary approach. Hence, BMs can significantly impact a patient's emotional and mental well-being; thus, psychological support can assist patients and their families in coping with the stress and anxiety which may arise. In turn, palliative care is crucial to enhance the quality of life for patients by managing symptoms, such as pain, nausea, and fatigue [73].

In summary, the management of BMs in patients with BC presents a challenging and continuously evolving landscape. Despite recent advances in radiation oncology, novel medical treatments and more personalized surgical approaches, treatment of BMs in patients with BC remains a complex issue due to the vast heterogeneity in tumor biology and presentation. The integration of advanced diagnostic modalities, novel medical treatments such as tucatinib, as well as biomarker-based treatment allocation, all of which in a multidisciplinary perspective, may enhance patient selection for individualized therapeutic strategies, thus ultimately leading to improved patient outcomes. Undoubtedly, further research is needed to better understand the biology of BMs in BC, identify reliable predictive biomarkers, and develop effective therapeutic compounds.

Funding

This research did not receive any specific grant from funding agencies in the public, commercial, or not-for-profit sectors.

CRediT authorship contribution statement

Carmen Criscitiello: Conceptualization, Methodology, Writing – original draft, Writing – review & editing, Supervision. **Chiara Corti:** Conceptualization, Methodology, Visualization, Writing – original draft, Writing – review & editing. **Michelino De Laurentiis:** Writing – review & editing. **Giampaolo Bianchini:** Writing – review & editing. **Barbara Pistilli:** Writing – review & editing. **Saverio Cinieri:** Writing – review & editing. **Lucio Castellan:** Writing – review & editing. **Grazia Arpino:** Writing – review & editing. **Pierfranco Conte:** Writing – review & editing. **Francesco Di Meco:** Writing – review & editing. **Alessandra Gennari:** Writing – review & editing. **Valentina Guarneri:** Writing – review & editing. **Luca Visani:** Writing – review & editing. **Lorenzo Livi:** Writing – review & editing. **Paolo Marchetti:** Writing – review & editing. **Fabio Puglisi:** Writing – review & editing. **Giuseppe Viale:** Writing – review & editing. **Lucia Del Mastro:** Writing – review & editing. **Sabino De Placido:** Writing – review & editing. **Giuseppe Curigliano:** Writing – review & editing.

Declaration of Competing Interest

CCr reports personal fees for consulting, advisory role and speakers' bureau from Lilly, Roche, Novartis, MSD, Seagen, Gilead and Pfizer. All the competing interests were outside the submitted work. CCo has no potential conflicts of interest to disclose. MDL reports honoraria for lectures, presentations, speakers bureaus, manuscript writing or educational events from Eli Lilly, Novartis, Seagen, Takeda, Roche, Daiichi Sankyo, Tomalab, Gilead, Genetic, Menarini, Sophos; support for attending meetings and/or travel from Gilead, Novartis, Roche, AstraZeneca; fees for participation on a Data Safety Monitoring Board or Advisory Board from Pfizer, AstraZeneca, Sanofi, Seagen, Novartis, Ipsen, Roche, Pierre-Fabre, Daiichi-Sankyo, GSK. All the competing interests were outside the submitted work. GB is a consultant and/or advisory board member for Amgen, AstraZeneca, Chugai, Daiichi Sankyo, EISAI, Eli Lilly, Genomic Health, Merck Sharp & Dohme, Neopharm, Novartis, Pfizer, Roche and Sanofi. All the competing interests were outside the submitted work. BP has no potential conflicts of interest to disclose. SC reports current presidency of the Italian Association of Medical Oncology (AIOM). All the competing interests were outside the submitted work. LC has no potential conflicts of interest to disclose. GA has no potential conflicts of interest to disclose. PC reports personal fees from Novartis, Eli Lilly, AstraZeneca, Tesaro, Daiichi Sankyo, and Gilead, revealing Genomics, BMS, and Roche. All the competing interests were outside the submitted work. FDM has no potential conflicts of interest to disclose. AG has no potential conflicts of interest to disclose. VG reports personal fees from Eli Lilly, Exact Sciences, Novartis, Pfizer, Gilead, MSD, Amgen, Sanofi, Merck Serono, and Eisai.

Table 2

Ongoing clinical trials currently investigating tucatinib in breast cancer, as of May 4th 2023. *Active, # recruiting, § not yet recruiting. Abbreviations: ADC, antibody-drug conjugate; AE, adverse events; BMs, brain metastases; CDK4/6i, Cyclin-dependent kinase 4 and 6 inhibitor; ChT, chemotherapy; DLT, dose-limiting toxicities; eBC, early breast cancer; ET, endocrine therapy; HR, hormone receptor; HER2, human epidermal growth factor receptor 2; LMD, leptomeningeal disease; LND, lymph nodes; mBC, metastatic breast cancer; mo, months; MRI, magnetic resonance imaging; MTD, maximum tolerated dose; (neo)adj, (neo)adjuvant; NR, not reported; Ø, diameter; pCR, pathologic complete response; PD, progressive disease; PFS, progression-free survival; PI, principal investigator; PIK3CA, phosphatidylinositol-4,5-bisphosphate 3-kinase catalytic subunit alpha; PTZ, pertuzumab; RP2D, recommended phase 2 dose; SRS, stereotactic radiosurgery; T-DM1, ado-trastuzumab emtansine; T-DXd, trastuzumab deruxtecan; TTZ, trastuzumab; tx, therapy; vs, versus; w/o, without .

Trial ID	Phase	Regimen	Setting	Primary Endpoint (s)	Sample	Active Brain mets
NCT03054363*	1–2	Tucatinib + palbociclib + letrozole	HR + HER2 + mBC; > 2 anti-HER2 tx (any setting), of which at least 1 in mBC	Safety (AEs), PFS	42	Eligible (if Ø > 2 cm on MRI, enrollment upon approval)
NCT05230810#	1b-2	Tucatinib + alpelisib +/- fulvestrant (if HR +)	PIK3CA-Mutant HER2 + mBC	MTD, AEs, PFS	40	Eligible (if Ø > 2 cm on MRI, enrollment upon approval)
NCT04896320#	1–2	Gemcitabine or Vinorelbine + Tucatinib + Trastuzumab	HER2 + mBC, after TTZ/cape and T-DM1	MTD	40	Eligible (if Ø > 2 cm on MRI, enrollment upon approval)
NCT04539938# (HER2CLIMB-04)	2	Tucatinib + T-DXd	HER2 + mBC, prior taxane and TTZ or PD within 6 mo after (neo)adj tx.	ORR	70	Eligible (if Ø > 2 cm on MRI, enrollment upon approval)
NCT05458674#	2	Tucatinib + eribulin + TTZ	HER2 + mBC, after prior taxane-TTZ or relapse within 6 mo (neo)adj setting	AEs, SAEs	30	Eligible (if Ø > 2 cm on MRI, enrollment upon approval)
NCT05132582# (HER2CLIMB-05)	3	Tucatinib/Placebo + TTZ + PTZ	HER2 + mBC, after 4–8 cycles of prior TTZ, PTZ and taxane in 1L w/o PD.	PFS	650	if asymptomatic and w/o PD, since starting 1L tx
NCT05583110§ (TrasTUCAN)	2	TTZ + tucatinib + vinorelbine	HER2 + mBC, ≥ 2 anti-HER2 tx in any setting. Prior taxane-TTZ mandatory.	ORR	49	Untreated BMs not needing immediate local tx.
NCT03975647#	3	Tucatinib/Placebo + T-DM1	HER2 + mBC, after taxane-TTZ in any setting.	PFS	565	Untreated BMs not needing immediate local tx.
NCT05553522#	1	Tucatinib, TTZ, and Capecitabine with SRS	HER2 + mBC, with newly-diagnosed BMs.	DLTs, Incidence of radiation-related toxicities	40	Allowed, except if within 5 mm of the optic chiasm/ optic nerve or brainstem involvement
NCT05041842# (InTTercePT)	2	Tucatinib + TTZ-PTZ +/- endocrine tx	Documented isolated BMs PD under TTZ-PTZ with or without taxane	PFS	55	No limit to the number and Ø of BMs
NCT05382364#	1	tucatinib	HER2 + mBC, gastric or GEJ, and CRC, no more available tx (Chinese population)	AEs	25	If asymptomatic
NCT04789096§	2	Tucatinib + TTZ + pembrolizumab +/- capecitabine	HER2 + mBC, after prior taxane, TTZ, PTZ and ADC (any setting)	ORR	50	Eligible (if Ø > 2 cm on MRI, enrollment upon approval)
NCT05323955# (BRIDGET)	2	Addition of tucatinib to either ongoing 1L TTZ/PTZ or 2L -T-DM1	HER2 + mBC with isolated intracranial recurrence on anti-HER2 tx	PFS	48	Only if Ø <5 mm
NCT03501979*	2	Tucatinib + TTZ + capecitabine	HER2 + mBC with LMD	OS	30	Patients must not have received any therapy specifically directed at LMD
NCT04457596# (CompassHER2 RD)	3	T-DM1 vs T-DM1 + tucatinib	HER2 + eBC T1-4, N0-3 and residual invasive disease	iDFS	1031	NA
NCT05319873#	1b-2	ribociclib, tucatinib, TTZ +/- fulvestrant (phase 1b and 2); vs docetaxel, carboplatin, TTZ, PTZ (phase 2)	HER2 + mBC (phase 1b, ≥2L) and HER2 + eBC neoadj (phase 2)	AEs, MTD, RP2D, pCR	18	Eligible (if Ø > 2 cm on MRI, enrollment upon approval)
NCT04579380#	2	Tucatinib + TTZ (+fulvestrant if HER2-mutant mBC)	HER2 + metastatic solid tumors, ≥1 prior line	ORR	270	NR
NCT04538742#	1b-2	T-DXd + tucatinib (module 5 and 6)	HER2 + mBC 1L (module 5), 1-2L (module 6)	AEs	450	Eligible in module 6
NCT04760431#	2	TTZ + PTZ + taxane; TTZ + taxane + TKIs (pyrotinib, neratinib or tucatinib)	HER2 + mBC with active BMs, after TTZ-based tx	ORR	120	eligible
NCT04802759# (MORPHEUS-BREAST CANCER)	1–2	Multiple Treatment Combinations, including tucatinib	HR + mBC on PD during or after 1-2L ET, must have received prior CKD4/6i (cohort 1); HR + HER2 + mBC after prior TTZ-based and taxane based tx.	ORR, AEs, drug plasma concentrations	510	Not eligible
NCT04632992* (MyTACTIC)	2	Multiple Treatment Combinations, including tucatinib	advanced solid malignancy	ORR	252	Not eligible
NCT01042379# (I-SPY)	2	Multiple Treatment Combinations, including tucatinib	eBC (stage II or III, or T4, any N, M0, including inflammatory BC or regional stage IV, if supraclavicular LND only met site	pCR	5000	NA
NCT02693535#	2	Multiple Treatment Combinations, including tucatinib	Locally advanced or metastatic solid tumor, multiple myeloma or B cell non-Hodgkin lymphoma no longer benefiting from standard anti-cancer treatment	ORR	3641	Eligible on a case-by-case basis

Source: clinicaltrials.gov

All the competing interests were outside the submitted work. LV has no potential conflicts of interest to disclose. LL has no potential conflicts of interest to disclose. PM declares grants to his Institution from Roche, BMS, Pfizer, Incyte, Novartis, Takeda, MSD, Pierre Fabre; personal payments from Roche, BMS, MSD, Novartis, Pfizer, Pierre Fabre; personal support for congress attendance from BMS, Roche; is President of the Italian Foundation of Personalized Medicine, of AIOM Servizi s.r.l., of the Steering and Verification Board of the 'Regina Elena' National Cancer Institute. All the competing interests were outside the submitted work. FP reports honoraria for advisory boards, activities as a speaker, travel grants, research grants from Amgen, AstraZeneca, Daiichi Sankyo, Celgene, Eisai, Eli Lilly, Exact Sciences, Gilead, Ipsen, Menarini, MSD, Novartis, Pierre Fabre, Pfizer, Roche, Seagen, Takeda, Viartis; research funding from AstraZeneca, Eisai, Roche. All the competing interests were outside the submitted work. GV has no potential conflicts of interest to disclose. LDM reports institutional grants or contracts from Eli Lilly, Novartis, Roche, Daiichi Sankyo, Seagen, AstraZeneca, Gilead; personal consulting fees from Eli Lilly; personal honoraria for lectures, presentations, speakers bureau, manuscript writing or educational events from Roche, Novartis, Pfizer, Eli Lilly, AstraZeneca, MSD, Seagen, Gilead, Pierre Fabre, Eisai, Exact Sciences, Ipsen, GSK, Agendia, Stemline; support for attending meetings and/or travel from Roche, Pfizer, Eisai, Daiichi Sankyo, AstraZeneca; personal fees for participation on a Data Safety Monitoring Board or Advisory Board from Novartis, Roche, Eli Lilly, Pfizer, Daiichi Sankyo, Exact Sciences, Gilead, Pierre Fabre, Eisai, Astrazeneca, Agendia, GSK, Seagen. All the competing interests were outside the submitted work. SDP reports personal fees for consulting or advisory role from Roche, Novartis, Pfizer, Lilly, Celgene, AstraZeneca/MedImmune, Seattle Genetics, Daiichi Sankyo/AstraZeneca, MSD. All the competing interests were outside the submitted work. GC reports personal fees for consulting, advisory role and speakers' bureau from Roche/Genentech, Novartis, Pfizer, Lilly, Foundation Medicine, Samsung and Daiichi Sankyo; honoraria from Ellipses Pharma and fees for travel and accommodations from Roche/Genentech and Pfizer. All the competing interests were outside the submitted work.

Acknowledgements

CCr, contributed to the literature search, conception, design of the article, provided critical revisions of the manuscript and supervision. CCo contributed to the literature search, conception, design of the article and drafted the first version of the manuscript. MDL, GB, BP, SC, LC, GA, PC, FDM, AG, VG, LV, LL, PM, FP, GV, LDM, SDP, GC provided critical revisions of the manuscript. Figure 1, Figure 2, Figure 3 and Figure 4 were created by CCo with biorender.com. All the authors provided final approval to the submitted work.

References

- [1] Corti C, Antonarelli G, Criscitiello C, Lin NU, Carey LA, Cortés J, et al. Targeting brain metastases in breast cancer. *Cancer Treat Rev* 2022;103:102324.
- [2] Gennari A, André F, Barrios C, Cortes J, al e: ESMO Clinical Practice Guideline for the diagnosis, staging and treatment of patients with metastatic breast cancer. *Annals of Oncology* October 19, 2021.
- [3] FDA approves tucatinib for patients with HER2-positive metastatic breast cancer. Published April 17, 2020. <https://bit.ly/3mOnvKY>.
- [4] EMA: summary of CHMP positive opinion about Tukysa (tucatinib). <https://bit.ly/37T1I34>.
- [5] Corti C, Criscitiello C. Tucatinib approval by EMA expands options for HER2-positive locally advanced or metastatic breast cancer. *ESMO Open* 2021;6(2):100063.
- [6] Murthy RK, Loi S, Okines A, Paplomata E, Hamilton E, Hurvitz SA, et al. Tucatinib, Trastuzumab, and Capecitabine for HER2-Positive Metastatic Breast Cancer. *N Engl J Med* 2020;382(7):597–609.
- [7] Wolff AC, Hammond MEH, Allison KH, Harvey BE, Mangu PB, Bartlett JMS, et al. Human Epidermal Growth Factor Receptor 2 Testing in Breast Cancer: American Society of Clinical Oncology/College of American Pathologists Clinical Practice Guideline Focused Update. *J Clin Oncol* 2018;36(20):2105–22.
- [8] Fehrenbacher L, Cecchini RS, Geyer Jr CE, Rastogi P, Costantino JP, Atkins JN, et al. NSABP B-47/NRG Oncology Phase III Randomized Trial Comparing Adjuvant Chemotherapy With or Without Trastuzumab in High-Risk Invasive Breast Cancer Negative for HER2 by FISH and With IHC 1+ or 2. *J Clin Oncol* 2020;38(5):444–53.
- [9] Ng CKY, Martelotto LG, Gauthier A, Wen H-C, Piscuoglio S, Lim RS, et al. Intratumor genetic heterogeneity and alternative driver genetic alterations in breast cancers with heterogeneous HER2 gene amplification. *Genome Biol* 2015;16(1).
- [10] Ng CKY, Pemberton HN, Reis-Filho JS. Breast cancer intratumor genetic heterogeneity: causes and implications. *Expert Rev Anticancer Ther* 2012;12(8):1021–32.
- [11] Ercoli G, Lopez G, Ciapponi C, Corti C, Despini L, Gambini D, et al. Building Up a High-throughput Screening Platform to Assess the Heterogeneity of HER2 Gene Amplification in Breast Cancers. *J Vis Exp* 2017.
- [12] Wolff AC, Hammond MEH, Hicks DG, Dowsett M, McShane LM, Allison KH, et al. Recommendations for human epidermal growth factor receptor 2 testing in breast cancer: American Society of Clinical Oncology/College of American Pathologists clinical practice guideline update. *Arch Pathol Lab Med* 2014;138(2):241–56.
- [13] Vance GH, Barry TS, Bloom KJ, Fitzgibbons PL, Hicks DG, Jenkins RB, et al. Pathologists CoA: Genetic heterogeneity in HER2 testing in breast cancer: panel summary and guidelines. *Arch Pathol Lab Med* 2009;133:611–2.
- [14] Murthy SS, Sandhya DG, Ahmed F, Goud KI, Dayal M, Suseela K, et al. Assessment of HER2/Neu status by fluorescence in situ hybridization in immunohistochemistry-equivocal cases of invasive ductal carcinoma and aberrant signal patterns: a study at a tertiary cancer center. *Indian J Pathol Microbiol* 2011;54:532–8.
- [15] Chang MC, Maloway JI, Mazurkiewicz J, Wood M. 'Genetic heterogeneity' in HER2/neu testing by fluorescence in situ hybridization: a study of 2,522 cases. *Mod Pathol* 2012;25(5):683–8.
- [16] Bartlett AI, Starczynski J, Robson T, MacLellan A, Campbell FM, van de Velde CJH, et al. Heterogeneous HER2 gene amplification: impact on patient outcome and a clinically relevant definition. *Am J Clin Pathol* 2011;136(2):266–74.
- [17] Tarantino P, Carmagnani Pestana R, Corti C, Modi S, Bardia A, Tolanev SM, et al. Antibody-drug conjugates: Smart chemotherapy delivery across tumor histologies. *CA Cancer J Clin* 2022;72(2):165–82.
- [18] Corti C, Antonarelli G, Valenza C, Nicolò E, Rugo H, Cortés J, et al. Histology-agnostic approvals for antibody-drug conjugates in solid tumours: is the time ripe? *Eur J Cancer* 2022;171:25–42.
- [19] Tarantino P, Hamilton E, Tolanev SM, Cortes J, Morganti S, Ferraro E, et al. HER2-Low Breast Cancer: Pathological and Clinical Landscape. *J Clin Oncol* 2020;38(17):1951–62.
- [20] Schettini F, Chic N, Brasó-Maristany F, Paré L, Pascual T, Conte B, et al. Clinical, pathological, and PAM50 gene expression features of HER2-low breast cancer. *npj Breast Cancer* 2021;7(1).
- [21] Won HS, Ahn J, Kim Y, Kim JS, Song JY, Kim HK, et al. Clinical significance of HER2-low expression in early breast cancer: a nationwide study from the Korean Breast Cancer Society. *Breast Cancer Res* 2022;24:22.
- [22] Tan RSYC, Ong WS, Lee K-H, Lim AH, Park S, Park YH, et al. HER2 expression, copy number variation and survival outcomes in HER2-low non-metastatic breast cancer: an international multicentre cohort study and TCGA-METABRIC analysis. *BMC Med* 2022;20(1).
- [23] Hein A, Hartkopf AD, Emons J, Lux MP, Volz B, Taran F-A, et al. Prognostic effect of low-level HER2 expression in patients with clinically negative HER2 status. *Eur J Cancer* 2021;155:1–12.
- [24] Gampenrieder SP, Rinnerthaler G, Tinchon C, Petzer A, Balic M, Heibl S, et al. Landscape of HER2-low metastatic breast cancer (MBC): results from the Austrian AGMT_MBC-Registry. *Breast Cancer Res* 2021;23(1).
- [25] Baselga J, Cortés J, Kim S-B, Im S-A, Hegg R, Im Y-H, et al. Pertuzumab plus trastuzumab plus docetaxel for metastatic breast cancer. *N Engl J Med* 2012;366(2):109–19.
- [26] Hurvitz S, Hegg R, Chung W-P, Im S-A, et al. Trastuzumab deruxtecan versus trastuzumab emtansine in patients with HER2-positive metastatic breast cancer: updated results of the randomized, phase 3 study DESTINY-Breast03. *San Antonio Breast Cancer Symposium, 2022 December, San Antonio, TX, USA.*
- [27] Cortés J, Kim S-B, Chung W-P, Im S-A, Park YH, Hegg R, et al. Trastuzumab Deruxtecan versus Trastuzumab Emtansine for Breast Cancer. *N Engl J Med* 2022;386(12):1143–54.
- [28] FDA grants regular approval to fam-trastuzumab deruxtecan-nxki for breast cancer. Available from: <https://bit.ly/3EOu9yg>. Accessed on November 20, 2022.
- [29] EMA recommends extension of indications for trastuzumab deruxtecan, Available at: <https://bit.ly/3Aq002r>. Accessed on November 20, 2022.
- [30] Verma S, Miles D, Gianni L, Krop IE, Welslau M, Baselga J, et al. Trastuzumab emtansine for HER2-positive advanced breast cancer. *N Engl J Med* 2012;367(19):1783–91.
- [31] Krop IE, Kim S-B, González-Martín A, LoRusso PM, Ferrero J-M, Smitt M, et al. Collaborators TRS: Trastuzumab emtansine versus treatment of physician's choice for pretreated HER2-positive advanced breast cancer (TH3RESA): a randomised, open-label, phase 3 trial. *Lancet Oncol* 2014;15(7):689–99.
- [32] Antonarelli G, Corti C, Tarantino P, Salimbeni BT, Zagami P, Marra A, et al. Management of patients with HER2-positive metastatic breast cancer after trastuzumab deruxtecan failure. *ESMO Open* 2023;8(4):101608.
- [33] Krop IE, Kim S-B, Martin AG, LoRusso PM, Ferrero J-M, Badovinac-Crnjevic T, et al. Trastuzumab emtansine versus treatment of physician's choice in patients with

- previously treated HER2-positive metastatic breast cancer (TH3RESA): final overall survival results from a randomised open-label phase 3 trial. *Lancet Oncol* 2017;18(6):743–54.
- [34] Schmid P, Jung KH, Wyszocki PJ, Jassem J, Ma CX, Fernandes R, et al. 166MO Datopotamab deruxtecan (Dato-DXd) + durvalumab (D) as first-line (1L) treatment for unresectable locally advanced/metastatic triple-negative breast cancer (a/mTNBC): Initial results from BEGONIA, a phase Ib/II study. *Ann Oncol* 2022;33. <https://doi.org/10.1016/j.annonc.2022.03.185>.
- [35] Montemurro F, Delalage S, Barrios CH, Wuerstlein R, Anton A, Brain E, et al. Trastuzumab emtansine (T-DM1) in patients with HER2-positive metastatic breast cancer and brain metastases: exploratory final analysis of cohort 1 from KAMILLA, a single-arm phase IIIb clinical trial. *Ann Oncol* 2020;31(10):1350–8.
- [36] Mosele MF, Lusque A, Dieras V, Deluche E, Ducoulombier A, Pistilli B, et al. LBA1 Unraveling the mechanism of action and resistance to trastuzumab deruxtecan (T-DXd): Biomarker analyses from patients from DAISY trial. *Ann Oncol* 2022;33. <https://doi.org/10.1016/j.annonc.2022.03.277>.
- [37] Omarini C, Piacentini F, Sperduti I, Cerma K, Barbolini M, Canino F, et al. T-DM1 efficacy in trastuzumab-pertuzumab pre-treated HER2 positive metastatic breast cancer patients: a meta-analysis. *BMC Cancer* 2022;22:623.
- [38] Rugo HS, Im S-A, Cardoso F, Cortés J, Curigliano G, Musolino A, et al. Efficacy of Margetuximab vs Trastuzumab in Patients With Pretreated ERBB2-Positive Advanced Breast Cancer: A Phase 3 Randomized Clinical Trial. *JAMA Oncol* 2021;7(4):573.
- [39] Saura C, Oliveira M, Feng Y-H, Dai M-S, Chen S-W, Hurvitz SA, et al. Neratinib Plus Capecitabine Versus Lapatinib Plus Capecitabine in HER2-Positive Metastatic Breast Cancer Previously Treated With ≥ 2 HER2-Directed Regimens: Phase III NALA Trial. *J Clin Oncol* 2020;38(27):3138–49.
- [40] Geyer CE, Forster J, Lindquist D, Chan S, Romieu CG, Pienkowski T, et al. Lapatinib plus capecitabine for HER2-positive advanced breast cancer. *N Engl J Med* 2006;355(26):2733–43.
- [41] Pivot X, Manikhas A, Żurawski B, Chmielowska E, Karaszewska B, Allerton R, et al. CEREBEL (EGF11438): A Phase III, Randomized, Open-Label Study of Lapatinib Plus Capecitabine Versus Trastuzumab Plus Capecitabine in Patients With Human Epidermal Growth Factor Receptor 2-Positive Metastatic Breast Cancer. *J Clin Oncol* 2015;33(14):1564–73.
- [42] Blackwell KL, Burstein HJ, Stormiolo AM, Rugo H, Sledge G, Koehler M, et al. Randomized study of Lapatinib alone or in combination with trastuzumab in women with ErbB2-positive, trastuzumab-refractory metastatic breast cancer. *J Clin Oncol* 2010;28(7):1124–30.
- [43] Pérez-García JM, Vaz Batista M, Cortez P, Ruiz-Borrego M, Cejalvo JM, de la Haba-Rodríguez J, et al. Trastuzumab deruxtecan in patients with central nervous system involvement from HER2-positive breast cancer: The DEBBRAH trial. *Neuro Oncol* 2023;25(1):157–66.
- [44] Kulukian A, Taylor J, de Vries P, Watson D, et al. Preclinical Activity of HER2-Selective Tyrosine Kinase Inhibitor Tucatinib as a Single Agent or in Combination with Trastuzumab or Docetaxel in Solid Tumor Models. *Mol Cancer Ther* 2020;19(4):976–87.
- [45] Lee AJ, Jiang J, Kumar V, Alley SC, Peterson S, Li J. 295P: Physiologically based pharmacokinetic (PBPK) modeling of the central nervous system (CNS) pharmacokinetics of tucatinib in patients with breast cancer brain metastasis. *Ann Oncol* 2020;31:S360.
- [46] Bianchini G, Gianni L. The immune system and response to HER2-targeted treatment in breast cancer. *Lancet Oncol* 2014;15(2):e58–68.
- [47] Murthy R, Borges VF, Conlin A, Chaves J, Chamberlain M, Gray T, et al. Tucatinib with capecitabine and trastuzumab in advanced HER2-positive metastatic breast cancer with and without brain metastases: a non-randomised, open-label, phase 1b study. *Lancet Oncol* 2018;19(7):880–8.
- [48] Bachelot T, Lin NU, Murthy RK, Hurvitz SA, Borges V, Oliveira M, et al. 293P - Impact of tucatinib on progression free survival in patients with HER2+ metastatic breast cancer and stable or active brain metastases. *Ann Oncol* 2020;31(suppl_4):S348–95. <https://doi.org/10.1016/j.annonc.2020.03.268>.
- [49] Lin NU, Murthy RK, Abramson V, Anders C, Bachelot T, Bedard PL, et al. Tucatinib vs Placebo, Both in Combination With Trastuzumab and Capecitabine, for Previously Treated ERBB2 (HER2)-Positive Metastatic Breast Cancer in Patients With Brain Metastases: Updated Exploratory Analysis of the HER2CLIMB Randomized Clinical Trial. *JAMA Oncol* 2023;9(2):197.
- [50] Lin NU, Borges V, Anders C, Murthy RK, Paplomata E, Hamilton E, et al. Intracranial Efficacy and Survival With Tucatinib Plus Trastuzumab and Capecitabine for Previously Treated HER2-Positive Breast Cancer With Brain Metastases in the HER2CLIMB Trial. *J Clin Oncol* 2020;38(23):2610–9.
- [51] Le Rhun E, Guckenberger M, Smits M, Dummer R, Bachelot T, Sahm F, et al. EANO-ESMO Clinical Practice Guidelines for diagnosis, treatment and follow-up of patients with brain metastasis from solid tumours. *Ann Oncol* 2021;32(11):1322–47.
- [52] Ramakrishna N, Anders CK, Lin NU, Morikawa A, Temin S, Chandralapaty S, et al. Management of Advanced Human Epidermal Growth Factor Receptor 2-Positive Breast Cancer and Brain Metastases: ASCO Guideline Update. *J Clin Oncol* 2022;40(23):2636–55.
- [53] Yan M. Screening for breast cancer brain metastases - Authors' reply. *Lancet Oncol* 2022;23(5):e201.
- [54] Matsuo S, Watanabe J, Mitsuya K, Hayashi N, Nakasu Y, Hayashi M. Brain metastasis in patients with metastatic breast cancer in the real world: a single-institution, retrospective review of 12-year follow-up. *Breast Cancer Res Treat* 2017;162(1):169–79.
- [55] Gaspar L, Scott C, Rotman M, Asbell S, Phillips T, Wasserman T, et al. Recursive partitioning analysis (RPA) of prognostic factors in three Radiation Therapy Oncology Group (RTOG) brain metastases trials. *Int J Radiat Oncol Biol Phys* 1997;37(4):745–51.
- [56] Lehrer EJ, Peterson JL, Zaorsky NG, Brown PD, Sahgal A, Chiang VL, et al. Single versus Multifraction Stereotactic Radiosurgery for Large Brain Metastases: An International Meta-analysis of 24 Trials. *Int J Radiat Oncol Biol Phys* 2019;103(3):618–30.
- [57] Yamamoto M, Higuchi Y, Sato Y, Aiyama H, Kasuya H, Barfod BE. Stereotactic Radiosurgery for Patients with 10 or More Brain Metastases. *Prog Neurol Surg* 2019;34:110–24.
- [58] Yamamoto M, Serizawa T, Shuto T, Akabane A, Higuchi Y, Kawagishi J, et al. Stereotactic radiosurgery for patients with multiple brain metastases (JLKG0901): a multi-institutional prospective observational study. *Lancet Oncol* 2014;15(4):387–95.
- [59] Sahgal A, Aoyama H, Kocher M, Neupane B, Collette S, Tago M, et al. Phase 3 trials of stereotactic radiosurgery with or without whole-brain radiation therapy for 1 to 4 brain metastases: individual patient data meta-analysis. *Int J Radiat Oncol Biol Phys* 2015;91(4):710–7.
- [60] Kondziolka D, Kano H, Harrison GL, Yang H-C, Liew DN, Niranjan A, et al. Stereotactic radiosurgery as primary and salvage treatment for brain metastases from breast cancer. *Clinical article J Neurosurg* 2011;114(3):792–800.
- [61] Perez JL, Ozpinar A, Kano H, Phan B, Niranjan A, Lunsford LD. Salvage Stereotactic Radiosurgery in Breast Cancer Patients with Multiple Brain Metastases. *World Neurosurg* 2019;125:e479–86.
- [62] Brown PD, Ballman KV, Cerhan JH, Anderson SK, Carrero XW, Whitton AC, et al. Postoperative stereotactic radiosurgery compared with whole brain radiotherapy for resected metastatic brain disease (NCCTG N107C/CEC-3): a multicentre, randomised, controlled, phase 3 trial. *Lancet Oncol* 2017;18(8):1049–60.
- [63] Mahajan A, Ahmed S, McAleer MF, Weinberg JS, Li J, Brown P, et al. Post-operative stereotactic radiosurgery versus observation for completely resected brain metastases: a single-centre, randomised, controlled, phase 3 trial. *Lancet Oncol* 2017;18(8):1040–8.
- [64] Redmond KJ, De Salles AAF, Fariselli L, Levivier M, Ma L, Paddick I, et al. Stereotactic Radiosurgery for Postoperative Metastatic Surgical Cavities: A Critical Review and International Stereotactic Radiosurgery Society (ISRS) Practice Guidelines. *Int J Radiat Oncol Biol Phys* 2021;111(1):68–80.
- [65] von Minckwitz G, Huang C-S, Mano MS, Loibl S, Mamounas EP, Untch M, et al. Trastuzumab Emtansine for Residual Invasive HER2-Positive Breast Cancer. *N Engl J Med* 2019;380(7):617–28.
- [66] Stavrou E, Winer EP, Lin NU. How we treat HER2-positive brain metastases. *ESMO Open* 2021;6(5):100256.
- [67] Piccart-Gebhart M, Holmes E, Baselga J, de Azambuja E, Dueck AC, Viale G, et al. Adjuvant Lapatinib and Trastuzumab for Early Human Epidermal Growth Factor Receptor 2-Positive Breast Cancer: Results From the Randomized Phase III Adjuvant Lapatinib and/or Trastuzumab Treatment Optimization Trial. *J Clin Oncol* 2016;34(10):1034–42.
- [68] Chan A, Moy B, Mansi J, Ejlersten B, Holmes FA, Chia S, et al. Final Efficacy Results of Neratinib in HER2-positive Hormone Receptor-positive Early-stage Breast Cancer From the Phase III ExteNET Trial. *Clin Breast Cancer* 2021;21(1):80–91.
- [69] von Minckwitz G, Procter M, de Azambuja E, Zardavas D, Benyunes M, Viale G, et al. Adjuvant Pertuzumab and Trastuzumab in Early HER2-Positive Breast Cancer. *N Engl J Med* 2017;377(2):122–31.
- [70] Swain SM, Baselga J, Miles D, Im Y-H, Quah C, Lee LF, et al. Incidence of central nervous system metastases in patients with HER2-positive metastatic breast cancer treated with pertuzumab, trastuzumab, and docetaxel: results from the randomized phase III study CLEOPATRA. *Ann Oncol* 2014;25(6):1116–21.
- [71] Bartsch R, Berghoff AS, Furtner J, Marhold M, Bergen ES, Roeder-Schur S, et al. Trastuzumab deruxtecan in HER2-positive breast cancer with brain metastases: a single-arm, phase 2 trial. *Nat Med* 2022;28(9):1840–7.
- [72] Krop IE, Lin NU, Blackwell K, Guardino E, Huober J, Lu M, et al. Trastuzumab emtansine (T-DM1) versus lapatinib plus capecitabine in patients with HER2-positive metastatic breast cancer and central nervous system metastases: a retrospective, exploratory analysis in EMILIA. *Ann Oncol* 2015;26(1):113–9.
- [73] García-Alvarez A, Papakonstantinou A, Oliveira M: Brain Metastases in HER2-Positive Breast Cancer: Current and Novel Treatment Strategies. *Cancers (Basel)* 2021, 13.
- [74] Morikawa A, Peereboom DM, Thorsheim HR, Samala R, Balyan R, Murphy CG, et al. Capecitabine and lapatinib uptake in surgically resected brain metastases from metastatic breast cancer patients: a prospective study. *Neuro Oncol* 2015;17(2):289–95.
- [75] Lin NU, Diéras Véronique, Paul D, Lossignol D, Stemmler H-J, et al. Multicenter phase II study of lapatinib in patients with brain metastases from HER2-positive breast cancer. *Clin Cancer Res* 2009;15(4):1452–9.
- [76] Bachelot T, Romieu G, Campone M, Diéras V, Cropet C, Dalenc F, et al. Lapatinib plus capecitabine in patients with previously untreated brain metastases from HER2-positive metastatic breast cancer (LANDSCAPE): a single-group phase 2 study. *Lancet Oncol* 2013;14(1):64–71.
- [77] Metro G, Foglietta J, Russillo M, Stocchi L, Vidiri A, Giannarelli D, et al. Clinical outcome of patients with brain metastases from HER2-positive breast cancer treated with lapatinib and capecitabine. *Ann Oncol* 2011;22(3):625–30.
- [78] Sutherland S, Ashley S, Miles D, Chan S, Wardley A, Davidson N, et al. Treatment of HER2-positive metastatic breast cancer with lapatinib and capecitabine in the lapatinib expanded access programme, including efficacy in brain metastases—the UK experience. *Br J Cancer* 2010;102(6):995–1002.
- [79] Freedman RA, Gelman RS, Anders CK, Melisko ME, Parsons HA, Cropp AM, et al. TBCRC 022: A Phase II Trial of Neratinib and Capecitabine for Patients With

- Human Epidermal Growth Factor Receptor 2-Positive Breast Cancer and Brain Metastases. *J Clin Oncol* 2019;37(13):1081–9.
- [80] Lee A. Tucatinib: First Approval. *Drugs* 2020;80(10):1033–8.
- [81] Modi S, Jacot W, Yamashita T, Sohn J, Vidal M, Tokunaga E, et al. Trastuzumab Deruxtecan in Previously Treated HER2-Low Advanced Breast Cancer. *N Engl J Med* 2022;387(1):9–20.
- [82] Wilking N, Bucsics A, Kandolf Sekulovic L, Kobelt G, Laslop A, Makaroff L, et al. Achieving equal and timely access to innovative anticancer drugs in the European Union (EU): summary of a multidisciplinary CECOG-driven roundtable discussion with a focus on Eastern and South-Eastern EU countries. *ESMO Open* 2019;4(6): e000550.