

This is an Open Access document downloaded from ORCA, Cardiff University's institutional repository: <https://orca.cardiff.ac.uk/id/eprint/162380/>

This is the author's version of a work that was submitted to / accepted for publication.

Citation for final published version:

Ahmed, Hany Mohamed Aly, Rossi Fedele, Giampiero and Dummer, Paul Michael Howell 2023. Critical analysis of a new system to classify root and canal morphology — A systematic review. Australian Endodontic Journal 10.1111/aej.12780

Publishers page: <https://doi.org/10.1111/aej.12780>

Please note:




Changes made as a result of publishing processes such as copy-editing, formatting and page numbers may not be reflected in this version. For the definitive version of this publication, please refer to the published source. You are advised to consult the publisher's version if you wish to cite this paper.

This version is being made available in accordance with publisher policies. See <http://orca.cf.ac.uk/policies.html> for usage policies. Copyright and moral rights for publications made available in ORCA are retained by the copyright holders.



SCHOLARLY REVIEW

Critical analysis of a new system to classify root and canal morphology — A systematic review

Hany Mohamed Aly Ahmed BDS, HDD (Endo), PhD, FICD, MDTFed (RCSEd),
FPFA, FADI¹  | Giampiero Rossi-Fedele DDS, MClintDent, PhD²  |
Paul Michael Howell Dummer BDS, MScD, PhD, DDSc³ 

¹Department of Restorative Dentistry,
Faculty of Dentistry, Universiti Malaya,
Kuala Lumpur, Malaysia

²Adelaide Dental School, Adelaide
University, Adelaide, South Australia,
Australia

³School of Dentistry, College of
Biomedical and Life Sciences, Cardiff
University, Cardiff, UK

Correspondence

Giampiero Rossi-Fedele, Adelaide
Dental School, The University of
Adelaide, 10th Floor, Adelaide Health
and Medical Sciences Building, Corner
North Terrace and George Street,
Adelaide, SA 5000, Australia.

Email: giampiero.rossi-fedele@adelaide.edu.au

Funding information

Universiti Malaya, Grant/Award
Number: GPF017A-2020

Abstract

A novel system to classify root and canal morphology was recently introduced (Ahmed et al. 2017). This systematic review aimed to answer the following research question: Does the Ahmed et al. system provide a more accurate and practical classification of root and canal anatomy compared to other classifications? A literature search was conducted in Google Scholar, Scopus and Wiley Online Library to identify the citation counts for the article entitled 'A new system for classifying root and root canal morphology; doi.org/10.1111/iej.12685'. After removal of duplicates and unrelated articles, 15 studies were included and analysed. All studies compared the Ahmed et al. system with the Vertucci classification. Results revealed that both systems were able to classify simple canal configurations in single-rooted anterior and premolar teeth, disto-buccal and palatal roots of maxillary molars. However, the Ahmed et al. system provided more accurate and comprehensive categorisations of single-rooted teeth with complex canal anatomy, multi-rooted maxillary and mandibular premolars and the mesio-buccal root of maxillary molars. Further evidence on the utility of the Ahmed et al. system is required using other diagnostic devices especially in molars.

KEYWORDS

Ahmed et al. classification, root canal anatomy, Vertucci classification, morphology

INTRODUCTION

A comprehensive understanding of root and canal anatomy is essential before carrying out endodontic procedures [1]. Root and canal morphology have been the subject of many studies using a wide variety of methodological procedures ranging from examination of ground extracted teeth to the more recent 3D imaging techniques such as cone-beam computed tomography (CBCT) and micro-computed tomography (micro-CT) [2–6]. This has

resulted in an exponential expansion in the knowledge generated on root and canal anatomy as well as increased awareness of potential challenges and limitations of endodontic treatment procedures [7].

Classifications of human anatomy and disease play a central role in the medical and dental sciences, where they are used not only as a way to organise knowledge, but also as a valid tool for defining characteristic features of a given subject in an accurate and practical manner [8]. For many years, the classification of tooth

This is an open access article under the terms of the [Creative Commons Attribution-NonCommercial](https://creativecommons.org/licenses/by-nc/4.0/) License, which permits use, distribution and reproduction in any medium, provided the original work is properly cited and is not used for commercial purposes.

© 2023 The Authors. *Australian Endodontic Journal* published by John Wiley & Sons Australia, Ltd on behalf of Australian Society of Endodontology Inc.

anatomy described by Vertucci [2] (with or without its supplemental configurations [9]) has been the most commonly used system to categorise root canal types using a small range of Roman numerals, for example, I–VIII. However, the morphological characteristics of root canal systems are highly complex, and many canal configurations had to be described as ‘non-classifiable’ when using that system [10–13]. In fact, in one study, as many as 13% of specimens could not be categorised using the Vertucci system [14].

In 2017, a novel coding system for classifying root and canal anatomy was proposed [15]. This new system provides information on tooth notation, number of roots and additional details on root canal configuration in a single code. In essence, the coding system is able to define the number of roots in every tooth type, and describes the main features of their root canal configuration [15]. The system has been reported to be accurate when classifying root and canal anatomy in both laboratory and clinical studies as well as in routine clinical practice [16–20].

Analysis of the literature related to this relatively new classification system is essential to assess its accuracy, practicability and to identify its strengths and potential limitations. This systematic review aimed to evaluate the evidence available for the application of the new classification system introduced by Ahmed et al. [15] compared to other classification systems in studies related to root and canal anatomy.

METHODOLOGY

The protocol of the current systematic review is registered in the open science framework registry (OSF) (doi.org/10.17605/OSF.IO/XA56W).

Research question

Does the new coding system of Ahmed et al. [15] provide a more accurate and practical characterisation of root and canal anatomy compared to other classifications?

Literature search methodology

The citation counts listed for the article entitled ‘A new system for classifying root and root canal morphology—International Endodontic Journal 2017; 50: 761–770—DOI: [10.1111/iej.12685](https://doi.org/10.1111/iej.12685)’ in three search databases (Google Scholar, Scopus and Wiley online library) were identified. Hand searches in the “Early online” and “accepted for publications” sections of the International Endodontic Journal, Journal of Endodontics, Australian

Endodontic Journal, European Endodontic Journal and Saudi Endodontic Journal websites were carried out up to 31 December 2022.

Inclusion criteria

Original research articles written in English that compared the new coding system by Ahmed et al. [15] with other classification systems were included.

Exclusion criteria

Letters, commentaries, editorials, case reports/series, narrative or scoping or systematic reviews were excluded. Studies published in languages other than English were also excluded.

Study selection

The study selection process was performed in two phases. Phase 1: The titles and abstracts of the retrieved documents were assessed independently and in duplicate by two reviewers (HMAA, GRF). Papers that did not meet the criteria were excluded. Phase 2: The two reviewers evaluated the full texts of the included studies. Disagreements were resolved by discussion between the reviewers.

Data extraction

Data extraction was performed by two reviewers (HMAA & GRF). The following details were extracted for each study: name of the first author, year published, study design (imaging system), classifications used, tooth type and the number of teeth included and the findings presented by the authors using the classification systems involved.

RESULTS

The literature search resulted in 458 publications. After removal of duplicates, a total of 229 were screened. Studies not related to root and canal anatomy were excluded leaving a total of 15 studies that fulfilled the inclusion criteria [8, 17, 18, 21–32]. The PRISMA 2000 flowchart summarises the search strategy (Figure 1). The excluded studies are presented in Supplementary Material A. Tables 1–5 summarise the details of the included studies. Out of the 15 studies, three examined the anatomy of maxillary anterior teeth in patients (CBCT clinical studies) (21–23), five

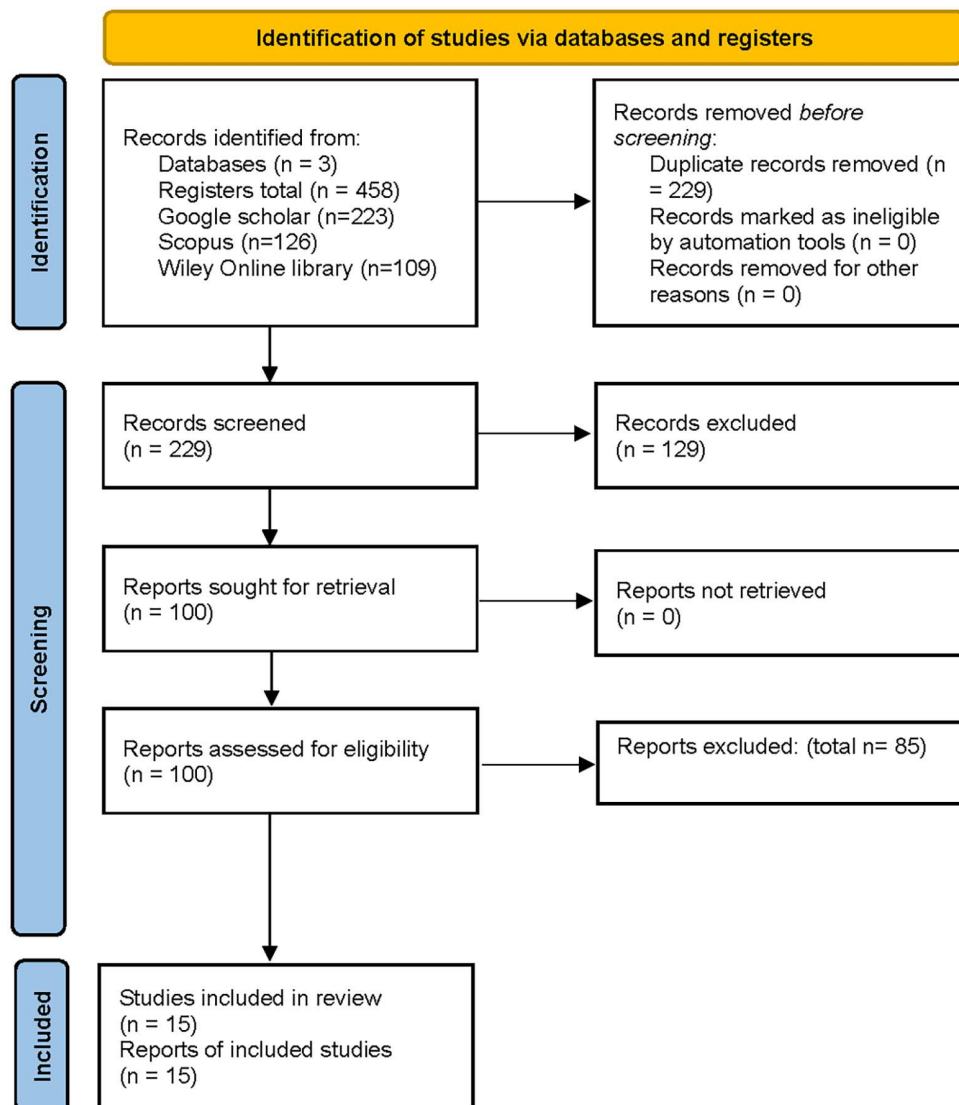


FIGURE 1 PRISMA flowchart of the systematic review.

examined mandibular anterior teeth (four clinical CBCT (21-24), and one *ex vivo* micro-CT (25) on extracted teeth), four studies examined maxillary premolar teeth (three clinical CBCT (18, 26, 27), and one *ex vivo* CBCT (17) on extracted teeth), two studies examined mandibular premolar teeth (one clinical CBCT (29), and one *ex vivo* micro-CT (28) on extracted teeth) and three studies examined maxillary molar teeth (clinical CBCT) (30-32). Interobserver agreement (Cohen's *k*) scores performed for selection of studies was calculated as 0.871—almost perfect agreement.

In terms of application, a total of 10 out of 15 studies compared the coding system of Ahmed et al. [15] with the original Vertucci classification (eight types) in six population groups (Brazilian, Indian, Polish, Saudi Arabian, South African) (Tables 1-5). Four studies compared the system with the Vertucci classification and its supplementary configuration types [9] (23 types) in 4 populations (Malaysian, Egyptian, Chilean and South African)

(Tables 1-5). One study compared the feedback of final year undergraduate dental students in Malaysian dental schools on the application of both systems in teaching and clinical practice [8].

Root and canal anatomy in the anterior dentition

Maxillary anteriors

Studies involved in this review reported that both Vertucci and Ahmed et al. systems classified maxillary incisors adequately in which Vertucci type I (Ahmed et al. code, ¹MaxA¹) was evident in more than 98% of the study samples [21-23]. Other canal configurations were classified with both systems (mainly maxillary canines) (Table 1). One study reported 0.5% of

TABLE 1 Studies using Vertucci and Ahmed et al. classifications in maxillary anteriors.

Author, year	Population and study model	Sample size and classification used	Main findings
Karobari et al. [21]	Malaysian	Central incisor ($n = 1636$) Lateral incisor ($n = 1651$) Canine ($n = 1692$)	According to Ahmed et al. system and Vertucci classification, code $^1\text{MaxA}^1$ and type I represented more than 99% of the samples
	CBCT (Clinical)	Vertucci [2]/supplementary Sert and Bayirli [9] and Ahmed et al. [15]	Codes: $^1\text{MaxA}^{2-1}$, $^1\text{MaxA}^{1-2}$, $^1\text{MaxA}^{1-2-1}$, $\text{MaxA}^{1-2-1-2}$ (Vertucci Types II, III, V and VII) were also identified in the anterior teeth Conclusion: Both systems provided an accurate presentation of the root canal anatomy in maxillary anteriors
Buchanan et al. [22] ^a	South African	Central incisor ($n = 387$) Lateral incisor ($n = 401$)	Code $^1\text{MaxA}^1$ and Vertucci type I represented 100%, 99.5% and 94.9% in maxillary central incisors, lateral incisors and canines, respectively
	CBCT (Clinical)	Canine ($n = 373$) Vertucci [2] and Ahmed et al. [15]	Two maxillary lateral incisors (0.5%) were considered Vertucci non-classifiable for teeth with dental anomalies (Dens Invaginatus [DI]). Codes (DI^{II}) $^1\text{MaxA}^1$ and (2DI^{III}) $^1\text{MaxA}^2$ were used for Ahmed et al. coding system 3.1% of maxillary canines showed code $^1\text{MaxA}^{1-2-1}$ (Vertucci type III). Codes: $^1\text{MaxA}^{2-1}$, $^1\text{MaxA}^{1-2}$, $^1\text{MaxA}^{1-2-1-2}$, MaxA^{2-1-2} (Vertucci Types II, V, VI and VII) were also identified in maxillary canines Conclusion: The two classifications were found to be comparable for evaluation of permanent anterior teeth. Complex configurations were better described using the new system
Iqbal et al. [23]	Saudi Arabian	Central incisor ($n = 558$)	Code $^1\text{MaxA}^1$ (Vertucci type I) was defined in about 98% of the samples
	CBCT (Clinical)	Lateral incisor ($n = 557$) Canine ($n = 559$) Vertucci [2] and Ahmed et al. [15]	Code $^1\text{MaxA}^{1-2-1}$ (Vertucci Types III) was also identified in about 2% of the anterior teeth Conclusion: Both systems classified the entire study samples

^aThe study used complementary codes from Ahmed and Dummer for dental anomalies [33] MaxA: Maxillary anterior.

teeth using the Vertucci system as non-classifiable for maxillary lateral incisors as a consequence of *Dens Invaginatus* [22], which was classified using the Ahmed et al. system with complementary codes for dental anomalies [33].

Mandibular anteriors

For mandibular anteriors, the studies involved in this review presented a wide range of root and canal anatomical variations (Table 2). Nevertheless, in CBCT clinical prevalence studies, both the Vertucci and Ahmed et al. classification systems were able to define the root canal anatomy (Table 2). However, some samples (up to 2.2%) were categorised as non-classifiable using the Vertucci system, even when the supplementary configuration types were involved alongside the original categories [21] (Figure 2) (Table 2). The percentage of Vertucci non-classifiable types was more evident when micro-CT devices were used for identification

with one study reporting that 6.67% of the samples did not fit into the original Vertucci classification [25].

Vertucci type V was the code used to describe both double- and single-rooted mandibular canines (ManC) having a 1–2 canal configuration. On the other hand, for the Ahmed et al. system, code $^2\text{ManC B}^1 \text{L}^1$ (level of the orifice at the coronal bifurcation—that is, no common canal initially) was used for double-rooted mandibular canines, and code $^1\text{ManC}^{1-2}$ was used for single-rooted mandibular canines with a single canal that divides into two more apically [level of the orifice is at the cemento-enamel junction] [21].

Root and canal anatomy in premolar teeth

Maxillary premolars

Similar to the anterior dentition, clinical CBCT studies reported that both the Vertucci and Ahmed et al. systems

TABLE 2 Studies using Vertucci and Ahmed et al. classifications in mandibular anteriors.

Author, year	Population and study model	Sample size and classification used	Main findings
Karobari et al. [21]	Malaysian CBCT (Clinical)	Central incisor ($n = 1692$) Lateral incisor ($n = 1701$) Canine ($n = 1702$) Vertucci [2]/ supplementary Sert and Bayirli [9] and Ahmed et al. [15]	Mandibular central incisors: $^1\text{ManA}^1$ (Vertucci type I) (65.2%) $^1\text{ManA}^{1-2-1}$ (Vertucci type III) (30.8%) Mandibular lateral incisors: $^1\text{ManA}^1$ (Vertucci type I) (45%) $^1\text{ManA}^{1-2-1}$ (Vertucci type III) (51%) Mandibular canines: $^1\text{ManA}^1$ (Vertucci type I) (90.7%) $^1\text{ManA}^{1-2-1}$ (Vertucci type III) (8.2%) Several variations non-classifiable using Vertucci's system were classified using Ahmed et al. system. These include codes $^1\text{ManA}^{2-1-2-1}$ (2.1%) and $^1\text{ManA}^{2-1-2-1-2-1}$ (0.1%) Double-rooted mandibular canines (0.3%) Both single and double rooted teeth were classified as Vertucci type V, while Ahmed et al. system— $^1\text{ManA}^{1-2}$ for single rooted and $^2\text{ManA} \text{La}^1 \text{Li}^1$ for double rooted Conclusion: Both systems were able to classify the root canal anatomy in the permanent anterior teeth. However, complex canal configurations and double-rooted teeth were more accurately described using the Ahmed et al. system
Alobaid et al. [24]	Saudi Arabian CBCT (Clinical)	Central incisor ($n = 1260$) Vertucci [2] and Ahmed et al. [15]	According to Ahmed et al. classification system, the most common code (82.6%) was $^1\text{ManA}^1$ (Vertucci type I), followed by $^1\text{ManA}^{1-2-1}$ (Vertucci type III; 13%). Other codes/types were identified with percentages less than 5% Conclusion: Both systems classified the entire study samples
Buchanan et al. [22]	South African CBCT (Clinical)	Central incisor ($n = 387$) Lateral incisor ($n = 387$) Canine ($n = 386$) Vertucci [2] and Ahmed et al. [15]	Mandibular lateral incisors: $^1\text{ManA}^1$ (Vertucci type I) (63.3%) $^1\text{ManA}^{1-2-1}$ (Vertucci type III) (33.3%) $^1\text{ManA}^{2-1}$ (Vertucci type II) (2.4%) Mandibular central incisors: $^1\text{ManA}^1$ (Vertucci type I) (66.1%) $^1\text{ManA}^{1-2-1}$ (Vertucci type III) (29.7%) $^1\text{ManA}^{2-1}$ (Vertucci type II) (2.1%) Mandibular canines: $^1\text{ManA}^1$ (Vertucci type I) (93.8%) $^1\text{ManA}^{1-2-1}$ (Vertucci type III) (5.45%) Rarely, $^1\text{ManA}^{1-2}$, $^1\text{ManA}^{1-2-1-2}$, $^1\text{ManA}^{2-1-2}$ and $^{1\text{BR}}\text{ManA}^{1-2}$ configurations were observed Conclusion: Both systems are adequate and comparable for the description of root canal anatomy
Iqbal et al. [23]	Saudi Arabian CBCT (Clinical)	Central incisor ($n = 570$) Lateral incisor ($n = 570$) Canine ($n = 570$) Vertucci [2] and Ahmed et al. [15]	Mandibular central incisors: $^1\text{ManA}^1$ (Vertucci type I) (85.8%) $^1\text{ManA}^{1-2-1}$ (Vertucci type III) (13%) $^1\text{ManA}^{1-2}$ (Vertucci type V) (1.2%) Mandibular lateral incisors: $^1\text{ManA}^1$ (Vertucci type I) (68.6%) $^1\text{ManA}^{1-2-1}$ (Vertucci type III) (25.3%) $^1\text{ManA}^{1-2}$ (Vertucci type V) (6.1%) Mandibular canines: $^1\text{ManA}^1$ (Vertucci type I) (90.4%) $^1\text{ManA}^{1-2-1}$ (Vertucci type III) (7%) $^1\text{ManA}^{1-2}$ (Vertucci type V) (2.5%) One unclassifiable Vertucci canal configuration— $^1\text{ManA}^{1-2-1-2-1}$ Except for one tooth, both systems classified the entire study samples.

(Continues)

TABLE 2 (Continued)

Author, year	Population and study model	Sample size and classification used	Main findings
Villa et al. [25]	Brazilian Micro-CT (Laboratory)	Mandibular incisor (n = 165) Vertucci [2] and Ahmed et al. [15]	The majority of ManA had a single root canal (52.1%). Type III Vertucci and ¹ ManA ¹⁻²⁻¹ Ahmed et al. were common (20%). Other types such as ¹ ManA ²⁻¹ (Vertucci type II) (6.1%), ¹ ManA ¹⁻² (Vertucci type V) (4.9%), ¹ ManA ¹⁻²⁻¹⁻² (Vertucci type VII) (4.2%), ¹ ManA ² (Vertucci type IV) (3%) and others (3%) were identified 6.67% of canal configurations did not fit into Vertucci classification, which were classified using Ahmed coding system Conclusion: Ahmed et al. classification was able to classify the entire samples studied while 11 samples did not fit Vertucci's classification

ManA: Mandibular anterior, BR: Bifid root.

TABLE 3 Studies using Vertucci and Ahmed et al. classifications in maxillary premolars.

Author, year	Population and study model	Tooth type and classification used	Main findings
Saber et al. [17]	Egyptian CBCT (Extracted teeth)	Maxillary premolars (1st = 358) (2nd = 342) Vertucci [2] and its supplemental configurations Sert and Bayirli [9] and Ahmed et al. [15]	According to the Vertucci classification: Canal type IV was the most common in both 1st and 2nd premolars, and canal types VIII and XV were used to classify teeth with three canals According to Ahmed et al. classification: ² FP B ¹ P ¹ was the most common for 1st premolars ² SP B ¹ P ¹ , ¹ SP ² and ¹ SP ²⁻¹ codes were the most common for 2nd premolars Codes ² MP B ¹⁻² P ¹ , ² MP B ¹⁻²⁻¹⁻² P ¹ and ³ MP ¹ (MB ¹ DB ¹) P ¹ were used to describe teeth with 3 canals Conclusion: The new system for classifying canal morphology describes the root and canal configurations in a more accurate and practical manner compared to the Vertucci classification
Buchanan et al. [18] ^a	South African CBCT (Clinical)	Maxillary premolars (1st = 316) (2nd = 285) Vertucci [2] and Ahmed et al. [15]	According to Vertucci classification: Canal type IV was most prevalent in the 1st premolars Canal type I was the most common for 2nd premolars Canal type VIII was used to describe teeth with three canals According to Ahmed et al. classification: ² MB B ¹ P ¹ was the most common configuration for 1st premolars ¹ MP ¹ was the most common for 2nd premolars Codes ² MP B ² P ¹ , ³ MP MB ¹ DB ¹ P ¹ , ³ MP ¹ (MB ¹ DB ¹) P ¹ and (RF ¹) ³ MP MB//DB ¹⁻²⁻¹ P ¹ were used to describe teeth with 3 canals Conclusion: Both classification systems adequately describe maxillary premolar anatomy; however, the system proposed by Ahmed et al. describe complex teeth more accurately
Olczak et al. [26]	Polish CBCT (Clinical)	Maxillary 1st premolars (n = 350) Vertucci [2] and Ahmed et al. [15]	According to Vertucci classification: Type IV was the most common for 1st premolars (78.5%), type II (8.6%), type V (5.1%), type VIII (2.9%), type III (2.6%) and type I (1.7%). Type VII was found in two teeth (0.6%) According to Ahmed et al. classification: ² FP B ¹ P ¹ was the most common (65.4%) followed by ¹ FP ² (13.1%), ¹ FP ²⁻¹ (8.6%), ² FP ¹ B ¹ P ¹ (3.4%), ¹ FP ¹⁻²⁻¹ and ³ FP MB ¹ DB ¹ P ¹ (2.6% each). ¹ FP ¹ and ¹ FP ¹⁻² were less common (1.7% each). ¹ FP ¹⁻²⁻¹⁻² was present in two teeth (0.6%) and ² FP B ¹⁻² P ¹ in one tooth (0.3%) Conclusion: The new system for classifying canal morphology based on Ahmed et al. is more accurate than the Vertucci classification

TABLE 3 (Continued)

Author, year	Population and study model	Tooth type and classification used	Main findings
Olczak et al. [27]	Polish	Maxillary 2nd premolars	According to Vertucci classification:
	CBCT (Clinical)	(n = 324)	Type I was the most common for 2nd premolars (59.6%), type IV (15.7%), type II (9.3%), type V (7.1%), type III (6.2%) and types VI, VII were found in three teeth (0.9% each). Type VIII found in one tooth
		Vertucci [2] and Ahmed et al. [15]	<p>According to Ahmed et al. classification:</p> <p>¹SP¹ was the most common (59.6%) followed by ¹SP²⁻¹ and ²SP B¹ P¹ (9.3% each), ¹SP¹⁻²⁻¹ (6.2%), ¹SP² (6.5%) and ¹SP¹⁻² (5.6%)</p> <p>²SP ¹B¹ P¹, ¹SP¹⁻²⁻¹⁻² and ¹SP²⁻¹⁻² were less common</p> <p>²SP B¹⁻² P¹ in one tooth (0.3%)</p> <p>Conclusion: The new system for classifying canal anatomy based on Ahmed et al. is more accurate and practical than Vertucci classification</p>

^astudy used complementary codes from Ahmed and Dummer for dental anomalies [33].

MP: Maxillary premolar, FP: First premolar, SP: Second premolar, B: Buccal, P: Palatal, MB: Mesio-buccal, DB: Disto-buccal

TABLE 4 Studies using Vertucci and Ahmed et al. classifications in mandibular premolars.

Author, year	Population and study model	Tooth type and classification used	Main findings
Sierra-Cristancho et al. [28]	Chilean	Mandibular first premolars	According to Vertucci classification:
	MicroCT (extracted teeth)	(n = 186)	Type I configuration is the most common (65.05%) followed by type V (24.19%) and type III (5.38%). Non-classifiable types (0.54%)
		Vertucci [2] and its supplemental configurations Sert and Bayirli [9], and Ahmed et al. [15]	<p>According to Ahmed et al. classification:</p> <p>Code ¹MP¹ was the most common (65.05%), followed by ¹MP¹⁻² (24.19%), ¹MP¹⁻²⁻¹ (5.38%) and other types such as ¹MP¹⁻³⁻²⁻¹, ¹MP¹⁻³, ²MP ¹M¹D² (5.38%)</p> <p>Conclusion: Ahmed et al. criteria allowed us to classify the internal anatomy of the root canal in a more precise and practical way than Vertucci's criteria</p>
Buchanan et al. [29] ^a	South African	Mandibular premolars	Mandibular 1st premolars:
	CBCT (Clinical)	(1st = 386) (2nd = 386)	<p>According to Vertucci classification:</p> <p>Type I configuration is the most common (48.5%) followed by type V (28%) and type III (9.2%). Other Vertucci types (6.3%). Vertucci unclassifiable (8.0%)</p>
		Vertucci [2] and Ahmed et al. [15]	<p>According to Ahmed et al. classification:</p> <p>Code ¹FP¹ is the most common (48.5%) followed by ¹FP¹⁻², (PGG^{III})¹FP¹⁻² and (PGG^{III}, CSC^I)¹FP¹⁻², (PGG^{III}, CSC^{II})¹FP¹⁻² (total 28.6%)</p> <p>Codes ¹FP¹⁻²⁻¹ (9.1%), (PGG^{III}, CSC^{III})¹FP¹⁻³⁻² (3.1%), ²FP ¹B¹ L¹, (PGG^{III})¹FP² (1.6% each) and other types (7.5%)</p> <p>Mandibular 2nd premolars:</p>

(Continues)

TABLE 4 (Continued)

Author, year	Population and study model	Tooth type and classification used	Main findings
			<p>Type I configuration is the most common (81.3%) followed by type III (6.1%) and type V (3.1%). Other Vertucci types (3.3%). Vertucci unclassifiable (6.2%)</p> <p>According to Ahmed et al. classification:</p> <p>Code ¹FP¹ is the most common (81.3%) followed by ¹FP¹⁻²⁻¹ (total 5.6%), ¹FP¹⁻² (total 1.8%), (PGG^{III}, CSC^{III})¹FP¹⁻³⁻¹ (1.55%) and other codes (≤1% each)</p> <p>Conclusion: The Ahmed et al. system proved superior to the Vertucci classification for reporting complex configurations and anatomical variations, although a greater number of unique categories were created</p>

^aThe Study used complementary codes from Ahmed and Dummer [33] for dental anomalies.

TABLE 5 Studies using Vertucci and Ahmed et al. classifications in maxillary molars.

Author, year	Population and study model	Tooth type and classification used	Main findings
Mirza et al. [30]	Saudi Arabian CBCT (Clinical)	Maxillary molars (1st = 681) (2nd = 651) Vertucci [2] and Ahmed et al. [15]	<p>According to Vertucci Classification:</p> <p>Maxillary first molars: MB root—Type II (51.7%), Type IV (32.2%), Type I (15.3%) and Type III (0.9%)</p> <p>Each of DB and P roots is type I</p> <p>Maxillary second molars: MB root—Type I (55.2%), Type II (20.6%) and Type IV (24.3%)</p> <p>Each of DB and P roots is type I</p> <p>According to Ahmed et al. classification:</p> <p>Maxillary first molars: ³MaxM MB²⁻¹ DB¹ P¹ (51.7%) ³MaxM MB² DB¹ P¹ (32.2%) ³MaxM MB¹ DB¹ P¹ (15.3%) ³MaxM MB¹⁻²⁻¹ DB¹ P¹ (0.9%)</p> <p>Maxillary second molars: ³MaxM MB¹ DB¹ P¹ (53.3%) ³MaxM MB² DB¹ P¹ (24.3%) ³MaxM MB²⁻¹ DB¹ P¹ (20.4%)</p> <p>In addition to other codes related to single, double, four and five-rooted second molars</p>
Rosaline et al. [31]	Indian CBCT (Clinical)	Maxillary second molars (n = 500) Vertucci [2] and Ahmed et al. [15]	<p>According to Vertucci Classification:</p> <p>MB root—Type I (67.9%), Type II (28.6%) and Type IV (3.2%)</p> <p>Each of DB and P roots is type I</p> <p>According to Ahmed et al. classification:</p> <p>³MaxM MB¹ DB¹ P¹ (67.9%) ³MaxM MB²⁻¹ DB¹ P¹ (28.6%) ³MaxM MB² DB¹ P¹ (3.2%)</p> <p>In addition to other types/codes related to single, double and four-rooted second molars</p> <p>Conclusion: The ability to use the Ahmed et al. classification as an 'integrated system' helped us to describe common and unusual variations of the root and canal morphology in a simpler format</p>

TABLE 5 (Continued)

Author, year	Population and study model	Tooth type and classification used	Main findings
Buchanan et al. [32]	South African CBCT (Clinical)	Maxillary second molars (<i>n</i> = 386) Vertucci [2] and its supplemental configurations Sert and Bayirli [9] and Ahmed et al. [15]	<p>According to Vertucci classification (three-rooted teeth)</p> <p>The most common configuration in MB roots was Type I (32.6%), followed by Type IV (19.7%), III (17.4%), II (11.3%) and V (7.8%). 3.5% of MB roots were considered unclassifiable</p> <p>The majority of DB roots (94.9%), as well as P roots (98.4%) roots, were single canal/Type I</p> <p>Non-classifiable types were identified in 3.2% and 0.5% in the DB and P roots, respectively</p> <p>According to Ahmed et al. classification (three-rooted teeth)</p> <p>The most common configuration was ³MSM MB¹ DB¹ P¹ (28.9%), followed by ³MSM MB² DB¹ P¹ (20.0%), ³MSM MB¹⁻²⁻¹ DB¹ P¹ (16.6%), ³MSM MB²⁻¹ DB¹ P¹ (11.4%) and ³MSM MB¹⁻² DB¹ P¹ (5.4%)</p> <p>A large number of codes with a small number of representatives were seen in the remaining maxillary second molars</p> <p>Other variants were described using both systems in single and double rooted teeth</p> <p>Ahmed & Dummer [33] classification for anomalies was used to classify second molars with fused roots and C-shaped canals</p> <p>Conclusion: The Ahmed et al. classification provided a better overall description of the morphology. In contrast to the Vertucci classification, it was able to classify all teeth, regardless of complexity</p>

MaxM: Maxillary molar, MB: Mesio-buccal, DB: Disto-buccal, P: Palatal, MSM: Maxillary second molar

classified root canals in single-rooted maxillary premolars in a similar manner (Table 3). In contrast, double-rooted maxillary premolars were classified differently compared to Vertucci since the Ahmed et al. classification considers the number of roots (Figure 3). For instance, the prevalence of Vertucci types I, II and III canals had the same percentages as the Ahmed et al. codes ¹MaxP¹, ¹MaxP²⁻¹, ¹MaxP¹⁻²⁻¹, respectively (17, 26, 27) (Table 3). However, the prevalence of Vertucci type IV canals was different from the Ahmed et al. classification since this type of canal system can present in single or double roots. Therefore, the codes for the Ahmed et al. classification can be either ¹MaxP² (for single rooted) or ²MaxP B¹ P¹ (for double rooted), [17, 18, 26, 27]. Vertucci type V is another example of the difference between Vertucci and Ahmed et al. classifications in which this type can be presented in two forms in single- (¹MaxP¹⁻²) and double-rooted teeth (²MaxP ¹B¹ P¹—with a common canal before the bifurcation) [18, 27].

Studies included in this review also revealed differences in the presentation of maxillary premolars with three canals, which are usually classified as type VIII when using the Vertucci system. This configuration was allocated different codes using the Ahmed et al. system that varied according to the number of roots, such as code ³MaxP MB¹ DB¹ P¹ [17, 26]—for three rooted variants, ³MaxP ¹(MB¹ DB¹) P¹ [17]—for three rooted variants with a common

buccal canal to the MB and DB roots and ²MaxP B¹⁻² P¹ [26]—for double-rooted variants. Notably, one study [18] considered the number of roots in Vertucci classification, which resulted in similar percentages as Ahmed et al. coding system. However, the three-rooted variant was presented more accurately using the Ahmed et al. coding system.

Mandibular premolars

For mandibular premolars, both systems classified simple canal configurations effectively [28, 29] (Table 4), however, non-classifiable canals using the Vertucci system were identified in one micro-CT study on mandibular first premolars (0.54%—when supplementary configurations were considered) [28], and in one CBCT clinical study on mandibular first (8%) and second premolars (6.2%) [29].

The occurrence of double-rooted mandibular first premolars has been reported [28, 29] (Figure 4), and they were classified differently using both systems. They were classified as non-classifiable or type IX when supplementary types are considered using the Vertucci system but when using the Ahmed et al. system, two codes were identified—²ManP ¹B¹ L¹ and ²ManP ¹M¹ D¹ [according to the location of roots either buccal (B) and lingual (L)

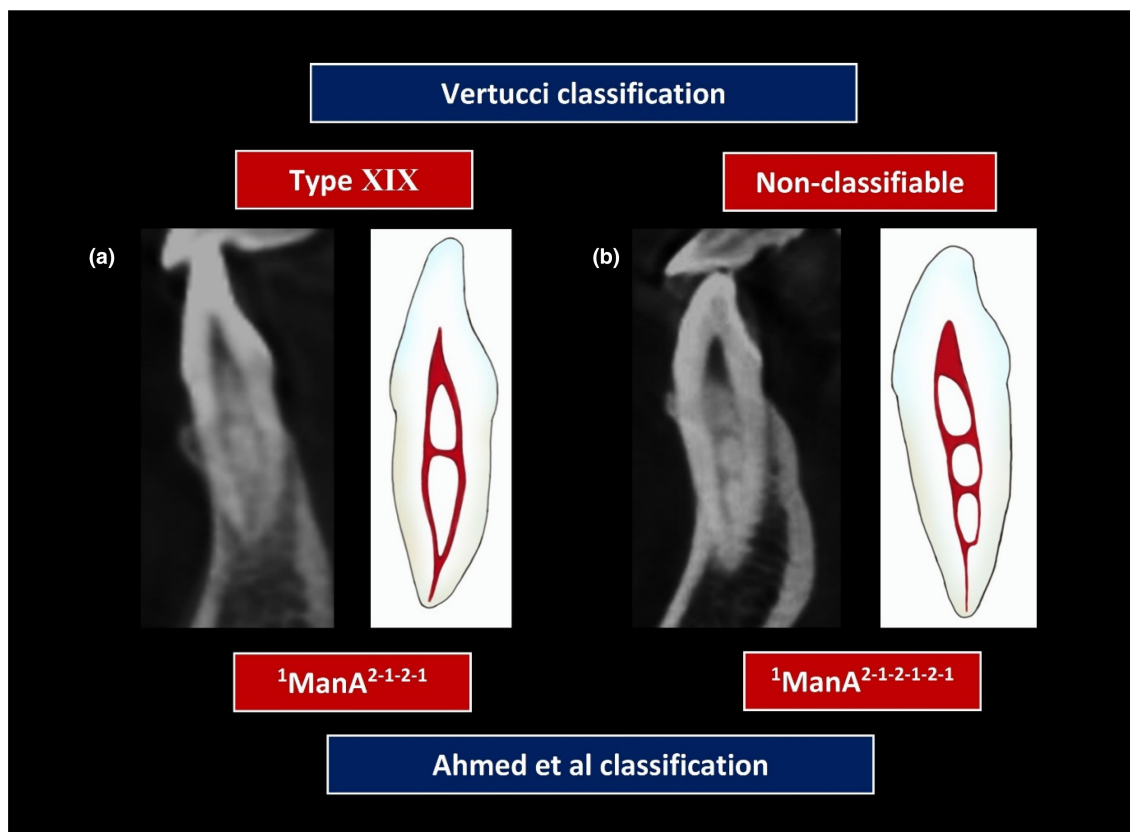


FIGURE 2 Cone beam computed tomography images showing Vertucci type XIX and non-classifiable teeth which were classified using the Ahmed et al. system as ${}^1\text{ManA}^{2-1-2-1}$ (a), and ${}^1\text{ManA}^{2-1-2-1-2-1}$ (b), respectively. Reproduced and modified from Karobari et al. [21, 34] with permission.

or mesial (M) and distal (D)] [28, 29]. Buchanan et al. [29] presented a number of codes to categorize double- and three-rooted mandibular premolars with different canal configurations.

Root and canal anatomy in molar teeth

The classification of maxillary molars using both systems has similar concepts since the Vertucci classification considers the number of roots in molars, in which the root canal type can be written separately for each root—this was demonstrated in three CBCT clinical studies [30–32]. However, for the Ahmed et al. system, the root and canal anatomy of maxillary molars were presented as codes for the entire tooth (not each root separately) (Table 5). One recent study reported 3.5% and 3.2% non-classifiable Vertucci types in the MB and DB roots of maxillary second molars, respectively [32]. Non-classifiable types were also identified in the P root (0.5%) (Table 5). The entire CBCT data was classified using Ahmed et al. coding system (Table 2). The authors also used supplementary codes for anomalies [33], to classify maxillary molars with fused roots. No study was identified that compared both systems in mandibular molar teeth.

Other studies

Apart from root and canal anatomy studies, one national survey in Malaysia compared the feedback of final year undergraduate dental students ($n = 382$) in eight Malaysian dental schools when the Ahmed et al. system was used and compared to the Vertucci classification [8]. The results revealed that $\geq 90\%$ of students found the new system was more accurate and more practical compared with the Vertucci system, and recommended the use of the new system in teaching, pre-clinical courses and clinical practice.

Supplementary material B summarizes the results of this systematic review in a PowerPoint presentation.

DISCUSSION

This systematic review aimed to assess the accuracy and practicability of the Ahmed et al. [15] classification system to characterise root and canal morphology in reports that used the system and compared it with other systems. All studies involved in this review used high-resolution 3D imaging tools (CBCT and micro-CT) to interpret root and canal anatomy (Tables 1–5).

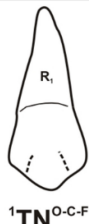
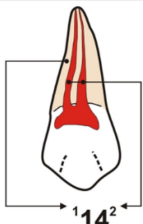
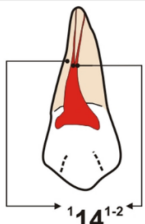
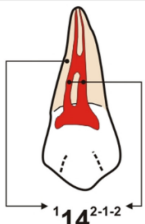
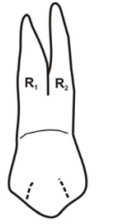
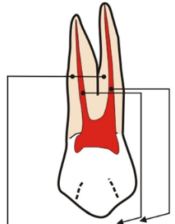
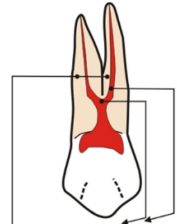
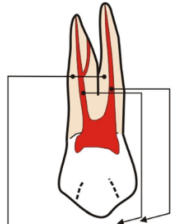

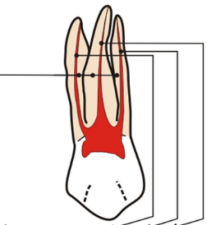
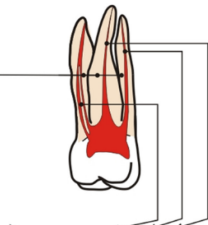
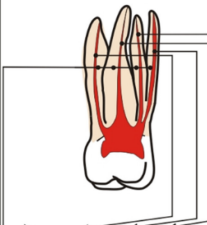
		Code			
Tooth type	Single - rooted	 $1TN^{O-C-F}$	 14^2	 14^{1-2}	 14^{2-1-2}
	Double - rooted	 $2TNR_1^{O-C-F} R_2^{O-C-F}$	 $14B^1P^1$	 $14^1B^1P^1$	 $14B^{1-2}P^1$
	Multi - rooted	 $3TNR_1^{O-C-F} R_2^{O-C-F} R_3^{O-C-F}$	 $14MB^1DB^1P^1$	 $26MB^{2-1}DB^1P^1$	 $26MB^1DB^1MP^1DP^1$

FIGURE 3 Application of Ahmed et al. classification system in maxillary premolars—considering the number of roots. Reproduced with permission from Olczak et al. [26].

This review reveals that both the Vertucci and Ahmed et al. classification systems are able to classify maxillary and mandibular anterior teeth in an accurate and practical manner since such teeth are most often single-rooted with simple canal configurations. However, the Vertucci classification was not able to classify teeth with complex canal anatomy (up to 6.67% of mandibular teeth scanned with micro-CT) [25]. Double-rooted mandibular canines are a less common anatomical variation ranging from <1% up to 5% [21, 35, 36]. The evidence provided in this review reveals that both the Vertucci and Ahmed et al. systems described this anatomy differently since the former does not consider the number of roots in the anterior dentition [21]. Therefore, Vertucci type V is used to describe canal configuration 1–2 in and

single- and double-rooted mandibular canines without distinguishing between them. On the other hand, for the Ahmed et al. system, both single- and double-rooted teeth are classified using appropriate codes [21] (Figure 5).

For maxillary premolar teeth, this review revealed that both systems were able to classify single-rooted premolars with simple canal configurations but double- and three-rooted teeth were categorised differently. A large proportion of maxillary premolar teeth (up to 65.4%) were classified in a different manner since the Vertucci system does not consider the number of roots in maxillary premolars (Figure 6a). Defining the number of roots in maxillary premolars has an impact in root canal treatment procedures, surgical treatments and post placement [37]. For instance,

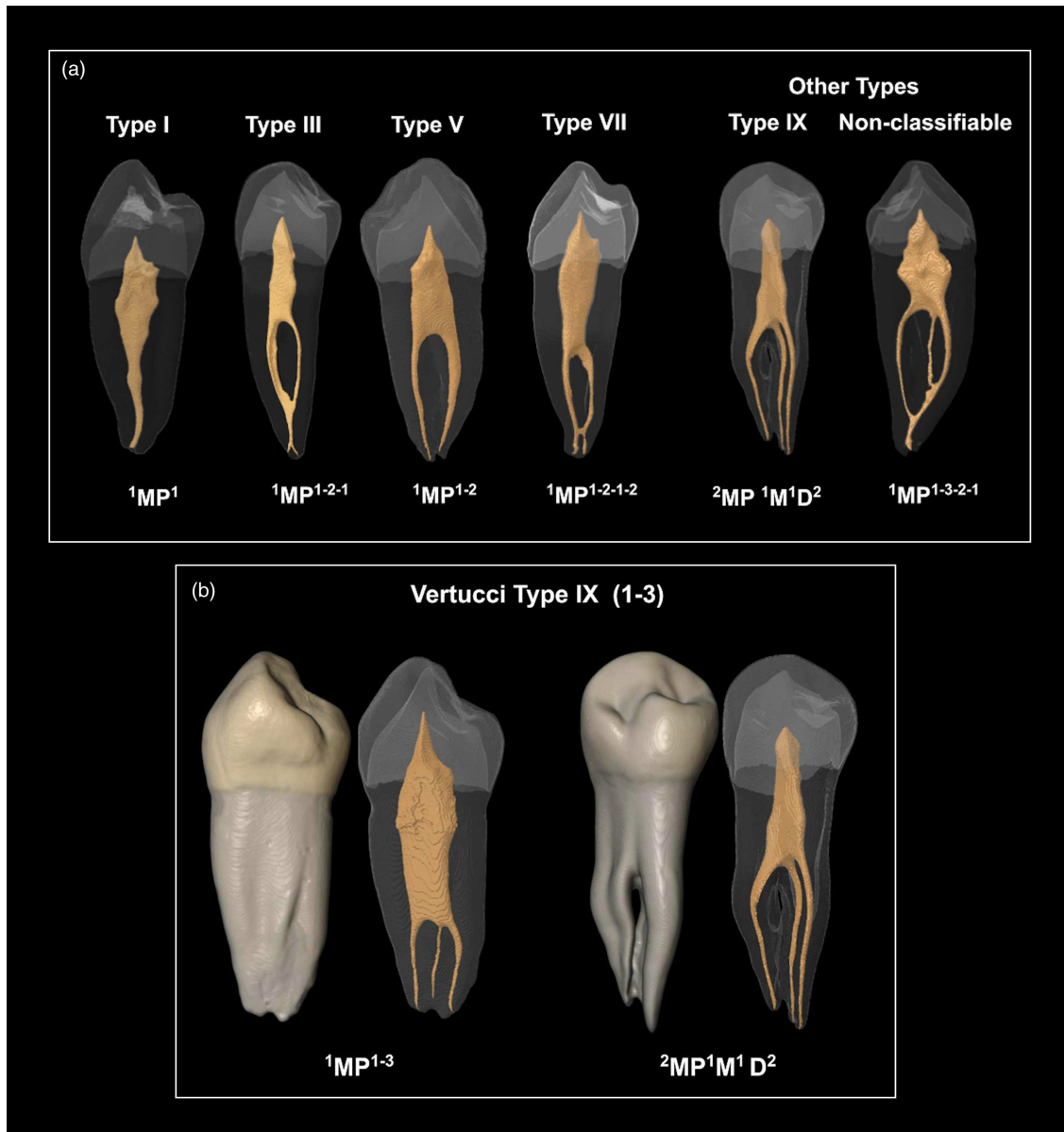


FIGURE 4 Differences between the Vertucci and Ahmed et al. systems when classifying single- and double-rooted mandibular premolars. (a) The use of both systems in simple and complex canal configurations in single-rooted mandibular premolars. (b) The use of both systems to classify single- and double-rooted mandibular premolars. Vertucci type IX was used to describe single- and double-rooted variants. However, two codes were used for the Ahmed et al. system (MP: Mandibular premolar, M: Mesial, D: Distal). Reproduced with permission from Sierra-Cristancho et al. [28].

the buccal root in double-rooted maxillary premolars usually shows the presence of a palatal furcation groove which has important clinical considerations [7, 37].

Three-canal maxillary premolars have been reported in many studies, and can occur more than 10% in some population groups [38]. This anatomical variation can occur mainly in three- or double-rooted maxillary premolars, which are usually classified as Vertucci type VIII. However, this anatomy has been described using codes in the Ahmed et al. classification such as $^3MaxP MB^1 DB^1 P^1$ and $^2MaxP B^{1-2} P^1$ (Figures 3 and 6b) that reflect

accurately the anatomy. In the first variant, two distinct buccal orifices are evident. However, for the latter, there is one common buccal canal orifice that divides into two root canals more apically. Methods of detection for such canals, instrumentation and filling vary, and have been discussed in several reports [17, 38–40].

Mandibular first premolars usually have complex root and canal anatomy. This was evident in the studies included in this review. Similar to other tooth types, simple root and canal configurations can be classified using both systems but the Ahmed et al. classification is able to

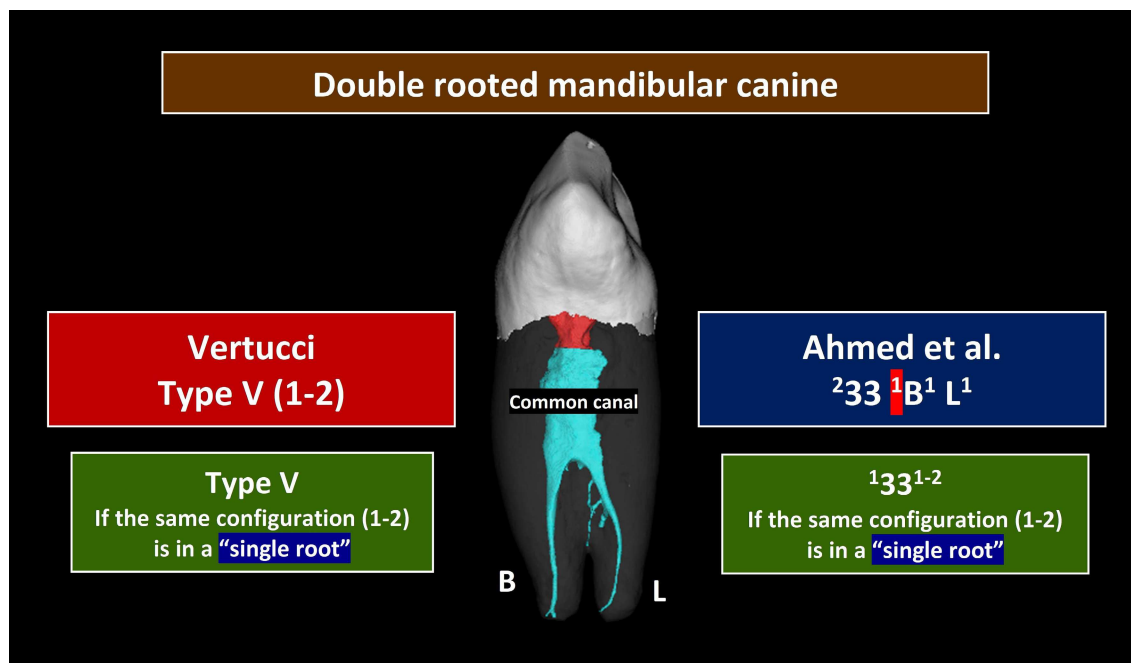


FIGURE 5 Difference between the Vertucci and Ahmed et al. systems when classifying double-rooted mandibular canines. Vertucci type V describes the canal configuration as 1-2 in both double- and single-rooted mandibular canines. For the Ahmed et al. classification, code ${}^233 {}^1B^1 L^1$ is used for double-rooted canines and ${}^133^{1-2}$ for single-rooted canines (B: Buccal, L: Lingual).

classify complex anatomical variations (such as Vertucci non-classifiable types, double-rooted teeth) more accurately, especially when complementary codes for anomalies are used [29]. The different location of the roots in the double-rooted variant identified in two studies (${}^2ManP {}^1B^1 L^1$ and ${}^2ManP {}^1M^1 D^1$) [28, 29] indicates that it is not only appropriate to define the ‘number’ of roots, but also to define the ‘location/position’ of such roots. This identification has important clinical implications during access cavity preparations, detection of root canals, instrumentation and root filling procedures as well as during surgical interventions [7, 19, 20].

The application of both classification systems in molar teeth is limited to a few studies on maxillary molars (Table 5), and requires further investigations using a range of other diagnostic tools (such as micro-CT). However, the application of both systems in molar teeth is similar since the Vertucci classification considers the number of roots in molar teeth. Usually, for the Vertucci system, the canal types are written for each root separately, but when using the Ahmed et al. classification, the codes describe the entire tooth (Table 5), or for the root of interest [16, 19]. It is worth mentioning that two CBCT clinical studies examined root and canal anatomy in mandibular first and second molars using the Vertucci classification [41, 42], but defined canals as non-classifiable when using that system but as ${}^236 M^{2-3-2-1} D^1$, ${}^{246} M^{2-3-2-1} D^1$ and ${}^{246} M^{2-3-2-1} D^{1-2-1}$ when using the Ahmed et al. system.

Considerations, advantages and limitations

Based on the above, the evidence available supports the accuracy and practicability of the Ahmed et al. [15] system when characterising root and canal anatomy in all tooth types compared to the Vertucci classification. This is especially true for single-rooted teeth with complex canal anatomy and multi-rooted anterior and premolar teeth, even though this usually results in the study samples having to be grouped into a larger number of categories (Tables 1–5). However, even though this may appear to be more complex, it is an essential part of the process as it provides the benefit of aligning each category with specific clinical challenges (such as three-canal maxillary premolars). These results, however, should not undermine the value of previous classification systems and researchers and dental practitioners should remain aware of their advantages and limitations [8]. In addition, despite its limitations, the Vertucci classification has been widely used for four decades in which the eight types identified can address many of the root canal configurations in the human dentition, and allows for comparison with other studies.

The Ahmed et al. coding system is an ‘open system’ which aims to describe details on the tooth, root and canals. This requires careful understanding of the basic concepts to allow the accurate application of the system. The identification of the ‘common canal’ in the coronal region of a root apical to the pulp chamber was

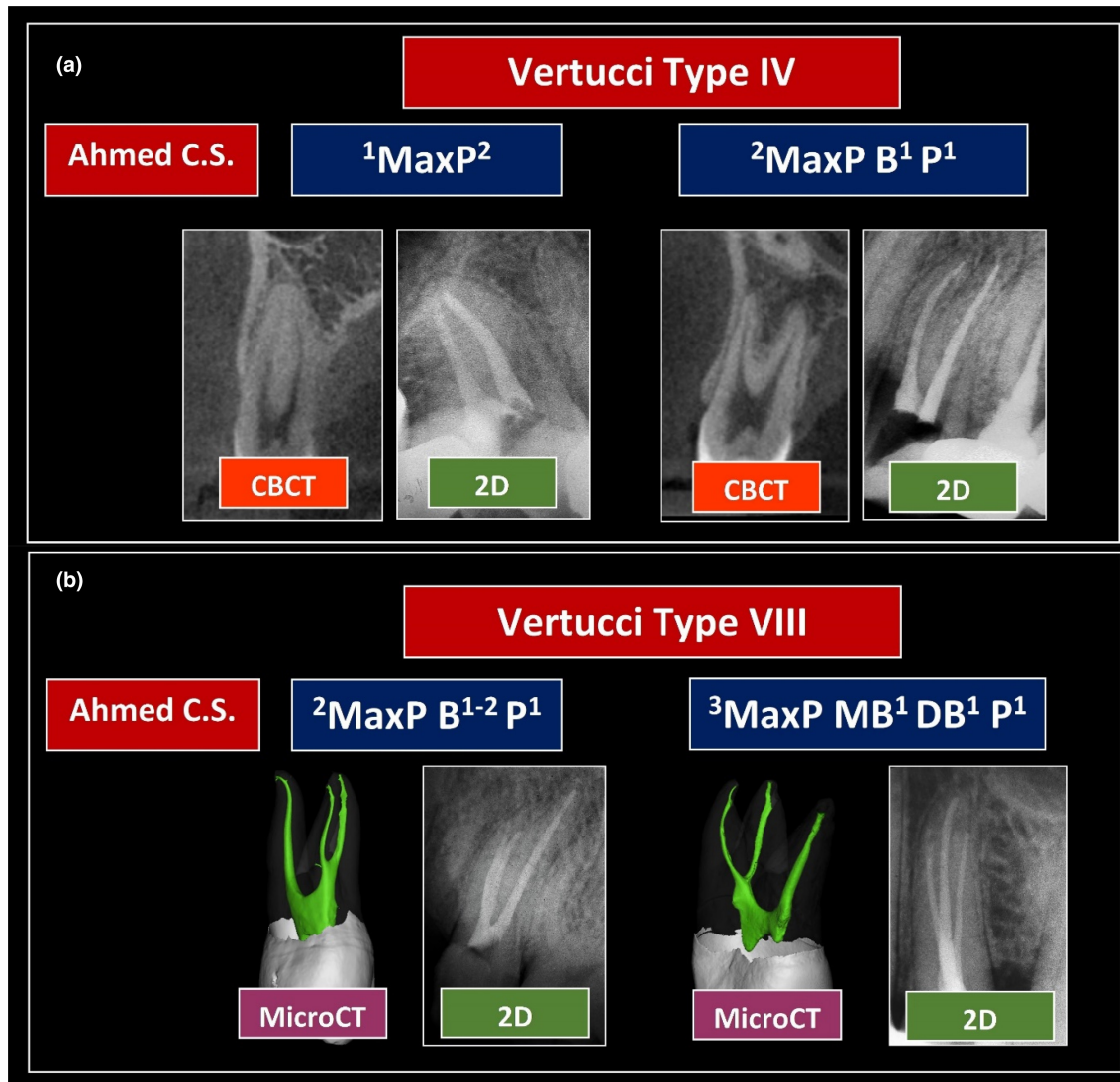


FIGURE 6 Differences between the Vertucci and Ahmed et al. systems when classifying (a) two separate canals in single- and double-rooted maxillary premolars, and (b) three canals in double- and three-rooted maxillary premolars. Reproduced with permission from Ahmed [7].

highlighted as a potential point of confusion for some students during the survey study undertaken in Malaysia [8]. It is worth mentioning that the Vertucci classification does not define the anatomical landmarks for a given canal configuration (such as the location of the canal orifice in single- and multi-rooted teeth), which is considered rather subjective. It is also important to note that the criteria followed by the Ahmed et al. [15] classification, which has been further explained [19, 20] require universal consensus for consistent application in root and canal anatomy studies.

The new coding system can be used adequately to characterise teeth using high-resolution devices (such as micro-CT and CBCT). However, such devices usually result in many complex anatomical variations (especially in molars) that would complicate data presentation using the coding system [43], especially if the anatomy code of

the entire tooth is used, which is a limitation. However, in molar teeth, the canal anatomy of each root can be described separately (such as M^{2-3-2} for mesial roots (M) in mandibular molars, MB^{2-3} for mesio-buccal roots in maxillary molars, etc) [7, 16]. This can be supplemented with the most common codes identified for the whole tooth. The use of an ‘asterisk’ has been suggested as one option to categorise complex canal anatomy (such as those canals with more than four digits) (Figure 7) [7, 19, 34]. Notably, minor editing errors have been identified in one of the studies included in this review (such as writing the canal configuration without a tooth number/abbreviation or superscript) [23]. It is important to have consistent presentation of the codes in different study designs [19, 20].

The new coding system does not describe the levels of merging and splitting of canals which may occur at

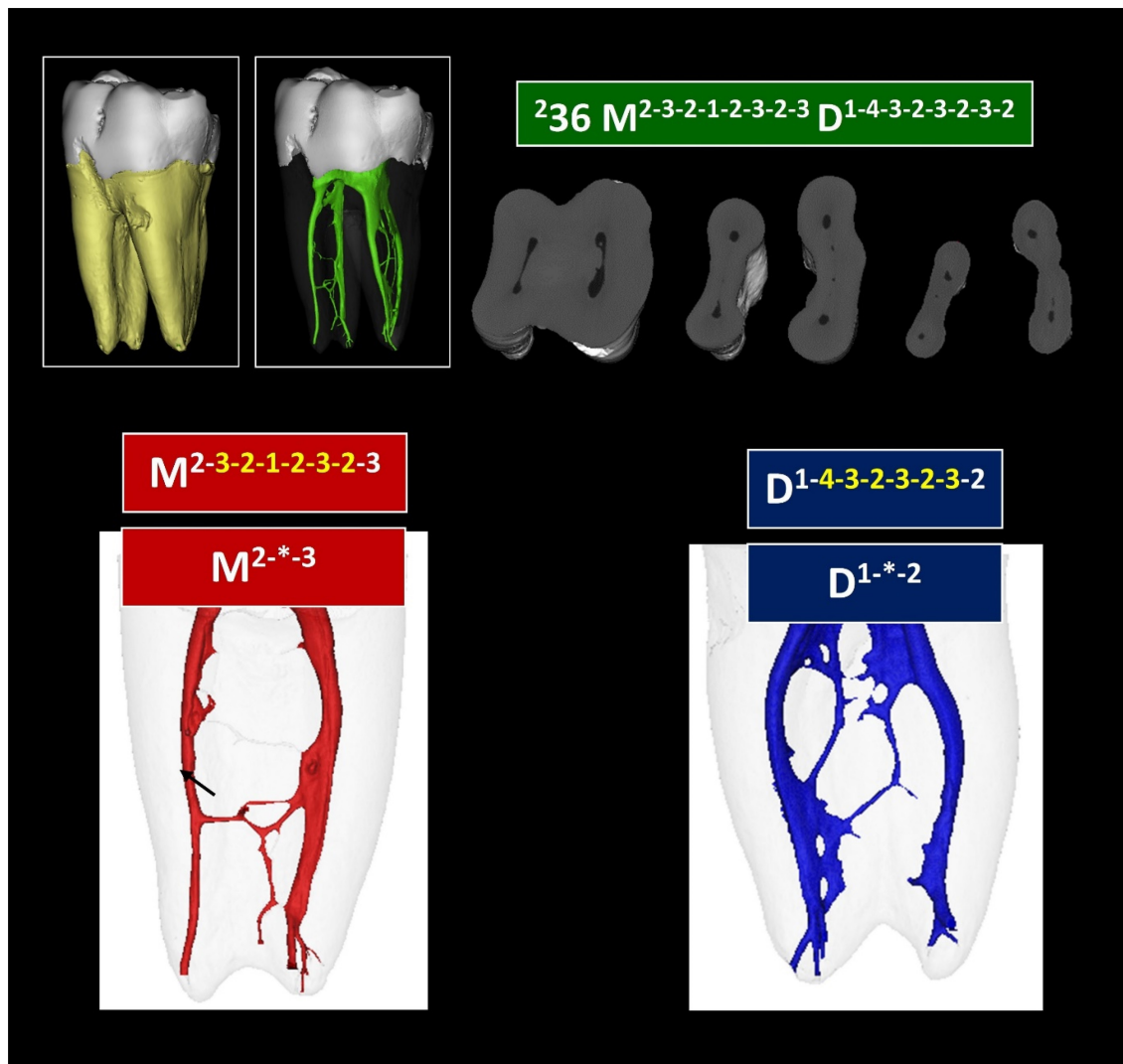


FIGURE 7 The application of the Ahmed et al. system to classify a mandibular molar with complex anatomy in the mesial and distal roots. Using an asterisk for very complex canal anatomy (such as canals with more than four digits) can be helpful to classify teeth or roots in certain categories.

different levels of the root. However, this parameter can be analysed separately according to the study objectives [17].

Future directions

The evidence from the literature supports the advantages of the Ahmed et al. system. However, the studies involved mainly use data derived from CBCT images in specific population groups. More CBCT data is needed for different tooth types in other population groups. More evidence is also required using micro-CT technology in different tooth types [44]. The integration of the new system with complementary codes to classify accessory canals [45] and anomalies [33] has been shown to be a useful demonstration of root and canal anatomy [22, 29, 32], which can be used in future studies.

Clinicians have used the new system to describe the anatomical variations of root canal treated teeth in a number of case reports (Supplementary Material C), which mainly focus on teeth with unusual anatomical variations (such as Vertucci non-classifiable types and maxillary premolars with different anatomical variations) detected using advanced diagnostic tools (such as the dental operating microscope and CBCT) (Figure 8). The new system is a promising platform for documenting the root and canal anatomy of different tooth types, and provides data that can be used for educational and research purposes. In addition, it can be used as a component for case difficulty assessment protocols. A recent report has explained a range of applications in clinical practice [20]. More evidence is needed to investigate its usefulness in clinical studies involving root canal treatment procedures.

The new system has the potential to be included in the undergraduate endodontic curriculum for teaching

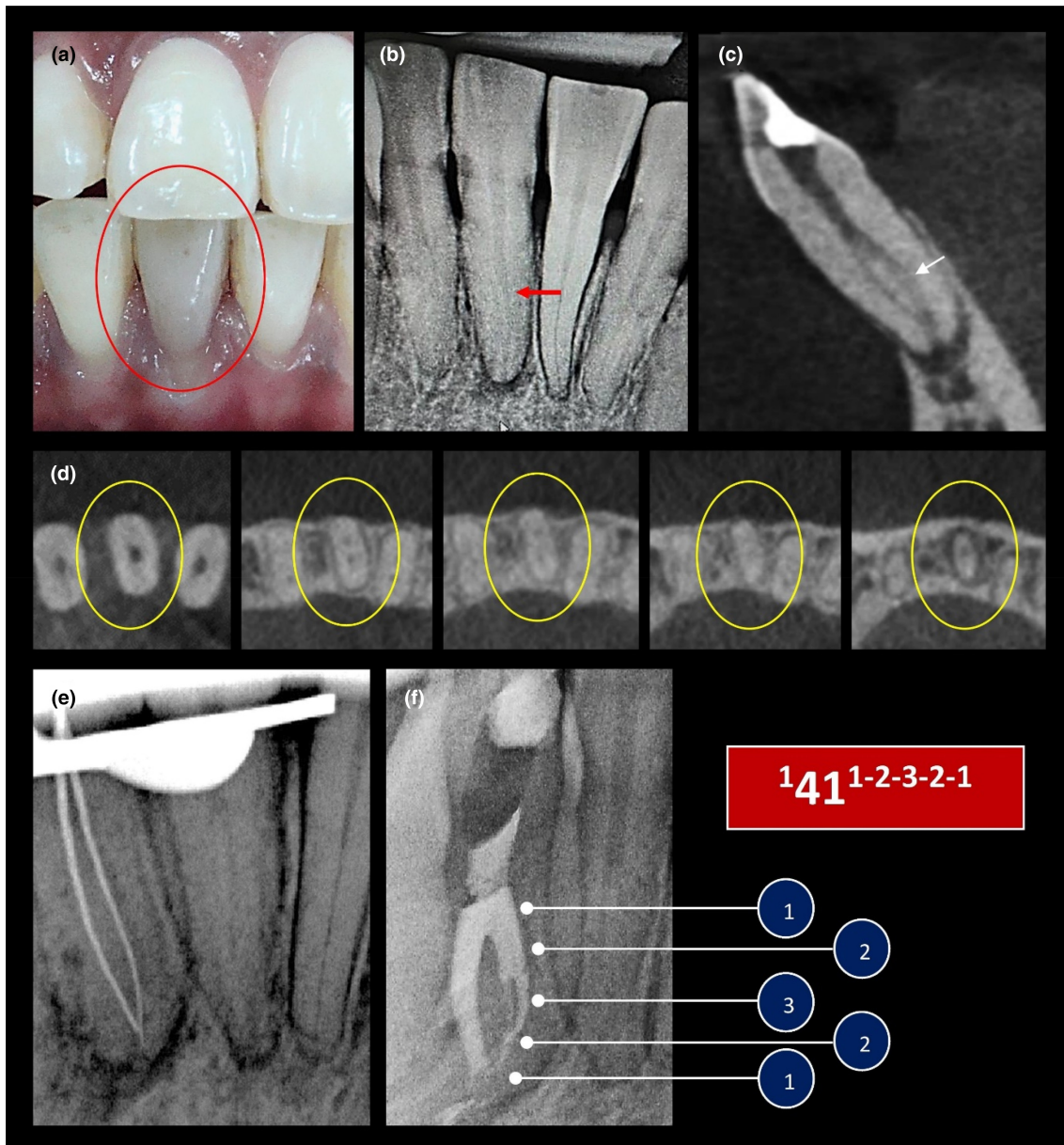


FIGURE 8 Application of the Ahmed et al. coding system to classify Vertucci non-classifiable types in clinical practice. (a) Pre-operative photograph showing a discoloured mandibular right central incisor (tooth 41). (b) 2D periapical radiographic image showing potential bifurcation (red arrow). (c, d) The sagittal section in (c) showed a root canal configuration type (1-2-1) with possibilities for a bifurcation in the lingual canal (white arrow). (d) The axial sections showed canal configuration (1-2-1). (e) After clinical exploration using stainless-steel hand files, two canals (with a common orifice) were initially identified (configuration of 1-2-1). A third canal was located after clinical exploration between the buccal and lingual canals. (f) Root canal filling was performed using a warm compaction technique. The root canal configuration was classified as ${}^{141} 1-2-3-2-1$ (Ahmed et al. system) (non-classifiable Vertucci configuration). Reproduced with permission from Ahmed [7].

programmes related to root and canal morphology as shown in one study [46]. However, the understanding of different users needs to be investigated further through calibration sessions and by examining the ability to provide consistent reporting on different tooth types with various root and canal anatomical variations. The response of general dental practitioners, specialists, researchers and lecturers, who are familiar with the Vertucci classification and its supplemental configurations, is also a potential for future research,

which was evidenced in one survey performed in Peru [47] and another in India [48] (not included in this review).

Limitations of the current review

This systematic review evaluated the accuracy and practicability of both classification systems based on the findings presented in the included studies (such as the ability

to present the root and canal anatomy in the tooth type investigated) regardless of the method used (clinical or laboratory). However, it did not evaluate the accuracy of the devices involved, criteria for tooth selection, scanning parameters and calibration between examiners. Indeed, such parameters are important to consider but they have been examined extensively in previous systematic reviews on root and canal anatomy studies [6, 49]. Only studies in English were included, which may have excluded some studies of relevance.

CONCLUSIONS

- Both the Ahmed et al. and Vertucci systems can accurately classify single-rooted teeth with simple canal configurations.
- For single-rooted teeth with more complex canal configurations (and certain roots in multi-rooted teeth such as the MB root in maxillary molars), the Ahmed et al. classification is able to characterise all canal configurations. The Vertucci system (and its supplementary configurations) is able to characterise the majority, but not all, canal configurations.
- For multi-rooted anterior and premolar teeth, the Ahmed et al. classification provides more accurate and practical presentation than the Vertucci classification since the number of roots and their location is provided.
- Future clinical and laboratory studies are needed to provide more evidence on the usage of Ahmed et al. coding system in molars.

ACKNOWLEDGEMENTS

Open access publishing facilitated by The University of Adelaide, as part of the Wiley - The University of Adelaide agreement via the Council of Australian University Librarians.

FUNDING INFORMATION

RU Grant (GPF017A-2020), Universiti Malaya, Malaysia—Principal Investigator: HMA Ahmed.


CONFLICT OF INTEREST STATEMENT

The authors deny any conflict of interest.

ORCID

Hany Mohamed Aly Ahmed  <https://orcid.org/0000-0003-0776-9288>

[org/0000-0003-0776-9288](https://orcid.org/0000-0003-0776-9288)

Giampiero Rossi-Fedele  <https://orcid.org/0000-0002-8287-1226>

[org/0000-0002-8287-1226](https://orcid.org/0000-0002-8287-1226)

Paul Michael Howell Dummer  <https://orcid.org/0000-0002-0726-7467>

[org/0000-0002-0726-7467](https://orcid.org/0000-0002-0726-7467)

REFERENCES

1. Vertucci FJ. Root canal morphology and its relationship to endodontic procedures. *Endod Top*. 2005;10:3–29.
2. Vertucci FJ. Root canal anatomy of the human permanent teeth. *Oral Surg Oral Med Oral Pathol*. 1984;58:589–99.
3. Weine FS, Healey HJ, Gerstein H, Evanson L. Canal configuration in the mesiobuccal root of the maxillary first molar and its endodontic significance. *Oral Surg Oral Med Oral Pathol*. 1969;28:419–25.
4. Versiani MA, Ordinola-Zapata R, Keleş A, Alcin H, Bramante CM, Pécora JD, et al. Middle mesial canals in mandibular first molars: a micro-CT study in different populations. *Arch Oral Biol*. 2016;61:130–7.
5. Martins JNR, Marques D, Mata A, Caramês J. Root and root canal morphology of the permanent dentition in a Caucasian population: a cone beam computed tomography study. *Int Endod J*. 2017;50:1013–26.
6. Ahmed HMA, Rossi-Fedele G. Preferred reporting items for root and canal anatomy in the human dentition (PROUD 2020)—a systematic review and a proposal for a standardized protocol. *Eur Endod J*. 2020;5:159–76.
7. Ahmed HMA. A critical analysis of laboratory and clinical research methods to study root and canal anatomy. *Int Endod J*. 2022;55(Suppl 2):229–80.
8. Ahmed HMA, Che Ab Aziz ZA, Azami NH, Farook MS, Khan AA, Mohd Noor NS, et al. Application of a new system for classifying root canal morphology in undergraduate teaching and clinical practice: a national survey in Malaysia. *Int Endod J*. 2020 Jun;53(6):871–9.
9. Sert S, Bayirli GS. Evaluation of the root canal configurations of the mandibular and maxillary permanent teeth by gender in the Turkish population. *J Endod*. 2004;30:391–8.
10. Verma P, Love RM. A micro CT study of the mesiobuccal root canal morphology of the maxillary first molar tooth. *Int Endod J*. 2011;44:210–7.
11. Kim Y, Chang SW, Lee JK, Chen IP, Kaufman B, Jiang J, et al. A micro-computed tomography study of canal configuration of multiple canal mesiobuccal root of maxillary first molar. *Clin Oral Investig*. 2013;17:1541–6.
12. Lee KW, Kim Y, Perinpanayagam H, Lee JK, Yoo YJ, Lim SM, et al. Comparison of alternative image reformatting techniques in microcomputed tomography and tooth clearing for detailed canal morphology. *J Endod*. 2014;40:417–22.
13. Leoni GB, Versiani MA, Pécora JD, Damião de Sousa-Neto M. Micro-computed tomographic analysis of the root canal morphology of mandibular incisors. *J Endod*. 2014;40:710–6.
14. Filpo-Perez C, Bramante CM, Villas-Boas MH, Hungaro Duarte MA, Versiani MA, Ordinola-Zapata R. Micro-computed tomographic analysis of the root canal morphology of the distal root of mandibular first molar. *J Endod*. 2015;41:231–6.
15. Ahmed HMA, Versiani MA, De-Deus G, Dummer PMH. A new system for classifying root and root canal morphology. *Int Endod J*. 2017;50:761–70.
16. Ahmed HMA, Dummer PMH. Advantages and applications of a new system for classifying roots and canal systems in research and clinical practice. *Eur Endod J*. 2018;3:9–17.
17. Saber SEDM, Ahmed MHM, Obeid M, Ahmed HMA. Root and canal morphology of maxillary premolar teeth in an Egyptian

- subpopulation using two classification systems: a cone beam computed tomography study. *Int Endod J.* 2019;52:267–78.
18. Buchanan GD, Gamielien MY, Tredoux S, Vally ZI. Root and canal configurations of maxillary premolars in a South African subpopulation using cone beam computed tomography and two classification systems. *J Oral Sci.* 2020;62:93–7.
 19. Ahmed HMA, Ibrahim N, Mohamad NS, Nambiar P, Muhammad RF, Yusoff M, et al. Application of a new system for classifying root and canal anatomy in studies involving micro-computed tomography and cone beam computed tomography: explanation and elaboration. *Int Endod J.* 2021;54:1056–82.
 20. Ahmed HMA, Hashem AAR, Dummer PMH. Application of a new system for classifying root and canal anatomy in clinical practice—explanation and elaboration. *Eur Endod J.* 2021;6:132–42.
 21. Karobari MI, Noorani TY, Halim MS, Ahmed HMA. Root and canal morphology of the anterior permanent dentition in Malaysian population using two classification systems: a CBCT clinical study. *Aust Endod J.* 2021;47:202–16.
 22. Buchanan GD, Gamielien MY, Fabris-Rotelli I, van Schoor A, Uys A. Root and canal morphology of the permanent anterior dentition in a Black South African population using cone-beam computed tomography and two classification systems. *J Oral Sci.* 2022;64:218–23.
 23. Iqbal A, Karobari MI, Alam MK, Khattak O, Alshammari SM, Adil AH, et al. Evaluation of root canal morphology in permanent maxillary and mandibular anterior teeth in Saudi subpopulation using two classification systems: a CBCT study. *BMC Oral Health.* 2022;22(1):171.
 24. Alobaid MA, Alshahrani EM, Alshehri EM, Shaiban A, Haralur SB, Chaturvedi S, et al. Radiographic assessment of root canal morphology of mandibular central incisors using new classification system: a cross-sectional study. *Medicine.* 2022;101(37):e30751.
 25. Villa N, Weissheimer T, Vier-Pelisser FV, Alcalde MP, Vivian RR, Duarte MAH, et al. Comparative study of Vertucci and Ahmed classifications to evaluate the main root canal configuration of mandibular incisors in a Brazilian population. *Aust Endod J.* 2022;48(3):409–14.
 26. Olczak K, Pawlicka H, Szymański W. Root form and canal anatomy of maxillary first premolars: a cone-beam computed tomography study. *Odontology.* 2022;110:365–75.
 27. Olczak K, Pawlicka H, Szymański W. Root and canal morphology of the maxillary second premolars as indicated by cone beam computed tomography. *Aust Endod J.* 2023;49(1):92–103.
 28. Sierra-Cristancho A, González-Osuna L, Poblete D, Cafferata EA, Carvajal P, Lozano CP, et al. Micro-tomographic characterization of the root and canal system morphology of mandibular first premolars in a Chilean population. *Sci Rep.* 2021;11:93.
 29. Buchanan GD, Gamielien MY, Fabris-Rotelli I, van Schoor A, Uys A. A study of mandibular premolar root and canal morphology in a Black South African population using cone-beam computed tomography and two classification systems. *J Oral Sci.* 2022;64:300–6.
 30. Mirza MB, Gufran K, Alhabib O, Alafraa O, Alzahrani F, Abuelqomsan MS, et al. CBCT based study to analyze and classify root canal morphology of maxillary molars—a retrospective study. *Eur Rev Med Pharmacol Sci.* 2022;26:6550–60.
 31. Rosaline H, Kanagasabai A, Shaji A, Bose S, Saeralathan S, Ganesh A. Analysis of root and canal morphologies of maxillary second molars in a South Indian population using cone-beam computed tomography: a retrospective study. *Endodontology.* 2021;33:133–8.
 32. Buchanan GD, Gamielien MY, Fabris-Rotelli I, Van Schoor A, Uys A. Root and canal morphology of maxillary second molars in a Black South African subpopulation using cone-beam computed tomography and two classifications. *Aust Endod J.* 2022 Nov 24. <https://doi.org/10.1111/aej.12720>. Epub ahead of print.
 33. Ahmed HMA, Dummer PMH. A new system for classifying tooth, root and canal anomalies. *Int Endod J.* 2018;51:389–404.
 34. Karobari MI, Noorani TY, Halim MS, Dummer PMH, Ahmed HMA. Should inter-canal communications be included in the classification of root canal systems? *Int Endod J.* 2019;52:917–9.
 35. Ouellet R. Canines inférieures permanentes à deux racines [Mandibular permanent cuspids with two roots]. *J Can Dent Assoc.* 1995;61:159–61.
 36. Pécora JD, Sousa Neto MD, Saquy PC. Internal anatomy, direction and number of roots and size of human mandibular canines. *Braz Dent J.* 1993;4:53–7.
 37. Lammertyn PA, Rodrigo SB, Brunotto M, Crosa M. Furcation groove of maxillary first premolar, thickness, and dentin structures. *J Endod.* 2009;35:814–7.
 38. Ahmed HMA, Cheung GS. Accessory roots and root canals in maxillary premolar teeth: a review of a critical endodontic challenge. *ENDO—Endod Pract Today.* 2012;6:7–18.
 39. Belizzi R, Hartwell G. Evaluating the maxillary premolar with three canals for endodontic therapy. *J Endod.* 1981;7:521–7.
 40. Sieraski SM, Taylor GN, Kohn RA. Identification and endodontic management of three-canal maxillary premolars. *J Endod.* 1989;15:29–32.
 41. Senan EM, Madfa AA, Alhadainy HA. Root and canal configuration of mandibular first molars in a Yemeni population: a cone-beam computed tomography. *Eur Endod J.* 2020;5:10–7.
 42. Senan EM, Alhadainy H, Madfa AA. Root and canal morphology of mandibular second molars in a Yemeni population: a cone-beam computed tomography. *Eur Endod J.* 2021;6:72–81.
 43. Tredoux S, Warren N, Buchanan GD. Root and canal configurations of mandibular first molars in a South African subpopulation. *J Oral Sci.* 2021;63:252–6.
 44. Al-Rammahi HM, Chai WL, Nabhan MS, Ahmed HMA. Root and canal anatomy of mandibular first molars using micro-computed tomography: a systematic review. *BMC Oral Health.* 2023;29(23):339.
 45. Ahmed HMA, Neelakantan P, Dummer PMH. A new system for classifying accessory canal morphology. *Int Endod J.* 2018;51:164–76.
 46. Reymus M, Liebermann A, Diegritz C. Virtual reality: an effective tool for teaching root canal anatomy to undergraduate dental students—a preliminary study. *Int Endod J.* 2020;53:1581–7.
 47. Salas H, Torres J, Pauro J, Ahmed HMA. A new coding system for root and canal morphology—an online survey from Peru. *Int Endod J.* 2021;54:147–9.
 48. Karobari MI, Ahmed HMA, Khamis MFB, Ibrahim N, Noorani TY. Application of two systems to classify the root and canal morphology in the human dentition: a national survey in India. *J Dent Educ.* 2023 May 10. <https://doi.org/10.1002/jdd.13236>. Epub ahead of print.

49. Martins JNR, Kishen A, Marques D, Nogueira Leal Silva EJ, Caramês J, Mata A, et al. Preferred reporting items for epidemiologic cross-sectional studies on root and root canal anatomy using cone-beam computed tomographic technology: a systematized assessment. *J Endod.* 2020;46:915–35.

SUPPORTING INFORMATION

Additional supporting information can be found online in the Supporting Information section at the end of this article.

How to cite this article: Ahmed HMA, Rossi-Fedele G, Dummer PMH. Critical analysis of a new system to classify root and canal morphology — A systematic review. *Aust Endod J.* 2023;00:1–19.
<https://doi.org/10.1111/aej.12780>