

ORIGINAL PAPER

Bilaterality of varicocele: The overlooked culprit in male infertility. Case series study

Khaled Mohamed Almekaty¹, Ahmed Mostafa Elsharkawy², Mohamed Hasan Zahran³, Maged Mostafa Ragab¹, Ayman Sayed Rashed⁴, Mahmoud Mohamed Soliman⁵, Khaled Abdelaziz Salem¹, Ahmed Fayez Ghaith¹

¹ Urology Department, Tanta University, Tanta, Egypt;

² Radiology Department, Tanta University, Tanta, Egypt;

³ Mansoura Urology and nephrology centre, Mansoura University, Mansoura, Egypt;

⁴ Urology Department, 6th of October University, Cairo, Egypt;

⁵ Obstetrics and Gynecology Department, Cairo University, Cairo, Egypt.

Summary *Objectives: Varicocele is the most common correctable cause of male infertility that always has been a debatable subject as regards how it affects fertility and the best way to treat it. Proper assessment of the disease bilaterality is crucial not to miss one side and not to jeopardize treatment outcome. This study aimed to objectively assess varicocele bilaterality in infertile men aiming to improve treatment outcome in this cohort of patients.*

Methods: This prospective study was conducted between January 2019 and January 2022 including infertile males with varicoceles. Assessment of missed concomitant contralateral varicocele done pre-operatively by Color Doppler Ultrasound and intra-operatively by intraoperative Doppler device and measurement of maximal vein diameter of contralateral side.

Results: A total of 329 cases completed the study. A hundred cases (30.4%) were initially referred as unilateral varicoceles and 229 (69.6%) as bilateral varicoceles. After reassessment of the study population, bilaterality of varicocele was found to be as high as 98.5% (324/329). Repeat CDUS strongly correlated with the intraoperative measured varicocele diameter ($r = 0.9$, $p < 0.001$). Moreover, sperm parameters showed significant improvement 3 and 6 months post varicocelectomy. Normal pregnancy after 1 year of surgery occurred in 118 cases (35.9%).

Conclusions: Varicocele bilaterality in infertile men is under-reported. Thorough assessment by expert radiologists and andrologists is of paramount importance not to miss significant pathology or hazard treatment outcome.

KEY WORDS: Male infertility; Varicocele bilaterality; Varicocelectomy; Semen parameters.

Submitted 9 July 2023; Accepted 28 July 2023

INTRODUCTION

Varicocele is the commonest surgical cause of male infertility and is found in 40% of patients with primary and 80% of those with secondary infertility (1). The etiopathogenesis of varicocele-induced infertility and the effect of surgical repair on the fertility potentials has always been a matter of debate (2).

As reported in the literature, varicocele is found in 78% -

93% of cases on the left side, while bilateral varicoceles are only found in about 25% of patients (3). Majority of the left sided varicocele is related to the anatomic factors of the left testicular vein (4).

In 1952, Tulloch for the first time reported an azoospermic case which responded very well to bilateral varicocelectomy with not only sperm development in the ejaculate, but also normal pregnancy of the wife (5). Since then, many studies reported significant improvement in the sperm parameters of patients following bilateral varicocelectomy (6, 7). One theory that claims varicocele to be a disease of bilaterality is the reflux theory. It depends on the presence of either incompetent or absent gonadal vein valves that allow blood to shunt back into the pampiniform plexus of veins. Obviously, this is an anatomical deficit that should theoretically exist on both sides (8). This explains why left varicocele can also affect spermatogenesis of the right side as well.

Previously, the incidence of coexisting right varicocele in the presence of palpable left varicocele was 21-60% as reported by venographic studies. Recently, the incidence of bilateral varicoceles is increasing due to the use of modern diagnostic means besides the physical examination, such as *Color Doppler Ultrasound* (CDUS) which has a sensitivity of 97% and specificity of 94% (9). As CDUS is operator dependent, its reliability to diagnose and grade varicocele is still controversial (10).

Thus, assessment of varicocele bilaterality in infertile men seems to be deficient in the literature. On this basis, this study tried to objectively assess varicocele bilaterality in infertile men aiming to improve treatment outcome in this cohort of patients.

PATIENTS AND METHODS

This is a case series study that was conducted in *Tanta Urology Department in Egypt* between January 2019 and January 2022. The study was conducted in accordance with the Declaration of Helsinki and it was approved by *Tanta University, Faculty of Medicine* review board (IRB number is 35903/10/22). Informed consent was obtained by all subjects when they were enrolled.

Infertile men (either primary or secondary infertility) initially assessed or referred as unilateral or bilateral varicocele patients were enrolled. Patients with history of orchidectomy, cryptorchidism, azoospermia or concomitant female partner infertility were excluded.

All patients were subjected to physical examination including local scrotal examination to evaluate the degree and laterality of varicocele and semen analysis before the operation. A repeat scrotal Doppler ultrasonography was done for all patients to confirm diagnosis of varicocele and reassess bilaterality of the disease. This repeat CDUS was performed by the same expert urologist who was blinded to the findings of physical examination.

All patients underwent microsurgical subinguinal varicocelectomy by expert urologists after taking a written informed consent with explanation of the potential complications of the procedure.

Patients who were diagnosed with bilateral varicoceles underwent bilateral subinguinal ligation straight away. Those who were referred with unilateral varicocele had a repeat CDUS for reassessment of missed concomitant contralateral varicocele. Their palpable sides were operated on first; then the contralateral side was explored as follows; the spermatic cord was delivered and opened at the level of the external inguinal ring. Then, the maximal dilated internal spermatic vein diameter was measured using a micrometer fixed to the surgical microscope. Also, the veins of the contralateral side were examined for reflux using an intraoperative Doppler device (VTI intraoperative Doppler system 20 MHz). The sound of venous reflux confirmed varicocele diagnosis.

Patients were followed up for at least 6 months after surgery to evaluate any complications and assess improvement in semen parameters.

The primary outcome measure was to assess disease bilaterality and the secondary outcome measure was to report on improvement in semen 3 and 6 months post varicocelectomy and normal pregnancy rate after 1 year.

Female partners were evaluated by full history taking and thorough examination to exclude female factor infertility. Good ovulation was suggested if the female showed menstrual regularity, *premenstrual syndrome* (PMS), mid cyclic pain or discharge, confirmed by normal *Follicle-stim-*

ulating hormone (FSH), *Luteinizing hormone* (LH), *Thyroid stimulating hormone* (TSH), *Prolactin*, *Estradiol* (E2), and *Anti-mullerian hormone* (AMH). Transvaginal ultrasound was done to exclude any uterine pathology or mullerian anomalies that may interfere with the occurrence of pregnancy. Furthermore, folliculometry was done and the presence of good ovulation was declared and confirmed by mid-luteal phase progesterone. After varicocelectomy, the female partners were followed up for 1 year to assess normal pregnancy rate.

Statistical analysis

Statistical analysis was performed using SPSS 16.0 for Windows software (SPSS, Inc., Chicago, IL). Chi-Square test is used to determine the significant association between the observed frequencies and the expected frequencies. Wilcoxon sign test and simple Student t-test were used for continuous variables. The difference was considered statistically significant at < 0.05 .

RESULTS

In this study 350 patients were initially enrolled and after exclusion, a total of 329 cases completed the study. Figure 1 shows the flowchart of cases. A hundred cases (30.4%) were initially referred as unilateral and 229 (69.6%) as bilateral varicoceles. Table 1 shows the baseline data of the study population.

Bilaterality of the disease was reassessed preoperatively by

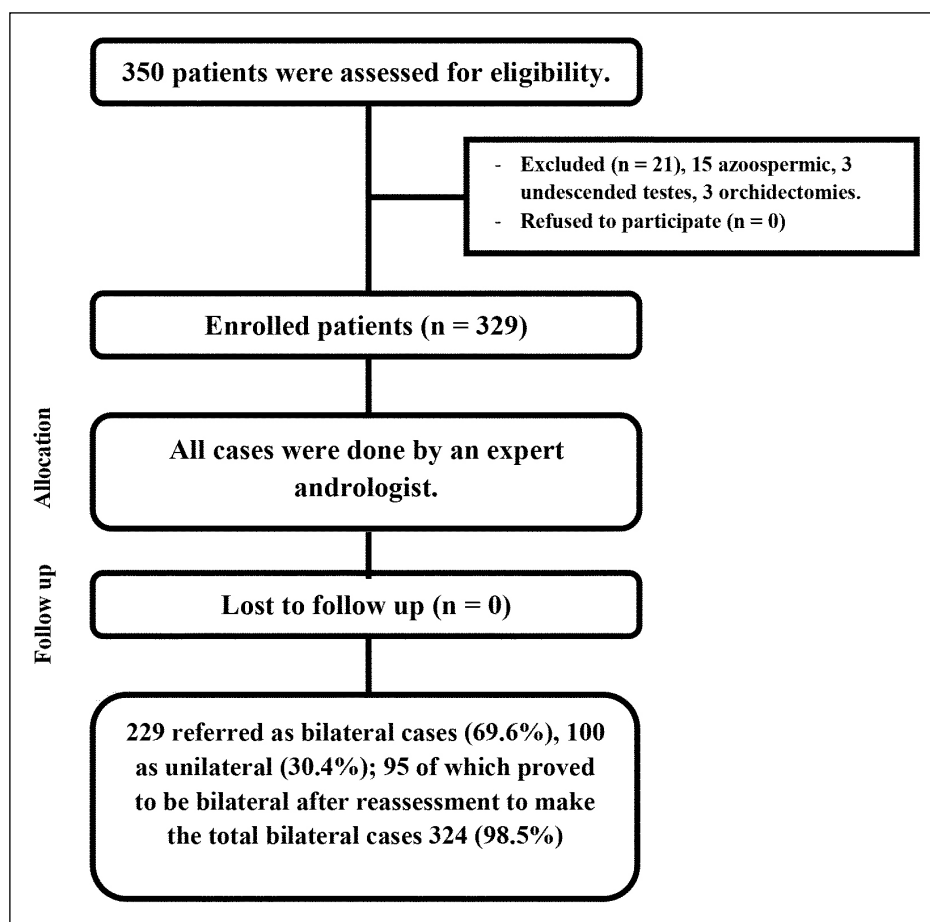


Figure 1.
Flowchart of study population.

	Total number (No. = 329)	Referred as bilateral varicocele (No. = 229)	Referred as unilateral varicocele (No. = 100; 4 right and 96 left)	P-value
Age (years)				
Mean ± SD	29.1 ± 3.7	29.1 ± 3.6	29.3 ± 4.5	0.8
Age of the partner (years)				
Mean ± SD	27.1 ± 4.1	26.7 ± 3.6	28.6 ± 5.7	0.7
Duration of infertility (years)				
Median (IQR)	3.5 (2-5)	3.5 (2-5)	3.5 (2-4)	0.9
Right testicular size (ml)				
Mean ± SD	14.9 ± 2.1	14.9 ± 1.9	15.1 ± 3.2	0.4
Left testicular size (ml)				
Mean ± SD	14 ± 1.5	14 ± 1.4	14.3 ± 1.6	0.1
Sperm density (million/ml)				
Mean ± SD	4.2 ± 1.5	4.2 ± 1.5	4.1 ± 1.2	0.5
Sperm motility (A+B)				
Mean ± SD	18.2 ± 5.7	18.3 ± 5.8	17.5 ± 4.6	0.3
Grade of varicoceles		G1:109 G2:211 G3:138	G1: 25 G2: 60 G3: 15	

Table 1.
Patients' demographics.

	Baseline	3 months after surgery	6 months after surgery	P1	P2
Sperm density (million/ml)					
Median (range, IQR)	5 (0.15-13, 4-5)	7.5 (0-80, 7-10)	11 (0-60, 10-13)	<0.001	<0.001
Sperm motility (A+B)					
Median (range, IQR)	20 (0-60, 15-20)	25 (0-70, 20-30)	40 (0-60, 35-45)	<0.001	<0.001

P1: comparison between baseline and 3 months.
P2: comparison between baseline and 6 months.

Table 2.
Outcomes of varicocelectomy.

a repeat CDUS and intraoperatively by measuring the maximal diameter of the largest vein and detecting venous reflux using operative Doppler as mentioned in the methodology section.

After reassessment of the study population, bilaterality of varicocele was found to be as high as 98.5% (324/329). This is statistically significantly higher than initial CDUS ($p < 0.001$).

Repeat CDUS showed bilaterality in 95 out of the 100 cases (95%) and all had grade 2 varicoceles with median (range, IQR) diameter of 3.2 (2.5-4.1, 2.8-3.5) mm.

The CDUS diameter strongly correlated with the intraoperative measured diameter 3.4 (1.5-4, 3-3.6) mm, ($r = 0.9$, $p < 0.001$).

Moreover, seminal parameters showed significant improvement at 3 and 6 months post varicocelectomy as shown in Table 2. Normal pregnancy after 1 year of surgery occurred in 118 cases (35.9%).

DISCUSSION

The exact relationship between bilateral varicocele and infertility is not fully understood, but since *Tulloch* noticed the positive effect of varicocelectomy on improving male fertility, many studies have been conducted to investigate this. Interestingly, the degree of varicocele seems to be unrelated to the degree of testicular function affection or even the improvement after varicocelectomy as even a subclinical varicocele can result in male subfertility (11).

The only study that tried to clearly address whether or not varicocele in infertile males is a disease of bilaterality

is that of *Gat et al.* (12) They used venography and contact thermography to detect "clinically missed" varicoceles. Using these 2 modalities, they detected varicocele in 255 out of 286 infertile males (89.1%); bilaterality was confirmed in 206 (80.8%). In the current study, reassessment of varicocele was done by repeat CDUS by an expert urologist and intraoperatively by measuring the diameter of the largest vein at the level of the external inguinal ring and by detecting venous reflux using intraoperative Doppler device. Out of a total of 329 patients, 229 were referred as bilateral (69.6%) but rate of bilaterality reached 98.5% (324 cases) after the "second look" evaluation.

Most of the studies in the literature reporting the prevalence of varicocele in infertile men rely on physical examination and scrotal ultrasound. *Gonda et al.* (13) reported 95% sensitivity with a 2-mm cutoff for vein diameters for diagnosis of varicocele.

Both are subjective, operator dependent with significant interpersonal variability. In the current study, 30.4% of patients were referred as unilateral varicocele cases and after reassessment bilaterality was proven in 98.5% (28.9% was misdiagnosed).

Reports in the literature looking at the prevalence of varicocele bilaterality are scarce. In 1986, *McClure and Hricak* used CDUS to detect subclinical varicocele and detected bilaterality in 70% of their study population (14).

Chatel et al., *Gonzalez et al.*, *Cockett et al.* and *Gat Y et al.* detected bilaterality in 60%, 61%, 57% and 89.1% respectively (15-17, 12). The higher prevalence of the disease bilaterality in the *Gat et al.* and the current study as compared to others can be attributed to the use of

objective methods of assessment; venography in the former and intraoperative Doppler and measurement of the diameter of largest vein in the latter and to the improvement in the accuracy of the modern CDUS devices available nowadays.

In the current study, both radiologists and surgeons have extensive experience in this field; so repeat CDUS strongly correlated to intraoperative assessment of the disease; ($r = 0.9$, $p < 0.001$; Pearson correlation coefficient). This means that the experience of the ultrasonographer and the surgeon should play a vital role to avoid misdiagnosed varicoceles.

The exact mechanism by which varicocele might lead to infertility is still unclear. The pathogenesis is thought to be multifactorial and complex, with several factors mostly acting together. In this complex etiopathogenesis, oxidative stress seems to have a crucial role, among others. Oxidative stress results from increased hydrostatic pressure in the pampiniform plexus of veins which leads to stagnation of toxic metabolites, hypoxia together with increased temperature (18).

One of the theories that can explain varicocele bilaterality is that there are venous anastomotic channels between the right and left gonadal veins that were detected in venography studies. Another theory is the reflux theory which supposes that damage or absence of valves in the gonadal veins is the etiology behind varicocele development which most probably is a bilateral disease (8). This explains why a unilateral palpable varicocele can affect the global testicular function (right and left) and why unilateral varicocelectomy may fail to improve sperm parameters in some cases. The current study supports these theories as varicocele bilaterality was found in 98.5% of patients. This finding shows that varicocele bilaterality is clearly underestimated in practice and in the literature.

Our technique of artery preservation varicocelectomy using intraoperative Doppler was previously described. Preserving testicular arteries during varicocelectomy provide significantly better sperm improvement especially in patients with severe oligozoospermia (19).

Regarding the indication of varicocelectomy, current evidence suggests a positive effect of varicocelectomy on sperm parameters and pregnancy rates only in couples with male factor infertility with a clinically palpable varicocele and abnormal semen parameters (18).

Randomized controlled trials looking at the effect of varicocelectomy on sperm parameters and pregnancy outcomes are lacking. Consequently, available meta-analyses are negatively affected by wide heterogeneity of available studies. However, the randomized controlled trial by *Abdel-Meguid et al.* supports the findings of meta-analyses which suggest a beneficial effect of varicocelectomy on sperm parameters. *Abdel-Meguid et al.* in 2011 randomized the patients into subinguinal varicocelectomy (treatment group) and observation (control group). After 1 year of follow up all sperm parameters significantly improved in the treatment group (32.2 ± 10.6 vs $18.1 \pm 5.8 \times 10^6$ sperm/ml, 41.0 ± 10 vs $25.3 \pm 12.8\%$, and 39.0 ± 4.5 vs $31.2 \pm 4.1\%$ for sperm concentration, motility and morphology, respectively); while no significant difference found in the control group (20).

In the current study sperm density and motility signifi-

cantly improved after 3 and 6 months and 35.9% of the couples achieved normal pregnancy after 1 year from varicocelectomy (Table 2).

The points of strength of this study among others is the good sample size, prospective design and using objective tools for varicocele reassessment, while the limitation is the lack of sperm morphology data. To the best of our knowledge, this is one of a very few reports addressing possible underestimation of varicocele bilaterality which must be taken into account during management of male factor infertility.

CONCLUSIONS

Varicocele bilaterality in infertile patients seems to be underestimated in the literature and in clinical practice. In our experience, varicocele bilaterality exists in 98.5% of infertile men. Thorough assessment of varicocele bilaterality in infertile men by expert urologist and andrologists is of utmost importance to avoid disease recurrence and optimize treatment outcomes.

REFERENCES

1. Sigman M, Jarow JP. Male infertility. In: Walsh PC, Retik AB, Vaughn ED, Wein AJ (eds.), *Campbell's Urology 8th ed.* Philadelphia: Saunders 2002; 1475-1532.
2. Yamaguchi M, Sakatoku J, Takihara H. The application of intrascrotal deep body temperature measurement for the non-invasive diagnosis of varicoceles. *Fertil Steril.* 1989; 52:295-301.
3. Masson P, Brannigan RE. The varicocele. *Urol Clin North Am.* 2014; 41:129-144.
4. Sabanegh E, Agarwal A. Male infertility, in *Campbell-Walsh Urology*, A. J. Wein, L. R. Kavoussi, A. C. Novick, and A. W. Partin, Eds., pp. 636-637, Saunders, Philadelphia, Pa, USA, 10th edition, 2012.
5. Tulloch WS. A consideration of sterility factors in the light of subsequent pregnancies. *Edinburgh Med J.* 1952; 59:29-34.
6. Fujisawa M, Ishikawa T, Takenaka A. The efficacy of bilateral varicocelectomy in patients with palpable bilateral varicoceles: comparative study with unilateral varicocele. *Urol Res.* 2003; 31:407-9.
7. Libman J, Jarvi K, Lo K, Zini A. Beneficial effect of microsurgical varicocelectomy is superior for men with bilateral versus unilateral repair. *J Urol.* 2006; 176:2602-5.
8. Gat Y, Bachar GN, Zukerman Z, et al. Varicocele: a bilateral disease. *Fertil Steril.* 2004; 81:424-9.
9. Trum J, Gubler F, Laan R, Van der Veen F. The value of palpation, varicoscreen contact thermography and colour Doppler ultrasound in the diagnosis of varicocele. *Hum. Rep.* 1996; 11:1232-1235.
10. Hussein AF. The role of color Doppler ultrasound in prediction of the outcome of microsurgical subinguinal varicocelectomy. *J Urol.* 2006; 176:2141-2145.
11. Paduch D, Niedzielski J. Repair versus observation in adolescent varicocele: a prospective study. *J Urol.* 1997; 158:1128-32.
12. Gat Y, Bachar GN, Zukerman Z, et al. Varicocele: a bilateral disease. *Fertil Steril.* 2004; 81:424-9.
13. Gonda RL Jr, Karo JJ, Forte RA, O'Donnell KT. Diagnosis of subclinical varicocele in infertility. *AJR Am J Roentgenol.* 1987; 148:71-75.

14. McClure RD, Hricak H. Scrotal ultrasound of infertile man: detection of subclinical unilateral and bilateral varicoceles. *J Urol.* 1986; 135:711-15.
15. Chatel A, Bigot JM, Helenon C, et al. Interet de la phlebographie spermatique dans le diagnostic des sterilités d'origine circulatoire (varicocele). Comparaison avec les données cliniques, thermographiques et anatomiques. *Ann. Rad.* 1978, 21:565.
16. Gonzalez R, Reddy P, Kaye KW, Narayan P. Comparison of Doppler examination and retrograde spermatic venography in the diagnosis of varicocele. *Fertil Steril.* 1983; 40:96-9.
17. Cockett ATK, Harrison RM, Comhaire F, Dubin L. The varicocele and its effect on fertility. *Contemp Surg* 1984; 24:111-14.
18. Jensen CFS, Østergren P, Dupree JM, et al. Varicocele and male infertility. *Nat Rev Urol.* 2017; 14:523-533.
19. Almekaty K, Zahran MH, Zoeir A, et al. The role of artery-preserving varicolectomy in subfertile men with severe oligozoospermia: a randomized controlled study. *Andrology.* 2019; 7:193-198.
20. Abdel-Meguid TA, Al-Sayyad A, Tayib A, Farsi HM. Does varicocele repair improve male infertility? An evidence-based perspective from a randomized, controlled trial. *Eur Urol.* 2011; 59:455-461.

Correspondence

Khaled Mohamed Almekaty, MD
dr.khaledhafez@med.tanta.edu.eg

Maged Mostafa Ragab, MD
mmregy@yahoo.com

Khaled Abdelaziz Salem, MD
khsalemmd@gmail.com

Ahmed Fayed Ghaith, MD (Corresponding Author)
dr_ahmedfayed@yahoo.com

Urology Department, Tanta University, Tanta, Egypt
El-Gharbia Governorate, Tanta. El-Gash st. Medical Campus, The Faculty of Medicine

Ahmed Mostafa Elsharkawy, MD
ahmed.elsharkawy84@gmail.com

Radiology Department, Tanta University, Tanta, Egypt

Mohamed Hasan Zahran, MD
ahmed.elsharkawy84@gmail.com

Mansoura Urology and Nephrology Centre, Mansoura University, Mansoura, Egypt

Ayman Sayed Rashed, MD
aymanrashed@msn.com

Urology Department, 6th of October University, Cairo, Egypt

Mahmoud Mohamed Soliman, MD
dr_mahmoudsoliman@yahoo.com

Obstetrics and Gynecology Department, Cairo University, Cairo, Egypt

Conflict of interest: The authors declare no potential conflict of interest.