

CYCLOSPORINE A FOR THE TREATMENT OF HODGKIN'S DISEASE IN RELAPSE AFTER EXTENSIVE CHEMOTHERAPY

ZDRAVLJENJE HODGKINOVE BOLEZNI V RELAPSU
PO KEMOTERAPIJI S CIKLOSPORINOM A

Zwitter M., Drinovec J., Vodnik-Cerar A., Žemva Ž.

Abstract — Cyclosporine A was given to two patients with Hodgkin's disease in relapse after previous MOPP and ABVD chemotherapy. Both patients had B symptoms and both an extensive relapse with involvement of bone marrow, spleen, and lymph nodes. Cyclosporine A was given orally at the initial dose 12.5 mg/kg, and the dose was later adjusted according to blood cyclosporine levels. In both patients fever disappeared, serum copper fell to within normal range, and a partial remission of the enlarged lymph nodes was recorded. Experience with more patients resistant to standard chemotherapy and followed for a longer period of time will show the perspectives of this new approach.

UDC: 616-006.442.085

Key words: Hodgkin's disease-drug therapy cyclosporins

Orig. sc. paper

Radiol. Iugosl. 19(4) 297—300, 1985

Introduction — Patients with Hodgkin's disease (HD) in relapse soon after extensive chemotherapy have only slim chances for a successful treatment, specially so if the relapse is accompanied by systemic (B) symptoms. We would like to report on two such patients who markedly improved upon treatment with Cyclosporine A (Cy A).

Case 1. In January, 1984, a 24-years old woman was found to have HD, mixed cellularity type, stage IV. B with extensive lymph node involvement and with lung infiltrates. She was first treated with MOPP, attained a short partial remission, and was then switched to ABVD combination, with only a partial response. In May, 1985, an extensive relapse was found with fever and with microscopically confirmed involvement of bone marrow, spleen, and lymph nodes both above and below the diaphragm (Fig. 1.). After informed consent, she was started on oral Cy A at the initial dose of 12.5 mg/kg. In three weeks, pain in the back (due to massive retroperitoneal nodes) subsided, and so did sweating and fever. A regression of the nodes was confirmed both clinically and by CT scan (Figure 2.). Serum

copper fell to within normal limits. Prednisone was then added at the dose 30mg/day, since the combination of Cy A with prednisone has been recommended for a better immunosuppression and less nephrotoxicity (5). Partial remission lasted till September when fever appeared again, lymph nodes progressed, and serum copper rose. At the same time, for an unknown reason, blood Cy A levels were below the therapeutic range (Figure 3.). The daily Cy A dose was then increased, and all parameters of disease activity resolved as soon as the blood Cy A levels rose over 400 ng/ml. Six month after the treatment with Cy A was instituted, the patient is in excellent general condition, without B symptoms and with partial regression of lymph nodes, as followed clinically and rentgenologically. Except for a moderate hypertrichosis and a slight impairment of renal function, no side effects have been observed.

This patient obviously had an aggressive form of disease with a short anamnesis, high initial stage, and poor response to standard chemotherapy. Under these circumstances, an improvement lasting for

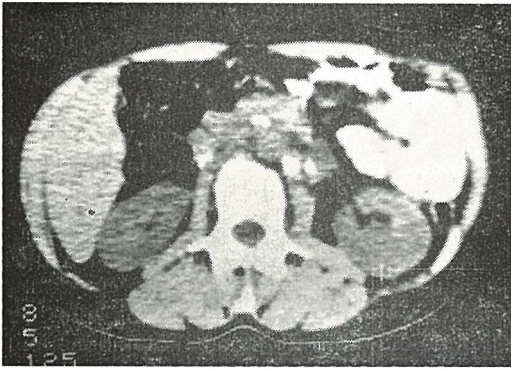


Fig. 1 — Case 1: enlarged retroperitoneal lymph nodes prior to Cy A

Slika 1 — Prvi bolnik: povečane retroperitonealne bezgavke pred Cy A

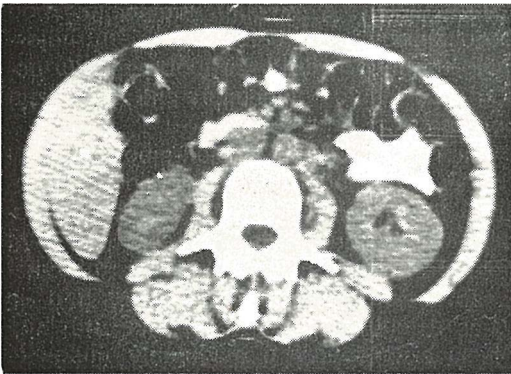


Fig. 2 — Retroperitoneal lymph nodes after three months of Cy A treatment

Slika 2 — Retroperitonealne bezgavke po treh mesecih zdravljenja s Cy A

more than six months should be regarded as a success. It seems unlikely that prednisone, used also previously during MOPP treatment had a major therapeutic role. An observation of disease progression correlating with low blood Cy A levels supports our belief that it is Cy A which had a decisive role in reversing the disease activity.

Case 2. A 27-years old man has been treated since September, 1981, when a diagnosis of HD, nodular sclerosis type, initial stage VI. A was made. His initial treatment was MOPP, followed by irradiation to the involved areas. A relapse in non-irradiated lymph nodes was diagnosed in March, 1984, and MOPP/ABVD alternation chemotherapy was given, resulting in a short remission.

From March till July, 1985, another relapse was treated by Vinblastine and additional irradiation. In September, fever and malaise re-appeared. Lymph node biopsy from the right axilla confirmed a relapse of HD. Other involved areas included mediastinum, lung parenchyma, liver, spleen, and bone marrow. After informed consent, Cy A at the initial dose of 12.5 mg/kg was given. The initial blood Cy A levels were around 1100 ng/ml, and the oral dose has been currently set at 6 mg/kg, aiming at blood Cy A levels between 400 and 800 ng/ml. B symptoms regressed after a few days of Cy A treatment and the previously markedly elevated serum copper returned to normal. No subjective or objective side effects of the treatment have been seen.

Discussion — The idea that immunosuppression in HD might represent the goal of the treatment, and not its side effect has been explained previously (8). While weak *in vivo* and *in vitro* immune responses are characteristically seen in remission, longitudinal studies have shown that a re-activation of the *in vitro* PHA responsiveness frequently heralds a relapse of the disease (7). Another similar observation comes from a randomized prospective study where patients in remission were given either immunostimulation with BCG, or no further therapy, and relapses were more frequent in the BCG group (1). Finally, it is a common clinical experience that an infection may provoke a relapse of a malignant lymphoma.

Cy A is not cytotoxic, but selectively inhibits the activation processes during an immune reaction (2). The drug was found to be effective not only in organ transplantation, but also in a wide variety of autoimmune diseases (4), and in Sézary syndrome (6). Our favourable experience with Cy A in HD indicates that also oncologists will have to re-examine their so far negative attitude towards immune suppression which may actually help to restrain HD as a proliferative, or a neoplastic disease of the immune system (9). Few side effects of Cy A have been seen in our patients, and oral route of drug administration is an important advantage for the patients who may have sclerosis of the veins due to previous che-

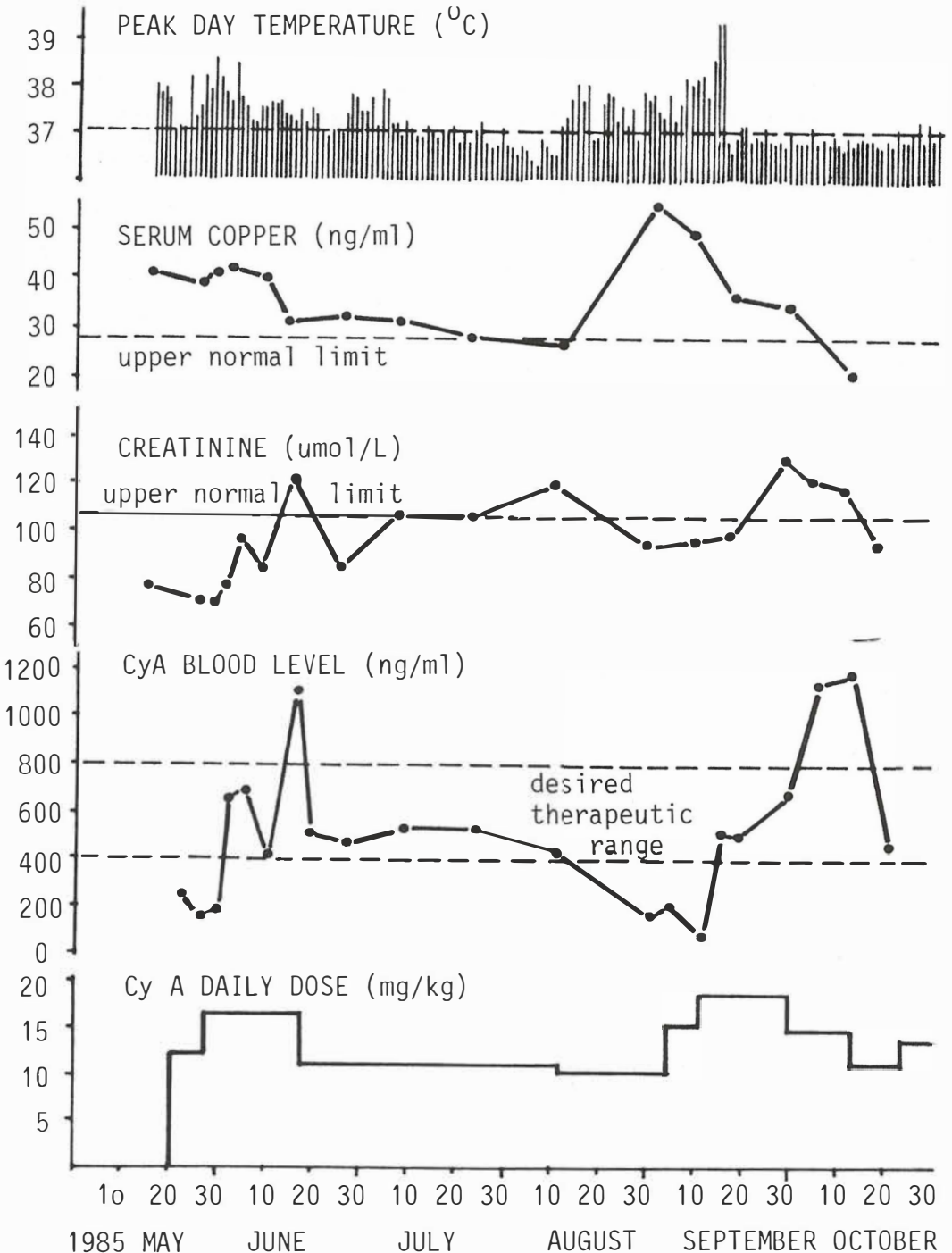


Fig. 3 — Daily dose of Cy A, Cy A blood levels, creatinine, serum copper, and peak daily temperature through six months of Cy A treatment

Slika 3 — Dnevne doze Cy A, koncentracije Cy A v krvi, kreatinin, serumski baker in najvišja dnevna temperatura v šestih mesecih zdravljenja s Cy A

therapy. The principal side effect of Cy A is nephrotoxicity: proper hydration, meticulous monitoring of renal function, and adjustment of the oral dose of Cy A according to blood Cy A levels are essential if renal damage is to be avoided (3). It is hoped that future carefully planned trials of Cy A in HD patients with no standard treatment left will bring answers to the effectiveness of this drug in HD, short- and long-term side effects, duration of treatment, and possible re-activation of the disease process after the treatment would be stopped.

Acknowledgement — Cyclosporine A was kindly provided by Dr. B. von Graffenried, Sandoz AG, Basel, Switzerland. The authors would also like to thank Neta Zwitter for drawing the figure.

Povzetek

S ciklosporinom A so avtorji zdravili dva bolnika s Hodgkinovo boleznijo v relapsu po poprejšnji kemoterapiji po shemah MOPP in ABVD. Oba bolnika sta imela B simptome in obsežen relaps s prizadetostjo kostnega mozga ter vranice in bezgavk. Ciklosporin A so dali oralno v začetni dozi 12,5 mg/kg, kasneje pa so dozo prilagodili nivoju ciklosporina v krvi. Pri obeh bolnikih je temperatura padla, serumski baker se je znižal na normalo in zabeležili so parcialno remisijo povečanih bezgavk. Da bi ocenili perspektive tega novega pristopa k zdravljenju Hodgkinove bolezni, bo potrebno zdraviti več bolnikov in jih slediti dlje časa.

References

1. Bakemeier R. F., Anderson J. R., Costello W., et al.: BCVPP chemotherapy for advanced Hodgkin's disease: evidence for greater duration of complete remission, greater survival, and less toxicity than with MOPP regimen. *Ann. Intern. Med.* 101 : 447—456, 1984.
2. Borel J. F., Lafferty K. J.: Cyclosporine: speculation about its mechanism of action. *Transplant. Proc.* 15: 1881—1885, 1983.
3. Palestine A. G., Nussenblatt R. B., Chan C.: Side effects of systemic cyclosporine in patients not undergoing transplantation. *Am. J. Med.* 77: 652—656, 1984.
4. Schindler R. (ed.): Cyclosporin in autoimmune diseases. Springer-Verlag, Berlin 1985.
5. Thiel G., Harder F., Lörtscher R. et al.: Cyclosporin A used alone or in combination with low-dose steroids in cadaveric renal transplantation. *Klin. Wochenschr.* 61: 991, 1983.

6. Tötterman T. H., Scheynius A., Killander A. et al.: Treatment of therapy-resistant Sézary syndrome with Cyclosporin A: suppression of pruritus, leukemic T cell activation markers and tumor mass. *Scand. J. Hematol.* 34: 196—203, 1985.

7. Van Rijswijk R. E. N., Sybesma J. P. H. B., Kater L.: A prospective study of the changes in the immune status before, during and after multiple-agent chemotherapy for Hodgkin's disease. *Cancer* 51: 637—644, 1983.

8. Zwitter M.: Hodgkin's disease: therapeutic role of measles vaccine. *Am. J. Med.* 77 (6): A 49—A 52, 1984.

9. Zwitter M.: Hodgkin's disease: five steps from autoimmunity to cancer. *Med. Hypoth.* 15: 399—413, 1984.

Author's adress: mag. dr. Matjaž Zwitter, Institute of Oncology, Zaloška 2, 61105 Ljubljana, Yugoslavia.