

Coronary-air-embolism-What-should-we-do

by Endin Nokik Stujanna Uploaded By Fauzan

Submission date: 18-Aug-2023 01:22PM (UTC+0700)

Submission ID: 2147433174

File name: Coronary-air-embolism-What-should-we-do.pdf (2.01M)

Word count: 1655

Character count: 9137

Coronary air embolism: What should we do?

Sidhi Laksono Purwowyoto^{1,2}, Hillary Kusharsamita³, Zahra Nurushofa², Ety Farida², Endin Nokik Stujanna²

Abstract

Background: Coronary air embolism continues to be a known complication of coronary catheterization despite the notable focus on prevention.

Case presentation: Here, we report a case of coronary air embolism (CAE) of the right coronary artery (RCA) during coronary angiography (CAG). The patient developed unstable hemodynamics with a sign of ST elevation during the

event. The patient recovered after simultaneous management, including oxygen, an injection of norepinephrine, atropine, morphine, and intracoronary aspiration, which successfully resolved the air emboli.

Conclusion: If a patient appears with chest pain, hypotension, or arrhythmias, clinicians should consider CAE as a differential diagnosis and perform CAG to confirm the existence of a distinct bubble.

Key words: Coronary air embolism, coronary angiography, intracoronary catheter aspiration.

1 Introduction

Coronary air embolism (CAE) is a very uncommon complication of cardiac catheterization, accounting for 0.3 to 1% of all diagnostic coronary angiography (CAG) and percutaneous coronary intervention (PCI) cases. (1) A significant incidence of morbidity and death is associated with CAE. Even with tiny bubbles, tissue ischemia from oxygen deprivation

causes cell injury and irreversible damage. (2) Complications of an air embolism might range from clinically vague symptoms to acute coronary syndrome and death. (3) Specific guidelines for handling CAE during a cardiac catheterization are not clear and are based on the experiences of each medical professional. (2) We report a rare case of an unexpected coronary artery air embolism during coronary angiography.

Case report

A patient came for a medical check-up with a result suggestive of cardiac ischemia. Cardiac computed tomography (CT) was then performed. CT scan revealed a significant coronary artery disease (CAD) in the right coronary artery (RCA) and the left anterior descending (LAD) artery with a CT coronary calcium score (CTCS) of 450.

The CAG was then executed. The moment before intravenous ultrasonography (IVU) was performed as an adjunctive to CAG, the angiogram showed multiple air emboli were introduced to RCA. An air embolism interrupted the mid-portion of the blood flow in the RCA to its distal circulation, and the patient then became hemodynamically unstable with hypotension and bradycardia (Figure 1A). In addition, there was a sign of ST elevation during the event (Figure 1B).

¹Department of Cardiology and Vascular Medicine, Pertamina Central Hospital, South Jakarta, Indonesia

²Faculty of Medicine, Universitas Muhammadiyah Prof. Dr. Hamka, Tangerang, Indonesia

³Faculty of Medicine, Universitas Diponegoro, Semarang, Indonesia

Address for correspondence:

Sidhi Laksono
Faculty of Medicine, Universitas Muhammadiyah Prof. Dr. Hamka

Jl. Raden Patah No. 01, Tangerang, Banten 13460, Indonesia

+628111585599

ORCID ID: <https://orcid.org/0000-0002-2959-8937>

Email: sidhilaksono@uhamka.ac.id

2 The patient was given 100% oxygen and IV atropine injections and put on IV norepinephrine. Simultaneously, an attempt was made to disperse the air emboli in 9 distal coronary circulation by Thrombuster. A coronary wire was tracked down the RCA, and multiple passages of intracoronary aspiration were done with a Thrombuster aspiration device. IV injection of morphine was also given as an analgesic. The hemodynamics slowly improved with the rise of blood pressure and heart rate in accordance with the improvement of electrocardiogram findings. Later, we repeated the CAG and confirmed the disappearance of the air embolism, and sufficient blood flow was obtained in the right coronary artery (Figure 2).

Discussion

Although it is rare, CAE is a complication of coronary angiography and angioplasty that can be prevented. An air embolism is diagnosed angiographically when distinct bubbles are detected in the coronary artery. CAE may cause the angiographic appearance of discrete vascular cut-offs due to vessel occlusion and slow flow phenomenon. (4) During coronary angiography, air embolism is nearly invariably iatrogenic. Improperly flushed catheters can cause it, and also the insertion or removal of balloon catheters and guidewires, balloon rupture, a right-to-left air shunt caused by an intracardiac shunt, 1 imaged manifold systems, leaky equipment, and self-venting catheters that are left outside the body with constant negative suction. (5) Our patient's poor aspiration of the diagnostic catheter appeared to let air enter, resulting in many air bubbles in the RCA that were visible during angiography. According to one study, in CAE, the RCA was damaged in 31% of cases and the LAD in 2%. (5)

There is a correlation between the amount of air that enters the coronary arteries and the mortality and symptomatology of air embolism. (4,5) After the air has been injected, an air lock may occur, preventing perfusion of the distal coronary bed. Chest discomfort, hypotension, myocardial ischemia, arrhythmias such as bradycardia, heart block, ventricular tachycardia, fibrillation, and cardiac arrest can all be symptoms of air embolism. They can also be asymptomatic. (6) Multiple air bubbles blocked RCA distal perfusion in our patient. While it initially resulted in hypotension and bradycardia, ST-segment elevation was observed later.

Before the procedure, operators must meticulously arrange the systems by aspirating the catheters, tightening all connections, and maintaining the manifold upright. (4) Multiple treatment options exist to effectively resolve an air embolism and restore

blood flow to the damaged coronary artery. It includes the use of 100% oxygen to stimulate nitrogen diffusion, transiently increasing intra-atrial pressure using inotropes and an intra-aortic balloon pump, injecting blood or saline forcefully to disperse intracoronary air, using thrombectomy catheters to aspirate air from the embolism, and administering vasodilators (adenine, calcium channel blockers, and nitrates) to treat slow coronary flow. (5)

Our case showed that hemodynamic compromise might arise quickly, precipitating an emergency, and could also be resolved quickly following immediate treatment, which involved simultaneous aspiration of air using thrombectomy catheters (Thrombuster), 100% oxygen therapy, and intravenously atropine and norepinephrine injections. In addition, morphine was administered intravenously as an analgesic.

The preservation and maintenance of vital functions is the fundamental objective of therapy. Therapy aims to preserve coronary blood flow while seeking to dissipate air bubbles. Air embolization may be resolved quicker when breathing with 100% oxygen than in room air, which includes mostly nitrogen gas. (2) The oxygen aids in the alleviation of ischemia. It eliminates nitrogen by diffusing down the concentration gradient and out of the air embolism, reducing the air bubbles' size. (4) Intravenous inotropic drugs should be administered following current clinical conditions to raise the patient's mean arterial blood pressure for a short period. Vasoconstriction and the resulting rise in mean arterial pressure stimulate the division of bubbles more proximal in the vascular bed, resulting in a more rapid dispersion of bubbles. (7) The direct aspiration of bubbles has been documented using thrombectomy catheters (Export, Diver, and Pronto) or over-the-wire balloon catheters. (2) One massive CAE case reported described a successful air aspiration utilizing the Thrombuster II (Kaneka Medical Products, Osaka, Japan) aspiration device, (8) which we executed in this case. Nevertheless, the best way to manage a CAE is to prevent it from happening in the first place, which may be done by aspirating catheters carefully and flushing the coronary equipment thoroughly. (5)

Conclusion

Every operator should obtain training on preventing and controlling CAE since it is preventable. To avoid related mortality and morbidity, cardiac catheterization devices should be flushed adequately, and catheters should be aspirated meticulously as primary prevention. Clinicians should consider CAE as a differential diagnosis if a patient presents

with chest discomfort, hypotension, or arrhythmias and performs CAG afterward to confirm the presence of a different bubble. CAE is treated with 100% oxygen, an IV infusion of norepinephrine, an injection of atropine, intracoronary aspiration with an aspiration device, and additional analgesics such as IV morphine.

17 **knowledge**

The authors thank all who supported this manuscript.

Conflict of interest

Nothing to declare.

4

Figure 1A. The blood flow in the middle of the right coronary artery was interrupted by air embolisms

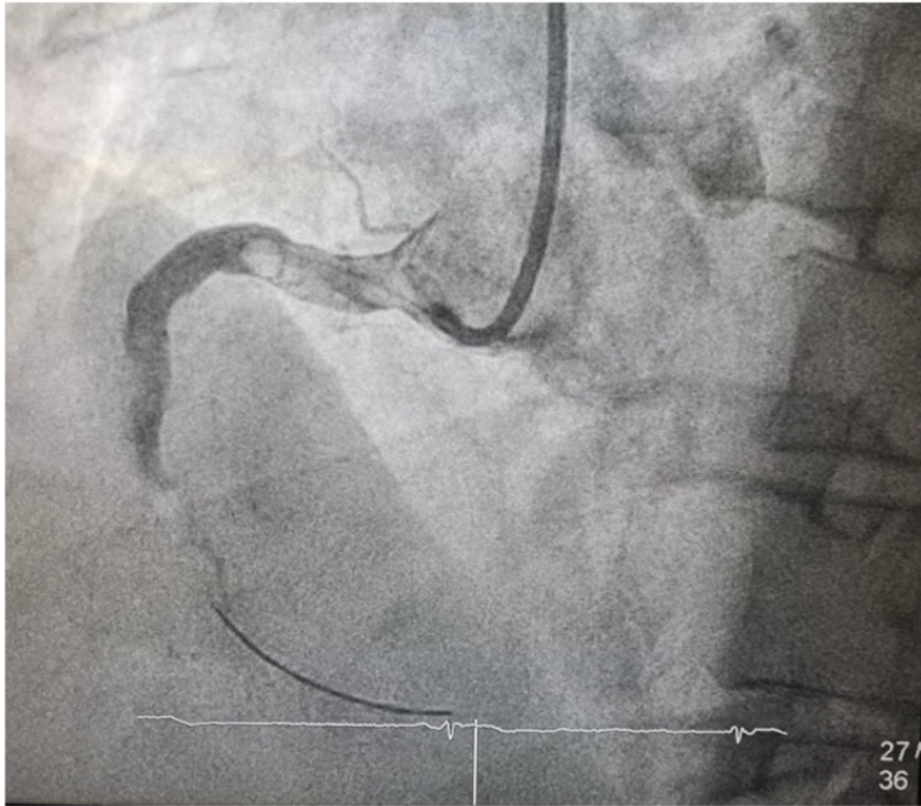


Figure 1B. An elevation of the ST segment

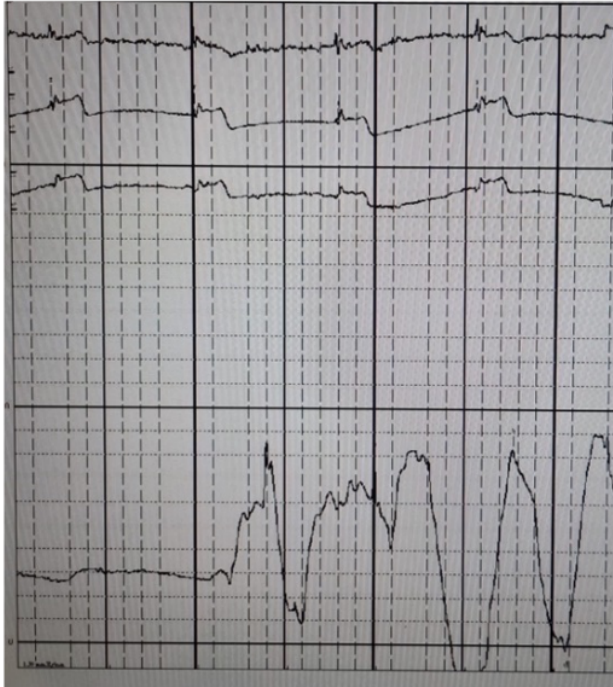
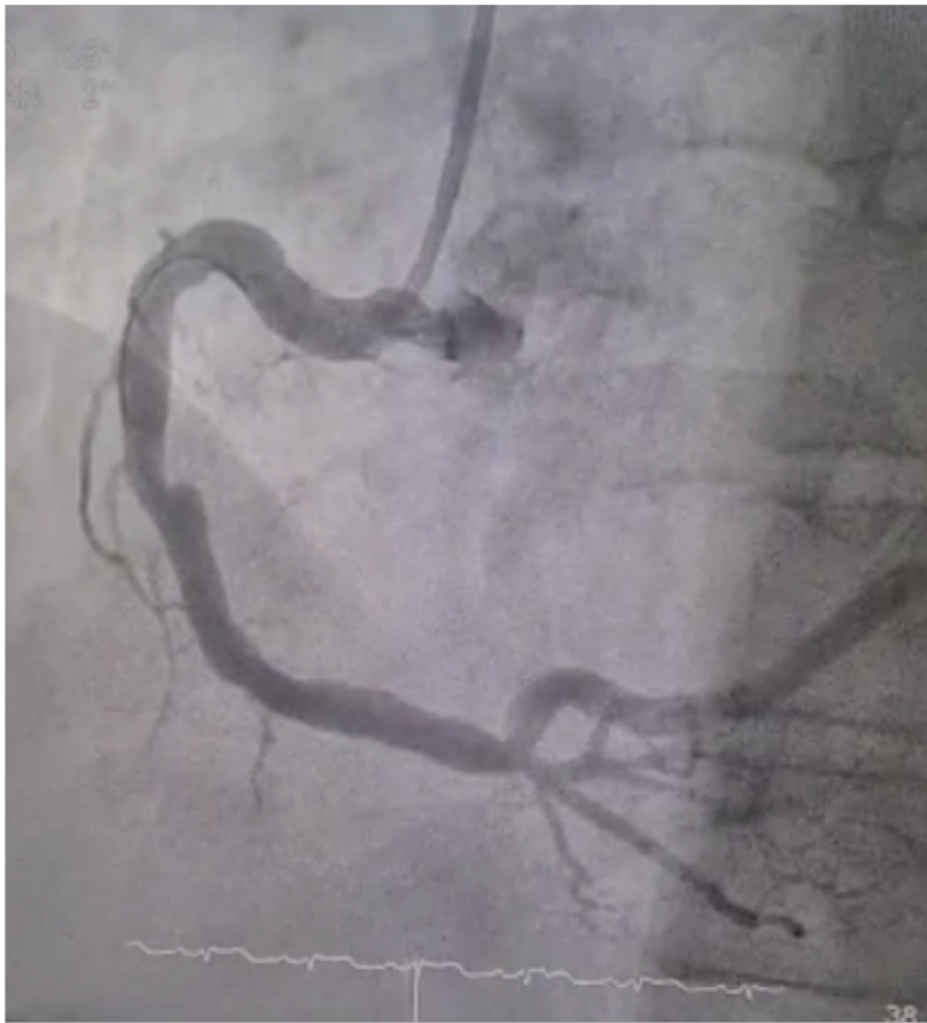
Figure 2. The angiography ¹² of the right coronary artery with no remaining air emboli



References

1. Kelly DJ. Coronary Air Embolism. In: Lindsay A, Chitkara K, Di Mario C, editors. *Complications of Percutaneous Coronary Intervention*. Springer London; 2016.
2. Dib J, Boyle AJ, Chan M, Resar JR. Coronary air embolism: A case report and review of the literature. *Catheter Cardiovasc Interv* 2006;68: 879-900.
3. Kahn JK, Hartzler GO. The spectrum of symptomatic coronary air embolism during balloon angioplasty: causes, consequences, and management. *Am Heart J* 1990;119:1374-7.
4. Suastika LOS, Oktaviono YH. Multiple Air Embolism During Coronary Angiography: How Do We Deal With It? *Clin Med Insights Cardiol* 2016;10:67-70.
5. Kariyanna PT, Jayarangaiah A, Jayarangaiah A, Hegde S, Marmur JD, Haseeb S, et al. Coronary Air Embolism During Coronary Angiography : A Systematic Review. *Scied J Cardiol* 2018; 15:16.
6. Topol EJ, Teirstein PS. *Textbook of Interventional Cardiology*. 7th ed. Philadelphia (PA): Elsevier; 2016.
7. Van Blankenstein JH, Slager CJ, Schuurbiens JCH, Strikwerda S, Verdouw PD. Heart function after injection of small air bubbles in coronary artery of pigs. *J Appl Physiol* (1985) 1993;75:1201-7.
8. Yew KL, Razali F. Massive coronary air embolism successfully treated with intracoronary catheter aspiration and intracoronary adenosine. *Int J Cardiol* 2015;188:56-7.

This page is intentionally left blank

Coronary-air-embolism-What-should-we-do

ORIGINALITY REPORT

34%

SIMILARITY INDEX

24%

INTERNET SOURCES

29%

PUBLICATIONS

17%

STUDENT PAPERS

PRIMARY SOURCES

1

erepo.unud.ac.id

Internet Source

5%

2

journals.sagepub.com

Internet Source

4%

3

hvt-journal.com

Internet Source

3%

4

spandidos-publications.com

Internet Source

3%

5

Submitted to Universitas Diponegoro

Student Paper

3%

6

Joud Dib, Andrew J. Boyle, Michael Chan, Jon R. Resar. "Coronary air embolism: A case report and review of the literature", Catheterization and Cardiovascular Interventions, 2006

Publication

2%

7

jcdronline.org

Internet Source

2%

8

journals.lww.com

Internet Source

2%

2%

9

Yew, Kuan Leong, and Farah Razali. "Massive coronary air embolism successfully treated with intracoronary catheter aspiration and intracoronary adenosine", International Journal of Cardiology, 2015.

Publication

10

Submitted to Carnegie Mellon University

Student Paper

1%

11

"Complications of Percutaneous Coronary Intervention", Springer Nature, 2016

Publication

1%

12

M.-J. Hung. "Irreversible Myocardial Damage After Coronary Air Embolism: A Case Report", Angiology, 03/01/2002

Publication

1%

13

www.actamedindones.org

Internet Source

1%

14

Submitted to Santa Barbara City College

Student Paper

1%

15

William S. Weintraub, William E. Boden. "Reexamining the Efficacy and Value of Percutaneous Coronary Intervention for Patients With Stable Ischemic Heart Disease", JAMA Internal Medicine, 2016

Publication

1%

16 Debabrata Dash. "Complications of coronary intervention: device embolisation, no-reflow, air embolism", Heart Asia, 2013 1 %
Publication

17 banglajol.info 1 %
Internet Source

18 www.coursehero.com 1 %
Internet Source

19 jddtonline.info 1 %
Internet Source

20 Luh Oliva Saraswati Suastika, Yudi Her Oktaviono. "Multiple Air Embolism during Coronary Angiography: How do We Deal with it?", Clinical Medicine Insights: Cardiology, 2016 <1 %
Publication

Exclude quotes Off

Exclude matches Off

Exclude bibliography Off