



Factors impacting time to total shoulder arthroplasty among patients with primary glenohumeral osteoarthritis and rotator cuff arthropathy managed conservatively with corticosteroid injections

Dhruv S. Shankar, Edward S. Mojica, Christopher A. Colasanti, Anna M. Blaeser, Paola F. Ortega, Guillem Gonzalez-Lomas, Laith M. Jazrawi

Department of Orthopedic Surgery, New York University Langone Health, New York, NY, USA

Background: The purpose of this study was to identify predictors of the time from initial presentation to total shoulder arthroplasty (TSA) in patients with primary glenohumeral osteoarthritis (OA) and rotator cuff (RTC) arthropathy who were conservatively managed with corticosteroid injections.

Methods: We conducted a retrospective cohort study of patients who underwent TSA from 2010 to 2021. Kaplan-Meier survival analysis was used to estimate median time to TSA for primary OA and RTC arthropathy patients. The Cox proportional hazards model was used to identify significant predictors of time to TSA and to calculate hazard ratios (HRs) with 95% confidence intervals (CIs). Statistical significance was set at $P < 0.05$.

Results: The cohort included 160 patients with primary OA and 92 with RTC arthropathy. In the primary OA group, median time to TSA was 15 months. Significant predictors of shorter time to TSA were older age at presentation (HR, 1.02; 95% CI, 1.00–1.04; $P = 0.03$) and presence of moderate or severe acromioclavicular joint arthritis (HR, 1.45; 95% CI, 1.05–2.01; $P = 0.03$). In the RTC arthropathy group, median time to TSA was 14 months, and increased number of corticosteroid injections was associated with longer time to TSA (HR, 0.87; 95% CI, 0.80–0.95; $P = 0.003$).

Conclusions: There are distinct prognostic factors for progression to TSA between primary OA patients and RTC arthropathy patients managed with corticosteroid injections. Multiple corticosteroid injections are associated with delayed time to TSA in RTC arthropathy patients.

Level of evidence: III.

Keywords: Arthroplasty; Shoulder; Osteoarthritis; Steroids; Retrospective studies

INTRODUCTION

Total shoulder arthroplasty (TSA) is the treatment for several shoulder pathologies including end-stage glenohumeral osteoarthritis (OA), inflammatory arthritis, rotator cuff (RTC) arthropathy, and humeral fractures [1]. Following TSA, marked improve-

ment in pain and function is consistently reported and patient satisfaction is high [2,3]. Due to the excellent outcomes observed, the number of TSA procedures performed rose substantially through the 2010s [4]. Though the benefit of TSA is evident, the risk for postoperative complications including infection and need for further surgery is present. Therefore, the use of non-surgical

Received: July 18, 2022 Revised: December 23, 2022 Accepted: December 25, 2022

Correspondence to: Dhruv S. Shankar

Department of Orthopedic Surgery, New York University Langone Health, 333 East 38th St, 4th Floor, New York, NY 10016, USA

Tel: +1-240-848-8645, Fax: +1-240-660-5485, Email: dhruv.shankar@nyulangone.org, ORCID: <https://orcid.org/0000-0002-4153-9382>

Copyright© 2023 Korean Shoulder and Elbow Society.

This is an Open Access article distributed under the terms of the Creative Commons Attribution Non-Commercial License (<http://creativecommons.org/licenses/by-nc/4.0/>) which permits unrestricted non-commercial use, distribution, and reproduction in any medium, provided the original work is properly cited.

treatment to delay surgery is of interest to patients and surgeons alike.

Prior to TSA, conservative management focuses on relief of symptomatic shoulder pathology, and a mainstay of this approach is intra-articular corticosteroid injections. Following corticosteroid injections, patients with shoulder pathology have reported decreased pain, increased function, and improved joint mobility [5,6]. In addition, when the injections provide relief, patients opt to delay operative treatment for some time. However, while the short-term benefits of corticosteroids have been well-characterized [7,8], little research has focused on the amount of time corticosteroid injections can “buy” before surgery, specifically TSA, is required. Furthermore, whether the time from initial presentation to TSA differs between patients with primary glenohumeral OA and those with RTC arthropathy is unclear. In addition, differences in prognostic factors between these two groups have not been determined.

The purpose of this study was to compare the time from initial presentation to primary TSA in patients who underwent conservative management for primary OA or RTC arthropathy with corticosteroid injections and to identify any independent predictors of this duration of time. We hypothesized that RTC arthropathy patients would have longer time to TSA than primary OA patients and that age, severity of glenohumeral OA, and number of injections received would be predictive factors for time to TSA in both groups.

METHODS

We conducted this retrospective cohort study in compliance with the principles of the Declaration of Helsinki. The study’s protocol was reviewed and approved by the Institutional Review Board of New York University Langone Health (No. #19-01430). Informed consent was waived.

Eligibility Criteria and Cohort Selection

Patients with primary glenohumeral OA or RTC arthropathy who underwent first-time corticosteroid shoulder injection prior to undergoing primary TSA were included in the cohort. The date range for injections and surgeries was from January 1, 2010, to December 1, 2021. Primary TSA procedures included either anatomic TSA (aTSA) or reverse TSA (rTSA). Both the index injection and index procedure were performed at the study institution. Patients who received other shoulder injections, e.g., corticosteroid or hyaluronic acid, prior to the index corticosteroid injection; who received non-corticosteroid injections in the interim between first injection and TSA; who had any prior open or ar-

throscopic surgery on the index shoulder; or who had any history of rheumatic joint disease, such as rheumatoid arthritis, were excluded.

Diagnostic Criteria and Surgical Indications

Primary glenohumeral OA was diagnosed based on a combination of clinical and radiographic features. Presenting symptoms included shoulder pain with motion; pain at night, particularly when sleeping on the affected shoulder; and reduced range of motion. Radiographic features of primary OA included joint space narrowing, subchondral sclerosis and/or cystic changes, inferior humeral head osteophytes ≥ 3 mm in length, and posterior subluxation of the humeral head with an index of subluxation $> 55\%$ [9]. RTC arthropathy was diagnosed using the same clinical and radiographic criteria along with supraspinatus/infraspinatus atrophy and/or pseudoparalysis, superior migration of humeral head (defined as an acromiohumeral interval < 7 mm) with or without acetabularization of the acromial undersurface, and RTC tear with fatty infiltration and/or retraction.

aTSA was indicated for patients with symptomatic glenohumeral OA without associated RTC arthropathy, irreparable RTC tear, inadequate bone stock, brachial plexus palsy, or joint infection. rTSA was indicated for patients with symptomatic glenohumeral OA with associated RTC arthropathy, rheumatoid arthritis, pseudoparalysis, non-union or mal-union of the greater tuberosity, B2 glenoid (if elderly), and/or three- or four-part proximal humerus fracture (if elderly). There was no difference in surgical indications between patients who received one versus multiple corticosteroid injections, but all patients were required to wait at least 3 months after their last injection before undergoing surgery in order to minimize the risk of periprosthetic joint infection.

Data Collection

Dates of initial presentation, first corticosteroid injection, and TSA surgery were obtained from electronic medical records. The time in months between the initial presentation and TSA procedure was used as the primary measure for this study. The number of additional corticosteroid injections received between the initial injection and surgery was also recorded. Demographics, age, sex, body mass index (BMI), and comorbidities, history of smoking diabetes mellitus, hypertension, coronary artery disease, hypothyroidism, chronic kidney disease, or cancer, at the time of presentation were also obtained from medical records. Diagnosis of primary glenohumeral OA or RTC arthropathy was obtained from clinic visit notes.

Anteroposterior and lateral plain radiographs taken at the initial clinical visit were used to grade shoulder OA severity. OA of

the glenohumeral joint was graded using the Kellgren-Lawrence (KL) classification system while acromioclavicular joint (ACJ) OA was graded on a 4-point scale ranging from none (0) to mild (1), moderate (2), and severe (3). For subjects with RTC arthropathy, severity of arthropathy on plain radiographs was graded using the Hamada classification system [10]. For all patients, presence of these was also noted on plain radiographs: subchondral sclerosis, posterior/superior subluxation of the humeral head, joint space narrowing, and inferior humeral head osteophytes. Preoperative computed tomography (CT) scans were used for operative planning and to identify the presence and degrees of glenoid retroversion. Intraoperative reports were used to identify the severity of glenohumeral pathology including: RTC tears, osteophytic changes, and chondral degeneration with concomitant long head of the biceps tendon (LHBT) and labral tears.

Corticosteroid Treatment Protocol

Once shoulder OA was clinically diagnosed, the appropriately trained orthopedic surgeon and patient discussed the viability of corticosteroid injections as a treatment option. Injections were either performed in-office using palpation or ultrasound guidance or in an interventional radiology suite using fluoroscopic guidance. Injection method (fluoroscopic or in-office) was abstracted from patient notes. At our institution, injection cocktails vary slightly between providers but typically consist of 1–2 mL triamcinolone acetonide (40 mg/mL) mixed with 2–3 mL of 1% lidocaine. Injections were administered intra-articularly using sterile technique. Patients were permitted to take anti-inflammatory medications up to 48 hours after injection for treatment of post-injection pain (“cortisone flare”).

Statistical Analysis

All statistical analyses were performed in SAS ver. 9.4 (SAS Institute). Descriptive statistics were calculated for continuous variables (means and standard deviations) and categorical variables (counts and percentages). Continuous variables were assessed for normality using the Shapiro-Wilk test, and all were found to be non-normally distributed. Inter-group comparisons of continuous variables were performed using Mann-Whitney U-test. Inter-group comparisons of categorical variables were performed using Fisher’s exact test. Median survival time from initial consult to TSA, i.e., the time by which 50% of the cohort had undergone TSA, was estimated using the Kaplan-Meier method. Predictors of initial consult-to-TSA time were identified separately for the primary OA and RTC arthropathy cohorts using the Cox proportional hazards model.

Predictor variables entered into the model included: age at

time of initial consult; sex; BMI at time of initial consult; history of smoking, diabetes mellitus, hypertension, or hypothyroidism; KL grade of glenohumeral OA (grade 4 vs. grades 1–3); grade of ACJ OA (grades 2–3 vs. grades 0–1); Hamada classification of RTC arthropathy (grades 4a–5 vs. grades 1–3); presence of glenoid retroversion, subchondral sclerosis, or posterior subluxation of the humeral head; complete loss of the glenohumeral joint space; presence of inferior humeral head osteophytes; number of corticosteroid injections received; time from initial consult to first corticosteroid injection; and use of ultrasound or fluoroscopic image guidance during injection. Backward selection was applied to eliminate predictor variables that did not significantly contribute to the model. Hazard ratios (HRs) with 95% Wald confidence intervals (CIs) were calculated for each of the significant predictors remaining in the model. Overall significance of the model fit was assessed using the chi-square values for the likelihood ratio and Wald statistic. All P-values < 0.05 were considered significant.

RESULTS

Patient Flow

The initial search of the electronic medical record system yielded 524 patients who had received an initial corticosteroid injection followed by shoulder arthroplasty between 2010 and 2021. Of these 524 patients, 272 were excluded for having received prior surgery on the index shoulder, for receiving a non-corticosteroid injection during the interim period, for the presence of inflammatory arthritis, or for undergoing an arthroplasty procedure besides TSA, i.e., hemiarthroplasty. After exclusions, 160 patients with a primary diagnosis of glenohumeral OA and 92 patients with a primary diagnosis of RTC arthropathy remained.

Demographics and Comorbidities

Demographics and comorbidities for both groups are presented in Table 1. The primary OA group had a mean age of 66.0 ± 9.9 years, was mostly female (63.8%), and had a mean BMI of 29.4 ± 6.0 kg/m². The RTC arthropathy group had a mean age of 72.3 ± 8.4 years, was mostly female (68.5%), and had a mean BMI of 29.0 ± 5.3 kg/m². Among all patients, the most common comorbidities were diabetes mellitus (primary OA 16.9% and RTC arthropathy 16.3%), hypertension (primary OA 27.5% and RTC arthropathy 22.8%), and hypothyroidism (primary OA 10.0% and RTC arthropathy 6.5%).

Radiographic and Intraoperative Findings

Radiographic and intraoperative findings for both groups are

Table 1. Demographics and comorbidities

Variable	Primary OA (n=160)	RTC arthropathy (n=92)
Demographics		
Age at presentation (yr)	66.0 ± 9.9	72.3 ± 8.4
Sex		
Male	58 (36.3)	29 (31.5)
Female	102 (63.8)	63 (68.5)
BMI at presentation (kg/m ²)	29.4 ± 6.0	29.0 ± 5.3
Laterality		
Left	70 (43.8)	31 (33.7)
Right	90 (56.3)	61 (66.3)
Comorbidity		
Smoker		
Never	65 (40.6)	44 (47.8)
Former	88 (55.0)	47 (51.1)
Current	7 (4.4)	1 (1.1)
Diabetes mellitus	27 (16.9)	15 (16.3)
Hypertension	44 (27.5)	21 (22.8)
Coronary artery disease	5 (3.1)	7 (7.6)
Hypothyroidism	16 (10.0)	6 (6.5)
Chronic kidney disease	5 (3.1)	4 (4.4)
History of cancer	6 (3.8)	9 (9.8)

Values are presented as mean ± standard deviation or number (%). OA: osteoarthritis, RTC: rotator cuff, BMI: body mass index.

presented in Table 2. End-stage glenohumeral OA (KL grade 4) was present in 90.6% of primary OA patients and 58.7% of RTC arthropathy patients. Severe ACJ OA was present in 12.5% of primary OA patients and 12.0% of RTC arthropathy patients. Among the RTC arthropathy group, most presented with Hama-da 4a (33.7%) and 4b (40.2%) arthropathy. LHBT tearing and/or subluxation was present in 70.6% of primary OA patients and 47.8% of RTC arthropathy patients. Labral tearing was present in 30.6% of primary OA patients and 21.7% of RTC arthropathy patients. In the primary OA group, ACJ OA grade was not significantly associated with RTC tearing ($P=0.88$).

Treatment Course

Treatment course information for both groups is presented in Table 2. In the primary OA group, mean time from initial presentation to first corticosteroid injection was 4.5 ± 11.7 months with most patients receiving an injection at their first visit (58.8%) and mean time from presentation to surgery was 25.5 ± 24.0 months with most patients undergoing aTSA (64.4%).

Injection counts ranged from one to ten; most primary OA patients received only one injection before undergoing surgery (75.6%). In the RTC arthropathy group, mean time from presentation to first injection was 2.7 ± 6.3 months with most patients receiving an injection at their first visit (62.0%); and mean time

from presentation to TSA was 23.7 ± 25.0 months with almost all patients undergoing rTSA (98.9%). Injection counts ranged from one to 17 with most RTC arthropathy patients receiving only one injection before undergoing surgery (79.4%). In both groups, most injections were performed using palpation-guided techniques (primary OA 86.3% and RTC arthropathy 84.8%).

Subgroup Analyses of Time from First Injection to TSA

Time from first corticosteroid injection to TSA was compared between patients who received palpation-guided and image-guided injections. In the primary OA group, patients who underwent image-guided injections had a longer time to TSA following the first injection (mean, 27.1 ± 23.3 months) compared to those who received palpation-guided injections (mean, 19.9 ± 21.3 months). This difference was statistically significant ($P=0.04$). In the RTC arthropathy group, patients who underwent image-guided injections also had a longer time to TSA following the first injection (mean, 22.6 ± 21.8 months) compared to those who received palpation-guided injections (mean, 20.7 ± 22.6 months). This difference was not statistically significant ($P=0.34$).

Time from first corticosteroid injection to TSA was also compared between patients with glenohumeral OA of KL grade 4 (end-stage) and those with KL grades 1–3. In the primary OA group, there was no significant difference ($P=0.65$) in time to TSA between patients with grade 4 glenohumeral OA (mean, 21.5 ± 22.3 months) and those without (mean, 15.7 ± 14.0 months). In the RTC arthropathy group, patients with grade 4 glenohumeral OA (mean, 22.8 ± 23.9 months) had significantly longer time to TSA ($P=0.02$) than those without (mean, 18.5 ± 27.1 months).

Survival Analysis and Predictive Factors for Time to TSA

Survival curves for time to TSA for the primary OA and RTC arthropathy groups are shown in Fig. 1. For the primary OA group, median survival time was estimated at 15 months (95% CI, 13–18 months). For the RTC arthropathy group, median survival time was estimated at 14 months (95% CI, 11–16 months).

Predictive factors for time to TSA are listed in Table 3. For the primary OA group, significant factors for shorter time to TSA were older age at presentation (HR, 1.02; $P=0.03$) and presence of moderate or severe ACJ arthritis (HR, 1.45; $P=0.03$); significant factors for longer time to TSA were presence of hypertension (HR, 0.53; $P<0.001$) and longer time from presentation to first corticosteroid injection (HR, 0.97; $P<0.001$). Overall model fit was significant based on the likelihood ratio (chi-square, 33.9; $P<0.001$) and Wald statistic (chi-square, 28.9; $P<0.001$).

For the RTC arthropathy group, the only significant factor for

Table 2. Radiographic findings, intraoperative findings, and treatment course

Variable	Primary OA (n = 160)	RTC arthropathy (n = 92)
Radiographic finding		
KL grade of glenohumeral OA		
1	2 (1.3)	7 (7.6)
2	4 (2.5)	14 (15.2)
3	9 (5.6)	17 (18.5)
4	145 (90.6)	54 (58.7)
Grade of ACJ OA		
None	25 (15.6)	7 (7.6)
Mild	74 (46.3)	44 (47.8)
Moderate	41 (25.6)	30 (32.6)
Severe	20 (12.5)	11 (12.0)
Hamada classification of RTC arthropathy		
1	-	2 (2.2)
2	-	8 (8.7)
3	-	8 (8.7)
4a	-	31 (33.7)
4b	-	37 (40.2)
5	-	6 (6.5)
Presence of glenoid retroversion	107 (66.9)	53 (57.6)
Degrees of retroversion (°)	11.5 ± 7.0	10.0 ± 8.2
Subchondral sclerosis	129 (80.6)	58 (63.0)
Complete loss of joint space	115 (71.9)	45 (48.9)
Inferior humeral head osteophytes	144 (90.0)	65 (70.7)
Humeral head posterior subluxation	44 (27.5)	14 (15.2)
Intraoperative finding		
Rotator cuff tear	31 (19.4)	92 (100.0)
LHBT tear or subluxation	113 (70.6)	44 (47.8)
Labral tear	49 (30.6)	20 (21.7)
Treatment course		
Time from presentation to first corticosteroid injection (mo)	4.5 ± 11.7	2.7 ± 6.3
Received injection at first visit	94 (58.8)	57 (62.0)
Number of injections given	1.6 ± 1.5	2.0 ± 3.0
Received only one injection	121 (75.6)	73 (79.4)
Injection method		
Palpation	138 (86.3)	78 (84.8)
Ultrasound	20 (12.5)	12 (13.0)
Fluoroscopy	2 (1.3)	2 (2.2)
Time from presentation to TSA (mo)	25.5 ± 24.0	23.7 ± 25.0
Time from first corticosteroid injection to TSA (mo)	20.9 ± 21.7	21.0 ± 25.2
TSA type		
Anatomic	103 (64.4)	1 (1.1)
Reverse	57 (35.6)	91 (98.9)

Values are presented as number (%) or mean ± standard deviation.

OA: osteoarthritis, RTC: rotator cuff, KL: Kellgren-Lawrence, ACJ: acromioclavicular joint, LHBT: long head of the biceps tendon, TSA: total shoulder arthroplasty.

shorter time to TSA was older age at presentation (HR, 1.06; $P < 0.001$) while significant factors for longer time to TSA included being a current or former smoker (HR, 0.52; $P = 0.004$), having hypothyroidism (HR, 0.38; $P = 0.04$), and having had a higher number of injections (HR, 0.87; $P = 0.003$). Overall model fit was significant based on the likelihood ratio (chi-square, 38.8; $P < 0.001$) and Wald statistic (chi-square, 29.1; $P < 0.001$).

DISCUSSION

The first aim of this study was to quantify and compare the time from initial presentation to TSA between glenohumeral OA and RTC arthropathy patients. The present study estimated that 50% of primary OA patients would undergo TSA by 15 months post-injection and 50% of RTC arthropathy patients would un-

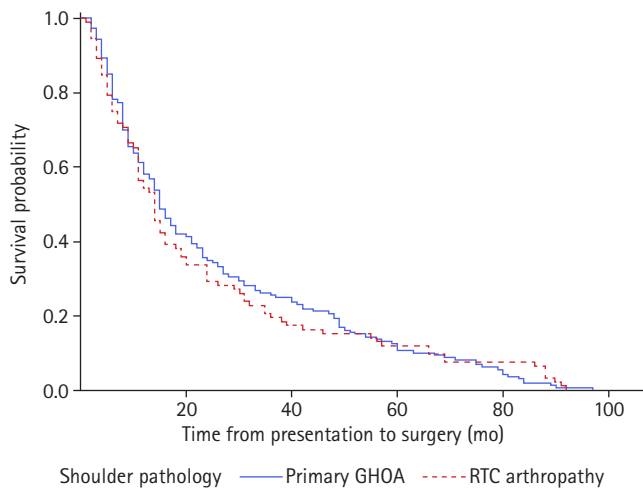


Fig. 1. Kaplan-Meier survival curve of time from initial presentation to total shoulder arthroplasty among patients with primary glenohumeral osteoarthritis (GHOA) and rotator cuff (RTC) arthropathy.

Table 3. Predictors of time from initial presentation to total shoulder arthroplasty

Predictor	Hazard ratio	95% Wald CI	P-value
Primary glenohumeral OA			
Age at presentation	1.02	1.00–1.04	0.03*
Hypertension	0.53	0.37–0.77	< 0.001*
Moderate or severe AC arthritis	1.45	1.05–2.01	0.03*
Time from presentation to first corticosteroid injection	0.97	0.96–0.99	< 0.001*
RTC arthropathy			
Age at presentation	1.06	1.03–1.10	< 0.001*
Current or former smoker	0.52	0.33–0.81	0.004*
Hypothyroidism	0.38	0.15–0.97	0.04*
Number of injections	0.87	0.80–0.95	0.003*

CI: confidence interval, OA: osteoarthritis, AC: acromioclavicular, RTC: rotator cuff.

* $P < 0.05$.

dergo TSA by 14 months post-injection. The second aim of this study was to identify independent predictors of time to TSA in both groups. In both groups, older age at presentation was predictive of shorter time to TSA. In the primary OA group, higher-grade ACJ OA was predictive of shorter time to TSA while presence of hypertension and longer time to first corticosteroid injection were associated with longer time to TSA. In the RTC arthropathy group, positive smoking history, presence of hypothyroidism, and higher number of injections were all predictive of longer time to TSA.

Corticosteroid injections have become a common, and controversial, treatment for shoulder OA. These injections are often administered with the intention of delaying eventual arthroplasty

by reducing pain to within the patient's acceptable parameters [11,12]. Among our cohort, the delay between the first corticosteroid injection and TSA procedure ranged considerably from just 1 month to 8 years. However, there is limited research quantifying the length of time these injections can control OA symptoms before pain and function deteriorate to the point that patients opt to undergo arthroplasty. Tang et al. [13] in a retrospective cohort study compared the time from initial presentation to the clinic until total hip arthroplasty or total knee arthroplasty in patients receiving or not receiving corticosteroid injections. There was a statistically prolonged time in those receiving injection, with an observed 12.4 months versus 7.3 months for total hip arthroplasty ($P < 0.001$) and 20.0 months versus 11.6 months for total knee arthroplasty ($P < 0.001$).

Several studies have also tried to quantify the duration of symptom relief provided by corticosteroid injections among shoulder arthritis patients. Metzger et al. [14] conducted a prospective study that found that glenohumeral OA symptoms were significantly alleviated by ultrasound-guided steroid injections with improvements in shoulder function and pain lasting up to 4 months post-injection. By contrast, Merolla et al. [15] found in a retrospective comparative cohort study that corticosteroids only reduced glenohumeral OA pain for up to 1-month post-injection. However, viscosupplementation with hyaluronic acid provided up to 6 months of relief. Interestingly, our study demonstrated that those patients who underwent image-guided corticosteroid injections experienced a significantly longer time from initial visit to TSA when controlling for both KL and Hamada grade. Also notable is that symptom relief is not the sole factor impacting the delay of arthroplasty following corticosteroid injection; several studies have raised concerns over the increased risk of infection following shoulder procedures due to the immunosuppressive effect of steroids [16,17]. Rashid et al. [18] critiqued some of these concerns in a 2015 retrospective cohort study that found no difference in postoperative joint infection rates between patients who received corticosteroid injections and those who did not prior to TSA. Nonetheless, the concern remains pervasive among orthopedic surgeons, and patients are often recommended to wait a minimum of 3 months before undergoing arthroplasty [19].

The mixed evidence surrounding the use of steroid injections for shoulder arthritis stems in part from the wide range of etiologies for this condition. Indeed, few studies have directly compared the use of corticosteroid injections to delay TSA between two of the most common etiologies of shoulder arthritis, primary glenohumeral OA and RTC arthropathy. Both disease processes involve chronic inflammation of the glenohumeral joint leading

to symptoms of pain and decreased range of motion; and, in both pathologies, the therapeutic mechanism of action of corticosteroids is to reduce the inflammatory response by downregulating the cellular expression of pro-inflammatory enzymes and factors [5,6]. However, the distinction between these two conditions is important given that patients with RTC arthropathy tend to have lower-grade glenohumeral joint disease on initial presentation and are often managed non-surgically for longer periods [20,21]. In addition, primary glenohumeral OA is more commonly managed by aTSA whereas surgical intervention for RTC arthropathy typically involves rTSA due to the compromised function of the RTC [20,22].

Our study cohort exhibited many of the known clinical differences between primary OA and RTC arthropathy. Primary OA patients were more likely to have end-stage glenohumeral OA and radiographic features of glenohumeral joint disease, e.g., complete loss of joint space and inferior humeral head osteophytes, compared to RTC arthropathy patients. Despite the differences in clinical and radiographic characteristics between both pathologies, we found that these patients had a similar time course from initial presentation to TSA. Furthermore, rate of progression of shoulder OA symptoms was also similar between the two groups as evidenced by comparable survival curves and median survival times. We theorize that while the underlying disease mechanisms may differ between these two etiologies, patients with either condition present for their initial visit with similar levels of shoulder pain and functional deficits. Following the initial injection, symptoms progress at the same rate for both primary OA and RTC arthropathy patients; therefore, both types of patients exceed their acceptable symptom threshold and undergo arthroplasty around the same time.

Our analysis found older age to be a significant risk factor for shorter time to TSA among both primary OA and RTC arthropathy patients. Advanced age is a well-established risk factor for progression of both conditions, which typically present in adults 60 years and older and progress in severity over time due to “wear and tear” of the various structures of the shoulder joint [23,24]. In the primary OA group alone, more severe ACJ OA was associated with shorter time to TSA. ACJ OA is more prevalent than glenohumeral OA in the elderly population [25] and can contribute to shoulder pain independently of glenohumeral joint disease. One of mechanisms by which ACJ pathology can cause shoulder pain and dysfunction is through RTC impingement [26], though we note that there was no significant association between ACJ OA grade and RTC tears in our primary OA cohort. Also notable was that patients in our cohort received corticosteroid injections into the glenohumeral joint and not the

ACJ; therefore, unalleviated ACJ-related pain could have contributed to the faster progression of symptoms among primary OA patients.

Several factors were found to be associated with longer time to TSA. In the primary OA cohort, these factors were presence of hypertension and longer time to first corticosteroid injection. In the RTC arthropathy cohort, these factors were positive smoking history, presence of hypothyroidism, and increased number of corticosteroid injections. The association between comorbidities and longer time to surgery is likely due to patients with these conditions being more likely to be poor surgical candidates. This results in a requirement for a longer period of nonoperative management before receiving medical clearance to undergo surgery. Likewise, the association between longer time to first corticosteroid injection and longer time to surgery is self-evident given that patients who managed their symptoms for longer without the need for steroid injections were probably less symptomatic at their initial visit than those who needed an injection at their initial visit.

In the RTC arthropathy cohort, each steroid injection in the period between initial presentation and TSA was associated with a 13% decrease in the likelihood of undergoing TSA at any given time. However, as discussed previously, this effect may be due to both the symptom relief provided by each injection thereby delaying the need for surgery and the minimum waiting time required after each injection before undergoing surgery in order to reduce the risk of postoperative infection. There is wide variation in corticosteroid dosing protocols for shoulder OA, and there is little agreement as to whether an increased number of injections has an impact on shoulder OA progression and symptom relief. Research on the use of corticosteroid injections for RTC tears further casts doubt on the utility of multiple doses. Gialanella and Prometti [27] found that administration of two doses of a corticosteroid (triamcinolone 40 mg) at a 21-day interval did not prolong the pain relief effect compared to a single dose among patients with RTC tears. Even more concerning, Desai et al. [28] reported that an increased number of corticosteroid injections prior to RTC repair surgery significantly increased the risk of subsequent revision surgery. While known deleterious effects of intra-articular corticosteroids such as chondrotoxicity may be of less concern for patients undergoing total arthroplasty, the marginal benefit of each additional injection prior to surgery must be carefully weighed against the risks of delaying surgery.

We note several limitations of our study design. First, the retrospective nature of the study introduces the possibility of selection bias. Second, all patients in the cohort were obtained from a single institution. While this is a strength in its elimination of

considerable inter-observer variations in the use of corticosteroid injections for shoulder OA, the limitation is that the frequency of these injections may not be representative of their frequency at other institutions and nationally. Third, the date of initial presentation to the clinic may not correspond to the actual date of onset of shoulder symptoms. Nonetheless, the time from presentation to TSA reflected the entire length of care and could be reliably determined for each patient in the cohort. Fourth, the timing of multiple corticosteroid injections was not accounted for in the Cox proportional hazards model. The reported HR for injection number should be interpreted with caution and may not be a reliable measure of risk reduction. Fifth, there may be a significant difference in the efficacy of intra-articular injections performed under ultrasound or fluoroscopic guidance compared to palpation-based methods as demonstrated by our subgroup analysis. We adjusted for the potential confounding effect of injection technique through its inclusion as a predictor variable in the Cox proportional hazards model. Sixth, corticosteroid injection formulations were not standardized across all providers, and different formulations may be associated with different periods of symptom relief. Unfortunately, injection formulations were not reported consistently across medical records; thus, we were unable to include this variable in our Cox proportional hazards model.

There are distinct prognostic factors for progression to TSA between primary OA patients and RTC arthropathy patients managed with corticosteroid injections. Multiple corticosteroid injections are associated with delayed time to TSA in RTC arthropathy patients.

NOTES

ORCID

Dhruv S. Shankar <https://orcid.org/0000-0002-4153-9382>
 Edward S. Mojica <https://orcid.org/0000-0002-6054-3096>
 Christopher A. Colasanti <https://orcid.org/0000-0003-3412-7272>
 Anna M. Blaeser <https://orcid.org/0000-0003-0060-1618>
 Guillem Gonzalez-Lomas <https://orcid.org/0000-0001-8283-0603>
 Laith M. Jazrawi <https://orcid.org/0000-0001-6417-9968>

Author contributions

Conceptualization: LMJ. Formal Analysis: DSS, ESM. Investigation: DSS, ESM, AMB, PFO. Methodology: DSS, ESM, CAC, GG, LMJ. Supervision: GG, LMJ. Visualization: DSS, ESM. Writing – original draft: DSS, ESM. Writing – review & editing: CAC, GG, LMJ.

Conflict of interest

None.

Funding

None.

Data availability

Contact the corresponding author for data availability.

Acknowledgments

None.

REFERENCES

1. Bell SN, Christmas MU, Coghlan JA. Proximal humeral osteolysis and glenoid radiolucent lines in an anatomic shoulder arthroplasty: a comparison of a ceramic and a metal humeral head component. *J Shoulder Elbow Surg* 2020;29:913–23.
2. Grey SG, Wright TW, Flurin PH, Zuckerman JD, Roche CP, Friedman RJ. Clinical and radiographic outcomes with a posteriorly augmented glenoid for Walch B glenoids in anatomic total shoulder arthroplasty. *J Shoulder Elbow Surg* 2020;29:e185–95.
3. Norris TR, Iannotti JP. Functional outcome after shoulder arthroplasty for primary osteoarthritis: a multicenter study. *J Shoulder Elbow Surg* 2002;11:130–5.
4. Kim SH, Wise BL, Zhang Y, Szabo RM. Increasing incidence of shoulder arthroplasty in the United States. *J Bone Joint Surg Am* 2011;93:2249–54.
5. Guo JJ, Wu K, Guan H, et al. Three-year follow-up of conservative treatments of shoulder osteoarthritis in older patients. *Orthopedics* 2016;39:e634–41.
6. Wang C, Zhang Z, Ma Y, Liu X, Zhu Q. Platelet-rich plasma injection vs corticosteroid injection for conservative treatment of rotator cuff lesions: a systematic review and meta-analysis. *Medicine (Baltimore)* 2021;100:e24680.
7. Giovannetti de Sanctis E, Franceschetti E, De Dona F, Palumbo A, Paciotti M, Franceschi F. The efficacy of injections for partial rotator cuff tears: a systematic review. *J Clin Med*;2020 10:51.
8. Steuri R, Sattelmayer M, Elsig S, et al. Effectiveness of conservative interventions including exercise, manual therapy and medical management in adults with shoulder impingement: a systematic review and meta-analysis of RCTs. *Br J Sports Med* 2017;51:1340–7.
9. Walch G, Ascani C, Boulahia A, Nové-Josserand L, Edwards TB. Static posterior subluxation of the humeral head: an unrecognized entity responsible for glenohumeral osteoarthritis in

- the young adult. *J Shoulder Elbow Surg* 2002;11:309–14.
10. Hamada K, Fukuda H, Mikasa M, Kobayashi Y. Roentgenographic findings in massive rotator cuff tears: a long-term observation. *Clin Orthop Relat Res* 1990;(254):92–6.
 11. Ansok CB, Muh SJ. Optimal management of glenohumeral osteoarthritis. *Orthop Res Rev* 2018;10:9–18.
 12. Gross C, Dhawan A, Harwood D, Gochanour E, Romeo A. Glenohumeral joint injections: a review. *Sports Health* 2013;5:153–9.
 13. Tang A, Almetwali O, Zak SG, Bernstein JA, Schwarzkopf R, Aggarwal VK. Do preoperative intra-articular corticosteroid and hyaluronic acid injections affect time to total joint arthroplasty. *J Clin Orthop Trauma* 2021;16:49–57.
 14. Metzger CM, Farooq H, Merrell GA, et al. Efficacy of a single, image-guided corticosteroid injection for glenohumeral arthritis. *J Shoulder Elbow Surg* 2021;30:1128–34.
 15. Merolla G, Sperling JW, Paladini P, Porcellini G. Efficacy of Hylan G-F 20 versus 6-methylprednisolone acetate in painful shoulder osteoarthritis: a retrospective controlled trial. *Musculoskelet Surg* 2011;95:215–24.
 16. Forsythe B, Agarwalla A, Puzziello RN, Sumner S, Romeo AA, Mascarenhas R. The timing of injections prior to arthroscopic rotator cuff repair impacts the risk of surgical site infection. *J Bone Joint Surg Am* 2019;101:682–7.
 17. Kew ME, Cancienne JM, Christensen JE, Werner BC. The timing of corticosteroid injections after arthroscopic shoulder procedures affects postoperative infection risk. *Am J Sports Med* 2019;47:915–21.
 18. Rashid A, Kalson N, Jiwa N, Patel A, Irwin A, Corner T. The effects of pre-operative intra-articular glenohumeral corticosteroid injection on infective complications after shoulder arthroplasty. *Shoulder Elbow* 2015;7:154–6.
 19. Bhattacharjee S, Wallace S, Luu HH, Shi LL, Lee MJ, Chen AF. Do we need to wait 3 months after corticosteroid injections to reduce the risk of infection after total knee arthroplasty. *J Am Acad Orthop Surg* 2021;29:e714–21.
 20. Feeley BT, Gallo RA, Craig EV. Cuff tear arthropathy: current trends in diagnosis and surgical management. *J Shoulder Elbow Surg* 2009;18:484–94.
 21. Chalmers PN, Salazar DH, Steger-May K, et al. Radiographic progression of arthritic changes in shoulders with degenerative rotator cuff tears. *J Shoulder Elbow Surg* 2016;25:1749–55.
 22. Jensen AR, Tangtiphaiboonana J, Marigi E, Mallett KE, Sperling JW, Sanchez-Sotelo J. Anatomic total shoulder arthroplasty for primary glenohumeral osteoarthritis is associated with excellent outcomes and low revision rates in the elderly. *J Shoulder Elbow Surg* 2021;30:S131–9.
 23. Menge TJ, Boykin RE, Byram IR, Bushnell BD. A comprehensive approach to glenohumeral arthritis. *South Med J* 2014; 107:567–73.
 24. Tashjian RZ. Epidemiology, natural history, and indications for treatment of rotator cuff tears. *Clin Sports Med* 2012;31:589–604.
 25. Horváth F, Kéry L. Degenerative deformations of the acromioclavicular joint in the elderly. *Arch Gerontol Geriatr* 1984;3: 259–65.
 26. Precerutti M, Formica M, Bonardi M, Peroni C, Calciati F. Acromioclavicular osteoarthritis and shoulder pain: a review of the role of ultrasonography. *J Ultrasound* 2020;23:317–25.
 27. Gialanella B, Prometti P. Effects of corticosteroids injection in rotator cuff tears. *Pain Med* 2011;12:1559–65.
 28. Desai VS, Camp CL, Boddapati V, Dines JS, Brockmeier SF, Werner BC. Increasing numbers of shoulder corticosteroid injections within a year preoperatively may be associated with a higher rate of subsequent revision rotator cuff surgery. *Arthroscopy* 2019;35:45–50.