








# The iceberg technique: an innovative approach for radiofrequency ablation of diving thyroid nodules

Antônio Rahal Junior   
 Erivelto Martinho Volpi   
 Bruno Pagnin Schmid   
 Priscila Mina Falsarella   
 Rodrigo Gobbo Garcia 

## ABSTRACT

Diving thyroid nodules are a limitation of radiofrequency ablation because the mediastinal component cannot be adequately identified by ultrasound (US). We aim to describe a new technique, the iceberg technique, to overcome this issue and explain our three-year experience of using this novel method. The iceberg technique consists of a two-stage treatment. First, the ablation of the cervical portion of the nodules (easily visualized during the initial US exam) using trans-isthmic access is performed using the moving-shot technique. After three to six months, there is a volumetric reduction of the treated portion, leading to retraction of the thyroid parenchyma. This brings the mediastinal component to the cervical region, thereby enabling a perfect visualization by US. Then, the second stage of treatment is carried out with complete nodule ablation, and the region that was treated first is looked at a second time. From April 2018 to April 2021, nine patients with nine benign nodules were submitted for the iceberg technique. No complications occurred during the entire follow-up period. The patients displayed normal hormonal levels after the procedures, and there was a significant volume reduction of the nodules until three months post-ablation. The iceberg technique is an effective and safe option for the radiofrequency treatment of diving goiters.

## KEYWORDS

Ablation, goiter, interventional, nodule, thyroid

**T**hyroid nodules are highly prevalent across the world. Among thyroid nodules, the vast majority are benign nodules.<sup>1</sup> Among these benign nodules, a significant number may cause such symptoms as a volumetric increase, with or without a mediastinal diving component; autonomous nodules; esophageal and tracheal compression; and foreign body perception.<sup>2</sup> Before the advent of thyroid nodules ablation, surgery was the gold-standard treatment for symptomatic benign thyroid nodules and malignant nodules. However, this treatment is associated with complications, including hypothyroidism, nerve damage, and hypocalcemia.<sup>3</sup> Regarding this situation, radiofrequency thermal ablation (RFA) emerges as a valuable option, allowing minimally invasive treatment and preserving thyroid function in selected patients.<sup>4</sup> Since thyroid RFA is entirely guided by ultrasound (US), in diving thyroid nodules, just the cervical portion (the peak of the iceberg) is visible on the US, and the presence of a mediastinal immersion component that cannot be identified by the method may be a limitation to the safe treatment of these nodules. We describe a new technique, the iceberg technique, to overcome this issue and a three-year single-center experience using this approach.

## Technique

This study was approved by the institutional review board and was in accordance with the Helsinki Declaration (ethics committee approval number: 24237019.0.0000.0071). All patients provided informed consent. From April 2018 to April 2021, 12 euthyroid consecutive patients were diagnosed with diving thyroid nodules presenting a mediastinal component. Among these, nine patients (six men, three women; mean age: 50.5 years) with nine benign

From the Department of Interventional Radiology (A.R.J., B.P.S. ✉ brunopschmid@gmail.com, P.F., R.G.G.), Hospital Israelita Albert Einstein, Sao Paulo, Brazil; Department of Head and Neck Surgery (E.M.V.), Hospital Alemão Oswaldo Cruz, Sao Paulo, Brazil.

Received 02 March 2022; revision requested 10 Apr 2022; last revision received 20 Apr 2022; accepted 10 May 2022.

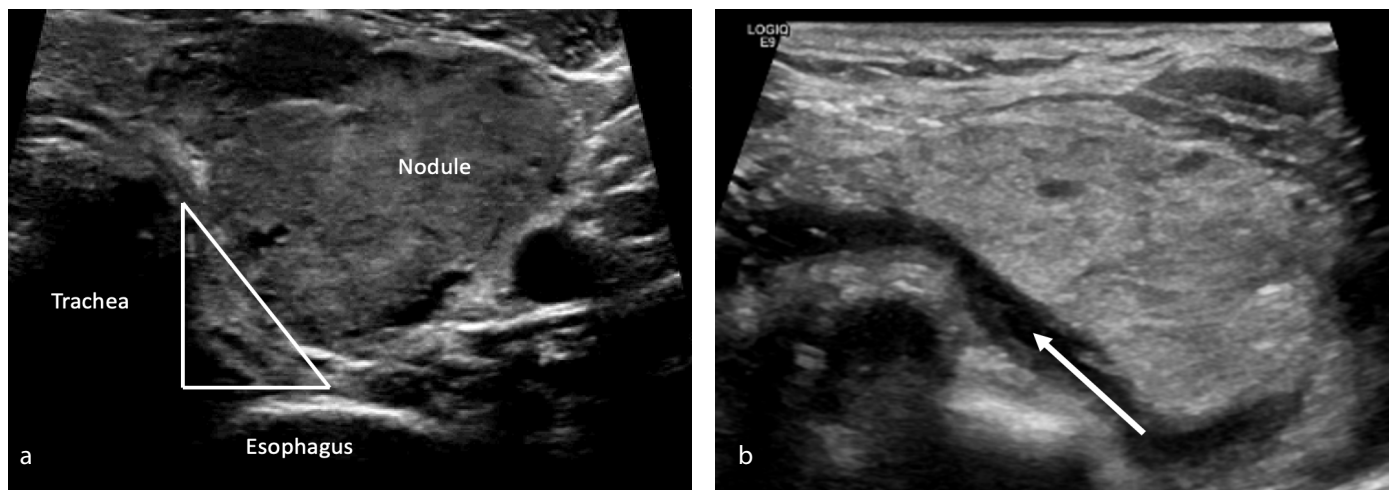


Epub: 23.12.2022

Publication date: 21.07.2023

DOI: 10.4274/dir.2022.221467

You may cite this article as: Junior AR, Volpi EM, Schmid BP, Mina Falsarella P, Garcia RG. The iceberg technique: an innovative approach for radiofrequency ablation of diving thyroid nodules. *Diagn Interv Radiol.* 2023;29(4):628-631.



**Figure 1.** (a) Danger triangle zone: a space between thyroid parenchyma, trachea, and laryngeous recurrent nerve. This area must be protected from heat. Hydrodissection is an excellent option to protect these structures. (b) Pre-procedural hydrodissection with a 5% glucose solution. We got a protection layer of 0.7 cm (white arrow), allowing a larger area ablative zone with greater protection.

nodules refused surgical treatment and were submitted to RFA using the iceberg technique. A pre-procedural thyroid fine-needle aspiration biopsy was routinely performed to exclude malignancy. Procedures were performed in a tertiary care hospital under US guidance (Logic E9-General Electric Healthcare, Milwaukee, United States) with 12 and 9 MHz linear transducers. A generator and RFA device (Seoul, South Korea, RF Medical) and 1-cm active tips (power between 40 and 50 W) dedicated to the thyroid approach were used. All ablations were headed by a highly experienced interventional radiologist (>15 years in practice) and assisted by one interventional radiology fellow. All patients were submitted to ablative treatment in a supine position with neck extension and were placed under local anesthesia with programmed stop sedation.<sup>4</sup> The iceberg technique consisted of a two-stage treatment. Both began with the identification of the “danger triangle” zone, which included the recurrent laryngeal nerve and the esophagus.<sup>5-7</sup> A pre-procedural hydrodissection with a 5% glucose solution injection using a 22-gauge spinal anesthesia needle (BD Medical, New Jersey, United States) was performed in all treatments to provide minimal heat exposure to the danger zone (Figure 1).

#### Main points

- The iceberg technique is an effective and safe option for the radiofrequency treatment of diving goiters.
- Significant nodule volume reduction occurred until the third month.
- The main limitation of this technique was that it took a long time (at least three months).

During the first stage, the ablation of the cervical portion of the nodules (easily visualized during the initial US exam) using trans-isthmic access was performed using the moving-shot technique, from the posterior to the anterior portion, without incurring unnecessary risks, with good visualization of the area by real-time US (Figure 2). Approximately three to six months after the first stage, there was a volumetric reduction of the treated portion, leading to retraction of the thyroid parenchyma. This brought the mediastinal component (that was previously difficult to assess) to the cervical region, enabling a perfect visualization by the US. Then, second-stage treatment was carried out, with complete nodule ablation and a second look directed at the region that was first treated to obtain the optimal result. Ablation ended when all units of the nodule had changed to transient hyperechoic zones and the impedance values were high in the whole treated tissue (Figure 3). As per local protocol, the patients were discharged from the hospital 2 h following the procedure if no complications were noted. An ice pack was routinely applied to the puncture site at 15-minute intervals to prevent cervical edema and provide an anesthetic effect. Oral analgesics were prescribed only if the patient complained of pain. The follow-up protocol included regular clinical assessments and USs that were performed at 1, 3, 6, and 12 months after the procedure. All exams were evaluated by the same interventional radiology team that performed the ablations. No complications were observed during the procedure time or the entire follow-up period. Normal hormonal levels after the procedures were observed in all patients with normal thyroid function. The

nodules' volumes were evaluated throughout different moments of US imaging. The mean and standard deviation were assessed and compared using the generalized estimation equations model, followed by the multiple comparison method of Bonferroni to assess each group and the moments when the differences occurred.

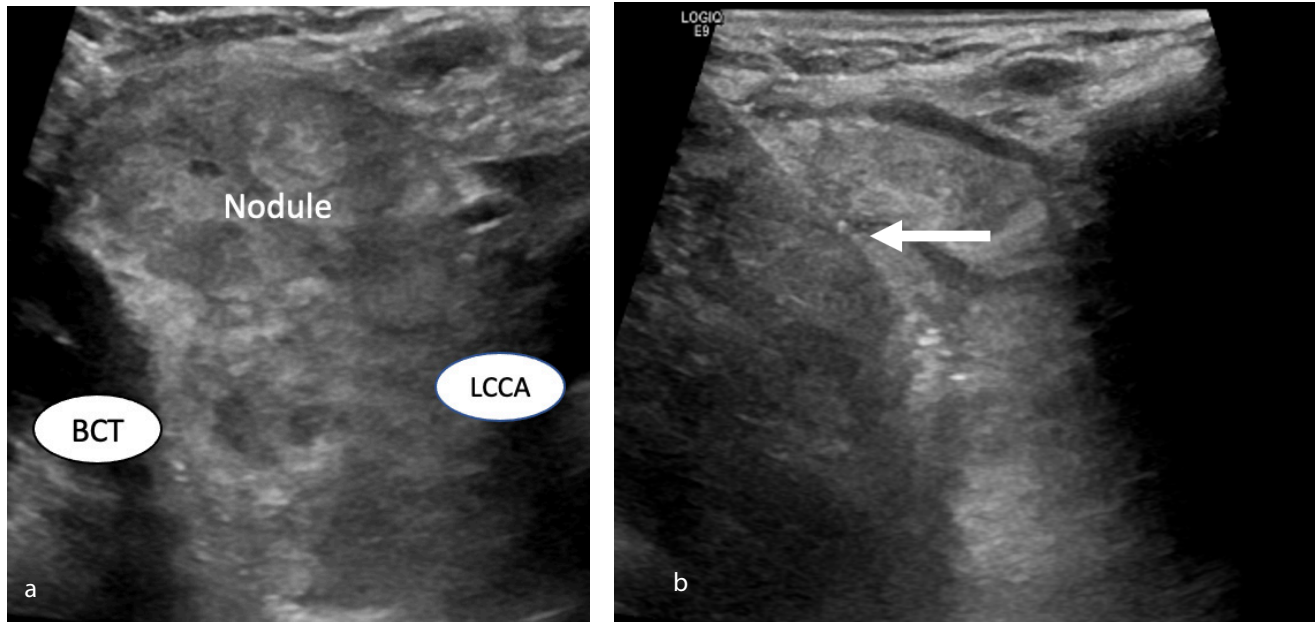
#### Statistical analysis

Statistical analyses were performed by a biomedical statistician using SPSS software version 22.0 (IBM, Armonk, NY, United States), and the statistical significance was assumed at the 5% level (Tables 1, 2).

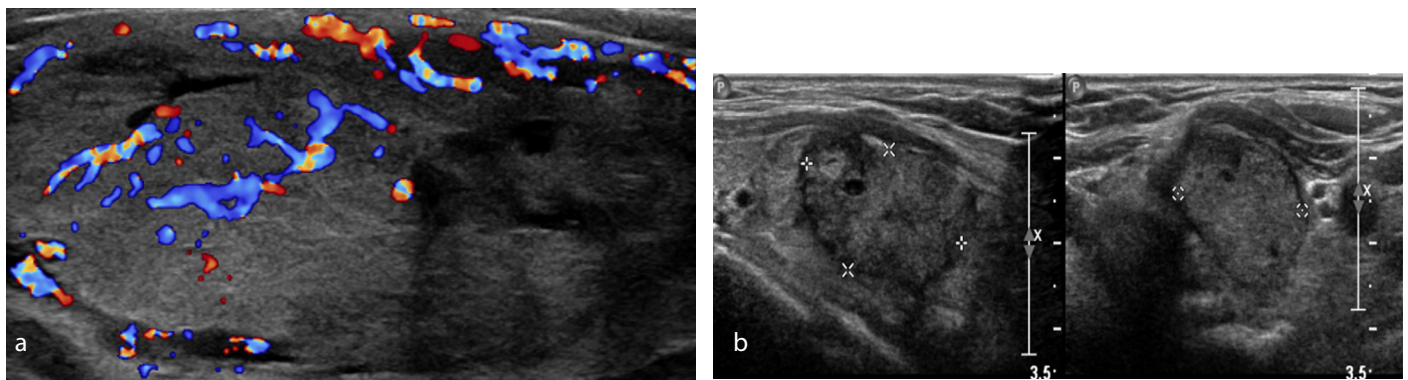
#### Discussion

The iceberg technique was an effective and safe option for the radiofrequency treatment of diving goiters, especially those who were initially ineligible due to the voluminous mediastinal component. It showed no complications and enabled thyroid function preservation, even in anatomically challenging cases.

As in cases of ablation performed only in a single step, when the iceberg technique was selected for the approach of large goiters, we had early hospital discharge, which was approximately 2 h after the procedure, as well as an early return to usual activities, after the first session and the second and last sessions. Furthermore, it could be performed under sedation anesthesia in all cases, which is an important advantage compared with surgical resection that usually demands general anesthesia.



**Figure 2.** (a) Initial thyroid ultrasound assessment showing a diving thyroid nodule with its mediastinal component, the brachiocephalic trunk, and the left common carotid artery. (b) First stage ablation of the nodule's cervical portion. The white arrow shows the radiofrequency probe.



**Figure 3.** (a) Second thyroid color Doppler ultrasound assessment showing retraction of the mediastinal nodule's component (now well visualized) to the cervical region. Color Doppler US demonstrates the clear difference between the previously ablated zone (with no color flow and heterogeneous and hypoechoogenic) and the residual portion (with color flow and isoechoogenic). (b) Follow-up images demonstrate a 90% volume reduction after two ablative sessions.

Table 1. The nodules' volumes throughout different moments of ultrasound imaging					
Time	Mean volume (cm <sup>3</sup> )	SD	Median (range)	n	P
Pre-ablation	50.62	25.81	40 (21–92.5)	9	<0.001
1 month	33.23	17.92	30.25 (7.8–57)	6	
3 months	24.63	15.11	21.3 (4–41.3)	5	
6 months	19.95	12.25	17.2 (2.3–32.93)	5	
12 months	20.2	-	20.2 (20.2)	1	

n, number of nodules; SD, standard deviation.

Table 2. The nodules' volume reduction comparison between different moments of ultrasound imaging				
Comparison	MD	SD	CI (95%)	P
Pre-ablation vs. 1 month	29.63	2.23	23.37–35.88	<0.001
1 month vs. 3 months	9.40	2.34	2.83–15.97	0.001
3 months vs. 6 months	4.11	2.59	-3.15–11.37	>0.999
6 months vs. 12 months	12.04	5.44	-3.22–27.30	0.268

SD, standard deviation; CI, confidence interval; MD, mean difference.

Our results also showed significant nodule volume reduction until the third month. This is especially important for the counseling of patients as they plan for the second ablation stage involved in the iceberg technique because this reduction is intimately associated with the migration of the mediastinal to the cervical region.

Therefore, we could infer that the ideal time to perform the second ablation was three months following the first procedure, aiming for the maximum retraction and, consequently, the best visualization during the US assessment and the optimal ablation zone.

The main limitation of this study was its small sample size (only nine patients). The main disadvantage of this technique is that it took a long time (at least three months). Despite this, we observed a significant improvement in symptoms, even after the first session. The second step was beneficial to obtain an optimal result, which was expected to be 90% after 12 months following the completed treatment.

Additionally, it required interventional radiologists with expertise in ablative methods and US imaging skills to avoid possible

serious complications, such as recurrent laryngeal nerve damage, skin burn, esophagus perforation, or Claude Bernard Horner syndrome. It is also important to mention the hole of hydrodissection to prevent complications; in this study, all cases underwent previous hydrodissection.

Finally, this new technique should be considered as a valuable alternative for patients with thyroid nodules with a huge mediastinal component.

### Acknowledgments

We are grateful to Rogério Ruscitto do Prado for statistical analysis.

### Conflict of interest disclosure

The authors declared no conflicts of interest.

### References

1. Junior AR, Falsarella PM, Rocha RD, et al. Correlation of thyroid imaging reporting and data system [TI-RADS] and fine needle aspiration: experience in 1,000 nodules. *Einstein (Sao Paulo)*. 2016;14(2):119-123. [\[CrossRef\]](#)
2. Haugen BR, Alexander EK, Bible KC, et al. 2015 American Thyroid Association Management

Guidelines for Adult Patients with Thyroid Nodules and Differentiated Thyroid Cancer: The American Thyroid Association Guidelines Task Force on Thyroid Nodules and Differentiated Thyroid Cancer. *Thyroid*. 2016;26(1):1-133. [\[CrossRef\]](#)

3. Muhammad H, Santhanam P, Russell JO. Radiofrequency ablation and thyroid nodules: updated systematic review. *Endocrine*. 2021;72(3):619-632. [\[CrossRef\]](#)
4. Souza KP, Rahal A Jr, Volpi EM, et al. Hydrodissection and programmed stop sedation in 100 % of benign thyroid nodules treated with radiofrequency ablation. *Eur J Radiol*. 2020;133:109354. [\[CrossRef\]](#)
5. Sinclair CF, Téllez MJ, Peláez-Cruz R, Díaz-Baamonde A, Ulkatan S. Continuous neuromonitoring during radiofrequency ablation of benign thyroid nodules provides objective evidence of laryngeal nerve safety. *Am J Surg*. 2021;222(2):354-360. [\[CrossRef\]](#)
6. Baek JH, Lee JH, Valcavi R, Pacella CM, Rhim H, Na DG. Thermal ablation for benign thyroid nodules: radiofrequency and laser. *Korean J Radiol*. 2011;12(5):525-540. [\[CrossRef\]](#)
7. Zhao CK, Xu HX, Lu F, et al. Factors associated with initial incomplete ablation for benign thyroid nodules after radiofrequency ablation: first results of CEUS evaluation. *Clin Hemorheol Microcirc*. 2017;65(4):393-405. [\[CrossRef\]](#)