



# A comprehensive review of transvenous obliteration techniques in the management of gastric varices

Irfan Masood   
Amin Moshksar   
Brian Wong   
Hasan Khan   
Arsalan Saleem 

## ABSTRACT

Bleeding gastric varices (GVs) is a life-threatening complication of portal hypertension, with higher morbidity and mortality rates compared with bleeding esophageal varices (EVs). The endovascular techniques for the management of GVVs are mainly transjugular intrahepatic portosystemic shunt (TIPS) and transvenous obliteration of the GVVs. Transvenous obliteration techniques can be an alternative or an adjunct to TIPS for treatment of GVVs, depending on the clinical scenario, and are less invasive than TIPS. However, these procedures are associated with increased portal pressure and related complications, mainly worsening of the EVs. In this article, the different techniques of transvenous obliteration of GVVs, their indications, contraindications, and outcomes are discussed.

## KEYWORDS

Cirrhosis, gastric varices, TIPS, transvenous obliteration, upper GI bleeding

Upper gastrointestinal bleeding due to gastric varices (GV) in patients with portal hypertension resulting from cirrhosis occurs less frequently than esophageal varices (EVs) but is associated with higher morbidity and mortality rates. This is due to severe blood loss, which results from higher rates of rebleeding and bleeding onset at lower pressures than EV, which are often more difficult to control using traditional endoscopic techniques.<sup>1,2</sup> As per the American Association for the Study of Liver Disease (AASLD), the initial management of choice remains endoscopic management, with endovascular treatment reserved for refractory cases.<sup>3</sup> The endovascular treatment options for GVVs are mainly transjugular intrahepatic portosystemic shunt (TIPS) and transcatheter obliteration of the GVVs.

The TIPS method helps decrease portal pressures by directing blood away from the liver, which decompresses and controls variceal bleeding. However, diverting blood away from the liver (hepatofugal flow) can result in worsening of hepatic encephalopathy (HE) and liver failure, particularly in patients with low hepatic reserve [model for end-stage liver disease (MELD) score >17-20].<sup>4,5</sup> Moreover, GV bleeding occurs at lower pressures than EV, and as Tripathi et al.<sup>6</sup> demonstrated, in patients with pre-TIPS portal pressure gradients of  $\leq 12$  mmHg, further reduction in pressure gradients after performing TIPS does not alter the risk of rebleeding from GVVs.

Transcatheter techniques for the obliteration of GVVs present endovascular alternatives/adjuncts to TIPS. When transvenous obliteration is carried out via the systemic veins, it is known as *retrograde* transvenous obliteration (RTO). The term RTO is a collective term that incorporates balloon-occluded retrograde transvenous obliteration (BRTO), plug-assisted retrograde transvenous obliteration (PARTO), and coil-assisted retrograde transvenous obliteration (CAR-TO). When transvenous obliteration is carried out via the portal vein, it is known as *antegrade* transvenous obliteration (ATO). If antegrade obliteration is performed via balloon-occlusion, vascular plug, or coils, then it is known as balloon-occluded antegrade transvenous obliteration (BATO, PATO, or CATO), respectively. The two most common subtypes of ATO procedures

From the Department of Interventional Radiology (I.M. ✉ irmasood@utmb.edu, A.M., B.W., H.K., A.S.), University of Texas Medical Branch, Texas, USA.

Received Received 19 March 2021; revision requested 12 April 2021; last revision received 12 September 2021; accepted 13 October 2021.



Epub: 11.01.2023

Publication date: 31.01.2023

DOI: 10.5152/dir.2022.21193

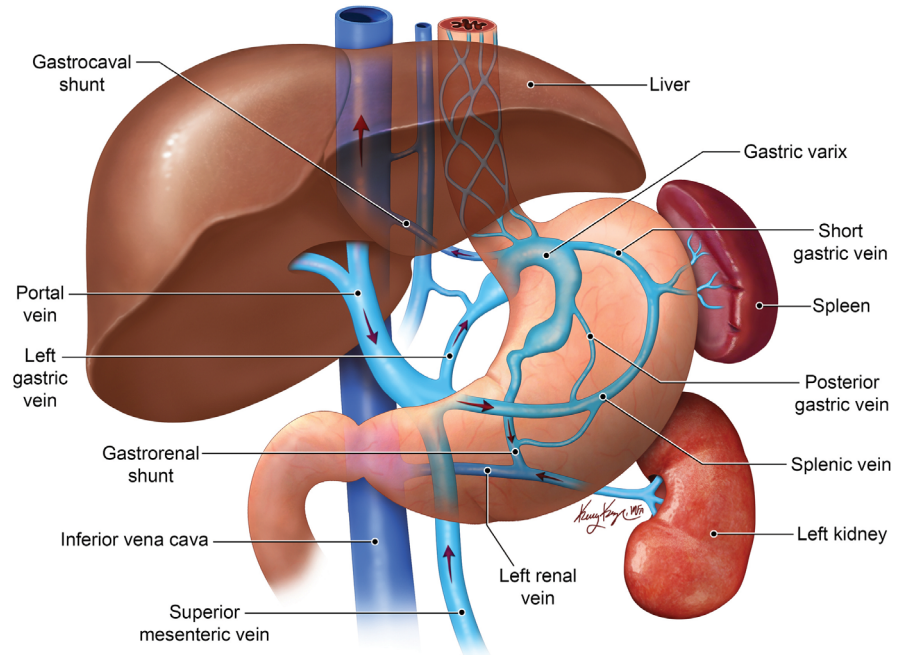
You may cite this article as: Masood I, Moshksar A, Wong B, Khan H, Saleem A. A comprehensive review of transvenous obliteration techniques in the management of gastric varices. *Diagn Interv Radiol.* 2023;29(1):146-154.

include percutaneous transhepatic obliteration (PTO) and trans-TIPS obliteration (Table 1). In this review, the focus is on different transvenous obliteration techniques for the management of GVs, the controversies over which technique is superior, and the geographic preferences of one technique over the other.

## Relevant anatomy

Generally, GVs are classified using Sarin's classification,<sup>2</sup> an endoscopic classification taking into account the location of the GVs and their relationship to EVs. Gastroesophageal varices type 1 (GOV1) are EVs that extend below the cardia into the lesser curvature. These are the most common type, accounting for 75% of cases. GOV2 are EVs that extend into the fundus and are associated with the second highest risk of bleeding after type 1 isolated gastric varices (IGV1), which are present in the fundus only and are associated with the highest risk of bleeding. IGV2s are present in the remaining portions of the stomach (body, antrum, pylorus) and are the least common type of varices in patients with cirrhosis. The risk of bleeding is higher in the presence of a large size, red spots on endoscopy, high-risk locations (as described above), and severe liver dysfunction (higher Child–Pugh grade).<sup>7</sup> Overall, IGV1 and GOV2 are the main types of GVs that are amenable to RTO procedures.

The afferent veins of GVs are most commonly the left gastric vein (LGV) and the posterior gastric vein (PGV), and, less commonly, the short gastric vein and gastroepiploic veins. The varices drain through two dominant pathways, which allow hepatofugal flow by redirecting blood away from the portal circulation. The most common pathway is drainage via a gastroduodenal shunt (GRS) (80%–85%) formed by the inferior phrenic vein joining the left renal vein at the same draining point of the left adrenal vein. The second



**Figure 1.** Anatomy of gastric variceal complex. Graphic showing that the afferent veins of GVal complex are mainly formed by the left gastric vein, posterior gastric vein, and short gastric vein. The efferent system is formed by the gastroduodenal shunt into the left renal vein and less commonly via gastrocaval shunt.

pathway is via a direct gastrocaval shunt, in which the GVs drain directly into the inferior vena cava (IVC) via the inferior phrenic vein or pericardiophrenic vein (Figure 1).<sup>8</sup>

To guide endovascular interventions, Kiyosue et al.<sup>9</sup> classify GVs based on the anatomy of their afferent (inflow) and efferent (outflow/draining) veins (Table 2). An understanding of this anatomy is of critical importance, as technical success in the obliteration of GVs is related to the anatomy of the varix. Based on afferent veins, the GVs are divided into three types (Figure 2). **Type I** has a single afferent (inflow) vein, either LGV or PGV, and is the easiest type to treat via RTO if the efferent (outflow) veins are occluded, with its high success rate due to high pressure from the portal system allowing the sclerosant to fill the whole variceal complex. **Type II** has two afferent gastric veins, namely, the LGV and the PGV. During the RTO procedure, it is important to know that once the efferent veins are occluded, one of these afferent veins (LGV or PGV) will act as a draining “efferent” vein, resulting in the efflux of sclerosant into the portal system. Type III has single or multiple afferent veins; however, an additional gastric vein drains into the shunt without communication to the varix. Failure to recognize this type can result in reflux of sclerosant into the portal system rather than the GVs. Based on the efferent veins, the GVs are divided into four types (Figure 3), as described in Table 2.<sup>9</sup>

## Preprocedure

### Indications

The main indications for transvenous obliteration of GVs are bleeding GVs refractory to endoscopic management, prevention of rebleeding after successful endoscopic management, refractory HE due to portosystemic shunts, and non-tolerance to TIPS.<sup>3,10,11</sup> The AASLD management recommendations for GVs are summarized in Table 3.<sup>3</sup>

### Contraindications

The contraindications to transvenous obliteration of GVs are severe coagulopathy, refractory ascites, severe liver dysfunction, and high-risk EVs. In patients with high-risk EVs, the EVs should be treated endoscopically prior to treatment with transvenous obliteration of GV. This GV obliteration increases the portal venous pressure following shunt occlusion, which can worsen both ascites and EVs.<sup>10,12,13</sup>

### Imaging

Preprocedural planning is conducted by performing computed tomography angiography, while magnetic resonance angiography can be considered if the patient is allergic to iodinated contrast. The role of preprocedural imaging is to define the anatomy of the shunt and varices, assess the diameter of the GRS, and allow for planning of the ap-

### Main points

- Upper gastrointestinal bleeding due to gastric varices (GVs) is less common than esophageal varices but is associated with higher morbidity and mortality.
- Transvenous obliteration techniques are an important tool in the management of bleeding GVs with ever-evolving modifications.
- Understanding the complex anatomy of a variceal complex is of paramount importance to achieving both high technical and clinical success in treating GVs.

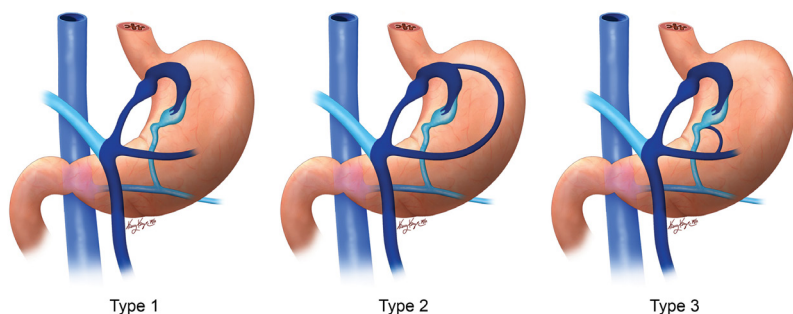
**Table 1.** Endovascular techniques for gastric varices

TIPS
<b>Retrograde transvenous obliteration (via the systemic veins):</b>
• Balloon-occluded retrograde transvenous obliteration
• Plug-assisted retrograde transvenous obliteration
• Coil-assisted retrograde transvenous obliteration
<b>Antegrade transvenous obliteration (via the portal vein):</b>
• This includes balloon-occluded antegrade transvenous obliteration, plug-assisted antegrade transvenous, and coil-assisted antegrade transvenous obliteration with the following subtypes:
1. Percutaneous transhepatic obliteration
2. Transjugular intrahepatic portosystemic shunt obliteration

**Table 2.** Classification of gastric varix based on afferent veins<sup>9</sup>

<b>Type I</b>	It is supplied by a single afferent (inflow) gastric vein—either LGV or PGV
<b>Type II</b>	It is supplied by two afferent gastric veins, namely the LGV and PGV
<b>Type III</b>	It is supplied by a single or multiple afferent veins; however, a separate gastric vein drains into the shunt without communication to the gastric varices
<b>Classification of gastric varix based on efferent veins</b>	
<b>Type A</b>	It has a single draining shunt—splenorenal or gastrocaval shunt
<b>Type B</b>	It has a single draining shunt with single or multiple collaterals
<b>Type C</b>	It has both gastrosplenic and gastrocaval shunts
<b>Type D</b>	It does not have a shunt and drains via small collaterals

LGV, left gastric vein; PGV, posterior gastric vein.



**Figure 2.** Classification of gastric varices on the basis of afferent veins. Type I has a single afferent vein, the left gastric vein in the graphic. Type II is supplied by two afferent veins: the left gastric vein and posterior gastric vein. Type III has a separate vein draining into the gastrorenal shunt without communication with the remaining afferents.

proach to cannulating the shunt, while it also helps identify portal and splenic vein thrombosis, as well as the presence of ascites.

### Sclerosants

The choice of sclerosant varies among interventionalists, with diverse safety profiles of each agent. Sodium tetradecyl sulfate (STS) is a commonly used agent in the US, originally introduced as an alternative to ethanolamine oleate (EO) for BRTO in 2006. It is an inexpensive agent that acts as a chemical irritant causing permanent endothelial damage. The STS foam is made by mixing lipiodol, 3% STS, and gas (air/carbon dioxide) in a ratio of 1:2:3 mL. Several studies have demonstrat-

ed that the result of BRTO with STS is similar to that with EO, with lower rates of complication, reporting a technical success rate of 79%–100% and a rebleeding rate of less than 5%.<sup>14–16</sup> Pulmonary edema and portal vein thrombosis are rarely reported side effects of STS.<sup>17,18</sup>

Polidocanol is another sclerosant that has been used in BRTO. Itou et al.<sup>15</sup> demonstrated that the technical success in achieving obliteration of varices using polidocanol foam is comparable to that of EO with a lower complication rate. In addition, polidocanol was initially used as a local anesthetic, and is therefore associated with significant reduction in pain compared with EO.<sup>15</sup>

In fact, EO was the initial sclerosant of choice, particularly in Asia; however, this agent is associated with hemolysis and release of free hemoglobin, causing renal tubular injury and renal failure, while it is also associated with the following reported side effects: pulmonary edema, cardiogenic shock, and disseminated intravascular coagulation.<sup>16,19–21</sup> Haptoglobin (4,000 U), which binds free hemoglobin, has been used to reduce the renal toxicity of the EO, but this is not approved by the Food and Drug Administration for use in the US. The sclerosant mixture is made by mixing 5%–10% EO with contrast in a ratio of 1:1.

The other agents used are N-butyl-2-cyanoacrylate glue and Gelfoam. Cyanoacrylate glue is expensive but an option for embolizing the collaterals, while Gelfoam is cheap, readily available, and a more familiar agent among interventional radiologists.<sup>21</sup> Jogo et al.<sup>22</sup> demonstrated that the use of GERTO (i.e., gelatin and 5% EO iopamidol mixture in RTO) for the treatment of GV is associated with fewer sclerosants and a shorter operative time compared with conventional BRTO.

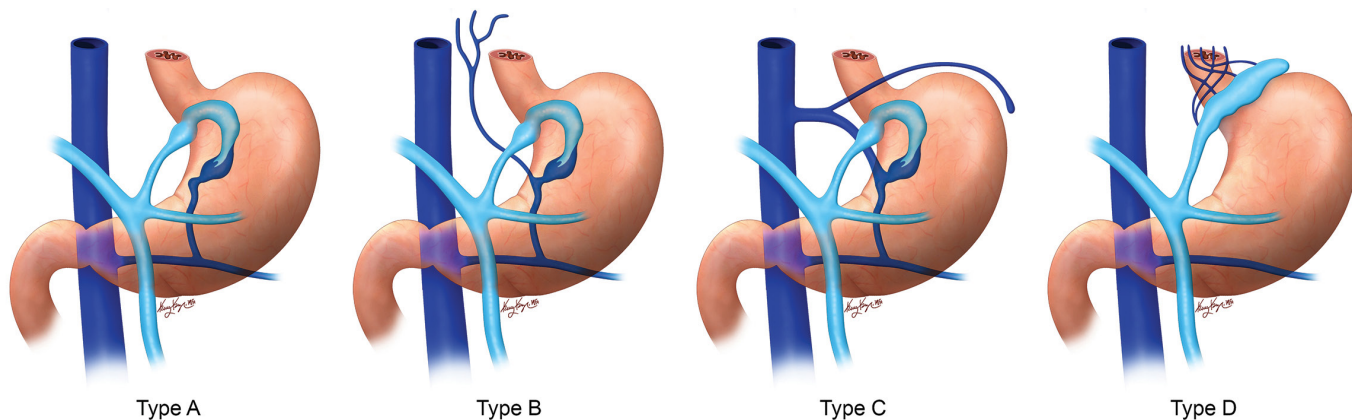
## Procedures

### Balloon-occluded retrograde transvenous obliteration

This is one of the subtypes of RTO, in which the left renal vein is cannulated in retrograde via the jugular or femoral vein, followed by occlusion of the shunt by a balloon and infusion of sclerosant to occlude the splenorenal shunt and fundal varices (Figure 4).<sup>23–25</sup> Once the shunt is occluded by the balloon, a digitally subtracted venography is performed to assess the type of varix, as well as its venous drainage.<sup>10</sup> The presence of collateral veins identified via venography may prevent the complete filling of the shunt; therefore, these veins are embolized with coils, Gelfoam, plugs, or glue, as per the size and characteristics of the collaterals.<sup>10,13,26</sup> Following embolization of the collateral veins, sclerosant with a contrast agent is injected into the varix until it is fully opacified with the balloon inflated. Several researchers advocate the use of a coaxial microcatheter system for more selective obliteration of the GVs while keeping the GRS patent.<sup>27</sup> However, a patent GRS may result in technical failure with recurrence of GVs, meaning obliteration of both GRS and GVs is crucial.<sup>28</sup>

The end point of embolization is when minimal filling of the afferent portal branches is noted during balloon occlusion venog-





**Figure 3.** Classification of gastric varices on the basis of efferent veins. Type A has a single draining shunt. Type B has a single draining shunt with single or multiple collaterals. Type C has both gastrorenal shunt and gastrocaval shunt. Type D does not have a shunt and drains via small collaterals.

**Table 3.** AASLD recommendations

**Primary prophylaxis for gastric varices**

- The recommendations for primary prophylaxis for GOV1 are similar to those for esophageal varices, which include either NSBBs or EVL
- In patients with IGV1, NSBBs can be considered for primary prophylaxis; however, the evidence is not as strong
- Neither TIPS nor transvenous obliteration (BRTO and its variations) are recommended for primary prophylaxis of IGV1

**Acute gastric variceal hemorrhage**

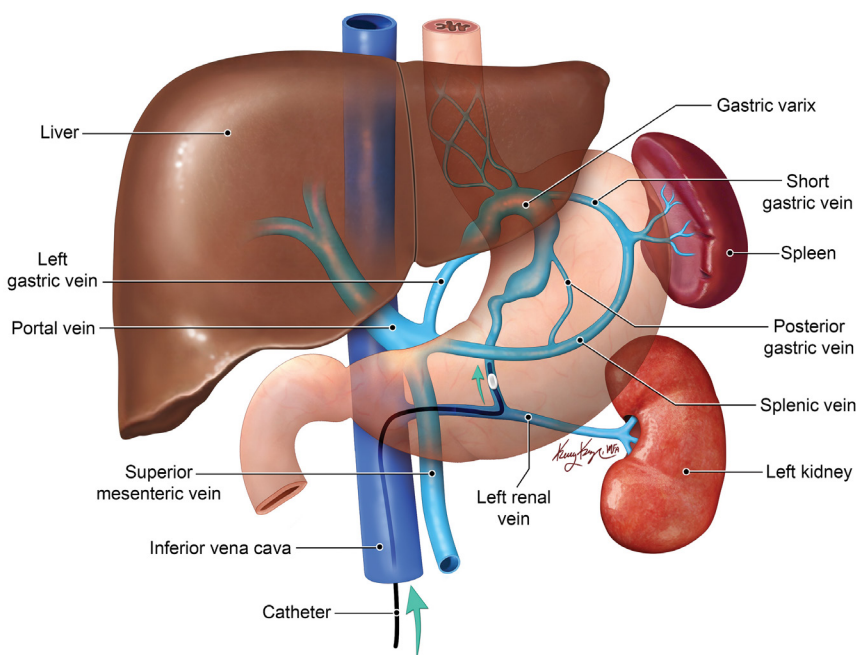
- The initial management of choice for bleeding GOV1 is endoscopy with either EVL or cyanoacrylate injection
- TIPS is the management of choice for bleeding cardiofundal varices (GOV2 and IGV1)
- TIPS or BRTO are first-line treatments in the prevention of rebleeding in patients who have recovered from GOV2 and IGV1 bleeding

AASLD, American Association for the Study of Liver Disease; GOV1, gastroesophageal varices type 1; NSBBs, non-selective beta-blockers; EVL, endoscopic variceal ligation; IGV1, type 1 isolated gastric varices; TIPS, transjugular intrahepatic portosystemic shunt; GOV2, gastroesophageal varices type 2; BRTO, balloon-occluded retrograde transvenous obliteration.

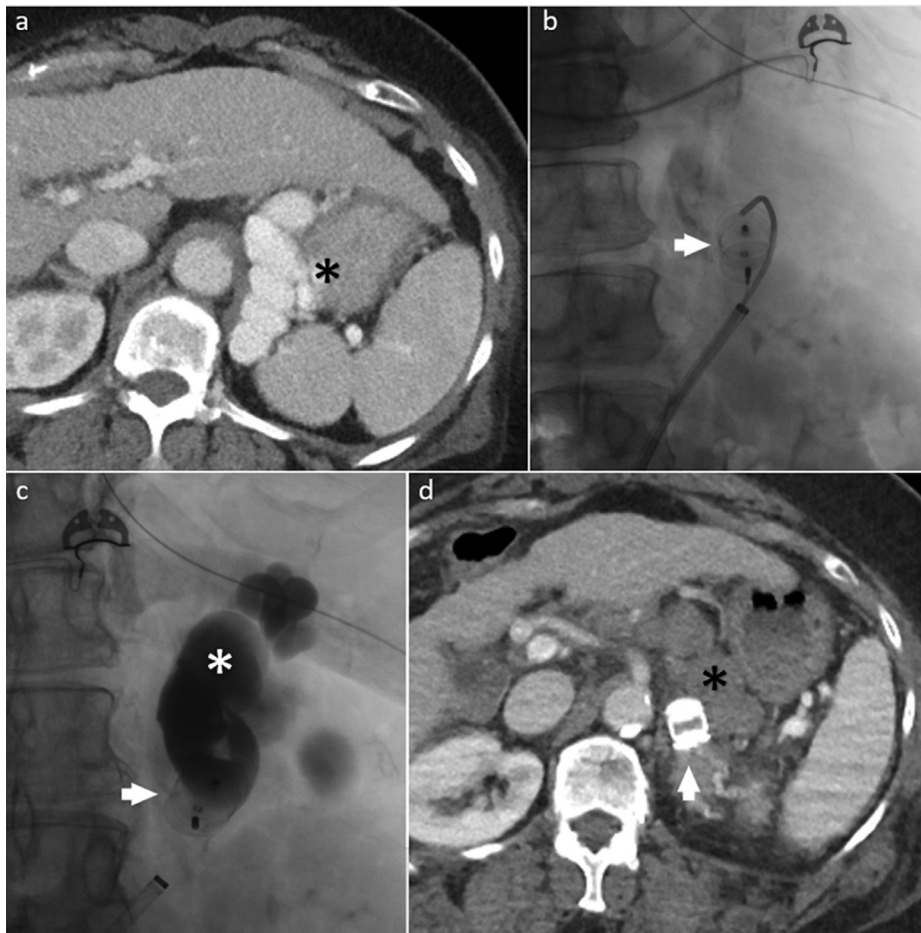
raphy. Treatment failure can occur if the sclerosant volume is insufficient to fill the entire variceal complex. Here, the balloon remains inflated while the patient is transferred to the intensive care unit. The duration of balloon inflation time is highly variable and ranges from 4 to 24 hours before the patient is returned to the interventional radiology suite for the deflation of the balloon.<sup>10,13,26</sup> Given the high level of care required for patients undergoing BRTO post-balloon inflation, this procedure has fallen out of favor in the US. Waguri et al.<sup>29,30</sup> demonstrated that BRTO combined with partial splenic embolization may help diminish the increase in portal pressures after BRTO, thereby reducing the exacerbation of EVs.

**Plug-assisted retrograde transvenous obliteration**

This subtype of RTO involves deployment of a permanent vascular plug in the efferent limb of the GRS (Figure 5) and was first described by Gwon et al.<sup>17</sup> Much like BRTO, the procedure involves retrograde cannulation of the left renal vein by the internal jugular or femoral vein following placement of an 8–10 Fr sheath. The GRS is then selected using an angled catheter (Simmons, Cobra), and venography is performed to assess the anatomy of the variceal complex and evaluate the narrowest part of the shunt. This is followed by placement of access sheath into the GRS and advancing a 0.035" guidewire through the sheath into the varix. A vascular plug that is 15%–30% larger than the narrowest portion of the shunt is then deployed (not released) into the narrowest portion of the shunt.<sup>21,31</sup> A 4 Fr catheter is then advanced over guidewire into the GV, and slow retrograde venography is performed after waiting 5–10 min for occlusion of the shunt. If additional collaterals are identified via venography, these are



**Figure 4.** Balloon-occluded retrograde transvenous obliteration (BRTO). Graphic shows a BRTO procedure for gastric varices that drain via the gastrorenal shunt. A balloon catheter is inserted into the outlet of the gastrorenal shunt (in this drawing) or gastrocaval shunt via femoral venous access. Following balloon-occluded venography, sclerosant is then infused through the balloon catheter to fill the entire variceal complex.



embolized with either Gelfoam or coils via a 4 Fr or coaxial microcatheter. A Gelfoam slurry is then infused through the 4 Fr catheter into the variceal complex. Once the Gelfoam slurry is delivered, the catheter is removed and the vascular plug is detached (released). The Gelfoam slurry is made by mixing a hand-cut Gelfoam sheet with contrast media, while a mixture of Gelfoam with a sclerosant (STS) has also been used.<sup>32</sup>

#### Coil-assisted retrograde transvenous obliteration

This subtype of RTO involves placement of coils and Gelfoam slurry instead of using balloons or plugs. It was first described by Lee et al.<sup>33</sup> and is a useful alternative in patients where the size of the shunt, angle of the shunt, and tortuosity of the vessel are not favorable to either BRTO or PARTO. There are two subtypes of CARTO procedure. The **CARTO-I** procedure involves placement of an access sheath in the efferent limb of the GRS (no balloon catheter). Here, two microcatheter systems are used, with one microcatheter placed proximally at the narrowest part of the GRS, and the second advanced upstream into the GV. Using the microcatheter placed in the GRS, multiple coils are deployed to completely occlude the shunt. Following embolization of the GRS, Gelfoam slurry or STS is injected through the microcatheter into the varix. **CARTO-II** follows the same steps as BRTO with placement of a balloon catheter into the efferent limb of GRS. This is followed by infusion of sclerosant into the variceal complex, followed by deploy-

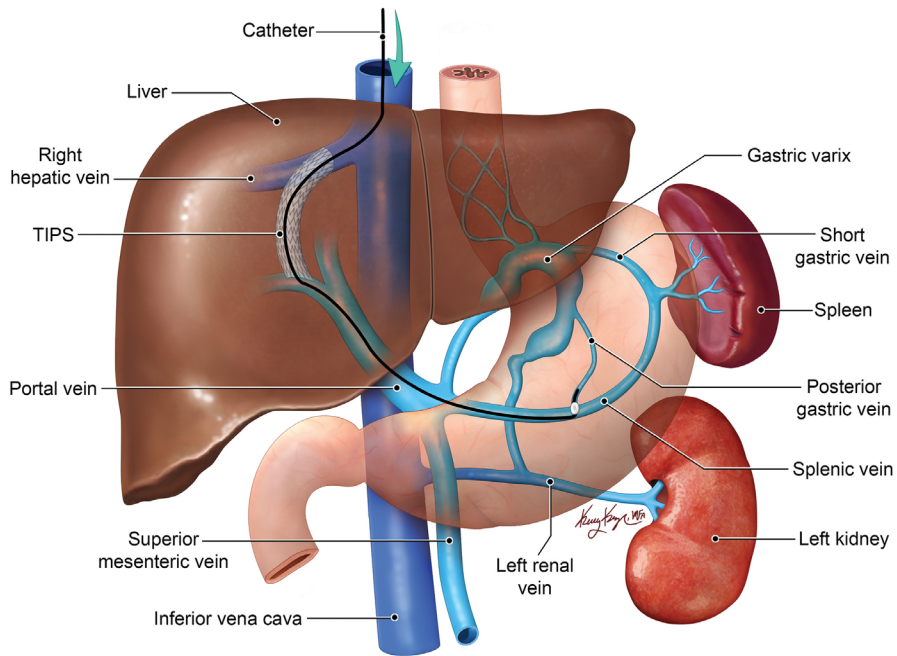
**Figure 5.** Vascular plug-assisted retrograde transvenous obliteration. A 68-year-old female with cirrhosis presented with upper gastrointestinal bleed and type 1 isolated gastric varices on endoscopy. A contrast-enhanced axial CT image (a) prior to the procedure showing fundal gastric varices (black\*). Fluoroscopic images (b, c) showing vascular plug placement in the left adrenal vein (white arrow) via the right femoral vein access site with embolization of the gastroduodenal shunt and fundal varices (white\*) using a thick slurry of Gelfoam mixed with saline and contrast. Contrast-enhanced axial CT image (d) after the procedure showing complete obliteration of the fundal varices. CT, computed tomography.

**Table 4.** Comparison of RTO and ATO techniques

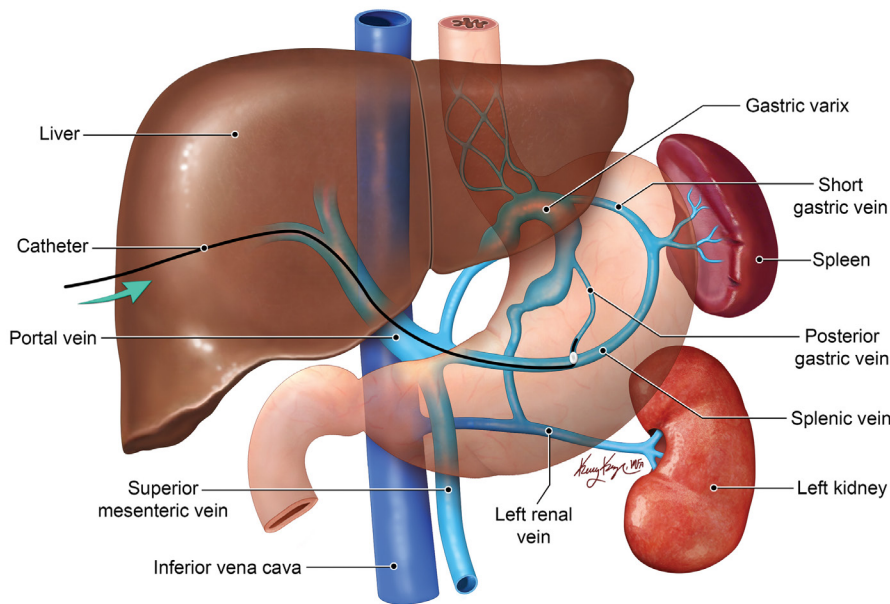
<b>BRTO</b>	<ul style="list-style-type: none"> <li>• High technical and clinical success rates</li> <li>• Long procedure times (40–360 min in BRTO with EO and 90–163 min in BRTO with STS)<sup>17</sup></li> <li>• Requires indwelling balloon occlusion (4–24 hours)</li> <li>• Requires higher level (ICU) monitoring before bringing patient back for balloon deflation</li> <li>• Balloon can rupture with potential systemic dissemination of sclerosing agent</li> <li>• Potential toxicity of sclerosing agents (pulmonary embolism, hemoglobinuria, renal failure, pulmonary edema, DIC)</li> </ul>
<b>PARTO</b>	<ul style="list-style-type: none"> <li>• High technical and clinical success rates</li> <li>• Shorter procedure times (20–68 min)<sup>32</sup></li> <li>• Does not require balloon occlusion or higher level monitoring</li> <li>• Coil embolization of small collateral veins is not required in all cases</li> <li>• Recurrence of gastric varices may be higher compared with BRTO<sup>17</sup></li> <li>• Limited by GR shunt angle</li> <li>• Limited by GR shunt size (shunts of &gt;18 mm are not routinely occluded)<sup>22</sup></li> </ul>
<b>CARTO</b>	<ul style="list-style-type: none"> <li>• High technical and clinical success rates</li> <li>• Intermediate procedure time 132–168 min compared with 20–68 mins in PARTO<sup>32,34</sup></li> <li>• Does not require balloon occlusion or higher level monitoring</li> <li>• It is not limited by GR shunt angle or size (can be used in shunts up to 25–30 mm)<sup>29</sup></li> </ul>
<b>ATO</b>	<ul style="list-style-type: none"> <li>• It is useful in patients with no GR shunt</li> <li>• It is useful in patients with TIPS</li> <li>• It can be performed via TIPS or via percutaneous transhepatic access</li> </ul>

RTO, retrograde transvenous obliteration; ATO, antegrade transvenous obliteration; BRTO, balloon-occluded retrograde transvenous obliteration; EO, ethanolamine oleate; STS, sodium tetradecyl sulfate; ICU, intensive care unit; DIC, disseminated intravascular coagulation; PARTO, plug-assisted antegrade transvenous obliteration; GR, gastroduodenal; CARTO, coil-assisted retrograde transvenous obliteration; TIPS, transjugular intrahepatic portosystemic shunt.





**Figure 6.** Balloon-occluded antegrade transvenous obliteration (BATO). Subtype: trans-transjugular intrahepatic portosystemic shunt (TIPS) BATO: BATO involves embolization of the varices from the portal venous side. The graphic shows a subclassification of the BATO procedure known as trans-TIPS obliteration, in which the portal vein, and subsequently the portal venous side of varices, is accessed via indwelling TIPS.



**Figure 7.** Balloon-occluded antegrade transvenous obliteration (BATO). Subtype: percutaneous transhepatic obliteration. BATO involves embolization of the varices from the portal venous side. The graphic shows a subclassification of the BATO procedure known as percutaneous transhepatic obliteration, in which the portal vein, and subsequently the portal venous side of varices, is accessed percutaneously.

ment of multiple metallic coils into the GRS via a balloon catheter. The balloon catheter is then removed approximately 30 min after injection of the sclerosant.<sup>34</sup>

### Antegrade transvenous obliteration

This procedure involves transvenous obliteration of GVs via portal venous access (antegrade) rather than the systemic venous access (retrograde) used in RTO procedures. This can be achieved by using balloon-occlusion (BATO), coils (CATO), or plugs (PATO). The

procedure can be used as an adjunct to RTO procedures or as an alternative procedure in treating GVs without a GRS.<sup>35</sup> The two most common subtypes of the ATO procedure are PTO and trans-TIPS obliteration (Figures 6, 7), with the former involving accessing the portal vein using a micropuncture technique under real-time ultrasound guidance. Once access is achieved, the needle is exchanged for a sheath of adequate size (5–7 Fr) to accommodate most occlusion balloons, coils, or plugs. A venogram is performed to delineate the anatomy. In BATO, if multiple afferent veins are present, the largest vein is left for balloon occlusion, while the small afferent veins are occluded using coils or vascular plugs. Once the small veins are embolized, the largest vein is then occluded by a balloon catheter, with subsequent steps of sclerosant injection into the varix similar to that of a standard BRTO procedure. In the **trans-TIPS** approach, the varices are accessed using the pre-existing TIPS, with the remaining steps similar to those of PTO. The advantage of this approach is that it involves no new access, which minimizes the risk of vascular and biliary injury, while the disadvantages include being an invasive route, being time consuming, and involving long and indirect access to the GVs.<sup>32,35</sup>

## Post-procedure

### Immediate complications

Minor periprocedural complications include access site bleeding and hematoma, access site infection, and pain. Additional transient complications include low-grade fever, hypertension, nausea and vomiting, abdominal and back pain.<sup>36</sup> Major complications include renal failure, pulmonary embolism, and venous thrombosis involving the portal vein, splenic vein, IVC, renal and iliac veins. A major complication specific to BRTO is related to balloon rupture and subsequent systemic dissemination of the embolic agent, which can cause hemoglobinuria, renal failure, and pulmonary embolism. Balloon rupture with embolization of the sclerosing material to the pulmonary arteries is a potentially fatal complication. Balloon rupture occurs in 2.3%–8.7% of BRTO procedures.<sup>37,38</sup> Complications specific to the type of sclerosing agent used are mentioned in the “sclerosant” section above.

### Delayed complications

The RTO procedures redirect blood flow to the liver (increased hepatopetal flow), which increases portal pressure and its re-

lated complications, such as EVs, ascites, and portal gastropathy. In terms of BRTO, EV exacerbation at one, two, and three years has been reported to be 27%–35%, 45%–66%, and 45%–91%, respectively.<sup>39</sup> Choi et al.<sup>40</sup> reported that in BRTO, bleeding from EVs was statistically significant at five and seven years, with *P* values of 0.02 and <0.01, respectively, and no significant bleeding risk at one and three years. In terms of the PARTO procedure, new or exacerbated EVs have been reported at between 22% and 33% at three to nine months.<sup>17,21,31,41</sup> The incidence of EV exacerbation is similar in patients post-CARTO at 23%.<sup>33</sup> Therefore, patients who have undergone a RTO procedure will require long-term endoscopic surveillance for EVs with the initial endoscopy at one to three months after intervention. Independent risk factors for the exacerbation of EVs include total bilirubin of >1.6 mg/dL and a hepatic venous pressure gradient of >13 mmHg.<sup>42</sup> Researchers have described the concomitant use of splenic embolization along with transvenous obliteration to prevent the exacerbation of EVs.<sup>29,30</sup> New or worsening ascites or hepatic hydrothorax is another major complication following BRTO, PARTO, and CARTO, with an incidence rate of 0%–44%, 11%–58%, and 25%, respectively.<sup>19,21,31,33,37,41</sup> Worsening portal gastropathy is reported in 5%–13% of patients following BRTO and 20% after CARTO.<sup>33,37</sup>

## Outcomes

The technical success of the procedure mainly relates to the successful cannulation of the portosystemic shunt, including the GRS, accurate placement of the occlusion device, and filling of the whole shunt with the sclerosant. Clinical success relates to resolution of the GI bleeding without recurrent bleeding, and/or complete obliteration of the shunt on follow-up imaging/endoscopy.

In terms of BRTO, the technical success rates range from 79% to 100%, with clinical success rates of 91%–100%. The technical success rate of BRTO is increased to 98%–100% when combined with BATO.<sup>26</sup> The rates of rebleeding in technically successful procedures range from 0% to 20%, but are typically below 10%. The survival rates at one year, three years, and five years range from 8% to 100%, 75%–100%, and 39%–85%, respectively.<sup>9,10</sup> Improvement in HE is reported in the range of 80%–100% at two to three years post-procedure.<sup>19,37,43,44</sup> This improvement in HE is due to improved hepatopetal flow. Post-BRTO, there is evidence of improved hepatic

synthetic function for six to nine months, after which the hepatic reserve returns to baseline.<sup>37,45</sup> This short-term improvement is due to improved hepatopetal flow and may prove beneficial in patients with a high likelihood of requiring a liver transplant. Given that there is a high incidence of ascites post-BRTO, the MELD score appears to be more sensitive for the assessment of hepatic function compared with the Child–Pugh score in patients who have undergone transvenous obliteration of GVs.<sup>46</sup>

In a recent meta-analysis, Wang et al.<sup>47</sup> compared the effects of TIPS versus BRTO on bleeding GVs, with the results indicating that BRTO was superior to TIPS, with higher overall survival rates and lower rates of rebleeding. These results were similar to those obtained in the meta-analysis conducted by Paleti et al.<sup>48</sup> and the retrospective study conducted by Gimm et al.<sup>49</sup> Increasingly, TIPS and transvenous obliteration are considered to be complementary procedures in treating patients with portal hypertension, reducing the risk of variceal bleeding. Transvenous obliteration procedures control bleeding from GVs by obliterating the spontaneous portosystemic shunt, which, in turn, increases portal pressure and the related complications of EV, ascites, and hepatic hydrothorax. By combining transvenous obliteration with TIPS, the increased portal pressure associated with transvenous obliteration is countered by the creation of the TIPS procedure. There is growing evidence that combining transvenous obliteration procedures with TIPS is more effective in managing GVs than either procedure alone.<sup>50–52</sup>

In terms of PARTO, the technical success rates range from 94.7% to 100%, with clinical success rates of 90.6%–100%. Post-PARTO improvement in the hepatic synthetic function has been reported in up to 67% of patients.<sup>16,17,21,31,41</sup> This improvement in liver function is significant during the first six months compared with the baseline.<sup>53</sup> Patients with a Child–Pugh class of B or C exhibit greater improvement in hepatic function compared with those in Child–Pugh A class.<sup>54</sup> The rebleeding rate is similar to that of BRTO and is reported to be 11% at one year.<sup>16</sup> In a recent retrospective study, Park et al.<sup>53</sup> reported a worsening of EVs in 53% of patients who underwent PARTO, and in this study, 16 out of the 26 patients with worsening of post-PARTO EVs underwent endoscopic variceal ligation.

In terms of CARTO, the technical and clinical success rates are up to 100%, as reported by Lee et al.<sup>33</sup>, with no variceal rebleeding noted during a mean follow-up of around 12 ± 5 months. Similar high technical (100%) and clinical (97.2%) success rates were reported in a retrospective study of 36 patients conducted by Yamamoto et al.<sup>34</sup> Compared with PARTO, the procedure time for CARTO is longer, as it requires deployment of multiple coils during the procedure, in contrast to a single vascular plug in PARTO.

## Conclusion

Generally, GVs are seen in around 20% of patients with cirrhosis and are associated with higher morbidity and mortality rates compared with EVs. Many researchers consider transvenous obliteration techniques to be as effective as placement of TIPS in controlling a GV hemorrhage. Increasingly, TIPS and transvenous obliteration are being considered as complementary procedures in treating patients with portal hypertension, reducing the risk of variceal bleeding. Knowledge of the complex anatomy of GVs, as well as familiarity with various procedural techniques, is essential for favorable clinical outcomes in these patient populations. Newer techniques and advances continue to make these procedures safer, shorter, and more effective in treating these complications and improving the quality of life and survival of the patients.

## Acknowledgment

The illustrations were drawn by Mrs. Kelly Kage, for which we thank her.

## Conflict of interest disclosure

The authors declared no conflicts of interest.

## References

1. de Franchis R, Primignani M. Natural history of portal hypertension in patients with cirrhosis. *Clin Liver Dis*. 2001;5(3):645-663. [\[CrossRef\]](#)
2. Sarin SK, Lahoti D, Saxena SP, Murthy NS, Makwana UK. Prevalence, classification and natural history of gastric varices: a long-term follow-up study in 568 portal hypertension patients. *Hepatology*. 1992;16(6):1343-1349. [\[CrossRef\]](#)
3. Garcia-Tsao G, Abraldes JG, Berzigotti A, Bosch J. Portal hypertensive bleeding in cirrhosis: risk stratification, diagnosis, and management: 2016 practice guidance by the American Association for the study of liver diseases. *Hepatology*. 2017;65(1):310-335. [\[CrossRef\]](#)

4. Ferral H, Gamboa P, Postoak DW, et al. Survival after elective transjugular intrahepatic portosystemic shunt creation: prediction with model for end-stage liver disease score. *Radiology*. 2004;231(1):231-236. [\[CrossRef\]](#)
5. Montgomery A, Ferral H, Vasan R, Postoak DW. MELD score as a predictor of early death in patients undergoing elective transjugular intrahepatic portosystemic shunt (TIPS) procedures. *Cardiovasc Intervent Radiol*. 2005;28(3):307-312. [\[CrossRef\]](#)
6. Tripathi D, Therapondos G, Jackson E, Redhead DN, Hayes PC. The role of the transjugular intrahepatic portosystemic stent shunt (TIPSS) in the management of bleeding gastric varices: clinical and haemodynamic correlations. *Gut*. 2002;51(2):270-274. [\[CrossRef\]](#)
7. Kim T, Shijo H, Kokawa H, et al. Risk factors for hemorrhage from gastric fundal varices. *Hepatology*. 1997;25(2):307-312. [\[CrossRef\]](#)
8. Sabri SS, Saad WE. Anatomy and classification of gastroduodenal and gastroduodenal shunts. *Semin Intervent Radiol*. 2011;28(3):296-302. [\[CrossRef\]](#)
9. Kiyosue H, Mori H, Matsumoto S, Yamada Y, Hori Y, Okino Y. Transcatheter obliteration of gastric varices. Part 1. Anatomic classification. *Radiographics*. 2003;23(4):911-920. [\[CrossRef\]](#)
10. Saad WE. Balloon-occluded retrograde transvenous obliteration of gastric varices: concept, basic techniques, and outcomes. *Semin Intervent Radiol*. 2012;29(2):118-128. [\[CrossRef\]](#)
11. Ishikawa T, Sasaki R, Nishimura T, et al. Comparison of patients with hepatic encephalopathy and those with gastric varices before and after balloon-occluded retrograde transvenous obliteration. *Hepatol Res*. 2018;48(12):1020-1030. [\[CrossRef\]](#)
12. Chikamori F, Kuniyoshi N, Shibuya S, Takase Y. Eight years of experience with transjugular retrograde obliteration for gastric varices with gastroduodenal shunts. *Surgery*. 2001;129(4):414-420. [\[CrossRef\]](#)
13. Saad WE, Kitanosono T, Koizumi J, Hirota S. The conventional balloon-occluded retrograde transvenous obliteration procedure: indications, contraindications, and technical applications. *Tech Vasc Interv Radiol*. 2013;16(2):101-151. [\[CrossRef\]](#)
14. Chu HH, Kim M, Kim HC, Lee JH, Jae HJ, Chung JW. Long-term outcomes of balloon-occluded retrograde transvenous obliteration for the treatment of gastric varices: a comparison of ethanolamine oleate and sodium tetradecyl sulfate. *Cardiovasc Intervent Radiol*. 2018;41(4):578-586. [\[CrossRef\]](#)
15. Itou C, Koizumi J, Hashimoto T, et al. Balloon-occluded retrograde transvenous obliteration for the treatment of gastric varices: polidocanol foam versus liquid ethanolamine oleate. *AJR Am J Roentgenol*. 2015;205(3):659-666. [\[CrossRef\]](#)
16. Kim YH, Kim YH, Kim CS, Kang UR, Kim SH, Kim JH. Comparison of balloon-occluded retrograde transvenous obliteration (BRTO) using ethanolamine oleate (EO), BRTO using sodium tetradecyl sulfate (STS) foam and vascular plug-assisted retrograde transvenous obliteration (PARTO). *Cardiovasc Intervent Radiol*. 2016;39(6):840-846. [\[CrossRef\]](#)
17. Gwon DI, Ko GY, Yoon HK, et al. Gastric varices and hepatic encephalopathy: treatment with vascular plug and gelatin sponge-assisted retrograde transvenous obliteration—a primary report. *Radiology*. 2013;268(1):281-287. [\[CrossRef\]](#)
18. Choi SY, Won JY, Kim KA, Lee DY, Lee KH. Foam sclerotherapy using polidocanol for balloon-occluded retrograde transvenous obliteration (BRTO). *Eur Radiol*. 2011;21(1):122-129. [\[CrossRef\]](#)
19. Park JK, Saab S, Kee ST, et al. Balloon-occluded retrograde transvenous obliteration (BRTO) for treatment of gastric varices: review and meta-analysis. *Dig Dis Sci*. 2015;60(6):1543-1553. [\[CrossRef\]](#)
20. Sabri SS, Saad WE. Balloon-occluded retrograde transvenous obliteration (BRTO): technique and intraprocedural imaging. *Semin Intervent Radiol*. 2011;28(3):303-313. [\[CrossRef\]](#)
21. Chang MY, Kim MD, Kim T, et al. Plug-assisted retrograde transvenous obliteration for the treatment of gastric variceal hemorrhage. *Korean J Radiol*. 2016;17(2):230-238. [\[CrossRef\]](#)
22. Jogo A, Yamamoto A, Kaminoh T, et al. Utility of low-dose gelatin sponge particles and 5% ethanolamine oleate iopamidol mixture in retrograde transvenous obliteration (GERTO) for gastric varices. *Br J Radiol*. 2020;93(1108):20190751. [\[CrossRef\]](#)
23. Fukuda T, Hirota S, Sugimura K. Long-term results of balloon-occluded retrograde transvenous obliteration for the treatment of gastric varices and hepatic encephalopathy. *J Vasc Interv Radiol*. 2001;12(3):327-336. [\[CrossRef\]](#)
24. Saad WE. Endovascular management of gastric varices. *Clin Liver Dis*. 2014;18(4):829-851. [\[CrossRef\]](#)
25. Koito K, Namieno T, Nagakawa T, Morita K. Balloon-occluded retrograde transvenous obliteration for gastric varices with gastroduodenal or gastroduodenal collaterals. *AJR Am J Roentgenol*. 1996;167(5):1317-1320. [\[CrossRef\]](#)
26. Saad WE, Kitanosono T, Koizumi J. Balloon-occluded antegrade transvenous obliteration with or without balloon-occluded retrograde transvenous obliteration for the management of gastric varices: concept and technical applications. *Tech Vasc Interv Radiol*. 2012;15(3):203-225. [\[CrossRef\]](#)
27. Takahashi K, Yamada T, Hyodoh H, et al. Selective balloon-occluded retrograde sclerosis of gastric varices using a coaxial microcatheter system. *Am J Roentgenol*. 2001;177:1091-1093. [\[CrossRef\]](#)
28. Katoh K, Sone M, Hirose A, Inoue Y, Fujino Y, Onodera M. Balloon-occluded retrograde transvenous obliteration for gastric varices: the relationship between the clinical outcome and gastroduodenal shunt occlusion. *BMC Med Imaging*. 2010;10:2. [\[CrossRef\]](#)
29. Waguri N, Hayashi M, Yokoo T, et al. Simultaneous combined balloon-occluded retrograde transvenous obliteration and partial splenic embolization for portosystemic shunts. *J Vasc Interv Radiol*. 2012;23(5):650-657. [\[CrossRef\]](#)
30. Waguri N, Osaki A, Ikarashi S, et al. Simultaneous combined balloon-occluded retrograde transvenous obliteration and partial splenic embolization for gastric fundal varices. *United European Gastroenterol J*. 2016;4(1):62-69. [\[CrossRef\]](#)
31. Kim T, Yang H, Lee CK, Kim GB. Vascular plug assisted retrograde transvenous obliteration (PARTO) for gastric varix bleeding patients in the emergent clinical setting. *Yonsei Med J*. 2016;57(4):973-979. [\[CrossRef\]](#)
32. Kim DJ, Darcy MD, Mani NB, et al. Modified balloon-occluded retrograde transvenous obliteration (BRTO) techniques for the treatment of gastric varices: vascular plug-assisted retrograde transvenous obliteration (PARTO)/coil-assisted retrograde transvenous obliteration (CARTO)/balloon-occluded antegrade transvenous obliteration (BATO). *Cardiovasc Intervent Radiol*. 2018;41(6):835-847. [\[CrossRef\]](#)
33. Lee EW, Saab S, Gomes AS, et al. Coil-assisted retrograde transvenous obliteration (CARTO) for the treatment of portal hypertensive variceal bleeding: preliminary results. *Clin Transl Gastroenterol*. 2014;5:e61. [\[CrossRef\]](#)
34. Yamamoto A, Jogo A, Kageyama K, et al. Utility of coil-assisted retrograde transvenous obliteration II (CARTO-II) for the treatment of gastric varices. *Cardiovasc Intervent Radiol*. 2020;43(4):565-571. [\[CrossRef\]](#)
35. Saad WE, Sze DY. Variations of balloon-occluded retrograde transvenous obliteration (BRTO): balloon-occluded antegrade transvenous obliteration (BATO) and alternative/adjunctive routes for BRTO. *Semin Intervent Radiol*. 2011;28(3):314-324. [\[CrossRef\]](#)
36. Sauer BG, Sabri SS, Shami VM, Al-Osaimi AM. Balloon-occluded retrograde transvenous obliteration (BRTO): follow-up and postprocedural imaging. *Semin Intervent Radiol*. 2011;28(3):325-332. [\[CrossRef\]](#)
37. Saad WE, Sabri SS. Balloon-occluded Retrograde Transvenous Obliteration (BRTO): technical results and Outcomes. *Semin Intervent Radiol*. 2011;28(3):333-338. [\[CrossRef\]](#)
38. Park SJ, Chung JW, Kim HC, Jae HJ, Park JH. The prevalence, risk factors, and clinical outcome



- of balloon rupture in balloon-occluded retrograde transvenous obliteration of gastric varices. *J Vasc Interv Radiol.* 2010;21(4):503-507. [\[CrossRef\]](#)
39. Saad WE, Darcy MD. Transjugular Intrahepatic Portosystemic Shunt (TIPS) versus balloon-occluded retrograde transvenous obliteration (BRTO) for the management of gastric varices. *Semin Intervent Radiol.* 2011;28(3):339-349. [\[CrossRef\]](#)
  40. Choi YS, Lee JH, Sinn DH, et al. Effect of balloon-occluded retrograde transvenous obliteration on the natural history of coexisting esophageal varices. *J Clin Gastroenterol.* 2008;42(9):974-979. [\[CrossRef\]](#)
  41. Gwon DI, Kim YH, Ko GY, et al. Vascular plug-assisted retrograde transvenous obliteration for the treatment of gastric varices and hepatic encephalopathy: a prospective multicenter study. *J Vasc Interv Radiol.* 2015;26:1589-1595. [\[CrossRef\]](#)
  42. Jogo A, Nishida N, Yamamoto A, et al. Factors associated with aggravation of esophageal varices after B-RTO for gastric varices. *Cardiovasc Intervent Radiol.* 2014;37(5):1243-1250. [\[CrossRef\]](#)
  43. Mukund A, Rajesh S, Arora A, Patidar Y, Jain D, Sarin SK. Efficacy of balloon-occluded retrograde transvenous obliteration of large spontaneous lienorenal shunt in patients with severe recurrent hepatic encephalopathy with foam sclerotherapy: initial experience. *J Vasc Interv Radiol.* 2012;23(9):1200-1206. [\[CrossRef\]](#)
  44. Inoue H, Emori K, Toyonaga A, et al. Long term results of balloon-occluded retrograde transvenous obliteration for portosystemic shunt encephalopathy in patients with liver cirrhosis and portal hypertension. *Kurume Med J.* 2014;61(1-2):1-8. [\[CrossRef\]](#)
  45. Takuma Y, Nouse K, Makino Y, Saito S, Shiratori Y. Prophylactic balloon-occluded retrograde transvenous obliteration for gastric varices in compensated cirrhosis. *Clin Gastroenterol Hepatol.* 2005;3(12):1245-1252. [\[CrossRef\]](#)
  46. Saad WE, Wagner CC, Al-Osaimi A, et al. The effect of balloon-occluded transvenous obliteration of gastric varices and gastrosplenic shunts on the hepatic synthetic function: a comparison between Child-Pugh and model for end-stage liver disease scores. *Vasc Endovascular Surg.* 2013;47(4):281-287. [\[CrossRef\]](#)
  47. Wang ZW, Liu JC, Zhao F, et al. Comparison of the effects of TIPS versus BRTO on bleeding gastric varices: a meta-analysis. *Can J Gastroenterol Hepatol.* 2020;2020:5143013. [\[CrossRef\]](#)
  48. Paleti S, Nutalapati V, Fathallah J, Jeepalyam S, Rustagi T. Balloon-occluded retrograde transvenous obliteration (BRTO) versus transjugular intrahepatic portosystemic shunt (TIPS) for treatment of gastric varices because of portal hypertension: a systematic review and meta-analysis. *J Clin Gastroenterol.* 2020;54(7):655-660. [\[CrossRef\]](#)
  49. Gimm G, Chang Y, Kim HC, et al. Balloon-occluded retrograde transvenous obliteration versus transjugular intrahepatic portosystemic shunt for the management of gastric variceal bleeding. *Gut Liver.* 2018;12(6):704-713. [\[CrossRef\]](#)
  50. Saad WE. Combining transjugular intrahepatic portosystemic shunt with balloon-occluded retrograde transvenous obliteration or augmenting TIPS with variceal embolization for the management of gastric varices: an evolving middle ground? *Semin Intervent Radiol.* 2014;31(3):266-268. [\[CrossRef\]](#)
  51. Sabri SS, Abi-Jaoudeh N, Swee W, et al. Short-term rebleeding rates for isolated gastric varices managed by transjugular intrahepatic portosystemic shunt versus balloon-occluded retrograde transvenous obliteration. *J Vasc Interv Radiol.* 2014;25(3):355-361. [\[CrossRef\]](#)
  52. Saad WE, Wagner CC, Lippert A, et al. Protective value of TIPS against the development of hydrothorax/ascites and upper gastrointestinal bleeding after balloon-occluded retrograde transvenous obliteration (BRTO). *Am J Gastroenterol.* 2013;108(10):1612-1619. [\[CrossRef\]](#)
  53. Park JW, Yoo JJ, Kim SG, et al. Change in portal pressure and clinical outcome in cirrhotic patients with gastric varices after plug-assisted retrograde transvenous obliteration. *Gut Liver.* 2020;14(6):783-791. [\[CrossRef\]](#)
  54. Uehara H, Akahoshi T, Tomikawa M, et al. Prediction of improved liver function after balloon-occluded retrograde transvenous obliteration: relation to hepatic vein pressure gradient. *J Gastroenterol Hepatol.* 2012;27(1):137-141. [\[CrossRef\]](#)