



Retrograde venous coil embolization prior to transarterial chemoembolization in hepatocellular carcinoma with arterio-hepatic venous shunts

Wenliang Zhu*

Zhenkang Qiu*

Huzheng Yan

Zhihui Zhong

Weiwei Jiang

Fujun Zhang*

Fei Gao*

PURPOSE

This study explored the clinical efficacy of transcatheter retrograde shunt occlusion with coils to prevent pulmonary oil or particle embolization prior to transarterial chemoembolization (TACE) in patients with arterio-hepatic venous shunts (AHVS) secondary to hepatocellular carcinoma (HCC).

METHODS

From July 2017 to January 2021, 6 patients with advanced, unresectable HCC were found to have an AHVS by hepatic arteriography at the time of attempted TACE. The AHVS was embolized retrogradely with metal coils through a transfemoral or transjugular venous approach. After venous embolization and confirmation of the absence of the AHVS, TACE was performed using an emulsion of iodized oil and doxorubicin or drug-eluting beads. Follow-up computed tomography (CT) was performed within 1 month after the first TACE to evaluate the results and complications.

RESULTS

Hepatic angiography after venous embolization showed that AHVS had utterly disappeared in all patients during the operation. The immediate technical success of the retrograde venous embolization was 100%. The AHVS had disappeared entirely during the follow-up period through triple-phase enhancement CT scanning. According to the modified response evaluation criteria in solid tumors, TACE in all 6 patients had a disease control response rate of 100% (6/6) with complete response in 2 patients and partial response in 4 patients. One patient died during the 6-month follow-up, and the other 5 were still alive. No complications related to pulmonary embolism occurred.

CONCLUSION

Retrograde venous coil embolization of AHVS via the draining hepatic vein appears to be a safe, feasible, and effective treatment to allow TACE treatment without pulmonary embolic events. This approach appears to provide better tumor control and effectively decreases the occurrence of pulmonary embolism.

From the Department of Minimally Invasive & Interventional Radiology (W.Z., Z.Q., Z.Z., W.J., F.Z. ✉ zhangfj@sysucc.org.cn, F.G. ✉ gaof@sysucc.org.cn); Sun Yat-sen University Cancer Center (W.Z., Z.Q., Z.Z., W.J., F.Z.), State Key Laboratory of Oncology in South China, Collaborative Innovation Center for Cancer Medicine, Guangzhou, China; Department of Interventional Radiology (H.Y.), The Third affiliated hospital, Sun Yat-sen University, Guangzhou, China.

*These authors contributed equally to this work.

Received 25 November 2021; revision requested 24 January 2022; last revision received 9 April 2022; accepted 21 April 2022.

Publication date: 1 December 2022.

DOI: 10.5152/dir.2022.211114

The development of intrahepatic arteriovenous shunts is a complication in hepatocellular carcinoma (HCC) patients, ranging between 1.3% and 6.3% in patients with advanced HCC.¹ Because transcatheter arterial chemoembolization (TACE) has been recognized as a choice for palliative local treatment of unresectable and recurring HCC after surgery,^{2,3} the development of arterio-hepatic venous shunts (AHVS) is one of the main impediments and relative contraindications to TACE in patients with advanced HCC. In particular, high-flow AHVS seriously decreases the efficacy of TACE and increases the risk of portal hypertension, gastrointestinal bleeding, liver damage, pulmonary embolism, and lung metastases.⁴⁻⁶ An AHVS also presents a clinical challenge in TACE treatment because anticancer drugs and any embolic materials deployed via an arterial approach to occlude the AHVS can migrate into the lung through the shunt.⁷⁻¹⁰ Therefore, safe, simple, and effective treatment is needed to manage AHVS during TACE. Herein, we developed a transvenous, retrograde embolization of metal coils into the draining hepatic vein combined with TACE to manage HCC with AHVS. In this study, we explored its safety and effectiveness.

You may cite this article as: Zhu W, Qiu Z, Yan H, et al. Retrograde venous coil embolization prior to transarterial chemoembolization in hepatocellular carcinoma with arterio-hepatic venous shunts. *Diagn Interv Radiol.* 2022;28(6):616-620.

Methods

Patients selection

From July 2017 to January 2021, we treated and retrospectively reviewed the outcomes of 6 patients with advanced HCC (4 men and 2 women; mean age, 57 years; range, 40–66 years) who were noted to have a high-flow AHVS by arteriography during a planned TACE treatment. All patients signed informed consent and underwent transvenous, catheter-delivered retrograde embolization with metal coils of the hepatic vein draining the AHVS combined with TACE. The Institutional Review Board approved this study (decision/protocol number, B2020-265).

Diagnosis and evaluation

The diagnostic criteria of HCC followed those of the American Association for the Study of Liver Diseases¹¹ and the European Association for the Study of the Liver.¹² AHVS was defined as direct blood flow between the hepatic artery and the hepatic venous system. Selective hepatic angiogram showed arteriovenous shunting with a filling of inferior vena cava (IVC) and right atrium.

Procedure

A right femoral artery puncture using the Seldinger method was performed. Hepatic angiography was performed using a 5 F Yashiro catheter. After the demonstration of the enhancement of the hepatocellular carcinoma, the AHVS, and the location of the draining hepatic vein, the feeding artery to the hepatocellular carcinoma was first selectively catheterized using a coaxial microcatheter (Progreat). Second, a headhunter catheter was positioned into the draining hepatic vein via the left femoral or

right internal jugular vein. Hepatic venography was used to confirm the draining vein of the AHVS, and the position of the draining vein shown in the hepatic angiography was also used as a reference to confirm the appropriate placement of the transvenous embolization catheter. Appropriately sized coils (length: 8, 10, 12, 14, or 20 cm; and diameter: 8, 10, 14, or 20 mm; Boston Scientific Inc) depending on the size of the fistula were chosen to occlude the distal end of the draining hepatic vein. Then, hepatic angiography was performed again to confirm that the shunt had been completely embolized. If a substantial shunt was still visible, we continued introducing coils into the hepatic vein until the hepatic angiography showed that the AHVS was almost disappeared. Transcatheter arterial chemoembolization was then performed in the same session following embolization. During TACE, we paid close attention to any symptoms of pulmonary embolisms, such as cough and chest tightness. The lung x-rays were performed to observe whether lipiodol was evident in the pulmonary parenchyma when perfusing lipiodol.

Follow-up and evaluation criteria

Intraoperative angiography was performed first to evaluate the completeness of the embolization of the AHVS; the possible outcomes were as follows: complete occlusion (AHVS disappeared) or partial occlusion (the degree of AHVS was decreased or the time to visualization of the AHVS contrast was delayed). The criteria for the technical success of this combined therapeutic procedure were as follows: the shunt through the AHVS was substantially decreased; the lipiodol was deposited in the tumor; the tumor staining was substantially decreased after TACE, and there were no clinical symptoms of pulmonary embolism. The modified response evaluation criteria in solid tumors (m-RECIST) evaluated the tumor response.¹³ Contrast-enhanced computed tomography (CT) of the chest and abdomen was performed 1 month after initial TACE and then once every 3 months. The second TACE was performed if enhanced CT found residual tumor or tumor recurrence. The follow-up period was 6 months. Common adverse reactions were based on common terminology criteria for adverse events version 4.0.3.¹⁴ Complications were classified as major and minor following the

Society of Interventional Radiology reporting standards.¹⁵

Results

The characteristics of the patients are summarized in Table 1. All 6 patients were Barcelona Clinic Liver Cancer stage C. The drainage vein of the AHVS was the right hepatic vein in 1 (17%) patient and the middle hepatic vein in 5 (83%) patients. The serum α -fetoprotein level was >400 ng/mL in 3 patients. The mean maximum diameter of HCC was 6.8 cm (range, 3.0–10.5 cm).

The AVHS was no longer visualized by hepatic angiography immediately after the embolization in all 6 patients, and the rate of complete occlusion was achieved to 100%. The technical success of the embolization was 100% for the treatment of AHVS. All 6 patients received subsequent TACE during the initial procedure. Hepatic angiography confirmed the complete disappearance of the shunt in repeat TACE. Thus, throughout the treatment of these 6 patients, there was no evidence of recanalization of the AHVS.

As defined by the m-RECIST criteria, the disease control rate was 100%. Complete response was present in 2 patients (Figures 1 and 2), and partial response occurred in 4 patients. Five patients survived after 6 months of follow-up, and 1 patient died of upper gastrointestinal hemorrhage.

Postembolization complications were transient fever in 2 patients and post-treatment pain in 4. The symptoms disappeared after symptomatic treatment. There were no significant complications. The levels of alanine aminotransferase (ALT) and aspartate aminotransferase (AST) increased transiently post-procedure but only up to 4 times the normal range and returned to normal with hepatoprotective treatment. Pulmonary embolism, lung tissue damage, and other lung complications related to embolism did not occur. Secondary portal hypertension, such as bleeding from gastric esophageal varices, ascites, and splenomegaly, was not observed after hepatic vein embolization. CT of the liver did not show increased liver and spleen volumes.

Discussion

The formation of AHVS appears to occur due to liver damage,¹⁶ cirrhosis,¹⁷ and tumor invasion of blood vessels;¹⁸ tumor invasion

Main points

- Retrograde permanent coil embolization of artero-hepatic venous shunts (AHVS) via the draining hepatic vein allowed safe delivery of transarterial chemoembolization (TACE) for advanced hepatocellular carcinoma.
- There were no noticeable adverse events, such as pulmonary embolism, post-operative portal hypertension, or liver dysfunction.
- The AHVS did not recanalize in patients, and the overall response rate after TACE is effective.

Table 1. Baseline characteristics and results

Patient	Age, sex	BCLC stage	Tumor location, diameter (cm)	Draining hepatic vein of the AHVS	Coil number, size	Materials	Total disappearance of the shunt	F-U
1	66 Female	C	S7/8,5/6 6 × 8, 2.8 × 2.5	M	4 8 mm × 14 cm	DEB 100-300 μm	Yes	6m+
2	59 Male	C	S5/6/8 6.6 × 6.5, 1 × 1	M	5 8 mm × 14 cm 3 10 mm × 14 cm	Lipiodol 10 mL	Yes	6m+
3	66 Male	C	S7/8,5/6 6.8 × 4.2	M	9 10 mm × 14 cm 4 8 mm × 14 cm	Lipiodol 5 mL	Yes	6m+
4	40 Female	C	S5 4.6 × 3.7	R	4 8 mm × 14 cm	Lipiodol 5 mL	Yes	6m+
5	63 Male	C	S5/6 10.4 × 7.0	M	5 8 mm × 14 cm	Lipiodol 20 mL	Yes	5 m
6	54 Male	C	S3/4 4.0 × 3.0	M	6 8 mm × 14 cm 2 10 mm × 14 cm	Lipiodol 10 mL	Yes	6 m+

BCLC, Barcelona Clinic Liver Cancer; DEB, drug-eluting beads; S, segment; AHVS, arterio-hepatic venous shunt; M, middle hepatic vein; R, right hepatic vein; F-U, follow-up.

of blood vessels is the most common cause of intrahepatic arteriovenous shunts. The formation of these shunts is related primarily to the tumor size, biological characteristics of the hepatic malignancy, and associated vascular invasion.

The AHVS is one of the main impediments and relative contraindications to TACE in patients with advanced HCC, and researchers resolved the paradox by applying different embolic materials or embolizing via arterial or venous. Previous

exploratory research attempted temporary, intrahepatic vein balloon occlusion to prevent pulmonary complications during TACE in patients with HCC and AHVS.¹⁹ Though almost all patients with HCC benefit from a protocol with repeated TACE, it is

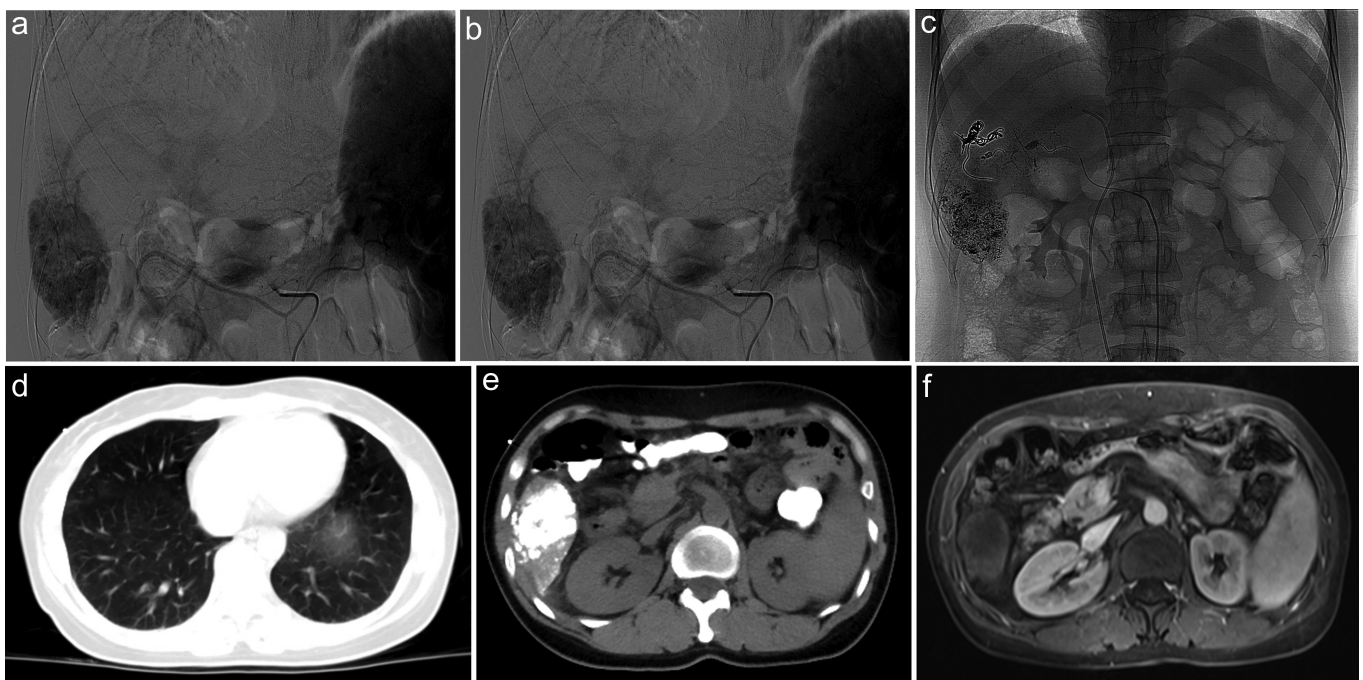


Figure 1. a-f. Images of a 40-year-old woman (patient 4) with hepatocellular carcinoma (HCC) (5.0 cm). Magnetic resonance image (MRI) shows the HCC in segment 5 (arrow) (a). Hepatic arteriography shows tumor staining and the hepatic artery to the middle hepatic vein shunt (AHVS) (b). After completion of transcatheter arterial chemoembolization (TACE), a single spot film shows coils occluding the AHVS and lipiodol deposited in the tumor (c). Two-month follow-up chest computed tomography shows no evidence of pulmonary embolism or lung metastasis, and the lipiodol was taken entirely up only within the tumor (d, e). MRI shows that the tumor has no enhancement (f).

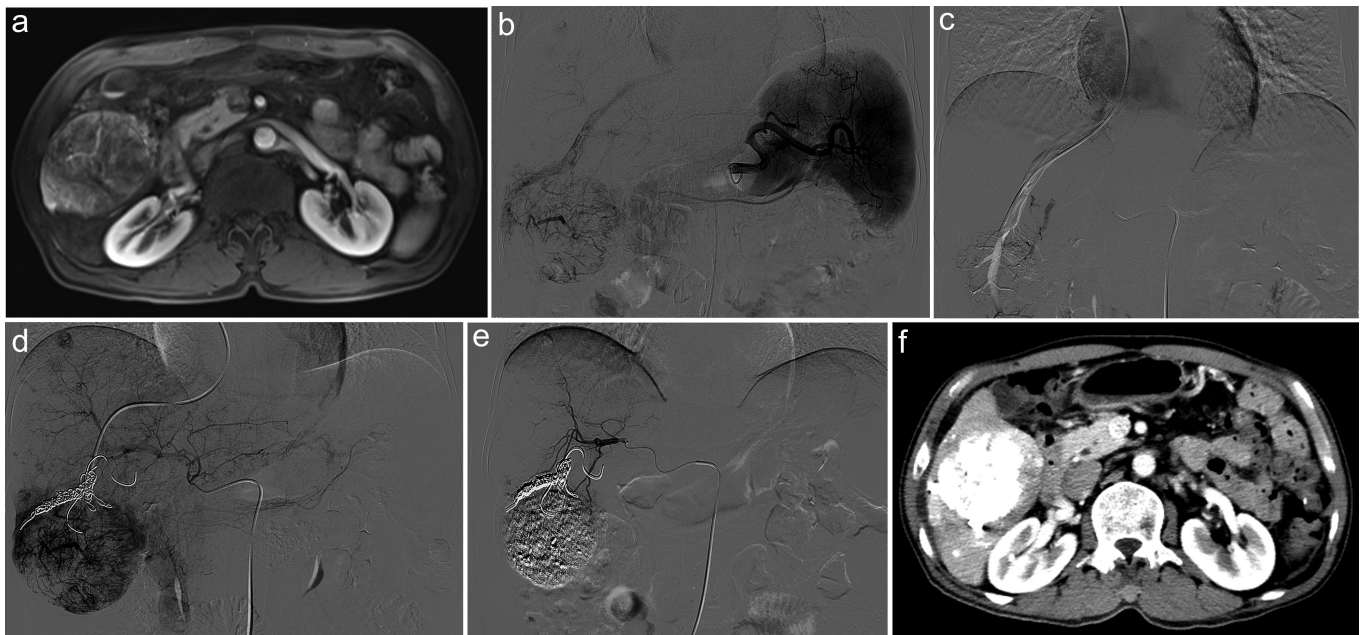


Figure 2. a-f. Images of a 59-year-old man (patient 2) with hepatocellular carcinoma (HCC) (6.6 cm). Magnetic resonance image (MRI) shows the HCC in segments 5 and 6 (a). Hepatic arteriography shows tumor staining and the hepatic artery to the middle hepatic vein shunt (AHVS) (b). Retrograde venography through the middle hepatic vein shows tumor staining (c). Arteriography after coil embolization shows tumor staining, while the AHVS disappeared (d). After transcatheter arterial chemoembolization, hepatic arteriography shows no residual tumor staining and complete occlusion of the AHVS (e). Two-month follow-up computed tomography shows that lipiodol was taken up within the tumor (f).

very inconvenient for the patient to receive transvenous hepatic vein balloon placement repeatedly. Some embolic agents, including coils, gelatin sponges, a combination of coils and gelatin sponges, absolute ethanol, and polyvinyl alcohol, have been trialed through the hepatic artery in patients with high-flow AHVS.¹⁹⁻²¹ However, there is a very high recanalization rate for HCC with high-flow AHVS, and the drug delivery does not reach the end hepatic parenchymal distribution via the arterial vessels that feed the tumor.

Consequently, the overall efficacy of TACE is poor. A thorough terminal embolization appeared to be the key to the clinical efficacy of TACE in these patients. Thus, we propose a treatment strategy to embolize the shunt via permanent retrograde occlusion of the draining hepatic vein. Regardless of the extent of the volume, number, and location of the invasion sites by the tumor of the arterial side of the shunt, the hepatic venous outflow will eventually return to 1 or 2 relatively limited hepatic veins. Through obliterating the venous drainage side of the shunt, the blood flow can be well embolized without damaging the arteries feeding the tumor, which prevents any substantial shunting of arterial supply away from the tumor. In our study, embolism of the AHVS

via the draining hepatic vein achieved 100% technical success, and the AHVS disappeared in 6 patients, which was better than the previous study. Murata and colleagues,¹⁹ using temporary balloon occlusion of the AHVS combined with TACE, reported that the AV shunt disappeared in 7 of 9 patients (78%).

In previous studies, TACE was not considered applicable in patients with an AHVS with high flow. In our study, 100% of the patients received subsequent TACE after occlusion of the AHVS, and the disease control rate was 100%, which was comparable to that previously reported in HCC without any hepatic arteriovenous fistulas.²³ The median survival of our patients was more than 6 months, which is less than the actual overall survival (OS). Except for 1 patient who died, the rest of the patients in our study are still alive until the end of follow-up.

TACE treatment in patients with HCC complicated by an AHVS may increase the post-treatment risk of pulmonary embolism, pulmonary infarction, and even cerebral embolism.²⁴ Furthermore, the histologic toxicity of the chemotherapy drugs may aggravate lung symptoms, such as pulmonary edema, atelectasis, blood pneumothorax, and even respiratory arrest.²⁵ Therefore, traditional TACE is not ideally appropriate

and may even be dangerous for patients with AHVS. In our study, we applied metal coils to retrogradely embolize the draining hepatic vein, and pulmonary embolism was not found in the patients after TACE, which is comparable with Chan's study.²⁶ The mild transient increase in ALT and AST levels (<4× upper limits of normal) was also due to the transient liver damage caused by TACE.

The limitations of this study include the retrospective study design and small sample size. The incidence of pulmonary complications after embolizing the shunt requires a large sample. Also, the incidence of post-procedure portal hypertension and liver dysfunction will need more significant numbers of patients to fully evaluate the potential morbidity of this combined approach of retrograde embolization combined with TACE.

Conclusion

Transvenous permanent embolization of AHVS via the draining hepatic vein appears to be a safe, feasible, and effective treatment. It may provide an opportunity for subsequent TACE for HCC patients with AHVS, leading to better tumor control and preventing pulmonary embolism effectively.

References

1. Murata S, Tajima H, Nakazawa K, Onozawa S, Kumita S, Nomura K. Initial experience of transcatheter arterial chemoembolization during portal vein occlusion for unresectable hepatocellular carcinoma with marked arterioportal shunts. *Eur Radiol.* 2009;19(8):2016-2023. [\[CrossRef\]](#)
2. Takayasu K, Arai S, Ikai I, et al. Prospective cohort study of transarterial chemoembolization for unresectable hepatocellular carcinoma in 8510 patients. *Gastroenterology.* 2006;131(2):461-469. [\[CrossRef\]](#)
3. Lencioni R. Loco-regional treatment of hepatocellular carcinoma. *Hepatology.* 2010;52(2):762-773. [\[CrossRef\]](#)
4. Adler J, Goodgold M, Mitty H, Gordon D, Kinkhabwala M. Arteriovenous shunts involving the liver. *Radiology.* 1978;129(2):315-322. [\[CrossRef\]](#)
5. Ohnishi K, Chin N, Sugita S, et al. Quantitative aspects of portal-systemic and arteriovenous shunts within the liver in cirrhosis. *Gastroenterology.* 1987;93(1):129-134. [\[CrossRef\]](#)
6. Kumar A, Ahuja CK, Vyas S, et al. Hepatic arteriovenous fistulae: role of interventional radiology. *Dig Dis Sci.* 2012;57(10):2703-2712. [\[CrossRef\]](#)
7. Chung JW, Park JH, Im JG, Han JK, Han MC. Pulmonary oil embolism after transcatheter oily chemoembolization of hepatocellular carcinoma. *Radiology.* 1993;187(3):689-693. [\[CrossRef\]](#)
8. Hiraki T, Kanazawa S. Hepatic outflow obstruction created by balloon occlusion of the hepatic vein: induced hepatic hemodynamic changes and the therapeutic applications of hepatic venous occlusion with a balloon catheter in interventional radiology. *Acta Med Okayama.* 2005;59(5):171-178. [\[CrossRef\]](#)
9. Hatamaru K, Azuma S, Akamatsu T, et al. Pulmonary embolism after arterial chemoembolization for hepatocellular carcinoma: an autopsy case report. *World J Gastroenterol.* 2015;21(4):1344-1348. [\[CrossRef\]](#)
10. Xia J, Ren Z, Ye S, et al. Study of severe and rare complications of transarterial chemoembolization (TACE) for liver cancer. *Eur J Radiol.* 2006;59(3):407-412. [\[CrossRef\]](#)
11. Marrero JA, Kulik LM, Sirlin CB, et al. Diagnosis, staging, and management of hepatocellular carcinoma: 2018 practice guidance by the American Association for the Study of Liver Diseases. *Hepatology.* 2018;68(2):723-750. [\[CrossRef\]](#)
12. Vogel A, Cervantes A, Chau I, et al. Correction to: "Hepatocellular carcinoma: ESMO Clinical Practice Guidelines for diagnosis, treatment and follow-up". *Ann Oncol.* 2019;30(5):871-873. [\[CrossRef\]](#)
13. Prajapati HJ, Spivey JR, Hanish SI, et al. mRECIST and EASL responses at early time point by contrast-enhanced dynamic MRI predict survival in patients with unresectable hepatocellular carcinoma (HCC) treated by doxorubicin drug-eluting beads transarterial chemoembolization (DEB TACE). *Ann Oncol.* 2013;24(4):965-973. [\[CrossRef\]](#)
14. Dueck AC, Mendoza TR, Mitchell SA, et al. Validity and reliability of the US National Cancer Institute's patient-reported outcomes version of the common terminology criteria for adverse events (PRO-CTCAE). *JAMA Oncol.* 2015;1(8):1051-1059. [\[CrossRef\]](#)
15. Angle JF, Siddiqi NH, Wallace MJ, et al. Quality improvement guidelines for percutaneous transcatheter embolization: Society of Interventional Radiology Standards of Practice Committee. *J Vasc Interv Radiol.* 2010;21(10):1479-1486. [\[CrossRef\]](#)
16. Si ZM, et al., Combination Therapies in the Management of Large (>= 5 cm) Hepatocellular Carcinoma: Microwave Ablation Immediately Followed by Transarterial Chemoembolization. *J Vasc Interv Radiol.* 2016;27(10):1577-1583.
17. Groszmann RJ, Kravetz D, Parysow O. Intrahepatic arteriovenous shunting in cirrhosis of the liver. *Gastroenterology.* 1977;73(1):201-204. [\[CrossRef\]](#)
18. Cai Z, Ran M, Song J, Zhen W, Li M. Imaging diagnosis and interventional treatment for hepatocellular carcinoma combined with arteriovenous fistula. *J Healthc Eng.* 2021;2021:6651236. [\[CrossRef\]](#)
19. Lee JH, Won JH, Park SI, Won JY, Lee DY, Kang BC. Transcatheter arterial chemoembolization of hepatocellular carcinoma with hepatic arteriovenous shunt after temporary balloon occlusion of hepatic vein. *J Vasc Interv Radiol.* 2007;18(3):377-382. [\[CrossRef\]](#)
20. Abajian A, Murali N, Savic LJ, et al. Predicting treatment response to intra-arterial therapies for hepatocellular carcinoma with the use of supervised machine learning-an artificial intelligence concept. *J Vasc Interv Radiol.* 2018;29(6):850-857.e1. [\[CrossRef\]](#)
21. Zhou WZ, Shi HB, Liu S, et al. Arterioportal shunts in patients with hepatocellular carcinoma treated using ethanol-soaked gelatin sponge: therapeutic effects and prognostic factors. *J Vasc Interv Radiol.* 2015;26(2):223-230. [\[CrossRef\]](#)
22. Murata S, Tajima H, Abe Y, et al. Temporary occlusion of two hepatic veins for chemoembolization of hepatocellular carcinoma with arteriohepatic vein shunts. *AJR Am J Roentgenol.* 2005;184(2):415-417. [\[CrossRef\]](#)
23. Nishikawa H, Kita R, Kimura T, et al. Transcatheter arterial chemoembolization for intermediate-stage hepatocellular carcinoma: clinical outcome and safety in elderly patients. *J Cancer.* 2014;5(7):590-597. [\[CrossRef\]](#)
24. Ishimaru H, Morikawa M, Sakugawa T, et al. Cerebral lipiodol embolism related to a vascular lake during chemoembolization in hepatocellular carcinoma: a case report and review of the literature. *World J Gastroenterol.* 2018;24(37):4291-4296. [\[CrossRef\]](#)
25. Tajima T, Honda H, Kuroiwa T, et al. Pulmonary complications after hepatic artery chemoembolization or infusion via the inferior phrenic artery for primary liver cancer. *J Vasc Interv Radiol.* 2002;13(9 Pt 1):893-900. [\[CrossRef\]](#)
26. Chan WS, Poon WL, Cho DH, Chiu SS, Luk SH. Transcatheter embolisation of intrahepatic arteriovenous shunts in patients with hepatocellular carcinoma. *Hong Kong Med J.* 2010;16(1):48-55.