



Endovascular management of renal angiomyolipomas: Do coils have a benefit in terms of clinical success rates?

Javid Ahmadov

Ferdi Çay

Gonca Eldem

Bülent Akdoğan

Cenk Yücel Bilen

Fazıl Tuncay Aki

Barbaros Erhan Çil

Ali Ergen

Bora Peynircioğlu

PURPOSE

This study evaluated single-center results of endovascular treatment in renal angiomyolipoma (AML) to determine whether there is clinical relevance of adding proximal coil embolization to distal particle embolization in terms of safety, efficacy, and retreatment rates.

METHODS

A retrospective analysis was performed to evaluate patients undergoing transarterial embolization for renal AMLs from January 2007 to October 2020. Parameters regarding patient and tumor characteristics, embolization technique, treatment outcome, and complications were recorded. Patients were divided into 2 groups as A (only particle group) and B (particle + coil group) based on the type of embolic agent used for treatment. Comparative analysis was performed between the 2 groups in terms of tumor size reduction, retreatment, and complication rates.

RESULTS

In this study, 42 patients (37 (88.1%) females and 5 (11.9%) males) harboring 48 AMLs were included. The mean age was 43.46 (range, 20-78). The technical success rate was 95.8% (46 of 48 procedures). The mean size reduction was 1.94 ± 1 cm ($P < .001$) after treatments; however, no significant difference was seen between groups in terms of tumor size reduction. Retreatment rates were 3.1% (1 of 32 cases) in group A and 14.3% (2 of 14 cases) in group B ($P = .21$). No significant difference was found between groups in terms of bleeding and complication rates during the perioperative period. Mean follow-up duration was 26.48 ± 25.71 (range, 2-102) months.

CONCLUSION

In this study, no clear supplementary benefit was observed in terms of safety and efficacy with the adjunction of coils to distal particle embolization in the management of AMLs.

Renal angiomyolipoma (AML) is one of the most common benign tumors of the kidney, with an incidence of 0.4% in the general population.^{1,2} AMLs are seen in 2 forms; sporadic and tuberous sclerosis (TSC) related. Sporadic form accounts for 80% of the AML cases. TSC-related AMLs tend to be bilateral, multifocal, larger with a faster growth rate and are more symptomatic than the sporadic type.³ AMLs have slow growth rates and rarely necessitate invasive treatment at all times.⁴ Historical data suggest that AMLs equal to or larger than 4 cm and those that have 5 mm or larger microaneurysms tend to be more symptomatic and prone to hemorrhage.^{5,6} Although a treatment indication based on tumor size larger than 4 cm is subject to dispute,⁷ treatment decisions are often made using these cut-off values in the literature. Treatment options consist of medical treatment, surgery, transarterial embolization (TAE), and thermal ablation with no definitive recommendation on the first-line treatment choice.^{8,9} However, because of its less-invasive nature, TAE is a favored choice in the management of AMLs over surgery. So far, various embolic agents (ethanol, microparticles, coils, gel foam, etc.) have been used in the management of patients with AML.¹⁰ Concerning the embolic materials, Patatas et al.¹¹ compared solely coil embolization with solely microparticle embolization in transarterial embolization of AMLs. They found similar reduction rates on computed tomography (CT) follow-up between the 2 groups. Ewalt et al.¹² showed that microparticle plus coil embolization is effective in terms of size reduction in large (>4 cm) and symptomatic and TSC-related AMLs. Although based

From the Department of Radiology (J.A., F.Ç., G.E., goncaeldem@gmail.com, B.P.); Department of Urology (B.A., C.Y.B., F.T.A., A.E.), Hacettepe University Hospital, Ankara, Turkey; and Department of Radiology (B.E.Ç.), Koç University Hospital, Istanbul, Turkey.

Received 4 January 2021; revision requested 10 February 2021; last revision received 5 October 2021; accepted 10 October 2021.

Publication date: 1 December 2022.

DOI: 10.5152/dir.2022.201044

You may cite this article as: Ahmadov J, Çay F, Eldem G, et al. Endovascular management of renal AMLs: Do coils have a benefit in terms of clinical success rates? *Diagn Interv Radiol.* 2022;28(6):597-602.

on the literature, coils, microparticles, and microparticle + coil embolization are all safe and efficient, there are no clear data on the additional benefit of adding coil embolization to microparticle embolization in terms of treatment efficacy. Therefore, this study aimed to evaluate within single-center results whether there is clinical relevance of adding proximal coil embolization to distal microparticle embolization in terms of safety, efficacy, and retreatment rates.

Methods

After approval from the institutional review board (decision number: GO 17/717-17), patients undergoing TAE for AML from January 2007 to October 2020 were retrospectively analyzed. Patients without follow-up data were excluded from the study. TAE indications were as follows: tumors ≥ 4 cm in the longest diameter, symptoms of pain and/or hematuria, and tumors with intratumoral or retroperitoneal hemorrhage. Parameters regarding (a) patients' demographics: symptoms, etiology (sporadic/TSC); (b) tumor characteristics: size, presence of intratumoral microaneurysms; (c) endovascular treatment technique: type/size of the embolic agent used; and (d) treatment outcomes and complications were recorded. Pretreatment tumor size was measured from CT and/or magnetic resonance imaging (MRI) images were obtained within 1 month before the procedure. The longest single diameter seen in 3 orthogonal planes (axial, coronal, sagittal) was used for size calculation. Posttreatment tumor size calculation was made from the latest available follow-up imaging from the same image plane that was used for pretreatment evaluation. In patients who underwent TAE with more than 1 session, posttreatment size measurement was

made from the images after completion of all TAE sessions. Intratumoral microaneurysm size was measured from the digital subtraction angiography (DSA) images. In AMLs with multiple intratumoral microaneurysms, the largest microaneurysm was included. Intratumoral microaneurysms were divided into 2 categories as longest diameter ≥ 5 mm in size and < 5 mm in size or no intratumoral microaneurysm. Additionally, patients were divided into 2 groups as A and B based on the type of embolic agent used for treatment: group A represents TAE with only particles and group B represents TAE with particles + coils. Embolic particles were categorized as < 150 μm and > 150 μm in size as previously described in the literature.¹³ Technical success was defined as superselective catheterization of tumor feeders and embolization till flow stasis, with no residual tumor staining in completion angiogram. In very large tumors with multiple feeders to avoid possible renal parenchymal damage with 1 aggressive session and to lower the procedure time and hence the radiation dose, the treatment was staged into more than 1 session. These additional sessions were not deemed in the retreatment rate as they were planned in advance at the beginning of the treatment. On the other hand, if the reintervention decision had been made after a certain follow-up time because of recurrences of symptoms and vascular enhancement, they were deemed to be retreatment. Complications were graded according to Cardiovascular and Interventional Radiological Society of Europe (CIRSE) classification.¹⁴

All procedures were performed by 3 interventional radiologists with 5, 15, and 18 years of experience. After obtaining written informed consent, under conscious sedation and antibiotic prophylaxis

(cefazolin 1 g), femoral artery puncture was performed and a 4 F vascular sheath was inserted. In 1 patient, brachial artery puncture was performed instead of the femoral artery because of significant iliac tortuosity. After vascular sheath insertion, aortography was obtained via a pigtail catheter. After catheterization of the renal artery with a 4 F diagnostic catheter, the arterial feeders contributing to each tumor were superselectively catheterized with a 2.4-2.8 F microcatheter. Superselective angiogram was obtained to assess the tumor and renal parenchyma stain via microcatheter. Embolization was performed with microparticles or microparticles plus coils based on the performing physician's discretion. Detachable coils were used for embolization. Coil embolization was performed after particle embolization and coils were placed in the tumor feeders after passing all branches that supply the normal renal parenchyma. In cases with intratumoral microaneurysms who underwent coil embolization, coils were placed proximally to the microaneurysm formation to minimize manipulation within the abnormal vessel which could cause rupture and retroperitoneal bleeding (Figure 1).

Puncture site hemostasis was achieved via manual compression. All TAE procedures were performed electively except for 2 patients with acute retroperitoneal hemorrhage. In those patients, TAE procedures were performed emergently. If there was no complication after treatment, patients were discharged from the hospital the day after with an outpatient post-procedure regimen of antibiotic.

Patients were tasked to return for a 1-week follow-up visit, for (a) blood analysis for renal function status and (b) for access site evaluation. Clinical follow-up was then

Main points

- Transarterial embolization is safe and effective in reducing lesion size and bleeding rates in the management of angiomyolipomas.
- Lesion size reduction can be achieved with both techniques; solely microparticle embolization or distal microparticle embolization plus proximal coil embolization.
- Proximal coil embolization does not provide an additional benefit with lesions having intratumoral microaneurysms ≥ 5 mm as the study showed no difference in complication and bleeding rates.

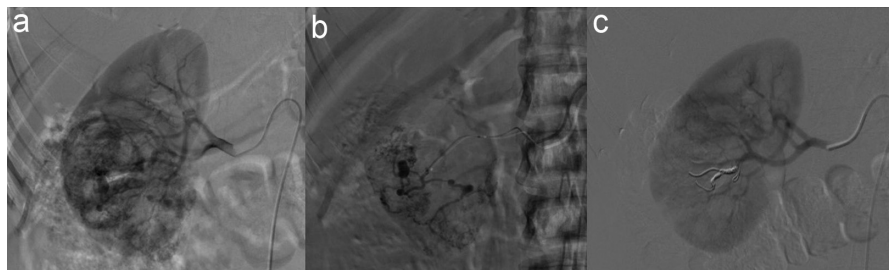


Figure 1. (a) Selective right renal angiography image obtained from main renal artery shows the AML stain with intratumoral microaneurysms at the mid-lower portion of the kidney. (b) Superselective image obtained from the tumoral feeder depicts tumoral stain and intratumoral microaneurysms more clearly. (c) Angiogram obtained after TAE with microparticles + coil shows the absence of the tumoral stain and intratumoral microaneurysms. AML, angiomyolipoma; TAE, transarterial embolization.

done at 3 and 6 months and yearly thereafter. Follow-up imaging (contrast-enhanced CT or MRI) was performed at 3-6 months and annually after that. If the TAE was performed for retroperitoneal hemorrhage related to ruptured AML, imaging was performed at 1 week follow-up.

The Statistical Packages for the Social Sciences 20.0 (IBM Corp) program was used for statistical analysis. Continuous data were presented as mean \pm standard deviation (SD) and categorical data as a percentage. Categorical variables were compared with the use of chi-square test (Fisher exact test if required). Minimum clinically important difference (MCID) was calculated for tumor size reduction with the following formula: $MCID = 1.96 \times \sqrt{2} \times \text{standard error of measurement (SEM)}$.¹⁵ SEM was calculated with the following formula: $SEM = SD \times \sqrt{1 - r}$, where r is reliability coefficient and intraclass correlation coefficient (ICC) was used as the reliability coefficient in this study. $SEM = 3.188 \times \sqrt{1 - 0.972} = 0.533$ and $MCID = 1.96 \times \sqrt{2} \times 0.533 = 1.479$ were calculated in this study. Assessment of corresponding power with the selected MCID was performed in accordance with Yang et al.'s manuscript.¹⁶ Type-1 error level was set to .05. For power analysis, MCID was used as the mean of difference and SD was 3.188. For the given number of the patients, power was calculated as 0.927.

Means of pre- and posttreatment tumor sizes were compared with the use of the Wilcoxon signed-rank test. Means of 2 independent samples were compared with Mann-Whitney U test. Pre- and posttreatment tumor sizes between groups were compared with the use of repeated measures analysis of variance. Statistical significance was set at $P < .05$.

Results

In this study, 42 patients (37 (88.1%) female, 5 (11.9%) male) harboring 48 AMLs were included. All of the AMLs were fat-rich. The mean age was 43.46 ± 15.26 (range, 20-78). Overall, patient and tumor characteristics are summarized in Table 1. Treatment indications were as follows: tumor size in 19 (39.6%) cases, tumor size and pain in 19 (39.6%) cases, tumor size and hematuria in 2 (4.2%) cases, tumor size and intratumoral hemorrhage in 3 (6.3%) cases, tumor size, pain, and intratumoral hemorrhage in 3 (6.3%) cases, and retroperitoneal hemorrhage in 2 (4.2%) cases. Also, in 4 cases, there

Table 1. Overall patient and tumor characteristics

Characteristics	n (%)
Patient number	42 (100)
Female	37 (88.1)
Male	5 (11.9)
Total number of AMLs	48 (100)
TSC-related AMLs	14 (29.2)
Mean of pre-operative tumor size \pm SD (cm)	7.66 ± 3.16
Mean of post-operative tumor size \pm SD (cm)	5.72 ± 2.92
Elective procedures	46 (95.8)

AML, angiomyolipoma; TSC, tuberous sclerosis; SD, standard deviation.

was coexisting hydronephrosis due to the mass effect of the AMLs. The technical success rate was 95.8% (46 of 48 procedures). In 2 cases, superselective catheterization could not be performed because of technical factors; proximal arterial embolization was avoided due to the projected unacceptable loss of normal renal parenchyma. Overall, pre- and posttreatment mean tumor sizes were 7.66 ± 3.16 cm and 5.72 ± 2.92 cm, respectively, and the difference was statistically significant (mean difference, 1.94 ± 1 cm; $P < .001$). Mean follow-up duration was 26.48 ± 25.71 (range, 2-102) months.

In total, 40 patients with 46 AMLs with technical success were included in groups A and B for comparison. No statistically significant difference was observed between

groups A and B based on patients and AML characteristics except for the presence of intratumoral microaneurysm equal or larger than 5 mm. Group B had a higher percentage of cases with intratumoral microaneurysms equal to or larger than 5 mm than in group A ($P = .001$). As a result, tumors containing microaneurysms were more likely to be embolized with coils, in addition to particles by the operators. There were 32 cases (15 with polyvinyl alcohol (PVA) and 17 with trisacryl gelatin microspheres) and 14 cases (6 with PVA + coils and 8 with trisacryl gelatin microsphere + coils) in groups A and B, respectively. Microparticle size range that was used for TAE procedures was 45-1500 μ m for PVA and 100-1200 μ m for trisacryl gelatin microspheres. The type and size of particles that were used were

Table 2. Patients and AMLs characteristics between groups

Characteristics	Group A (%)	Group B (%)	P
Total number	32 (69.6)	14 (30.4)	
Age (mean \pm SD)	43.75 ± 15.77	41.86 ± 13.1	.77
TSC-related AMLs	8 (25)	5 (35.7)	.49
Presence of the symptoms	18 (56.3)	9 (64.3)	.61
Right side tumor	16 (50)	9 (64.3)	.37
Pretreatment hemorrhage (intratumoral or retroperitoneal)*	6 (18.8)	3 (21.4)	1
Intratumoral microaneurysm equal to or larger than 5 mm	10 (31.3)	12 (85.7)	.001
Pretreatment tumor size (mean \pm SD) (cm)	7.34 ± 2.91	8.41 ± 3.69	.46
Particle type			
PVA	15 (46.9)	6 (42.9)	.80
Trisacryl-gelatin microsphere	17 (53.1)	8 (57.1)	
Particle size larger than 150 μ m	19 (59.4)	7 (50)	.55
Follow-up duration (mean \pm SD) (months)	23.22 ± 23.64	33.93 ± 29.48	.13
Retreatment rates	1 (3.1)	2 (14.3)	.21
TAE with more than 1 session	3 (9.4)	4 (28.6)	.17

*There was 1 retroperitoneal hemorrhage for each group.

AML, angiomyolipoma; group A, only particle embolization; group B, particle + coil embolization; SD, standard deviation; TSC, tuberous sclerosis; PVA, polyvinyl alcohol; TAE, transarterial embolization.

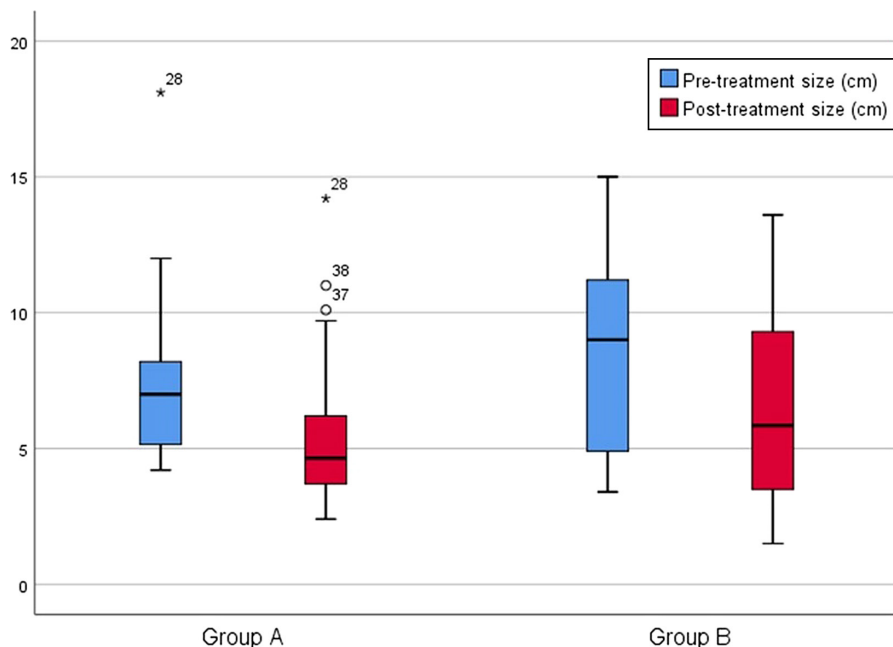


Figure 2. Change of pre- and post-treatment tumor sizes in group A and group B. Tumor size reduction was not significant between groups ($P = .32$).

also similar between groups (Table 2). In group B, the mean size of the tumor feeders embolized with coils was 2.1 ± 0.79 mm (range, 1.2-4.3 mm). Pre- and post-treatment tumor sizes were 7.34 ± 2.91 cm and 5.49 ± 2.65 cm in group A, respectively. Pre- and post-treatment tumor sizes were 8.41 ± 3.69 cm and 6.24 ± 3.53 cm in group B, respectively. Tumor size reduction was significant within the groups when evaluated separately (group A; $P < .001$, group B; $P = .001$); however, no significant difference was found between groups ($P = .32$) (Figure 2).

Seven cases were treated with more than 1 session of TAE (range, 2-4), performed within 1-3 months. Among these, 2 of them underwent radical nephrectomies, one because of coexisting marked hydronephrosis, diffuse involvement of the kidney and renal parenchymal thinning and the other due to suspicion for malignancy. Group B had a higher percentage of cases that underwent TAE with more than 1 session than group A (3 (9.4%) of the 32 cases in group A and 4 (28.6%) of the 14 cases in group B; $P = .17$). During follow-up, 3 cases showed recurrence of pain symptoms and recurrent tumoral enhancement in the entire cohort. Among them, 2 of them were treated with TAE and 1 underwent partial nephrectomy. Retreatment rate was 6.5%, 3 of the 46 cases with technical success. Retreatments were performed at 18, 27, and 30 months. There was no statistically

significant difference based on retreatment rates between group A and group B ($P = .21$).

In the perioperative period (≤ 30 days), postembolization syndrome, as grade 1 complication, had occurred in 20 (62.5%) of 32 cases and in 8 (57.1%) of 14 cases in groups A and B, respectively. There was no significant difference between groups in terms of postembolization syndrome occurrence ($P = .73$). One patient in group A had renal abscess formation, as a grade 3 complication, after TAE. In this patient, there was coexisting hydronephrosis due to the mass effect before the treatment. The patient underwent percutaneous drainage for abscess and double J stent insertion for hydronephrosis. One patient in group B had self-limiting hematuria, as grade 2 complication. All patients' renal function tests remained within normal limits (glomerular filtration rate > 60 mL/min/1.73 m²) except in 2 patients who already had chronic kidney failure before the treatment. There was no bleeding in either group during the perioperative period or follow-up.

Discussion

The current study findings did not show any benefit of additional proximal embolization with coils when treating AMLs with particles in terms of safety and efficacy. The groups were similar regarding the size and type of the particles. Lesion size reduction

rates were significant and in accordance with the literature within groups.^{11,17-19} However, there was no significant difference in the reduction rates between groups. Many studies with different embolic agents (PVA, trisacryl embolic gelatin microsphere, ethanol, n-Butyl cyanoacrylate (n-BCA), gel foam, coils, ethylene vinyl alcohol (onyx), and combinations of them) have been published and showed good results in the management of AML with TAE.¹⁷⁻¹⁹ Although PVA particles and coils are reported more commonly,³ there is no clear evidence of one agent being superior to another.

The vessels of AMLs are abnormal with no internal elastic lamina, making them prone to microaneurysm formation and rupture.²⁰ In this study, group B had a higher percentage of cases with intratumoral microaneurysms equal to or larger than 5 mm than in group A. As a result, performing physicians preferred to occlude these tumor feeders containing microaneurysms with additional coils to exclude the microaneurysms from pressurized arterial system that could cause microaneurysm rupture. This may be of importance when treating, especially, emergency cases with retroperitoneal bleeding. Although the current study contained only 2 emergency cases, other studies have shown the efficacy of using coils and particles together under emergency scenarios.²¹⁻²³

Lenton et al.²⁴ reported 7 cases (30%) with microaneurysm rupture following particle embolization and advocated the use of proximal inflow artery embolization to prevent delayed rupture even in elective cases. Some other studies also favor performing proximal embolization along with distal embolization to reduce the risk of recruitment of new collaterals and exclude the tumor from the pressurized arterial system to prevent delayed rupture and regrowth.^{11,12,19,24} In contrast, Kothary et al.²⁵ reported that coils should be avoided because collaterals can form around the level of the occlusion and also proximal coil embolization could jeopardize further endovascular retreatments in cases of rebleeding or regrowth. Hence, there is an ongoing debate about the use of proximal embolization in the treatment of AMLs.

The present study data showed no clear benefit of coils in opposition, with the results favoring proximal embolization in terms of bleeding. Although group A consisted of 45.5% cases with intratumoral

microaneurysms ≥ 5 mm in size (10 of 22 cases), none of them had bleeding in the perioperative period or during follow-up. On the other hand, no robust collateralization at the site of coils was seen in cases in group B requiring additional sessions in contrast to the authors opposing proximal embolization.

Retreatment rate was 6.5% (3 of the 46 cases) for the entire cohort and is in agreement with the literature.^{3,10} Although it did not reach statistical significance, group B had a higher number of lesions requiring planned additional sessions and also higher retreatment rates. This result cannot be attributed solely to the addition of coils. Although not statistically significant, group B comprised of larger tumors assumedly consisting of multiple tumor feeders, which can explain those higher rates. Also, group B had a higher percentage of TSC-related AMLs, which is a risk factor for recurrence.^{11,25}

The current study found no significant difference between groups based on post embolization syndrome occurrence in the perioperative period. The findings are consistent with the study findings by Schwartz et al.¹⁸ who reported no difference in post embolization syndrome regarding the type of the embolizing agent. One patient with coexisting hydronephrosis was complicated with abscess formation after TAE in group A in the perioperative period. It would have been preferable to perform urinary diversion before TAE as, intuitively, stagnant urine could be a risk factor for bacterial growth. In group B, other than post embolization syndrome, self-limiting hematuria was seen in 1 patient as a perioperative complication.

When treating lesions with PVA or trisacryl microspheres, avoiding non-target embolization should be one of the concerns. Non-target embolization can result in fatal pulmonary embolization or even brain ischemia if a patient has a patent foramen ovale.²⁶ Cases of fatal pulmonary embolization with PVA and trisacryl microspheres have been described with hepatic and uterine embolization.^{26,27} Therefore, before injecting particles, selective angiograms should be obtained and the images should be checked for early venous fillings and also for the size of abnormal vessels although arteriovenous fistula is not a prominent feature of AMLs. Small sizes that would allow passage to the systemic circulation should be avoided. In the current

study, small-sized particles (<150 μm) were used only in lesions with small vasculature after obtaining selective injections. Non-target embolization was not seen in any of the study cohort. It should also be noted that Villata et al.¹³ found higher retreatment rates with smaller (<150 μm) particles and advised not to use them to avoid pulmonary complications.

Another agent that can be used when in concern of high flow communications or direct AV fistula is Onyx. Studies with Onyx advocate proximal embolization of the tumor feeders instead of coils. In this case, both distal vascular bed embolization and embolization of proximal feeders are achieved.^{19,21} No hemorrhage was reported during follow-up in these studies as well.

Ethanol is an alternative sclerosing agent causing endothelial injury. The inflammatory reaction triggered by the endothelial injury results in vascular thrombosis. Usually, it is delivered as a mixture with lipiodol with or without the use of a balloon catheter. However, there are also centers preferring to use ethanol alone. The advantages of ethanol-lipiodol embolization are: that it provides distal penetration at the capillary level along with thrombosis of the proximal feeders of the lesions. It also obviates the need for conventional iodinated contrast agent use. The need for general anesthesia and pulmonary artery pressure monitoring are the disadvantages of ethanol when used in large amounts as large amounts of bolus injection cause elevation of the pulmonary pressure due to precapillary spasm leading to hemodynamic collapse. However, large maximally recommended doses are hardly ever reached in AML embolization. Very slow injection rates and small volumes obviate the need for general anesthesia and pulmonary artery pressure monitoring. The maximum injection rate should be 0.1 mg/kg every 10 min without exceeding a total dose of 0.5 mg/kg.^{25,28-31}

This study data suggested that solely distal particle embolization suffices to prevent bleeding in AMLs. Also, avoiding coil embolization would have a benefit on radiation dose and cost and eliminate the potential risk of hindering endovascular selective catheterization in case of retreatment.

The study's limitations are its retrospective design with a long inclusion period, the relatively small sample size,

non-standardized embolization technique, and relatively short and incomplete follow-up time. No specific indications for the use of proximal embolization with coils were defined, and the decision was made by the performing physician's discretion.

Transarterial embolization of AMLs is a well-supported, safe and effective treatment option providing reduction in lesion size and preventing hemorrhage, and growing number of centers prefer TAE over surgery as first-line treatment. Although further prospective randomized studies are needed to show superiority between different embolic agents, adding proximal embolization with coils to distal particle embolization showed no clear benefit in terms of safety and efficacy in this study.

Conflict of interest disclosure

The authors declared no conflict of interest.

References

1. Park BK. Renal angiomyolipoma: radiologic classification and imaging features according to the amount of fat. *AJR Am J Roentgenol*. 2017;209(4):826-835. [\[CrossRef\]](#)
2. Fittschen A, Wendlik I, Oetzuerk S, et al. Prevalence of sporadic renal angiomyolipoma: a retrospective analysis of 61,389 in-and outpatients. *Abdom Imaging*. 2014;39(5):1009-1013. [\[CrossRef\]](#)
3. Fernández-Pello S, Hora M, Kuusk T, et al. Management of sporadic renal angiomyolipomas: a systematic review of available evidence to guide recommendations from the European Association of Urology Renal Cell Carcinoma Guidelines Panel. *Eur Urol Oncol*. 2020;3(1):57-72. [\[CrossRef\]](#)
4. Mues AC, Palacios JM, Haramis G, et al. Contemporary experience in the management of angiomyolipoma. *J Endourol*. 2010;24(11):1883-1886. [\[CrossRef\]](#)
5. Oesterling JE, Fishman EK, Goldman SM, Marshall FF. The management of renal angiomyolipoma. *J Urol*. 1986;135(6):1121-1124. [\[CrossRef\]](#)
6. Yamakado K, Tanaka N, Nakagawa T, Kobayashi S, Yanagawa M, Takeda K. Renal angiomyolipoma: relationships between tumor size, aneurysm formation, and rupture. *Radiology*. 2002;225(1):78-82. [\[CrossRef\]](#)
7. Chan KE, Chedgy E, Bent CL, Turner KJ. Surveillance imaging for sporadic renal angiomyolipoma less than 40 mm: lessons learnt and recommendations from the experience of a large district general hospital. *Ann R Coll Surg Engl*. 2018;100(6):480-484. [\[CrossRef\]](#)
8. Kiefer RM, Stavropoulos SW. The role of interventional radiology techniques in the management of renal angiomyolipomas. *Curr Urol Rep*. 2017;18(5):36. [\[CrossRef\]](#)

9. Rabenou RA, Charles HW. Differentiation of sporadic versus tuberous sclerosis complex-associated angiomyolipoma. *AJR Am J Roentgenol.* 2015;205(2):292-301. [\[CrossRef\]](#)
10. Murray TE, Doyle F, Lee M. Transarterial embolization of angiomyolipoma: a systematic review. *J Urol.* 2015;194(3):635-639. [\[CrossRef\]](#)
11. Patatas K, Robinson GJ, Ettles DF, Lakshminarayan R. Patterns of renal angiomyolipoma regression post embolisation on medium-to long-term follow-up. *Br J Radiol.* 2013;86(1024):20120633. [\[CrossRef\]](#)
12. Ewalt DH, Diamond N, Rees C, et al. Long-term outcome of transcatheter embolization of renal angiomyolipomas due to tuberous sclerosis complex. *J Urol.* 2005;174(5):1764-1766. [\[CrossRef\]](#)
13. Villalta JD, Sorensen MD, Durack JC, Kerlan RK, Stoller ML. Selective arterial embolization of angiomyolipomas: a comparison of smaller and larger embolic agents. *J Urol.* 2011;186(3):921-927. [\[CrossRef\]](#)
14. Filippiadis DK, Binkert C, Pellerin O, Hoffmann RT, Krajina A, Pereira PL. Cirse quality assurance document and standards for classification of complications: the cirse classification system. *Cardiovasc Intervent Radiol.* 2017;40(8):1141-1146. [\[CrossRef\]](#)
15. Haugan G, Drageset J, André B, Kukulu K, Mugisha J, Utvær BKS. Assessing quality of life in older adults: psychometric properties of the OPQoL-brief questionnaire in a nursing home population. *Health Qual Life Outcomes.* 2020;18(1):1. [\[CrossRef\]](#)
16. Yang S, Berdine G. Minimal clinically important difference. *The Chronicles.* 2021;9(39):73-75. [\[CrossRef\]](#)
17. Anis O, Rimon U, Ramon J, et al. Selective arterial embolization for large or symptomatic renal angiomyolipoma: 10 years of follow-up. *Urology.* 2020;135:82-87. [\[CrossRef\]](#)
18. Schwartz MJ, Smith EB, Trost DW, Vaughan Jr ED. Renal artery embolization: clinical indications and experience from over 100 cases. *BJU Int.* 2007;99(4):881-886. [\[CrossRef\]](#)
19. Thulasidasan N, Sriskandakumar S, Ilyas S, Sabharwal T. Renal angiomyolipoma: mid-to long-term results following embolization with onyx. *Cardiovasc Intervent Radiol.* 2016;39(12):1759-1764. [\[CrossRef\]](#)
20. Eble JN. Angiomyolipoma of kidney. *Semin Diagn Pathol.* 1998;15(1):21-40.
21. Urbano J, Paul L, Cabrera M, Alonso-Burgos A, Gómez D. Elective and emergency renal angiomyolipoma embolization with ethylene vinyl alcohol copolymer: feasibility and initial experience. *J Vasc Interv Radiol.* 2017;28(6):832-839. [\[CrossRef\]](#)
22. Chatziioannou A, Gargas D, Malagari K, et al. Transcatheter arterial embolization as therapy of renal angiomyolipomas: the evolution in 15 years of experience. *Eur J Radiol.* 2012;81(9):2308-2312. [\[CrossRef\]](#)
23. Hocquelet A, Cornelis F, Le Bras Y, et al. Long-term results of preventive embolization of renal angiomyolipomas: evaluation of predictive factors of volume decrease. *Eur Radiol.* 2014;24(8):1785-1793. [\[CrossRef\]](#)
24. Lenton J, Kessel D, Watkinson AF. Embolization of renal angiomyolipoma: immediate complications and long-term outcomes. *Clin Radiol.* 2008;63(8):864-870. [\[CrossRef\]](#)
25. Kothary N, Soulen MC, Clark TW, et al. Renal angiomyolipoma: long-term results after arterial embolization. *J Vasc Interv Radiol.* 2005;16(1):45-50. [\[CrossRef\]](#)
26. Fatal nontarget embolization via an intrafibroid arterial venous fistula during uterine fibroid embolization. *J Vasc Interv Radiol.* 2009;20(3):419-420. [\[CrossRef\]](#)
27. Brown KT. Fatal pulmonary complications after arterial embolization with 40-120- μ m tris-acryl gelatin microspheres. *J Vasc Interv Radiol.* 2004;15(2 Pt 1):197-200. [\[CrossRef\]](#)
28. Lee S, Park HS, Hyun D, et al. Radiologic and clinical results of transarterial ethanol embolization for renal angiomyolipoma. *Eur Radiol.* 2021;31(9):6568-6577. [\[CrossRef\]](#)
29. Shin BS, Do YS, Cho HS, et al. Effects of repeat bolus ethanol injections on cardiopulmonary hemodynamic changes during embolotherapy of arteriovenous malformations of the extremities. *J Vasc Interv Radiol.* 2010;21(1):81-89. [\[CrossRef\]](#)
30. Ko JS, Kim JA, Do YS, et al. Prediction of the effect of injected ethanol on pulmonary arterial pressure during sclerotherapy of arteriovenous malformations: relationship with dose of ethanol. *J Vasc Interv Radiol.* 2009;20(1):39-45. [\[CrossRef\]](#)
31. Ko SE, Do YS, Park KB, et al. Subclassification and treatment results of ethanol embolotherapy of Type II arteriovenous malformations of the extremity and body. *J Vasc Interv Radiol.* 2019;30(9):1443-1451. [\[CrossRef\]](#)