

CT colonography has low sensitivity but high specificity in the detection of internal hemorrhoids

Lukas Lambert 

Jiri Jahoda 

Gabriela Grusova 

Pavel Hrabak 

Ales Novotny 

Andrea Burgetova 

PURPOSE

We aimed to evaluate the diagnostic performance of computed tomography colonography (CTC) in the detection of internal hemorrhoids.

METHODS

Three gastroenterologists systematically reported on the presence of internal hemorrhoids in patients with incomplete colonoscopy, for whom they considered a subsequent CTC. For 44 patients with internal hemorrhoids revealed by optical colonoscopy, an age- and gender-matched cohort of 66 patients with normal findings in the rectum was selected. Endoluminal and transaxial CTC views of the rectum were evaluated for the presence of internal hemorrhoids, the anal verge prominence, asymmetry, and cushion-like appearance on a Likert scale by two experienced radiologists and two gastroenterologists.

RESULTS

The sensitivity, specificity, and AUC for identification of internal hemorrhoids were 0.61 (95% CI, 0.53–0.68), 0.69 (95% CI, 0.63–0.75) and 0.66 (95% CI, 0.62–0.70), respectively. The radiologists showed a better specificity, the gastroenterologists a slightly better sensitivity. When only the rating “very likely” was considered as positive, the specificity rose to 0.89 (95% CI, 0.81–0.94) with a sensitivity of 0.50 (95% CI, 0.38–0.62). The interobserver agreement was fair. The best predictor of the presence of hemorrhoids was a prominent anal verge in the supine position (OR=1.789, 95% CI, 1.267–2.525). The difference between supine and prone positions in the evaluated features in patients with internal hemorrhoids was not significant.

CONCLUSION

CTC has low sensitivity but high specificity in the detection of internal hemorrhoids, if the rater is confident in detecting them. Internal hemorrhoids do not substantially change their shape between prone and supine positions.

In the detection of colonic neoplasms, computed tomography colonography (CTC) has diagnostic performance comparable to optical colonoscopy (OC) (1). However, difficult imaging and recognition of low rectal lesions including hemorrhoids, varices, anal papillae, low rectal polyps and tumors, or fecal residue are among the CTC limitations and pitfalls (2–4). Hemorrhoids are vascular submucosal cushions that assist in sealing the anal canal (5). They are classified as internal (above the dentate line), external (below the dentate line), and mixed. Internal hemorrhoids are a common condition at screening age (6, 7). Unless thrombosed, they are difficult to palpate on digital rectal examination. Internal hemorrhoids may present with rectal bleeding, itching, or pain that require further assessment to exclude neoplasm (7, 8).

Advanced internal hemorrhoids appear on endoluminal view as cushion-like low-lying bullous protrusions arising semi-circumferentially around the rectal tube when its balloon is deflated (2). Internal hemorrhoids may change shape or disappear with different patient position and enhance after intravenous injection of contrast material (2, 3). Occasionally internal hemorrhoids may be identified by computer-aided detection as polyp candidates (4). Although internal hemorrhoids are common and their appearance on CTC has been described, the diagnostic performance of CTC in detecting them has not been explored yet.

From the Departments of Radiology (L.L. ✉ lambert.lukas@gmail.com, J.J., A.B.) and the Fourth Department of Medicine (G.G., P.H., A.N.), First Faculty of Medicine Charles University and General University Hospital in Prague, Prague, Czech Republic.

Received 22 February 2019; revision requested 02 April 2019; last revision received 19 July 2019; accepted 02 August 2019.

DOI 10.5152/dir.2019.19098

You may cite this article as: Lambert L, Jahoda J, Grusova G, Hrabak P, Novotny A, Burgetova A. CT colonography has low sensitivity but high specificity in the detection of internal hemorrhoids. *Diagn Interv Radiol* 2020; 26:82–86.

The aim of this prospective study was to evaluate the diagnostic performance of CTC in detecting internal hemorrhoids compared with OC and assess the interobserver agreement.

Methods

This study was performed in accordance with the Declaration of Helsinki, and it was approved by the institutional Ethics Committee (1/16 S-IV). All patients signed the informed consent.

Between March 2016 and May 2018, three gastroenterologists from the institution were requested to make a note in their report on the presence of internal hemorrhoids in patients with incomplete colonoscopy, for whom they considered a subsequent CTC. The CTC was mostly performed on the same day as OC. From the cohort of 249 subjects, patients with a previous surgical or endoscopic procedure in the low rectum (n=7) were not considered for the study. Patients with insufficient visualization of the rectal floor (poor distension, intraluminal content) on CTC (n=9) were also excluded. For the 44 patients in which internal hemorrhoids were reported on OC, an age- and gender-matched cohort of 66 patients with normal findings in the rectum on OC was selected. The patients were 66±13 years old (mean±standard deviation) and 34 (30.91%) were males.

CTC was performed in patients with cleansed colon and stool tagging. The colon was distended with CO₂ delivered by automated insufflation (PROTOCO2L Touch, Bracco Diagnostics Inc.) via a balloonless rectal tube with a target pressure of 25 mmHg. CT was performed in supine and prone positions on a 256-slice scanner (Brilliance iCT 256; Philips Healthcare) with a peak voltage of 120 kV and planned tube-time current of 15 mAs as a breath-hold low-dose unenhanced acquisition (9, 10).

The images were reconstructed in 0.9 mm slices with soft tissue filter (A) and iterative reconstruction (iDOSE4). For each patient, images containing the endoluminal and transaxial views of the anal verge in both positions were created for later analysis. Four independent raters, two radiologists with experience in CTC and two gastroenterologists (different from those who performed the OC) with experience in OC but blinded to the OC result, were asked to evaluate the images in a random order for the presence of internal hemorrhoids on a five-point Likert scale (very unlikely, rather unlikely, undecided, rather likely, very likely) and presence of the anal verge prominence, asymmetry, and cushion-like appearance on a three-point scale (absent, visible, conspicuous) in both positions.

Statistical analysis

Statistical tests were performed in SPSS 19 (IBM Corp.). To test for statistical significance, the Mann-Whitney U test and the Wilcoxon signed rank test was used. Receiver operating characteristics (ROC) analysis for the detection of internal hemorrhoids on CTC was performed for all raters altogether and for the two specialties (radiologists and gastroenterologists) separately; the 95% confidence intervals (95% CI) were calculated using the binomial exact method. Multivariate analysis was performed

using binary logistic regression model with forward stepwise (likelihood ratio) method. Intraobserver agreement was expressed by the kappa coefficient (κ). Scores were presented as median and range (minimum to maximum). Specificity, sensitivity, and agreement were expressed as values with their 95% confidence intervals (95% CI). A *P* value <0.05 was considered significant.

Results

The difference between patients with and without internal hemorrhoids on OC was significant in all the evaluated morphological features (Table 1). The overall sensitivity, specificity, and area under the curve (AUC) for identification of internal hemorrhoids were 0.61 (95% CI, 0.53–0.68), 0.69 (95% CI, 0.63–0.75) and 0.66 (95% CI, 0.62–0.70), respectively. The specificity was better for the radiologists (0.79; 95% CI, 0.71–0.86) compared with the gastroenterologists (0.59; 95% CI, 0.49–0.68) and the sensitivity was slightly better for the gastroenterologists (0.64; 95% CI, 0.53–0.74) compared with the radiologists (0.58 [95% CI, 0.46–0.69], Fig. 1). The difference in AUC between gastroenterologists (AUC=0.639; 95% CI, 0.572–0.702) and radiologists (AUC=0.696; 95% CI, 0.631–0.756) was not significant (*P* = 0.0879). In case where only the rating “very likely” was considered as positive, the overall specificity rose to 0.89 (95% CI, 0.81–0.94) with a sen-

Table 1. Median scores for morphological features of the anal verge and overall impression in the supine and prone positions on CTC grouped by the presence or absence of internal hemorrhoids on optical colonoscopy

	Internal hemorrhoids on OC		<i>P</i>
	Absent n=66 Median (min–max)	Present n=44 Median (min–max)	
Anal verge prominence (scale 1–3)			
Supine	1.25 (1.00–2.50)	2.00 (1.00–3.00)	<0.001
Prone	1.50 (1.00–2.75)	2.00 (1.00–3.00)	0.003
Anal verge asymmetry (scale 1–3)			
Supine	1.25 (1.00–2.50)	1.75 (1.00–2.75)	<0.001
Prone	1.50 (1.00–2.50)	2.00 (1.00–3.00)	<0.001
Cushion-like appearance (scale 1–3)			
Supine	1.25 (1.00–2.75)	2.00 (1.00–3.00)	<0.001
Prone	1.25 (1.00–2.75)	1.75 (1.00–3.00)	<0.001
Presence of hemorrhoids on CTC (scale 1–5)			
Supine	2.00 (1.00–4.25)	3.50 (1.00–5.00)	<0.001
Prone	2.00 (1.00–4.50)	3.00 (1.00–5.00)	<0.001

OC, optical colonoscopy; CTC, computed tomography colonography.
P values were calculated by the Mann-Whitney U test.

Main points

- CT colonography has low sensitivity but high specificity in the detection of internal hemorrhoids, if the reader is confident in seeing them.
- Internal hemorrhoids do not substantially change their shape between prone and supine positions.
- The best predictor of the presence of hemorrhoids was a prominent anal verge in the supine position.

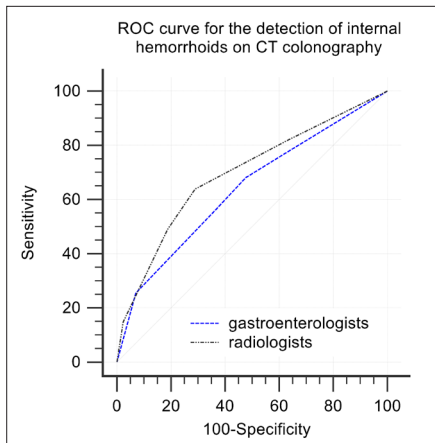


Figure 1. Receiver-operator characteristic (ROC) curve for the assessment of internal hemorrhoids on computed tomography colonography (CTC) on a five-point Likert scale (very unlikely, rather unlikely, undecided, rather likely, very likely) plotted for the gastroenterologists (AUC=0.639; 95% CI, 0.572–0.702) and radiologists (AUC=0.696; 95% CI, 0.631–0.756) separately ($P = 0.0879$).

sitivity of 0.50 (95% CI, 0.38–0.62). From the other evaluated parameters, confident identification of anal verge prominence, anal verge asymmetry, or cushion-like appearance in any of the imaged positions yielded a specificity of 0.86 (95% CI, 0.80–0.90), 0.91 (95% CI, 0.87–0.95), or 0.86 (95% CI, 0.81–0.91) with a sensitivity of 0.47 (95% CI, 0.39–0.56), 0.37 (95% CI, 0.29–0.46) or 0.39 (95% CI, 0.31–0.47, Fig. 2), respectively. The agreement between the raters in the assessment of the presence of hemorrhoids was $\kappa=0.52$ ($P < 0.0001$). The difference between the supine and prone positions in the anal verge prominence, asymmetry, or cushion-like appearance in patients with internal hemorrhoids confirmed by OC was not significant (Table 2, Fig. 3). According to binary logistic regression, the best predictor for the presence of hemorrhoids was a prominent anal verge in the supine position (Odds ratio [OR]=1.789) together with anal verge asymmetry in the prone position (OR=1.537) and cushion-like appearance in the supine position (OR=1.481) with a model significance of $P < 0.0001$ (Table 3).

Discussion

Our study has shown that the assessment of hemorrhoids on CTC is difficult, with low sensitivity but high specificity if the rater is confident in detecting them, and that other analyzed features also have high specificity but low sensitivity. Radiologists show a slightly better specificity than gastroenter-

Table 2. Comparison of median scores for the anal verge prominence, asymmetry, or cushion-like appearance between supine and prone positions in patients with hemorrhoids confirmed by optical colonoscopy

Feature	Supine n=44 Median (min–max)	Prone n=44 Median (min–max)	P
Anal verge prominence (scale 1–3)	2.00 (1.00–3.00)	2.00 (1.00–3.00)	0.203
Anal verge asymmetry (scale 1–3)	1.75 (1.00–2.75)	2.00 (1.00–3.00)	0.092
Cushion-like appearance (scale 1–3)	2.00 (1.00–3.00)	1.75 (1.00–3.00)	0.683

P values were calculated by the Wilcoxon signed rank test.

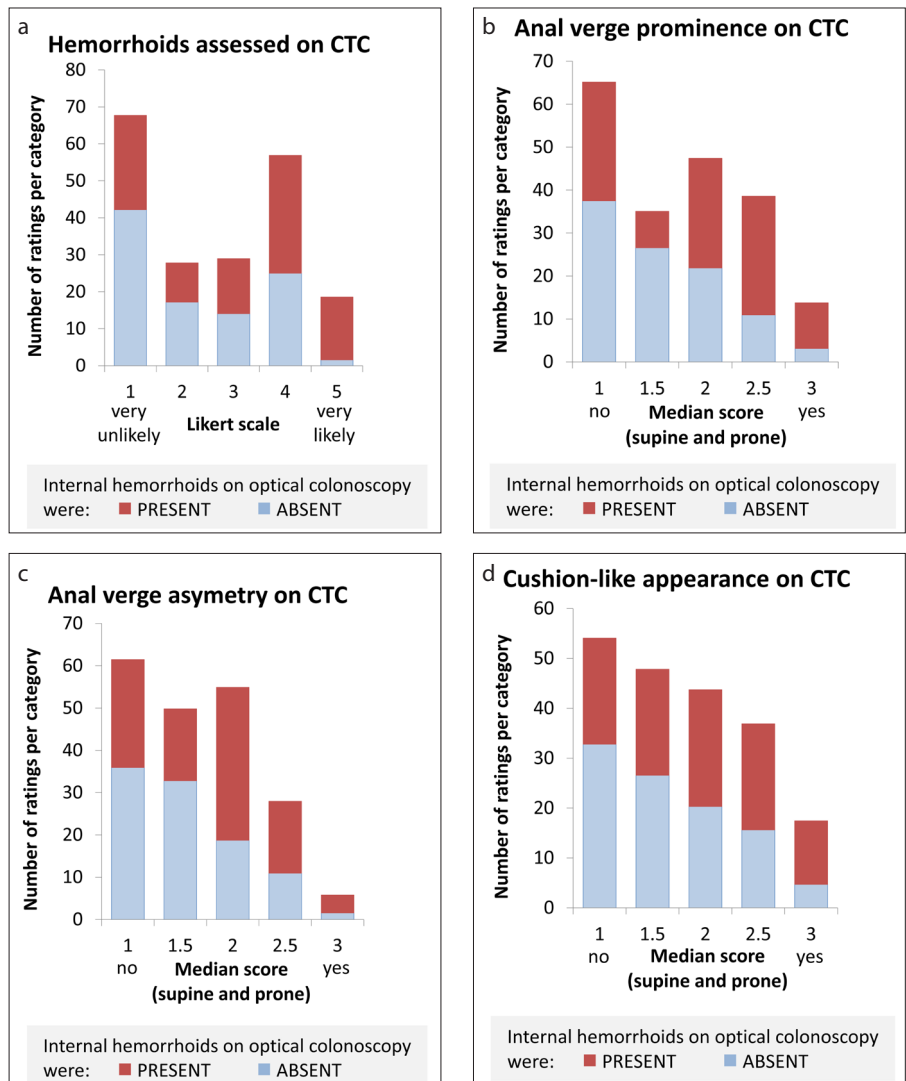


Figure 2. a–d. Assessment of internal hemorrhoids on CTC on a five-point Likert scale shows that a “very likely” rating is most likely to be true (a). Other assessed features, anal verge prominence (b) and asymmetry (c), or cushion-like appearance (d) ratings are shown as median scores (supine and prone) on a three-point Likert scale (absent, visible, conspicuous). Patients with internal hemorrhoids confirmed by optical colonoscopy are shown in red color.

ologists and overall interobserver agreement is fair.

To our best knowledge, this is the first study to assess the diagnostic performance of CTC in the detection of internal hemorrhoids. We have not found any previous

studies on CTC to compare our results with. On barium enema, the appearance of hemorrhoids has been previously evaluated (11). Although Levine et al. (11) confirmed low sensitivity and specificity of barium enema due to overlap with low rectal neo-

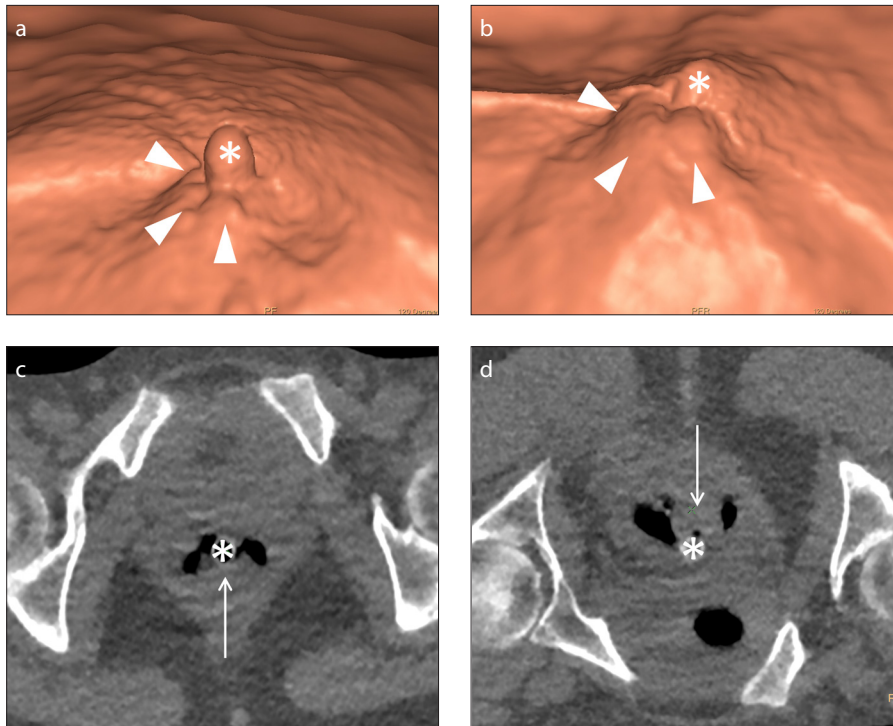


Figure 3. a–d. Internal hemorrhoids shown on endoluminal (a, b) and cross-sectional (c, d) views on CTC in the supine (a, c) and prone (b, d) position. Endoluminal views (a, b) show the prominence and asymmetry of the anal verge (arrowheads). The cushion-like appearance of the prominent anal verge (arrow) is best depicted on the cross-sectional image (c, d). An asterisk marks the balloonless rectal tube.

plasms and proctitis; they reported that the appearance of multiple submucosal nodules yielded a sensitivity of 77%. They also suggested that lobulated folds representing hemorrhoids usually did not extend 3 cm beyond the anal verge.

Apart from the overall impression of both the endoluminal and cross-sectional views, we separately assessed three other parameters, the anal verge prominence, asymmetry, and a cushion-like appearance that showed comparable low sensitivity and high specificity. The choice of the anal verge prominence and asymmetry was based on the common appearance of internal hemorrhoids. The cushion-like appearance was based on the assumption that the rectal tube would indent the prominent nodules, because unless thrombosed, they would mostly be compliant.

In a broader sense, gastroenterologists and radiologists have a similar perception of the appearance of internal hemorrhoids. Slightly better specificity in radiologists can be explained by their better familiarity with two-dimensional images and with endoluminal views that do not contain information about color changes of the mucosa. Another disadvantage of CTC that contributes to

its low sensitivity is that insufflation target pressure of 25 mmHg is higher than that of the venous system and this, in turn, leads to the collapse of internal hemorrhoids during CTC (12, 13). Contrary to current knowledge, we found no evidence that internal hemorrhoids change their shape between supine and prone positions.

Internal hemorrhoids are difficult to detect by digital rectal examination unless they are thrombosed (7). This feature makes them distinguishable from other low-lying rectal lesions including cancer. Anal papillae are pyramidal protrusions arising from the dentate line in a spoke wheel arrangement (2). When hypertrophied, they assume the shape of a fibroepithelial polyp, which is firm on palpation (14). These polyps are usually small and solitary (15). Internal hemorrhoids may also be incidentally depicted by routine abdominal CT examination by their contrast enhancement, MRI of the rectum, or by transanal ultrasound with power Doppler (16).

This study has several limitations. First, the CTC examinations were performed without contrast enhancement and therefore venous phase enhancement of internal hemorrhoids could not be assessed. Sec-

ond, we commonly use a balloonless rectal catheter, while some institutions prefer a balloon catheter which should be deflated before the second acquisition (17). Third, this study did not assess the interobserver agreement of the OC, the gold standard. Fourth, CTC can visualize only internal hemorrhoids that bulge from the rectal floor; hemorrhoids in the anus or protruding hemorrhoids cannot be assessed. Lastly, on CTC there is an overlap in the appearance of internal hemorrhoids and other low-lying rectal lesions including polyps or a mass that were not studied.

In conclusion, the assessment of hemorrhoids on CTC is difficult, with low sensitivity but high specificity if the rater is confident in detecting them. Other features including prominence, asymmetry, or cushion-like appearance also have high specificity but low sensitivity. Radiologists show a better specificity than gastroenterologists and overall interobserver agreement is fair.

Funding disclosure

This work was supported by the Charles University in Prague (Progres Q28/LF1, UNCE 204065).

Acknowledgments

The authors thank the gastroenterologists from the Fourth Department of Medicine for performing optical colonoscopies and consistent reporting on the presence or absence of internal hemorrhoids.

Conflict of interest disclosure

The authors declared no conflicts of interest.

References

- Pickhardt PJ, Hassan C, Halligan S, Marmo R. Colorectal cancer: CT colonography and colonoscopy for detection - systematic review and meta-analysis. *Radiology* 2011; 259:393–405. [CrossRef]
- Pickhardt PJ, Kim DH. CT colonography: pitfalls in interpretation. *Radiol Clin North Am* 2013; 51:69–88. [CrossRef]
- Silva AC, Vens EA, Hara AK, Fletcher JG, Fidler JL, Johnson CD. Evaluation of benign and malignant rectal lesions with CT colonography and endoscopic correlation. *Radiographics* 2006; 26:1085–1099. [CrossRef]
- Trilisky I, Dachman AH, Wroblewski K, Vannier MW, Horne JM. CT colonography with computer-aided detection: recognizing the causes of false-positive reader results. *Radiographics* 2014; 34:1885–1905. [CrossRef]
- Raman SP, Horton KM, Fishman EK. MDCT and CT angiography evaluation of rectal bleeding: the role of volume visualization. *AJR Am J Roentgenol* 2013; 201:589–597. [CrossRef]
- Riss S, Weiser FA, Schwameis K, et al. The prevalence of hemorrhoids in adults. *Int J Colorectal Dis* 2012; 27:215–220. [CrossRef]
- Schubert MC, Sridhar S, Schade RR, Wexner SD. What every gastroenterologist needs to know about common anorectal disorders. *World J Gastroenterol* 2009; 15:3201–3209. [CrossRef]

8. Hock D, Materne R, Ouhadi R, Mancini I, Aouachria SA, Nchimi A. Test-positive rate at CT colonography is increased by rectal bleeding and/or unexplained weight loss, unlike other common gastrointestinal symptoms. *Eur J Radiol Open* 2015; 2:32–38. [\[CrossRef\]](#)
9. Lambert L, Danes J, Jahoda J, Masek M, Lisy J, Ourednicek P. Submillisievert ultralow-dose CT colonography using iterative reconstruction technique: a feasibility study. *Acta Radiol* 1987 2015; 56:517–525. [\[CrossRef\]](#)
10. Lambert L, Ourednicek P, Jahoda J, Lambertova A, Danes J. Model-based vs hybrid iterative reconstruction technique in ultralow-dose submillisievert CT colonography. *Br J Radiol* 2015; 88:20140667. [\[CrossRef\]](#)
11. Levine MS, Kam LW, Rubesin SE, Ekberg O. Internal hemorrhoids: diagnosis with double-contrast barium enema examinations. *Radiology* 1990; 177:141–144. [\[CrossRef\]](#)
12. Kim SY, Park SH, Choi EK, et al. Automated carbon dioxide insufflation for CT colonography: effectiveness of colonic distention in cancer patients with severe luminal narrowing. *AJR Am J Roentgenol* 2008; 190:698–706. [\[CrossRef\]](#)
13. Sosna J, Bar-Ziv J, Libson E, Eligulashvili M, Blachar A. CT colonography: positioning order and intracolonic pressure. *AJR Am J Roentgenol* 2008; 191:W175–180. [\[CrossRef\]](#)
14. Gupta PJ. Hypertrophied anal papillae and fibrous anal polyps, should they be removed during anal fissure surgery? *World J Gastroenterol* 2004; 10:2412–2414. [\[CrossRef\]](#)
15. Bortz J. Potential pitfalls in the anorectal region during CT colonography: A discussion and pictorial overview of common pitfalls. *South Afr J Radiol* 2017; 21:11. [\[CrossRef\]](#)
16. Miyamoto H, Asanoma M, Miyamoto H, Takasu C, Masamune K, Shimada M. Visualization and hypervascularization of the haemorrhoidal plexus in vivo using power Doppler imaging transanal ultrasonography and three-dimensional power Doppler angiography. *Colorectal Dis* 2013; 15:e686–e691. [\[CrossRef\]](#)
17. Neri E, Halligan S, Hellström M, et al. The second ESGAR consensus statement on CT colonography. *Eur Radiol* 2013; 23:720–729. [\[CrossRef\]](#)