

Percutaneous transgastric pancreatic duct drainage for pancreaticojejunal leak after pancreaticoduodenectomy

Minobu Kamo 
Ryo Miyazawa 
Tomoya Nisiyama 
Kenji Nakamura 
Kunihiro Yagihashi 

ABSTRACT

Pancreaticojejunal anastomotic leakage is one of the severe complications after pancreaticoduodenectomy and is often difficult to manage. A 64-year-old man status post pancreaticoduodenectomy had the gastroduodenal artery stump bleeding caused by the pancreaticojejunal anastomotic leakage, successfully treated by placing a covered stent. To control the leakage, subsequent percutaneous transgastric pancreatic duct puncture was performed under fluoroscopic guidance, targeting a surgically placed pancreaticojejunal internal drainage catheter. A 5 F catheter with side holes was inserted into the main pancreatic duct, the tip of which was placed in the anastomosed jejunum. The leak was successfully treated using this catheter. Percutaneous transgastric pancreatic duct drainage might be a useful and feasible option to resolve the condition.

Pancreaticojejunal anastomotic leakage is known as one of the severe complications after pancreaticoduodenectomy, which could cause life-threatening arterial bleeding at the hepatic artery or the gastroduodenal artery stump (1). There have been various treatment methods including percutaneous or endoscopic drainage of the leaked fluid collection, although the results of these approaches are not always satisfactory (2). Herein we report a case of postoperative pancreaticoduodenal leakage successfully treated by percutaneous transgastric pancreatic duct drainage.

Technique

A 64-year-old man status post pancreaticoduodenectomy for adenocarcinoma in the pancreatic head had gastroduodenal artery stump bleeding on postoperative day (POD) 14, which was treated by coil embolization of the origin of the gastroduodenal artery. The bleeding recurred on POD 17 and was successfully treated by placing a covered stent (8×40 mm Fluency stent graft, Bard Peripheral Vascular) into the hepatic artery this time.

Although a 4 F pancreaticojejunal internal catheter (Sumitomo Bakelite) (Fig. 1) and a surgical-bed drainage catheter were placed during the operation of pancreaticoduodenectomy and showed no sign of migration, a fluid collection developed in the area. The fluid from the drainage catheter (approximately 500 mL/day) showed remarkably high pancreatic amylase value (more than 10000 U/L), suggesting pancreaticojejunal anastomotic leakage and malfunction of the previously placed pancreaticojejunal internal catheter. Considering the recurrent episodes of bleeding and the persistent leakage of pancreatic fluid around the surgical site, percutaneous transgastric drainage of the main pancreatic duct was planned after multidisciplinary discussion. Informed consent was obtained from the patient. The procedure was performed on POD 20. First, the stomach was fixed to the anterior abdominal wall using a gastrostomy device called the "Funada-kit II" (Create Medic Co) under fluoroscopic and endoscopic guidance with assistance of an endoscopist. Second, through this site of the fixation, a 21-gauge CHIBA needle (Cook Medical) was introduced fluoroscopically to access the nondilated main pancreatic duct, targeting the surgically placed pancreaticojejunal internal drainage catheter (Fig. 2). A 0.018-inch guidewire (Thruway guidewire, Boston Scientific) was successfully advanced into the main pancreatic duct (Fig. 3). A dilator was advanced along the guidewire and a small amount of contrast media was injected from it, which revealed the leakage of the pancreaticojejunal anastomosis. Subsequently,

From the Department of Radiology (M.K. ✉ kamominobu@gmail.com, R.M., T.N., K.Y.) and Gastroenterology (K.N.), St. Luke's International Hospital, Tokyo, Japan; Department of Diagnostic and Interventional Radiology (M.K.), University Medical Center Hamburg-Eppendorf, Hamburg, Germany; Department of Radiology (K.Y.), Kawasaki Municipal Tama Hospital, Kawasaki, Japan.

Received 21 January 2019; revision requested 12 February 2019; last revision received 25 March 2019; accepted 21 March 2019.

Published online 23 August 2019.

DOI 10.5152/dir.2019.19038

You may cite this article as: Kamo M, Miyazawa R, Nisiyama T, Nakamura K, Yagihashi K. Percutaneous transgastric pancreatic duct drainage for pancreaticojejunal leak after pancreaticoduodenectomy. *Diagn Interv Radiol* 2019; 25:471–472.

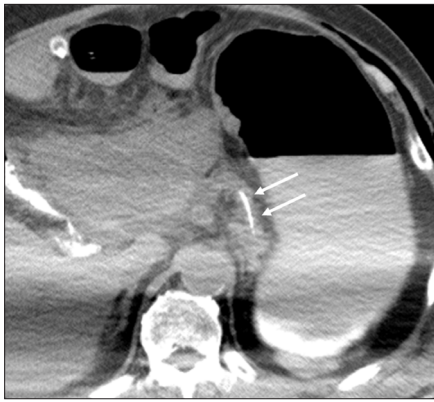

Figure 1. Axial unenhanced CT shows the pancreaticojejunal internal drainage catheter (arrows) placed during the operation of pancreaticoduodenectomy.

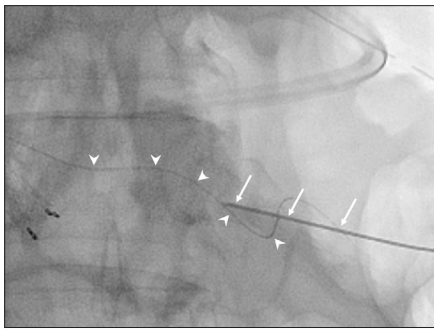


Figure 2. At the site where the stomach is fixated to the abdominal wall, a 21-gauge needle (arrows) was fluoroscopically introduced to access the nondilated main pancreatic duct, targeting the surgically placed pancreaticojejunal internal drainage catheter (arrowheads).

the 0.018-inch guidewire was successfully advanced to the anastomosed jejunum. The guidewire was upsized to 0.035-inch after dilatation. Finally, a 5 F catheter (Anthon PU catheter, Toray), in which side holes were created, was inserted into the main pancreatic duct (Fig. 4). The tip of the catheter was placed in the anastomosed jejunum.

The pancreatic-duct drainage catheter was upsized to an 8 F catheter two months later.

Main points

- Pancreaticojejunal anastomotic leakage is one of the severe complications after pancreaticoduodenectomy and is often difficult to be managed.
- Targeting a surgically placed pancreaticojejunal internal drainage catheter makes it possible to safely puncture the nondilated main pancreatic duct fluoroscopically.
- Percutaneous transgastric pancreatic duct drainage might be a useful and feasible option to resolve the condition.

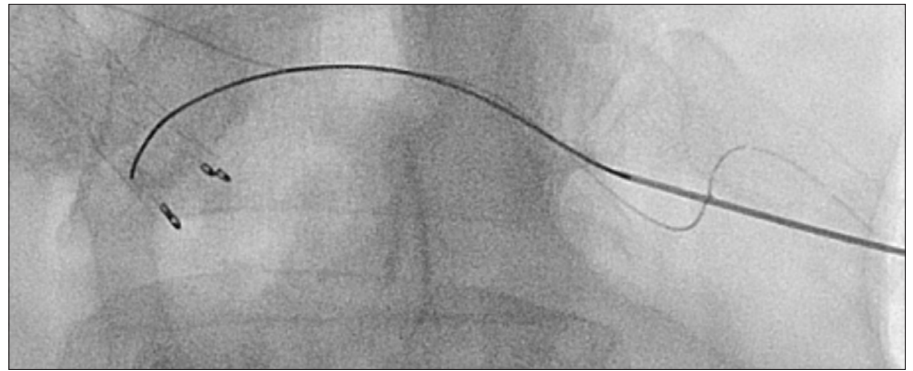


Figure 3. A 0.018-inch guidewire was successfully advanced to the main pancreatic duct.

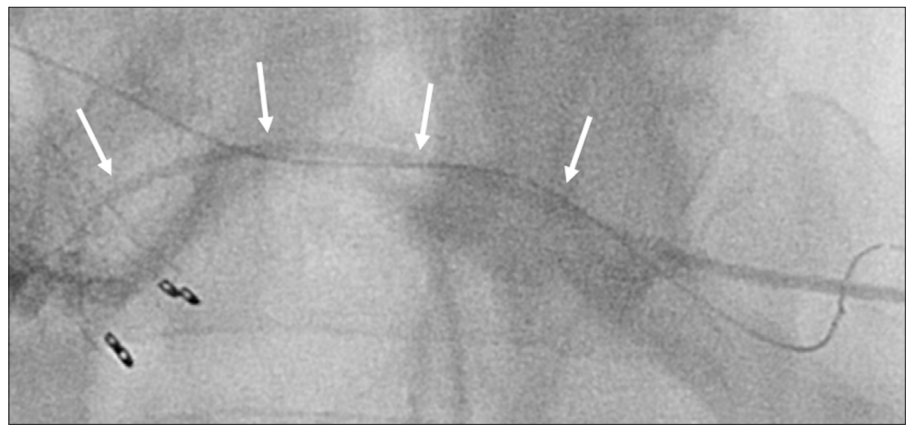


Figure 4. A 5 F catheter with side holes (arrows) was inserted into the main pancreatic duct.

The leak was successfully treated using this catheter and the fluid collection in the area disappeared. The patient remained symptom and re-bleeding free until his death from acute cholangitis due to fast-growing multiple liver metastasis four months later.

Discussion

Percutaneous interventional approach to the pancreatic duct was first reported by Gobien et al. in 1983 (3). Mizandari et al. (4) recently reported successful procedures of the percutaneous approach to the pancreatic duct in 30 patients. These procedures, however, have been so far applied mainly to patients with pancreatic duct obstruction accompanying dilated pancreatic ducts, and not to patients with pancreatic leakage after pancreatic operations.

In this case, targeting a previously placed pancreaticojejunal internal drainage catheter made it possible to safely puncture the main pancreatic duct fluoroscopically. By fixing the stomach to the abdominal wall, risks of injuring surrounding structures were presumably reduced. Transgastric approach would also have an advantage of creating an internal fistula to the stomach, enabling removal of the catheter thereafter.

In conclusion, pancreaticojejunal anastomotic leakage is one of the common and severe complications after pancreatic operation and is often clinically difficult to be controlled. Percutaneous transgastric pancreatic duct drainage might be a useful and feasible option to resolve the condition.

Acknowledgements

The authors are grateful to Jay Starkey, M.D. for the revision of the English text.

Conflict of interest disclosure

The authors declared no conflicts of interest.

References

1. Puppala S, Patel J, McPherson S, Nicholson A, Kessel D. Hemorrhagic complications after Whipple surgery: Imaging and radiologic intervention. *AJR Am J Roentgenol* 2001; 196:192–197. [\[CrossRef\]](#)
2. Voss M, Pappas T. Pancreatic fistula. *Curr Treat Options Gastroenterol* 2002; 5:345–353. [\[CrossRef\]](#)
3. Gobien RP, Stanley JH, Anderson MC, Vujic I. Percutaneous drainage of pancreatic duct for treating acute pancreatitis. *AJR Am J Roentgenol* 1983; 141:795–796. [\[CrossRef\]](#)
4. Mizandari M, Arzumelashivili T, Kumar J, Habin N. Percutaneous image-guided pancreatic duct drainage: technique, results and expected benefits. *Cardiovasc Intervent Radiol* 2017; 40:1911–1920. [\[CrossRef\]](#)