

Cryoablation of low-flow vascular malformations

Raja S. Ramaswamy 

Tatulya Tiwari 

Michael D. Darcy 

Seung K. Kim 

Olagueke Akinwande 

Niloy Dasgupta 

Carlos J. Guevara 

PURPOSE

We aimed to evaluate the safety and effectiveness of cryoablation in the treatment of low-flow malformations, specifically venous malformation (VM) and fibroadipose vascular anomaly (FAVA).

METHODS

We conducted a retrospective review of 11 consecutive patients with low-flow malformations (14 lesions; 9 VM, 5 FAVA), median lesion volume 10.8 cm³, (range, 1.8–55.6 cm³) with a median age of 19 years (range, 10–50 years) who underwent cryoablation to achieve symptomatic control. Average follow-up was at a median of 207 days postprocedure (range, 120–886 days). Indications for treatment included focal pain and swelling. Technical success was achieved if the cryoablation ice ball covered the region of the malformation that corresponded to the patient's symptoms. Clinical success was considered complete if all symptoms resolved and partial if some symptoms persisted but did not necessitate further treatment.

RESULTS

The technical success rate was 100%. At 1-month follow-up, 13 of 14 lesions (93%) had a complete response and one (7%) had a partial response. At 6-month follow-up 12 of 13 (92%) had a complete response and 1 (8%) had a partial response. A total of 6 patients underwent primary cryoablation. Out of 9 VM cases, 7 had prior sclerotherapy and 2 had primary cryoablation. Out of the 5 FAVA cases, 1 had prior sclerotherapy and the remaining 4 cases underwent primary cryoablation. There were 3 minor complications following cryoablation including 2 cases of skin blisters and 1 case of transient numbness. These complications resolved with conservative management.

CONCLUSION

Cryoablation is safe and effective in the treatment of low-flow vascular malformations, either after sclerotherapy or as primary treatment.

The diagnosis and management of vascular malformations is challenging due to lesion rarity, confusing nomenclature, and clinical symptom overlap in many cases (1, 2). Low-flow vascular malformations are the most common type of congenital vascular anomaly. Traditionally, low-flow vascular malformations include venous malformation (VM) and lymphatic malformation (LM) (2). However, the distinct entity of fibroadipose vascular anomaly (FAVA) was recently described by Alomari et al. (3). FAVA is a complex vascular malformation in the spectrum of low-flow malformations that typically presents with focal pain, discomfort, contractures, and phlebectasia. Imaging characteristics include a fibrofatty lesion overlying a VM usually located in the calf or forearm (3).

For the treatment of low-flow malformations, sclerotherapy has evolved as a primary treatment modality (4, 5). This is in particular true for VMs; however, other potential treatment options for FAVA include conservative management and surgical resection (6). Surgical resection has been found to be effective for focal lesions (7). However in the treatment of malformations, surgery may be associated with increased risk of bleeding or worsening of symptoms. Also surgery is associated with incomplete lesion resection and lesion recurrence (8). Alternative techniques such as radiofrequency ablation (9–11) and cryoablation (6, 12–14) have been proposed to treat low-flow malformations with promising results especially when the lesion is refractory to sclerotherapy.

From the Department of Radiology (R.S.R. ✉ ramaswamy@wustl.edu, M.D.D., S.K.K., O.A., N.D.), Mallinckrodt Institute of Radiology, Washington University School of Medicine, St. Louis, Missouri, USA; Department of Radiology, Division of Endovascular Surgery and Interventional Radiology (T.T.), Lexington Veterans Affairs (VA) Medical Center, Lexington, Kentucky, USA; Department of Diagnostic and Interventional Radiology (C.J.G.), University of Texas Health Center, Houston, Texas, USA.

Received 27 June 2018; revision requested 16 July 2018; last revision received 29 October 2018; accepted 3 November 2018.

Published online 12 April 2019.

DOI 10.5152/dir.2019.18278

There are a few published studies evaluating cryoablation as second-line therapy for the treatment of low-flow malformations (12, 13, 15). Percutaneous cryoablation has been used as second-line therapy with favorable results for the treatment of VMs (13, 15) and as a promising primary treatment for FAVA (6). However, previous studies in particular for VMs have not evaluated cryoablation as a primary treatment modality. The purpose of this study is to evaluate the safety and effectiveness of cryoablation of VM and FAVA either as a primary modality or as second-line treatment after sclerotherapy.

Methods

This retrospective review of all consecutive VM and FAVA patients that underwent cryoablation was approved by the Institutional Review Board (IRB #201806101) and conducted over a study period between 2014 and 2017. Informed consent was obtained from all patients/legal guardians prior to the procedure. Eleven patients (6 male, 5 female) with 14 lesions with a median age of 19 years (range 10–50 years) were included in this study. The median lesion volume was 10.8 cm³ (range, 1.8–55.6 cm³). Prior to the procedure, the lesion volumes were measured on magnetic resonance imaging (MRI) using the formula length × breadth × width × 0.5233. Patients were included if they had clinical history, physical exam findings, and MRI findings consistent with VM or FAVA. No patients were excluded from this study. Clinical records, pre-cryoablation procedures, cryoablation procedural details, preprocedural symptoms, clinical outcomes, and complications were evaluated.

Main points

- For the treatment of low-flow malformations, sclerotherapy has evolved as a primary treatment modality. Other treatment options include conservative management and surgical resection.
- Prior literature indicates that percutaneous cryoablation has been used as second-line therapy with favorable results for the treatment of venous malformations (VM) and as a promising primary treatment for fibroadipose vascular anomaly (FAVA).
- The findings of this study indicate that percutaneous cryoablation appears to be safe and effective in the treatment of symptomatic low-flow vascular malformations either as a primary modality or secondary therapy in addition to sclerotherapy.

Imaging findings

MRI features of VM typically include intermediate to decreased signal intensity on T1-weighted images and increased signal intensity on T2-weighted images. Heterogeneous signal may be observed in cases of associated thrombosis or hemorrhage. The presence of phleboliths are characteristic of VMs (16). On MRI, FAVA demonstrates high signal intensity due to the fibrofatty components on T1- and T2-weighted images. Fibro-fatty components may be present in the intr fascial, intramuscular, or subcutaneous layers. Both VM and FAVA enhance with contrast due to the venous components of the lesion (6).

Patient evaluation

Patients were evaluated in a multidisciplinary clinic prior to cryoablation. Cryoablation was offered as primary treatment if the patient experienced severe focal pain and had a localized low-flow malformation. Otherwise, patients were treated initially with sclerotherapy as primary treatment and once sclerotherapy did not provide symptomatic relief any longer, cryoablation was offered. If sclerotherapy was performed first, there was a minimum of 8 weeks before cryoablation was performed. Indications for cryoablation included pain and swelling. Symptoms, pre-cryoablation treatments, imaging, procedural reports,

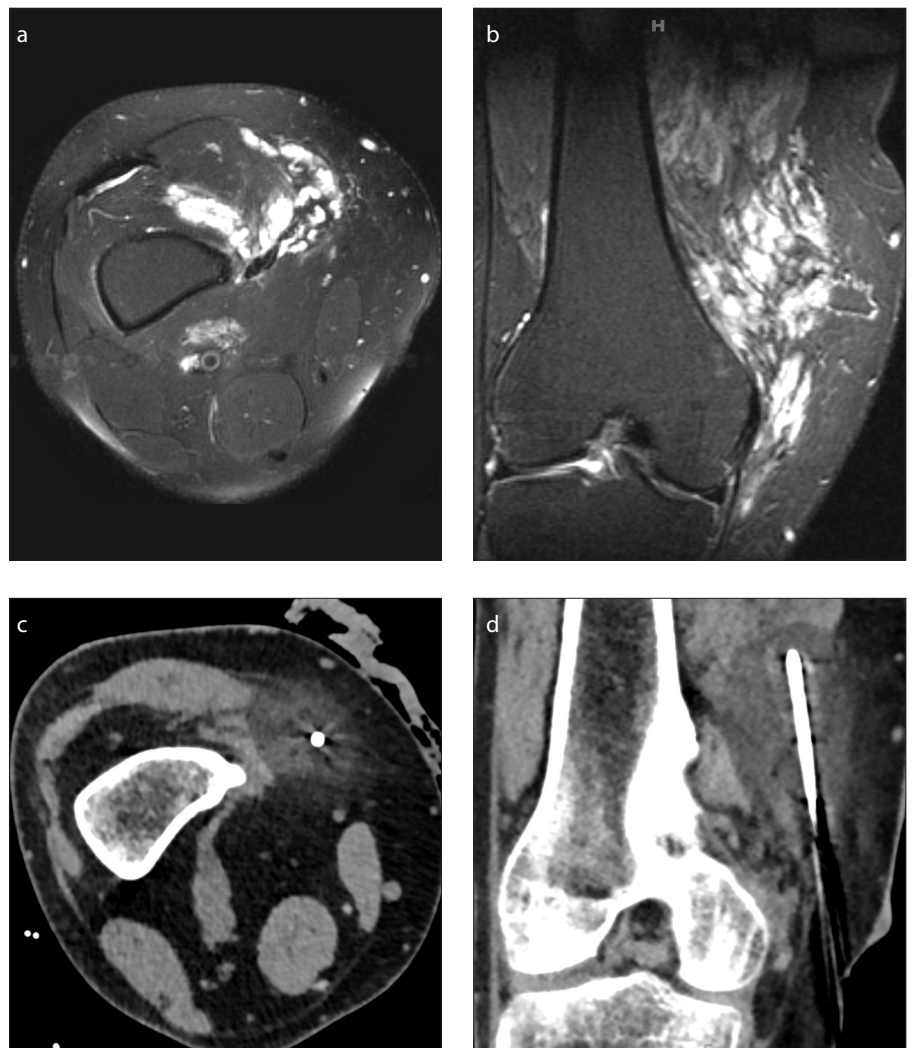


Figure 1. a–d. A 29-year-old male with a venous malformation (VM) primarily in the right vastus lateralis muscle. Due to the extent of VM and symptoms which the patient was able to localize, primary cryoablation was offered. Axial and coronal T2-weighted images of the right lower extremity (a, b) demonstrate an extensive VM that is intramuscular in location and primarily confined to the vastus lateralis extending into the subcutaneous tissues. A total of three cryoprobes (c, d) were used to ablate the VM. The ice ball demonstrates coverage of the lesion which corresponded to the patient's clinical symptoms of pain. Clinic follow-up 1 and 6 months later demonstrated symptom resolution.

clinical outcomes and complications were investigated by reviewing the electronic medical record. Complications were classified according to SIR criteria (17).

Cryoablation technique

Prior to the procedure, patients were asked to point the area where they experienced symptoms. This area was evaluated with ultrasonography (US), and the skin was marked to denote the target area. All cases were performed on an outpatient basis under general anesthesia. If the lesion was determined to be in close proximity to a major motor nerve or at risk due to the intended ablation zone, continuous cutaneous neural monitoring or electromyography (EMG) was used intra-procedurally to avoid nerve injury. Surface electrode locations were chosen based on discussion by the interventional radiologist and the monitoring neurologist. Cryoablation was halted if there was a significant decrease in the amplitude of the compound motor action potential as determined by the neurologist.

The cryoablation probes were placed under the direction of US and/or computed tomography (CT) guidance. The goal of the cryoablation procedure was to create an ice ball large enough to cover the area underlying the malformation that was pre-procedurally marked on the skin. Therefore, the aim was to treat the symptomatic region and not necessarily the entire malformation. If there was less than 1 cm of subcutaneous tissue overlying the lesion, hydrodissection and/or warm compresses were used to avoid skin injury. Hydrodissection was performed under US-guidance by instilling saline through a 21-gauge needle to provide separation between the skin surface and the malformation (18). The Endocare PerCryo System (Endocare PerCryo System; Healthtronics) was used with Endocare Perc-17 or Perc-24 cryoprobes selected based on the reference chart provided by the vendor. Two 10-minute freeze cycles were used; however freeze times were adjusted (between 3–10 minutes) based on real-time monitoring of the ice ball growth to cover the lesion and avoid freezing of critical structures including the skin. Final active thaw was performed with helium before probe removal (13). Treatment effects including ice ball coverage were monitored under real-time US and CT. A CT was obtained every 5 minutes in cases where critical structures were located close to the lesion (19). Technical success was achieved if the cryoablation ice ball

covered the region of the malformation that corresponded to the patient's symptoms. Patients were discharged at approximately 2–4 hours postprocedure with antiinflammatory and pain medication.

Postprocedure

Following cryoablation, patients were referred for physical therapy evaluation to improve strength, flexibility, and range of motion. Patients were followed up in clinic 1 month and 6 months after the procedure. After the 6-month clinic visit, patients were given the option to return to clinic at a year interval or as needed. Clinical success was defined at 1 month and 6 months after the procedure. At the time of the clinic visit the patient was asked to describe their residual symptoms and compare them to their presenting symptoms. Complete response was described if all preprocedural symptoms resolved. Partial response was considered if there were some residual symptoms that no longer required medications or interfered with activities. Clinical failure was considered if the cryoablation procedure did not improve the symptoms enough to avoid

using medications or required additional procedures.

Results

Eleven patients with fourteen lesions underwent percutaneous cryoablation with or without prior sclerotherapy. Nine of the lesions were VMs and the remaining 5 were FAVAs. MRI was used to make all diagnoses of VM or FAVA in conjunction with clinical symptoms. A diagnosis of VM was made if there was intermediate-to-decreased signal intensity on T1-weighted images and increased signal on T2-weighted images. A diagnosis of FAVA was made if there was high signal on both T1- and T2-weighted images which are typically due to the fibrofatty components. Both lesions enhance with contrast due to the underlying venous component.

The median lesion diameter and volume was 4.4 cm (range, 2.0–10.9 cm) and 10.8 cm³ (range, 1.8–55.6 cm³), respectively. All malformations were intramuscular in location and involved the subcutaneous tissues. Four lesions were in the thigh, 3 in the calf, 2 in the foot, 3 in the arm, 1 in the torso, and 1 in the lumbar region.

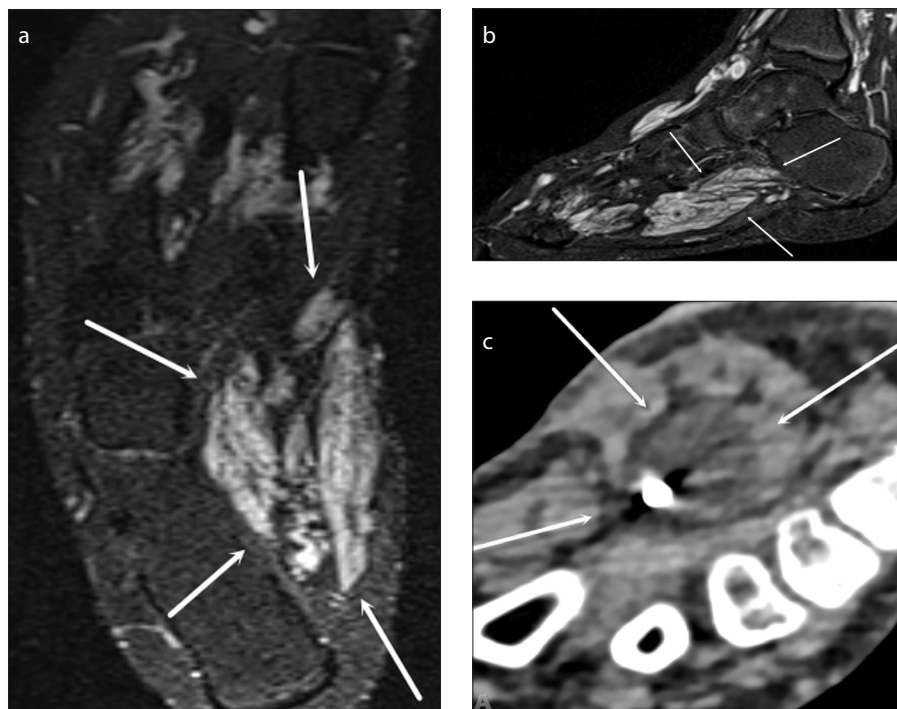


Figure 2. a–c. A 12-year-old female with a fibroadipose vascular anomaly (FAVA) in the plantar musculature of the medial right foot. The patient was offered primary cryoablation due to the location of the lesion. Pre-cryoablation MRI in the axial (a) and sagittal (b) planes demonstrates a primarily fat-based lesion with underlying venous vessels in the right foot (arrows). In this case, EMG monitoring was utilized due to the proximity to neurovascular structures. A single cryoprobe (c) was used to ablate the FAVA with ice ball coverage encircling the patient's primary area of symptoms. At 1-month follow-up visit the patient's symptoms of pain had resolved but a partial contracture still persisted.

All 11 patients with VM and FAVA presented with focal pain referable to the lesion. Out of 9 VM cases, 7 had prior sclerotherapy and 2 had primary cryoablation. All 7 VM patients that received sclerotherapy had recalcitrant pain despite treatment. Thus cryoablation was offered (Fig. 1). Of the 5 FAVA cases, 1 had prior sclerotherapy and the remaining four cases underwent primary cryoablation (Fig. 2). None of the lesions had prior intervention including intralesional steroid therapy or surgical resection.

The technical success rate was 100%. The median follow-up time postprocedure was 206 days (120–886 days). At 1-month follow-up, 13 of 14 lesions had a complete response and 1 had a partial response. At 6-month follow-up, 12 of 13 had a complete response and 1 had a partial response. One patient did not have a 6-month follow-up visit. Of the 9 patients in the VM cohort, 7 patients had a complete response. Both

patients that were categorized as partial response had improved but continued to have residual pain on follow-up; however, they did not require additional treatments. Of the 5 patients in the FAVA cohort, 4 had complete response. One patient had a partial response with residual contracture; however, she did not require any medications or further treatment (Table). There was a total of 6 patients that were treated with cryoablation as a primary modality (2 VM, 4 FAVA). In this cohort, 5 of 6 patients had complete resolution of symptoms.

There were 3 minor complications following cryoablation as defined by SIR Criteria (14). Two skin blisters were observed, both of which resolved in less than 2 weeks with conservative management and did not leave any skin marks or scars. There was 1 case of transient numbness, which subsided with conservative management. Conservative management for this patient in-

cluded stretching/strengthening exercises along with antiinflammatory medications to reduce soft tissue swelling. No motor or sensory nerve injuries were observed.

Discussion

In the present series of 11 patients with 14 vascular malformations, US and CT-guided cryoablation was feasible, safe, and provided complete symptomatic relief for most patients. Notably, cryoablation was used as a primary treatment modality in 6 patients with favorable result and a positive treatment result was observed in all lesions treated.

The treatment of vascular malformations has changed in the last few decades. Initially, surgery was the main modality; however, there have been significant morbidity and recurrence rates (20, 21). Percutaneous and endovascular treatments including sclerotherapy and embolization have now become the mainstay for the treatment of

Table. Characteristics of study patients treated by cryoablation

Patient no	Age (yrs)	Preprocedure symptoms	Malformation	Prior sclerotherapy	Lesion location	Maximal dimension (cm)	Volume (cm ³)	Number of cryoprobes	Postprocedure symptoms	Complications
1	29	Pain, swelling	VM	No	Thigh	9.0	52.75	3	Asymptomatic	None
2	10	Pain, contracture	FAVA	Yes	Foot	2.3	4.12	1	Asymptomatic	None
11	11	Pain, contracture	FAVA	No	Calf	5.9	9.15	2	Asymptomatic	None
12	12	Pain, contracture	FAVA	No	Foot	3.7	9.76	1	Residual contracture	Skin blister
3	17	Pain, swelling	FAVA	No	Calf	10.9	55.59	1	Asymptomatic	None
4	12	Pain, contracture	FAVA	No	Calf	6.0	47.10	3	Asymptomatic	Skin blister
5	41	Pain, swelling	VM	Yes	Arm	3.3	10.64	1	Residual pain	None
6	14	Pain, tightness	VM	Yes	Thigh	2.0	6.91	1	Asymptomatic	None
7	49	Pain, tightness	VM	Yes	Back – Lumbar	3.6	7.23	1	Asymptomatic	None
50	50	Pain, swelling	VM	No	Torso	8.0	37.68	4	Asymptomatic	None
8	41	Pain, tenderness	VM	Yes	Thigh	8.7	49.72	2	Residual pain	None
9	35	Pain, swelling	VM	Yes	Arm	5.0	45.79	2	Asymptomatic	None
10	21	Pain, swelling	VM	Yes	Arm	3.4	10.96	1	Asymptomatic	Transient numbness
11	12	Pain, swelling	VM	Yes	Thigh	2.1	1.81	1	Asymptomatic	None

VM, venous malformation; FAVA, fibrovascular adipose vascular anomaly.

vascular malformations with improved outcomes, decreased complication rates, and less morbidity (2, 6, 22).

While the outcomes have improved over time, there is a subset of patients that has had multiple sclerotherapy sessions yet remain symptomatic and thus cryoablation appears to serve a role in treatment (15). More recently, FAVA has been recognized as a separate entity, which is within the spectrum of low-flow malformations (3). FAVAs do not appear to respond as well to sclerotherapy because solely treating the venous component of the malformation does seem to be as important as treating the fibroadipose element that causes contractures and pain. Previous studies have used cryoablation for the indication of neuropathic pain (23, 24). Cryoablation for FAVA appears efficacious in its ability to treat focal pain that results from the malformation (6).

In previous studies, second-line treatment was defined as a treatment regimen that is pursued when first-line therapy is not efficacious. Prior studies have evaluated the use of cryoablation for either the second-line treatment of various vascular anomalies (12), second-line therapy for VMs (13, 15), and FAVAs (6). A previous study by Thompson et al. (12) found cryoablation and laser ablation to be effective second-line treatments of vascular anomalies in eight patients. Cornelis et al. (15) found cryoablation to be a safe and effective second-line treatment option for VMs in a series of 24 patients.

The findings of this current study agree with previously published studies regarding the feasibility of cryoablation in the treatment of vascular malformations. However, in the current study, cryoablation was utilized with success as primary treatment modality in 6 patients: 2 with VMs and 4 with FAVAs. In the 6 patients where cryoablation was used as the primary modality, US and MRI showed a well-circumscribed focal lesion. Due to these imaging findings and the desire to optimize treatment cryoablation was utilized specifically for those lesions.

In this study there were no major complications and 3 minor complications. The complication rate in the current study compares to previously published studies which also report low complication rates (6, 15). The ice ball was continuously monitored with US along with preventative measures including hydrodissection and/or warm compresses on the skin. In the future these

complications may be avoided by more aggressive hydrodissection or decreasing the size of the ice ball.

There are several limitations in this study. This is a retrospective review of a small cohort of patients with one patient having short-term follow-up of less than 6 months. In this study, the treatment for low-flow malformations was not standardized therefore some patients had sclerotherapy prior to cryoablation which may confound the results. The choice of sclerotherapy and/or cryoablation was performed on a case-by-case basis via a multidisciplinary vascular anomalies conference. Other limitations include the lack of standardized quantification of symptoms and a limited follow-up time period. A small number of lesions was evaluated which owes to the fact that VMs and FAVAs are rare. VMs may be diffuse, infiltrative, and involve the skin. In this study, only cases of localized VMs were treated. All FAVA and VMs selected to be treated were localized lesions in the muscle +/- the subcutaneous region.

In conclusion, percutaneous cryoablation appears to be safe and effective in the treatment of symptomatic low-flow vascular malformations either as a primary modality or secondary therapy in addition to sclerotherapy. Due to its underlying nature, vascular malformations are difficult to manage. Cryoablation provides an additional treatment option for patients due to its implications in improvement in quality of life and functionality.

Conflict of interest disclosure

The authors declared no conflicts of interest.

References

1. Clemens RK, Pfammatter T, Meier TO, Alomari AI, Amann-Vesti BR. Vascular malformations revisited. *Vasa* 2015; 44:5–22. [\[CrossRef\]](#)
2. Wassef M, Blei F, Adams D, et al. Vascular anomalies classification: recommendations from the international society for the study of vascular anomalies. *Pediatrics* 2015; 136:e203–214. [\[CrossRef\]](#)
3. Alomari AI, Spencer SA, Arnold RW, et al. Fibroadipose vascular anomaly: clinical-radiologic-pathologic features of a newly delineated disorder of the extremity. *J Pediatr Orthop* 2014; 34:109–117. [\[CrossRef\]](#)
4. Behraves S, Yakes W, Gupta N, et al. Venous malformations: clinical diagnosis and treatment. *Cardiovasc Diagn Ther* 2016; 6:557–569. [\[CrossRef\]](#)
5. Horbach SE, Lokhorst MM, Saeed P, de Gouyon Matignon de Pontouraude CM, Rothova A, van der Horst CM. Sclerotherapy for low-flow vascular malformations of the head and neck: A systematic review of sclerosing agents. *J Plast Reconstr Aesthet Surg* 2016; 69:295–304. [\[CrossRef\]](#)

6. Shaikh R, Alomari AI, Kerr CL, Miller P, Spencer SA. Cryoablation in fibro-adipose vascular anomaly (FAVA): a minimally invasive treatment option. *Pediatr Radiol* 2016; 46:1179–1186. [\[CrossRef\]](#)
7. Fernandez-Pineda I, Marcilla D, Downey-Carmona FJ, Roldan S, Ortega-Laureano L, Bernabeu-Wittel J. Lower extremity fibro-adipose vascular anomaly (FAVA): a new case of a newly delineated disorder. *Ann Vasc Dis* 2014; 7:316–319. [\[CrossRef\]](#)
8. Yakes WF. Endovascular management of high-flow arteriovenous malformations. *Semin Intervent Radiol* 2004; 21:49–58. [\[CrossRef\]](#)
9. Garg S, Kumar S, Singh YB. Intralesional radiofrequency in venous malformations. *Br J Oral Maxillofac Surg* 2015; 53:213–216. [\[CrossRef\]](#)
10. Childs DD, Emory CL. Successful treatment of intramuscular venous malformation with image-guided radiofrequency ablation. *J Vasc Interv Radiol* 2012; 23:1391–1393. [\[CrossRef\]](#)
11. van der Linden E, Overbosch J, Kroft LJ. Radiofrequency ablation for treatment of symptomatic low-flow vascular malformations after previous unsuccessful therapy. *J Vasc Interv Radiol* 2005; 16:747–750. [\[CrossRef\]](#)
12. Thompson SM, Callstrom MR, McKusick MA, Woodrum DA. Initial results of image-guided percutaneous ablation as second-line treatment for symptomatic vascular anomalies. *Cardiovasc Intervent Radiol* 2015; 38:1171–1178. [\[CrossRef\]](#)
13. Cornelis F, Havez M, Labreze C, et al. Percutaneous cryoablation of symptomatic localized venous malformations: preliminary short-term results. *J Vasc Interv Radiol* 2013; 24:823–827. [\[CrossRef\]](#)
14. Cornelis FH, Labreze C, Pinsolle V, et al. Percutaneous image-guided cryoablation as second-line therapy of soft-tissue venous vascular malformations of extremities: a prospective study of safety and 6-month efficacy. *Cardiovasc Intervent Radiol* 2017; 40:1358–1366. [\[CrossRef\]](#)
15. Cornelis FH, Marin F, Labreze C, et al. Percutaneous cryoablation of symptomatic venous malformations as a second-line therapeutic option: a five-year single institution experience. *Eur Radiol* 2017; 27:5015–5023. [\[CrossRef\]](#)
16. Flors L, Leiva-Salinas C, Maged IM, et al. MR imaging of soft-tissue vascular malformations: diagnosis, classification, and therapy follow-up. *Radiographics* 2011; 31:1321–1341. [\[CrossRef\]](#)
17. Omary RA, Bettmann MA, Cardella JF, et al. Quality improvement guidelines for the reporting and archiving of interventional radiology procedures. *J Vasc Interv Radiol* 2003; 14:S293–295. [\[CrossRef\]](#)
18. Farrell MA, Charboneau JW, Callstrom MR, Reading CC, Engen DE, Blute ML. Paraneuritic water instillation: a technique to prevent bowel injury during percutaneous renal radiofrequency ablation. *AJR Am J Roentgenol* 2003; 181:1315–1317. [\[CrossRef\]](#)
19. Erinjeri JP, Clark TW. Cryoablation: mechanism of action and devices. *J Vasc Interv Radiol* 2010; 21:S187–191. [\[CrossRef\]](#)

20. Cahill AM, Nijs EL. Pediatric vascular malformations: pathophysiology, diagnosis, and the role of interventional radiology. *Cardiovasc Intervent Radiol* 2011; 34:691–704. [\[CrossRef\]](#)
21. Mcafferty I. Management of low-flow vascular malformations: clinical presentation classification, patient selection, imaging and treatment. *Cardiovasc Intervent Radiol* 2015; 38:1082–1104. [\[CrossRef\]](#)
22. Puig S, Aref H, Chigot V, Bonin B, Brunelle F. Classification of venous malformations in children and implications for sclerotherapy. *Pediatr Radiol* 2003; 33:99–103. [\[CrossRef\]](#)
23. Yoon JH, Grechushkin V, Chaudhry A, Bhattacharji P, Durkin B, Moore W. Cryoneurolysis in patients with refractory chronic peripheral neuropathic pain. *J Vasc Interv Radiol* 2016; 27:239–243. [\[CrossRef\]](#)
24. Moore W, Kolnick D, Tan J, Yu HS. CT guided percutaneous cryoneurolysis for post thoracotomy pain syndrome: early experience and effectiveness. *Acad Radiol* 2010; 17:603–606. [\[CrossRef\]](#)