

# Persistence of pulmonary arteriovenous malformations after successful embolotherapy with Amplatzer vascular plug: long-term results

Ahmed Kamel Abdel-Aal  
Rafik Mohamed Ibrahim  
Amr Soliman Moustafa  
Maysoon Farouk Hamed  
Souheil Saddekni

## PURPOSE

We aimed to evaluate the frequency of persistence and complication rates of pulmonary arteriovenous malformations (PAVMs) treated with Amplatzer vascular plug (AVP) or Amplatzer vascular plug type 2 (AVP2).

## METHODS

We retrospectively reviewed a total of 22 patients with 54 PAVMs between June 2004 and June 2014. We included 12 patients with 35 PAVMs who received percutaneous embolization using AVP or AVP2 only without the use of any other embolic devices. The mean follow-up was  $54 \pm 24.3$  months (range, 31–97 months). The primary end-points of the study were the efficacy of embolotherapy, the increase in oxygen saturation, and the persistence of PAVM on follow-up. Secondary end point was the incidence of complications.

## RESULTS

The study included 10 female and two male patients with a mean age of  $50.2 \pm 13.7$  years (range, 21–66 years). All PAVMs had a simple angioarchitecture. The technical success of the procedure for PAVM occlusion was 100%. There was a significant increase in the oxygen saturation following embolotherapy ( $P < 0.0001$ ). Follow-up computed tomography angiography revealed successful treatment in 34 PAVMs (97%) and failed treatment in one PAVM (3%). Twenty-three aneurysmal sacs (67%) showed complete disappearance. The failed treatment was due to persistence of PAVM caused by subsequent development of systemic reperfusion, which did not require further intervention. There were two minor complications but no major complications were encountered.

## CONCLUSION

Embolotherapy of PAVMs using AVP or AVP2 devices is safe and effective, with high technical success rate, low persistence and complication rates, and with excellent long-term results.

**P**ulmonary arteriovenous malformations (PAVMs) represent abnormal communications between pulmonary arteries and pulmonary veins resulting in a right-to-left shunt (1). This shunt results in hypoxemia manifesting with dyspnea, as well as paradoxical embolization, which can cause serious neurologic complications (2). Therefore, significant morbidity has been associated with these PAVMs, and the aim of treatment is to embolize the shunt to improve the patient's functional status, and prevent complications related to paradoxical embolization (3).

Since the first transcatheter embolization of a PAVM in 1977 by Porstmann (4), this technique has become widely used for the management of these lesions since it is less invasive than surgery with a high success rate (2, 5). The endovascular approach favors embolization of PAVMs mainly with coils or Amplatzer vascular plug (AVP). In regards to traditional coils, migration into the systemic circulation and reperfusion are the most important complications that may occur with nondetachable coils. Coil migration into the systemic circulation is reported to occur in 2% to 4% of the treated patients, especially with high flow, large PAVMs (6, 7). Persistence of PAVMs can result from recanalization of the embolized vessels through the previously placed embolic material; interval reperfusion through accessory vessels, which could be from the pulmonary or systemic circulation; or incomplete primary treatment especially in complex PAVMs (2, 7–10). The most common cause of persistence is PAVM recanalization, which accounts for 88% to 91% of cases treated with coils (1, 10–12).

The initial studies of PAVM embolization with AVP and AVP2 (St. Jude Medical) showed good immediate technical success rates (3, 13–16), and the data published in literature

From Department of Radiology (A.K.A.

✉ [akamel@uabmc.edu](mailto:akamel@uabmc.edu), R.M.I., A.S.M., S.S.), University of Alabama at Birmingham, Birmingham, Alabama, USA; the Department of Family Medicine (M.F.H.), University of Alabama, Tuscaloosa, Alabama, USA.

Received 8 August 2015; revision requested 11 September 2015; last revision received 23 October 2015; accepted 19 November 2015.

Published online 31 March 2016.  
DOI 10.5152/dir.2015.15262

provide short-term and mid-term results (3, 17, 18). The objective of our study is to present the long-term efficacy and safety of these plugs in the treatment of PAVMs, by presenting the persistence rates and complication rates of these devices.

## Methods

### Patients

Approval from our institutional review board was obtained. We retrospectively reviewed the medical records of patients who underwent percutaneous transcatheter embolotherapy of PAVMs between June 2004 and June 2014. A total of 22 patients with 54 PAVMs were identified. Three patients were excluded since their PAVMs were treated using coils only based on physician preference. We also excluded seven patients who were lost to clinical and/or imaging follow-up. Twelve patients, who had a total of 35 PAVMs that were treated with AVP and/or AVP2 only were included in our study. The mean age of these patients was  $50.2 \pm 13.7$  years (range, 21–66 years). Two patients (17%) were males and ten patients (83%) were females. Nine patients (75%) complained of dyspnea prior to embolization therapy. Oxygen saturation was measured in all individuals and was less than 92% in six patients (50%). Four patients (33%) presented with either stroke or transient ischemic attack caused by paradoxical embolization. One of these four patients had bilateral middle cerebral arteries territory strokes due to paradoxical embolization from a previously undiagnosed deep vein thrombosis, resulting in devastating neurologic consequences. No long-term neurologic consequences were observed in the remaining three patients. One patient (8%) presented with seizure and magnetic resonance imaging of the brain revealed cerebral abscess. Another patient (8%) had a history of renal abscess related to his

disease. Although no patients underwent genetic testing, five patients (42%) had hereditary hemorrhagic telangiectasia (HHT) that was diagnosed by Curacao criteria including clinical presentation and history of first degree relative with HHT (19). The clinical presentation of patients with HHT included recurrent epistaxis and oropharyngeal, cerebral, and hepatic telangiectasia. One patient (8%) had Charcot-Marie-Tooth syndrome at the time of embolization with advanced disease progression and severe peripheral neurologic disease. The coagulation profile for each of the patients was normal before the procedure. Table 1 shows the clinical presentation of patients included in our study.

### Technique

Access through the common femoral vein was obtained and diagnostic pulmonary angiograms were performed to locate the PAVMs. Selective catheterization of the branch pulmonary artery feeding the PAVM was then performed to identify the diameter and number of the feeding arteries. The PAVMs were classified according to the number of feeding arteries into simple or complex as proposed by White et al. (20).

The AVP or AVP2 was then flushed and introduced through the appropriate size guiding catheter (Envoy, Cordis) or sheath (Shuttle, Cook) under water seal. The guiding catheter and sheath were connected with continuous saline flush bags to avoid thrombus formation at their tips. The diameter of the device was chosen to be 30%–50% larger than the size of the feeding artery. The plug was then placed as distal as

possible in the feeding artery but not in the aneurysmal sac. The choice between the two plugs was based mainly on the length of the landing zone, which is the distance between the aneurysm sac and the first proximal pulmonary arterial branch. The AVP was used when the landing zone was short enough to hinder placement of AVP2 without covering more proximal normal pulmonary arterial branches. The position of the device was then checked by doing angiograms through the guide catheter or sheath, which was done immediately after device placement. A decision to deploy or retrieve the device was made as quickly as possible to avoid retrieving a partially thrombosed device, which carries the risk of showering emboli through the shunt into the systemic circulation. If the position of the device was found to be adequate and satisfactory, the device was released. No technical difficulties were encountered during placement or deployment of the device. Postembolization angiography was performed at 3–4 minutes interval after device deployment until total occlusion was visualized. Immediate technical success was defined as embolization of the PAVM using AVP or AVP2 only without the need to use additional embolization material. No heparin was used throughout the procedure. Patients who had more than two PAVMs underwent staged embolization of their PAVMs on several sessions.

We recorded the number, location, and type (simple or complex) of the PAVMs, as well as the diameter and number of the feeding arteries. We also recorded the number, location, and size of the devices used

### Main points

- Pulmonary arteriovenous malformation persisted in 3% of the cases following treatment with Amplatzer vascular plugs (AVPs).
- The use of AVP and AVP2 for embolotherapy of pulmonary arteriovenous malformations is effective, with high technical success rate and excellent long-term results.
- The use of AVP and AVP2 devices is safe, with no major complications.

**Table 1.** Demographics and clinical presentations of patients with PAVMs

| Characteristics   | Value      |
|---|------------|
| Sex (M/F), n  | 2/10       |
| Age (years)   |            |
| Mean±SD   | 50.2±13.7  |
| Range   | 21–66      |
| Dyspnea, n/N (%)  | 9/12 (75)  |
| Systemic abscesses, n/N (%)   | 2/12 (16)  |
| TIA/stroke, n/N (%)   | 4/12 (33)  |
| HHT, n/N (%)  | 5/12 (42)  |
| Oxygen saturation before treatment, %   | 92.67±3.17 |
| Oxygen saturation after treatment, %  | 98.08±1.62 |
| PAVM, pulmonary arteriovenous malformation; M, male; F, female; SD, standard deviation; HHT, hereditary hemorrhagic telangiectasia; TIA, transient ischemic attack. |            |

to occlude each PAVM. The location of the device was measured between the distal marker of the device and either the aneurysm sac or the arteriovenous connection.

### Follow-up

Follow-up imaging was done at 3–6 months after the embolization procedure. Imaging follow-up consisted of computed tomography angiography (CTA) of the chest done according to our institution's protocol. The technique of CTA included scans of the chest before and after administration of intravenous nonionic contrast material (Omnipaque 350, GE Healthcare) at a standard dose of 1 mL/kg, and with a rate of injection of 4 mL/s. Axial images were reconstructed at 2 mm thickness. Additional coronal reformatted images were also obtained. Imaging follow-up was continued until there was no significant change in the finding between two consecutive exams.

Clinical follow-up and oxygen saturation measurements were obtained by reviewing the patients' medical records. Data on complications that occurred during the procedure and on follow-up were recorded. Complications were classified as minor or major according to Society of Interventional Radiology clinical practice guidelines (21).

Analysis of the CTA images was based on the categories published by Remy-Jardin et al. (22), which were based on morphologic changes and the perfusion of PAVMs on CTA; (a) successful treatment: marked (>30%) reduction or disappearance of the aneurysmal sac, with no pulmonary or systemic perfusion; (b) partially successful treatment: ≤30% reduction in the size of the aneurysmal sac, with patent feeding artery(ies) distal to the embolic device that is smaller than 3 mm in diameter, which is too small to require repeat intervention; (c) partially failed treatment: substantial reduction in the size of the aneurysmal sac, with patent feeding artery(ies) distal to the embolic device that is larger than 3 mm in diameter, which was large enough to justify repeat intervention; and (d) failed treatment: unchanged or enlarged aneurysmal sac with persistent perfusion. Any case that showed subsequent development of additional feeding artery or development of systemic perfusion supplying the aneurysm was considered as failed treatment.

### Definitions

Persistence of PAVMs was defined as continued perfusion of the PAVM sac on CTA

images. This can be due to recanalization of the feeding artery with flow through the previously placed AVP device(s), pulmonary-to-pulmonary reperfusion in which the feeding artery remains occluded but small feeders developed from adjacent pulmonary arteries or were missed during initial embolization, or, systemic-to-pulmonary reperfusion in which the PAVM persisted due to development of systemic arterial feeders. Immediate technical success was defined as embolization of the PAVM using AVP or AVP2 only without the need to use additional embolization material. Clinical success was defined as either increase in oxygen saturation and/or resolution of symptoms attributed to the PAVM during follow-up after embolization.

### Statistical analysis

Oxygen saturation values were compared before and after embolotherapy using paired Student t test. Central tendency was measured by the mean, while range and standard deviation were used to measure the dispersion of data. The Bland and Altman (23) procedures were used to test differences in dependent variances. Pearson correlation coefficient was used to measure the strength of a linear association between different variables. Analysis was conducted using SAS software (SAS Institute). A difference was considered significant when *P* value was less than 0.05. We studied the

correlation between the number of AVP devices used to achieve successful embolotherapy and their location, and the size of the feeding artery.

### Results

The results are summarized in Tables 1 and 2. The study group included 12 patients with 35 PAVM. All studied PAVMs were simple having a single feeding artery and a single draining vein. Nine patients (75%) had unilateral PAVMs, while three patients (25%) had bilateral PAVMs. Six patients (50%) had single PAVM, one patient (8%) had two PAVMs, and five patients (42%) had more than two PAVMs. Twenty-seven of the PAVMs (77%) were in the lower lung lobes, six of the PAVMs (17%) were in the right middle lobe, and two of the PAVMs (6%) were distributed in the upper lobes. Ten PAVMs (29%) were embolized using AVP only, 24 PAVMs (68%) were embolized using AVP2 only, and one PAVM (3%) was embolized with a combination of AVP and AVP2. Embolization was achieved using a single device in 30 PAVMs (86%) and two devices in five PAVMs (14%). One patient in our series had previous embolization of his PAVM using Azur & Tornado coils, and presented with recanalization of the feeding artery, which was treated using a single AVP2 device.

The mean diameter of the feeding arteries was  $5.1 \pm 2.2$  mm (range, 3–12 mm). There

**Table 2.** Summary of the type of PAVM, type and number of devices used, and the change in size of the aneurysm sac after treatment

| Characteristics  | n=35     |
|--|----------|
| Type of PAVM   |          |
| Simple   | 35 (100) |
| Complex  | 0 (0)    |
| Type of AVP device used  |          |
| AVP  | 10 (29)  |
| AVP2   | 24 (68)  |
| AVP & AVP2   | 1 (3)    |
| Number of AVP devices used   |          |
| Single device  | 30 (86)  |
| Two devices  | 5 (14)   |
| Changes in aneurysm sac size   |          |
| Disappeared  | 22 (63)  |
| Decreased (>30%)   | 12 (34)  |
| Decreased (≤30%)   | 1 (3)    |
| Data are presented as n (%).   |          |
| PAVM, pulmonary arteriovenous malformations; AVP2, Amplatzer vascular plug type 2. |          |

was a weak positive correlation ( $r=0.106$ ,  $P=0.54$ ) between the size of the feeding artery and the number of AVP devices used. The mean diameter of the plugs used was  $8\pm 2.9$  mm (range, 4–16 mm). There was a strong positive correlation ( $r=0.932$ ,  $P < 0.001$ ) between the size of the feeding artery and the size of the AVP device used. The average distance between the distal marker of the AVP and the aneurysm sac or arteriovenous connection was  $11\pm 11.93$  mm (range, 0–44 mm). There was a weak positive correlation ( $r=0.416$ ,  $P=0.012$ ) between the size of the feeding artery and the location of the AVP in relation to the PAVM.

Immediate technical success was 100%, with complete occlusion achieved in all PAVMs. The 30-day mortality was zero, and there was no procedure related mortality. There were no complications during the procedures; however, we encountered 25% minor complications in the immediate post-procedure period. Two patients (17%) had transient elevation in their creatinine level, which may be attributed to contrast material administration during the procedure; however, creatinine level returned to baseline in less than 24 hours after embolization in both patients. One patient (8%) had pleuritic chest pain on the same side of the embolized PAVM, in spite of being on nonsteroidal antiinflammatory drug, and it was resolved within 48 hours without further management.

The mean clinical follow-up period was  $54\pm 24.3$  months (range, 31–97 months). The mean imaging follow-up period was  $21\pm 14.6$  months (range, 3–51 months). Clinical success was encountered in all patients with either increase in oxygen saturation or resolution of their dyspnea. The mean oxygen saturation before embolotherapy was  $92.67\%\pm 3.17\%$ . After embolotherapy with AVP and AVP2 devices, the oxygen saturation levels increased to a mean of  $98.08\% \pm 1.61\%$ , which was statistically significant ( $P < 0.001$ ) (Table 1). The Bland-Altman test also indicated significant post-treatment reduction in the variation in oxygen saturation. Patients who presented with stroke or transient ischemic attack had no further clinical events.

According to the criteria published by Remy-Jardin et al. (22), which are based on the morphologic changes and the perfusion findings in the PAVMs on CTA, successful treatment was encountered in 34 PAVMs (97%). This was evident by complete disappearance of the aneurysmal sac in 22 of

the 34 PAVMs (65%), and a decrease in size of aneurysm sac of  $>30\%$  (range, 54%–84%) in the remaining 12 PAVMs (35%) (Fig. 1). Partially failed treatment was noted in one PAVM, which showed patency of the feeding artery measuring 3.0 mm distal to the AVP plug. A follow-up angiogram was therefore obtained with the intent to treat the recanalized feeding artery. However, there was no evidence of recanalization on the angiogram. Review of the CTA study in retrospect revealed an overlapping artery, which led to this misinterpretation (Fig. 2). Therefore, no intervention was performed, and this case was considered as successful treatment.

Failed treatment was encountered in one PAVM (3%) in a 21-year-old female who suffered from dyspnea and oxygen saturation of 91%. Her CTA showed a large PAVM in the right middle lobe, which was successfully treated with 14 mm and 16 mm AVP2. Follow-up CTA performed four months after the procedure showed 39% decrease in the aneurysm sac; however, there was persistence of the PAVM sac only without recanalization of the feeding artery, which raised suspicion of pulmonary-to-pulmonary or systemic-to-pulmonary reperfusion. Pulmonary angiogram revealed continued occlusion of the feeding pulmonary artery without feeders from adjacent pulmonary arteries; however, a right subclavian angiogram showed that there was systemic supply to the aneurysm sac through branches from the internal mammary and lateral thoracic arteries (Fig. 3). No further treatment was attempted since the persistence of the PAVM through systemic supply does not pose any risk of paradoxical embolization.

## Discussion

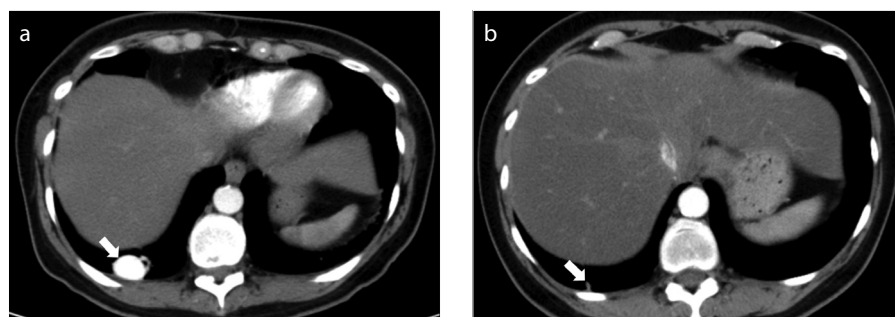
In this study immediate technical success was 100%, with complete occlusion

achieved in all PAVMs. Minor complications were seen in 25% of cases in the immediate post-procedure period. Clinical success was achieved in all patients with statistically significant increase in the oxygen saturation level. Successful treatment was observed in 34 PAVMs (97%), with one failed treatment resulting from systemic-to-pulmonary reperfusion.

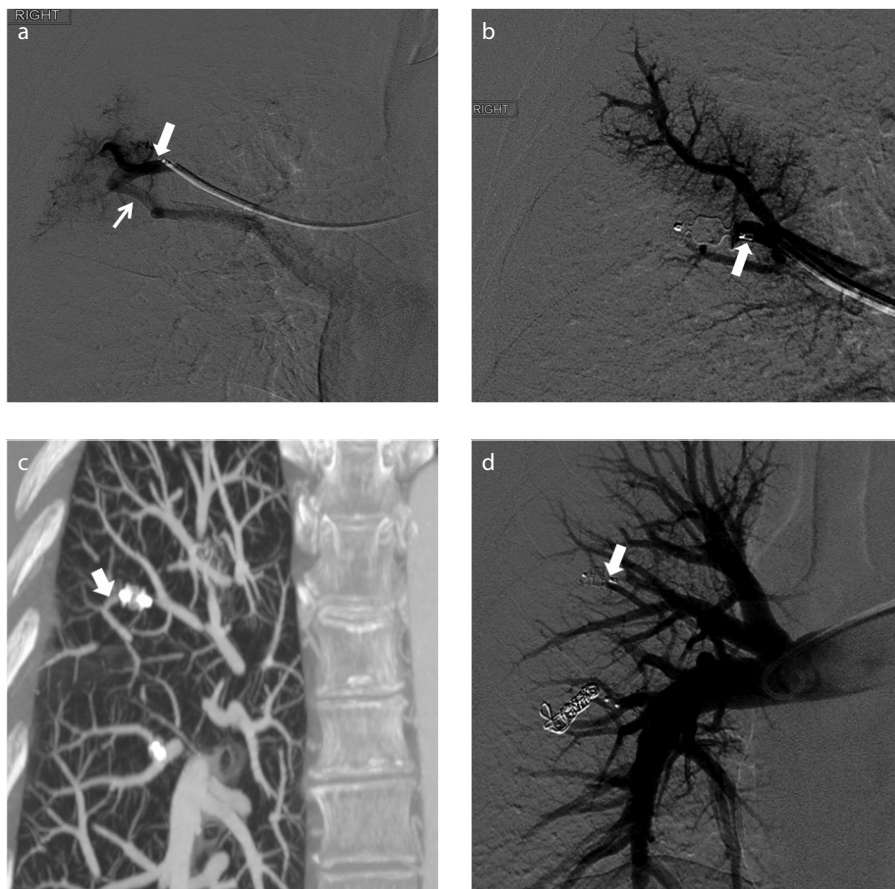
The morphology of PAVMs is variable and could be a large aneurysmal sac, plexiform dilated vascular channels, or a direct communication between artery and vein, which is often dilated and tortuous (24–27). From the treatment standpoint, White et al. (20) classified the PAVMs angioarchitecture as either simple or complex. About 80% to 90% of PAVM are simple having only one feeding segmental artery with a single draining vein. The rest of the PAVMs are complex having several feeding arteries or draining veins. All PAVMs included in our study were simple.

Although most PAVMs, especially if small, remain asymptomatic until the fourth to sixth decade, they are usually associated with significant mortality and morbidity, and therefore, should be readily treated (1). Several studies and case reports have been reported in the literature documenting successful treatment of PAVMs using coils and detachable balloons (7, 28–31). Recently, the AVP became available as a tool in the armamentarium for arterial and venous embolization. Several studies reported the successful use of these devices in embolotherapy of PAVMs (2, 3, 13–15, 17, 18). In our study we used both AVP and AVP2 for embolization of PAVMs.

The AVP offer several advantages over traditional coils in treatment of PAVMs. In the majority of PAVMs, the plugs can be placed very distally yet safely in the feeding artery, since they can be recaptured and re-



**Figure 1. a, b.** A 50-year-old female patient with multiple bilateral pulmonary arteriovenous malformations presenting with dyspnea and low oxygen saturation. Computed tomography (CT) angiography before (a) and 28 months after (b) embolization of one of the pulmonary arteriovenous malformations shows 84% decrease in the aneurysm sac size (arrow in a and b).



**Figure 2. a–d.** A 66-year-old female patient with multiple bilateral pulmonary arteriovenous malformations presenting with dyspnea and low oxygen saturation. Selective pulmonary angiogram of the right upper lobe posterior segmental artery (a) shows a direct communication between the artery (*large arrow*) and the draining vein (*small arrow*) without an aneurysm sac. Selective pulmonary angiogram through the feeding artery (*arrow*) after deployment of the plug (b) shows occlusion of the pulmonary arteriovenous malformation with no contrast seen distal to the plug. Follow-up CT angiography image (c) performed four months after embolotherapy shows recanalization of the previously embolized feeding artery distal to the plug (*arrow*). Subsequent right pulmonary angiogram (d) shows no flow in the feeding artery distal to the AVP (*arrow*), and no evidence of pulmonary-to-pulmonary reperfusion.

positioned for better adjustment (18). This feature is important, since it was documented in a study by Milic et al. (12) that proximal placement of coils in the feeding artery more than 1 cm from the aneurysm sac associated with persistence of PAVMs. Placing the embolic device in the feeding artery close to the venous sac not only reduces the risk of occlusion of the side-branches supplying the adjacent normal lung parenchyma, but may also decrease the risk of persistence of the PAVM sac by preventing recanalization of the feeding artery. Distal occlusion is usually very difficult to accomplish when coils are used, especially when the feeding artery is large because of the increased risk of migration of coils into systemic circulation (1).

In our patients, we were able to place the AVP devices distally in the feeding artery

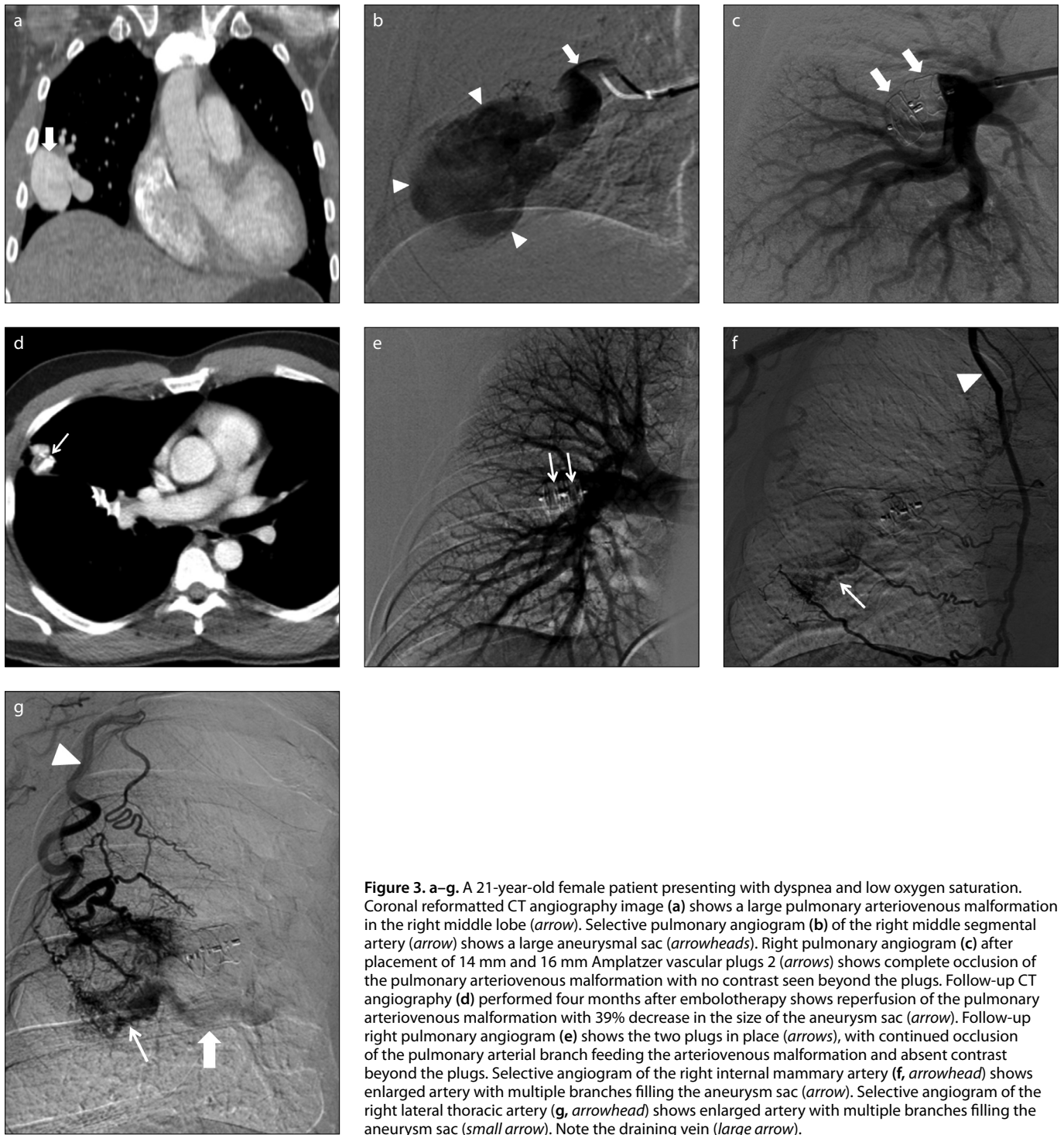
without any fear of device migration. This accounted for the high technical success, and the very low rate of persistence of the PAVMs (3%) encountered in our study. Because of the inherent radial force of the AVP, we did not encounter any complications related to device migration into the systemic circulation with the AVP and we are unaware of any published reports of this particular complication. The high technical success rate was also related to the fact that all our PAVMs were simple in angioarchitecture.

The main concern after successful initial embolization is the persistence of PAVM, which justifies the need for adequate follow-up after treatment (17, 32). Persistence can result from recanalization of the occluded vessels through the previously placed embolic material; interval reperfu-

sion through accessory vessels from the pulmonary or systemic circulation; or incomplete primary treatment, especially in complex PAVMs (2, 8–10). Recanalization of the occluded feeding artery is considered as the most common cause of persistence of PAVM treated with coils, occurring in 88%–91% of these patients (1, 10–12). In our study, persistence occurred in one PAVM, yielding a rate of 3%. A follow-up CTA performed four months after the embolization showed persistence of PAVM sac due to reperfusion through systemic arterial feeders from the internal mammary and lateral thoracic arteries that were filling the PAVM sac. In that case, there was no recanalization of the feeding artery that was previously embolized.

Several studies reported persistence of PAVMs (persistence rate ranged from 0%–7%) following successful embolotherapy using AVP after a short-term follow-up period ranging from 14 to 36 months (3, 17, 18, 33). The most common cause of persistence was recanalization of the feeding artery through the AVP, which was attributed to placement of the AVP more than 1 cm proximal to the aneurysm sac, a similar finding encountered in our study. The short term follow-up, the low number of PAVMs enrolled, and the fact that imaging was sometimes not part of the routine follow-up of PAVMs were significant limitations for several of these studies. Our study has the longest follow-up period (54 months) among the published studies and therefore presents the long-term efficacy of these devices in the treatment of PAVMs. Despite the relatively smaller sample size in published studies on AVP and AVP2 devices compared with coils and detachable balloon, the recanalization rate of AVP and AVP2 devices does not appear to be higher than that of coils and detachable balloons, which ranged between 2.8%–10.3% (1, 20, 34). Trerotola and Peyeritz (35) described embolization of 39 PAVMs using a combination of AVP and coils to prevent recanalization, as they speculated that the thrombogenic effect of the polyester fibers on the coils may augment the mechanical occlusive effect of the plugs.

The limitations of our study include the relatively small sample size due to absent clinical and/or imaging follow-up in some of the patients who received this treatment in our institution. All treated PAVMs in this study were simple in angioarchitecture. The design of our study was retrospective resulting in selection bias, and the inconsis-



**Figure 3. a–g.** A 21-year-old female patient presenting with dyspnea and low oxygen saturation. Coronal reformatted CT angiography image (a) shows a large pulmonary arteriovenous malformation in the right middle lobe (arrow). Selective pulmonary angiogram (b) of the right middle segmental artery (arrow) shows a large aneurysmal sac (arrowheads). Right pulmonary angiogram (c) after placement of 14 mm and 16 mm Amplatzer vascular plugs 2 (arrows) shows complete occlusion of the pulmonary arteriovenous malformation with no contrast seen beyond the plugs. Follow-up CT angiography (d) performed four months after embolotherapy shows reperfusion of the pulmonary arteriovenous malformation with 39% decrease in the size of the aneurysm sac (arrow). Follow-up right pulmonary angiogram (e) shows the two plugs in place (arrows), with continued occlusion of the pulmonary arterial branch feeding the arteriovenous malformation and absent contrast beyond the plugs. Selective angiogram of the right internal mammary artery (f, arrowhead) shows enlarged artery with multiple branches filling the aneurysm sac (arrow). Selective angiogram of the right lateral thoracic artery (g, arrowhead) shows enlarged artery with multiple branches filling the aneurysm sac (small arrow). Note the draining vein (large arrow).

tency in the technique of embolization is an inherent limitation.

In conclusion, the use of AVP and AVP2 for embolotherapy of PAVMs is effective, with high technical success rate and excellent long-term results. The low persistence rate of these devices is comparable with the published studies on coils and detachable balloons, with one caveat

being the shorter follow-up interval compared with the previous studies using coils and detachable balloons. The use of these devices is also safe with no major complications.

#### Conflict of interest disclosure

Ahmed Kamel Abdel Aal and Souheil Saddekni are consultants for St Jude Medical. The other authors declared no conflicts of interest.

#### References

1. Mager J, Overtoom T, Lammers H, Westermann C. Embolotherapy of pulmonary arteriovenous malformations: long-term results in 112 patients. *J Vasc Interv Radiol* 2004; 15:451–456. [\[CrossRef\]](#)
2. Abdel Aal A, Hamed M, Biosca R, Saddekni S, Raghuram K. Occlusion time for amplatzer vascular plug in the management of pulmonary arteriovenous malformations. *AJR Am J Roentgenol* 2009; 192:793–799. [\[CrossRef\]](#)

3. Letourneau-Guillon L, Faughnan M, Soulez G, et al. Embolization of pulmonary arteriovenous malformations with amplatzer vascular plugs: Safety and midterm effectiveness. *J Vasc Interv Radiol* 2010; 21:649–656. [\[CrossRef\]](#)
4. Porstmann W. Therapeutic embolization of arteriovenous pulmonary fistula by catheter technique. In: Kelop O, ed. *Current Concepts in Pediatric Radiology*. Berlin: Springer, 1977; 23–31. [\[CrossRef\]](#)
5. Apostolopoulou SC, Kelekis NL, Papagiannis J, Hausdorf G, Rammos S. Transcatheter occlusion of a large pulmonary arteriovenous malformation with use of a Cardioseal device. *J Vasc Interv Radiol* 2001; 12:767–769. [\[CrossRef\]](#)
6. Saluja S, Henderson J, White RI Jr. Embolotherapy in the bronchial and pulmonary circulations. *Radiol Clin North Am* 2000; 38:425–448. [\[CrossRef\]](#)
7. Dutton JA, Jackson JE, Hughes JM, et al. Pulmonary arteriovenous malformations: results of treatment with coil embolization in 53 patients. *AJR Am J Roentgenol* 1995; 165:1119–1125. [\[CrossRef\]](#)
8. Swanson KL, Prakash UB, Stanson AW. Pulmonary arteriovenous fistulas: Mayo clinic experience, 1982–1997. *Mayo Clinic Proc* 1999; 74:671–680. [\[CrossRef\]](#)
9. Moussouttas M, Fayad P, Rosenblatt M, et al. Pulmonary arteriovenous malformations: cerebral ischemia and neurologic manifestations. *Neurology* 2000; 55:959–964. [\[CrossRef\]](#)
10. Woodward CS, Pyeritz RE, Chittams JL, Trerotola SO. Treated pulmonary arteriovenous malformations: patterns of persistence and associated retreatment success. *Radiology* 2013; 269:919–926. [\[CrossRef\]](#)
11. Sagara K, Miyazono N, Inoue H, Ueno K, Nishida H, Nakajo M. Recanalization after coil embolotherapy of pulmonary arteriovenous malformations: study of long-term outcome and mechanism of recanalization. *AJR Am J Roentgenol* 1998; 170:727–730. [\[CrossRef\]](#)
12. Milic A, Chan R, Cohen J, Faughnan M. Reperfusion of pulmonary arteriovenous malformations after embolotherapy. *J Vasc Interv Radiol* 2005; 16:1675–1683. [\[CrossRef\]](#)
13. Rossi M, Rebonato A, Greco L, et al. A new device for vascular embolization: report on case of two pulmonary arteriovenous fistulas embolization using Amplatzer vascular plug. *Cardiovasc Intervent Radiol* 2006; 29:902–906. [\[CrossRef\]](#)
14. Cil B, Canyigit M, Ozkan OS, Pamuk GA, Dogan R. Bilateral multiple pulmonary arteriovenous malformations: endovascular treatment with the Amplatzer vascular plug. *J Vasc Interv Radiol* 2006; 17:141–145. [\[CrossRef\]](#)
15. Beck A, Dagan T, Matitiau A, Bruckheimer E. Transcatheter closure of pulmonary arteriovenous malformations with Amplatzer devices. *Catheter Cardiovasc Interv* 2006; 67:932–937. [\[CrossRef\]](#)
16. Hinterseer M, Becker A, Barth AS, Kozlik-Feldmann R, Wintersperger BJ, Behr J. Interventional embolization of a giant pulmonary arteriovenous malformation with right-left-shunt associated with hereditary hemorrhagic telangiectasia. *Clin Res Cardiol* 2006; 95: 174–178. [\[CrossRef\]](#)
17. Tapping C, Ettles D, Robinson G. Long-term follow-up of treatment of pulmonary arteriovenous malformations with amplatzer vascular plug and amplatzer vascular plug II devices. *J Vasc Interv Radiol* 2011; 22:1740–1746. [\[CrossRef\]](#)
18. Hart J, Aldin Z, Braude P, Shovlin C, Jackson J. Embolization of pulmonary arteriovenous malformations using the Amplatzer vascular plug: Successful treatment of 69 consecutive patients. *Eur Radiol* 2010; 20:2663–2670. [\[CrossRef\]](#)
19. Faughnan ME, Palda VA, Garcia-Tsao G, et al. International guidelines for the diagnosis and management of hereditary haemorrhagic telangiectasia. *J Med Genet* 2011; 48:73–87. [\[CrossRef\]](#)
20. White RI Jr, Pollak JS, Wirth JA. Pulmonary arteriovenous malformations: diagnosis and transcatheter embolotherapy. *J Vasc Interv Radiol* 1996; 7:787–804. [\[CrossRef\]](#)
21. Sacks D, McClenny TE, Cardella JF, Lewis CA. Society of Interventional Radiology clinical practice guidelines. *J Vasc Interv Radiol* 2003; 14(Suppl):S199–S202. [\[CrossRef\]](#)
22. Remy-Jardin M, Dumont P, Brillet P, Dupuis P, Duhamel A, Remy J. Pulmonary arteriovenous malformations treated with embolotherapy: Helical CT evaluation of long-term effectiveness after 2–21-year follow-up. *Radiology* 2006; 239:576–585. [\[CrossRef\]](#)
23. Altman DG, Bland JM. Measurement in medicine: the analysis of method comparison studies. *The Statistician* 1983; 32:307–317. [\[CrossRef\]](#)
24. Shovlin CL, Letarte M. Hereditary haemorrhagic telangiectasia and pulmonary arteriovenous malformations: issues in clinical management and review of pathogenic mechanisms. *Thorax* 1999; 54:714–729. [\[CrossRef\]](#)
25. White RI, Lynch-Nyhan A, Terry P, et al. Pulmonary arteriovenous malformations: techniques and long-term outcome of embolotherapy. *Radiology* 1988; 169:663–669. [\[CrossRef\]](#)
26. Anabtawi I, Ellison R, Ellison L. Pulmonary arteriovenous aneurysms and fistulas: anatomical variations, embryology, and classification. *Ann Thorac Surg* 1956; 1:277–285. [\[CrossRef\]](#)
27. Hales R. Multiple small arteriovenous fistulae of the lungs. *Am J Pathol* 1956; 32:927–943.
28. Jackson J, Whyte M, Allison D, Hughes J. Coil embolization of pulmonary arteriovenous malformations. *Cor Vasa* 1990; 32:191–196.
29. Terry P, White R, Barth K, Kaufman S, Mitchell S. Pulmonary arteriovenous malformations: physiologic observations and results of therapeutic balloon embolization. *N Engl J Med* 1983; 308:1197–1200. [\[CrossRef\]](#)
30. Remy-Jardin M, Wattinne L, Remy J. Transcatheter occlusion of pulmonary arterial circulation and collateral supply: failures, incidents, and complications. *Radiology* 1991; 180:699–705. [\[CrossRef\]](#)
31. Pollak J. Clinical results of transvenous systemic embolotherapy with a neuroradiologic detachable balloon. *Radiology* 1994; 19:477–482. [\[CrossRef\]](#)
32. Kawai T, Shimohira M, Kan H, et al. Feasibility of time-resolved MR angiography for detecting recanalization of pulmonary arteriovenous malformations treated with embolization with platinum coils. *J Vasc Interv Radiol* 2014; 25:1339–1347. [\[CrossRef\]](#)
33. Kucukay F, Özdemir M, Şenol E, Okten S, Eren M, Karan A. Large pulmonary arteriovenous malformations: long-term results of embolization with amplatzer vascular plugs. *J Vasc Interv Radiol* 2014; 25:1327–1332. [\[CrossRef\]](#)
34. Pollak JS, Saluja S, Thabet A, Henderson KJ, Denbow N, White RI Jr. Clinical and anatomic outcomes after embolotherapy of pulmonary arteriovenous malformations. *J Vasc Interv Radiol* 2006; 17:35–44. [\[CrossRef\]](#)
35. Trerotola SO, Pyeritz RE. Does use of coils in addition to Amplatzer Vascular Plugs prevent recanalization? *AJR Am J Roentgenol* 2010; 195:766–771. [\[CrossRef\]](#)