

University of Groningen

## Bronchoscopic lung volume reduction treatment in severe COPD: from improving patient selection to management of complications

Koster, Theodoor David

DOI:  
[10.33612/diss.762939378](https://doi.org/10.33612/diss.762939378)

**IMPORTANT NOTE:** You are advised to consult the publisher's version (publisher's PDF) if you wish to cite from it. Please check the document version below.

*Document Version*  
Publisher's PDF, also known as Version of record

*Publication date:*  
2023

[Link to publication in University of Groningen/UMCG research database](#)

*Citation for published version (APA):*

Koster, T. D. (2023). *Bronchoscopic lung volume reduction treatment in severe COPD: from improving patient selection to management of complications*. [Thesis fully internal (DIV), University of Groningen]. University of Groningen. <https://doi.org/10.33612/diss.762939378>

### Copyright

Other than for strictly personal use, it is not permitted to download or to forward/distribute the text or part of it without the consent of the author(s) and/or copyright holder(s), unless the work is under an open content license (like Creative Commons).

The publication may also be distributed here under the terms of Article 25fa of the Dutch Copyright Act, indicated by the "Taverne" license. More information can be found on the University of Groningen website: <https://www.rug.nl/library/open-access/self-archiving-pure/taverne-amendment>.

### Take-down policy

If you believe that this document breaches copyright please contact us providing details, and we will remove access to the work immediately and investigate your claim.

*Downloaded from the University of Groningen/UMCG research database (Pure): <http://www.rug.nl/research/portal>. For technical reasons the number of authors shown on this cover page is limited to 10 maximum.*

# **Bronchoscopic lung volume reduction treatment in severe COPD: from improving patient selection to management of complications**

**T. David Koster**





**Bronchoscopic lung volume reduction treatment  
in severe COPD: from improving patient  
selection to management of complications**

T. David Koster

Printed by Ipskamp Printing  
Enschede, the Netherlands

Design & layout Bianca Pijl, [www.pijlldesign.nl](http://www.pijlldesign.nl)  
Groningen, the Netherlands

© Copyright: 2023 T.D. Koster, Groningen, the Netherlands  
All rights reserved. No part of this thesis may be reproduced, stored in a retrieval system, or transmitted in any form or by any means, without prior written permission of the author, or when appropriate, of the publishers of the publications included in this thesis.



rijksuniversiteit  
groningen

# **Bronchoscopic lung volume reduction treatment in severe COPD: from improving patient selection to management of complications**

Proefschrift

ter verkrijging van de graad van doctor aan de  
Rijksuniversiteit Groningen  
op gezag van de  
rector magnificus prof. dr. C. Wijmenga  
en volgens besluit van het College voor Promoties.

De openbare verdediging zal plaatsvinden op

woensdag 27 september 2023 om 16.15 uur

door

**Theodoor David Koster**

geboren op 12 december 1984  
te Ruinen

**Promotores**

Prof. dr. D.J. Slebos

Prof. dr. H.A.M. Kerstjens

**Copromotor**

Dr. K. Klooster

**Beoordelingscommissie**

Prof. dr. P.L. Shah

Prof. dr. P.J. Wijkstra

Prof. dr. L.E.G.W. Vanfleteren





## **Paranimfen**

Martin Olieman Bonne

Jelmer Soes

## TABLE OF CONTENTS


Chapter 1	<b>General introduction</b>	11
Chapter 2	<b>Bronchoscopic Lung Volume Reduction for Emphysema: Review and Update</b> T.D. Koster, M. van Dijk, D.J. Slebos. <i>Published in: Semin Respir Crit Care Med (2022)</i>	19
Chapter 3	<b>The fissure: interlobar collateral ventilation and implications for endoscopic therapy in emphysema</b> T.D. Koster, D.J. Slebos. <i>Published in: Int J Chron Obstruct Pulmon Dis (2016)</i>	43
Chapter 4	<b>Predicting Lung Volume Reduction after Endobronchial Valve Therapy Is Maximized Using a Combination of Diagnostic Tools</b> T.D. Koster, E.M. van Rikxoort, R.H. Huebner, F. Doellinger, K. Klooster, J.P. Charbonnier, S. Radhakrishnan, F.J.F. Herth, D.J. Slebos. <i>Published in: Respiration (2016)</i>	61
Chapter 5	<b>An Integrative Approach of the Fissure Completeness Score and Chartis Assessment in Endobronchial Valve Treatment for Emphysema</b> K. Klooster, T.D. Koster, C. Ruwwe-Glösenkamp, D. Theilig, F. Doellinger, J. Saccomanno, H.A.M. Kerstjens, D.J. Slebos, R.H. Huebner. <i>Published in: Int J Chron Obstruct Pulmon Dis (2020)</i>	77
Chapter 6	<b>An adjusted and time-saving method to measure collateral ventilation with Chartis</b> T.D. Koster, K. Klooster, H. McNamara, N.S. Shargill, S. Radhakrishnan, R. Olivera, D.J. Slebos. <i>Published in: ERJ Open Res (2021)</i>	97
Chapter 7	<b>Temporary Right Middle Lobe Occlusion with a Blocking Device to Enable Collateral Ventilation Measurement of the Right Major Fissure</b> J.B.A. Welling, T.D. Koster, J.E. Hartman, M. van Dijk, H.A.M. Kerstjens, K. Klooster, D.J. Slebos. <i>Published in: Respiration (2020)</i>	111

## TABLE OF CONTENTS

Chapter 8	<b>HRCT-Approximated Perfusion is Comparable to Nuclear Perfusion Imaging in Severe COPD</b>	121
	T.D. Koster, J.P. Charbonnier, J. Pruijm, H.A. Gietema, R. Posthuma, L.E.G.W. Vanfleteren, M. van Dijk, K. Klooster, D.J. Slebos. <i>Published in: Am J Respir Crit Care Med (2023)</i>	
Chapter 9	<b>Endobronchial valve therapy for severe emphysema: an overview of valve-related complications and its management</b>	131
	T.D. Koster, K. Klooster, N.H.T. Ten Hacken, M. van Dijk, D.J. Slebos. <i>Published in: Expert Rev Respir Med (2020)</i>	
Chapter 10	<b>Biodegradable stent placement for airway kinking after bronchoscopic lung volume reduction treatment</b>	157
	T.D. Koster, K. Klooster, M. van Dijk, D.J. Slebos. <i>Published in: Ann Thorac Surg (2022)</i>	
Chapter 11	<b>A multicenter, prospective, single-arm clinical investigation of a modified staged treatment algorithm using the AeriSeal system - The STAGE trial</b>	165
	T.D. Koster, R. Eberhardt, R.H. Huebner, A. Valipour, F. Herth, K. Klooster, N.S. Shargill, S. Radhakrishnan, D.J. Slebos <i>Published in: Respir Med (2022)</i>	
Chapter 12	<b>Summary</b>	173
Chapter 13	<b>General discussion and future perspectives</b>	181
Appendices		195
	<b>Nederlandse samenvatting</b>	197
	<b>Dankwoord</b>	205
	<b>Curriculum vitae</b>	209
	<b>Publications</b>	211

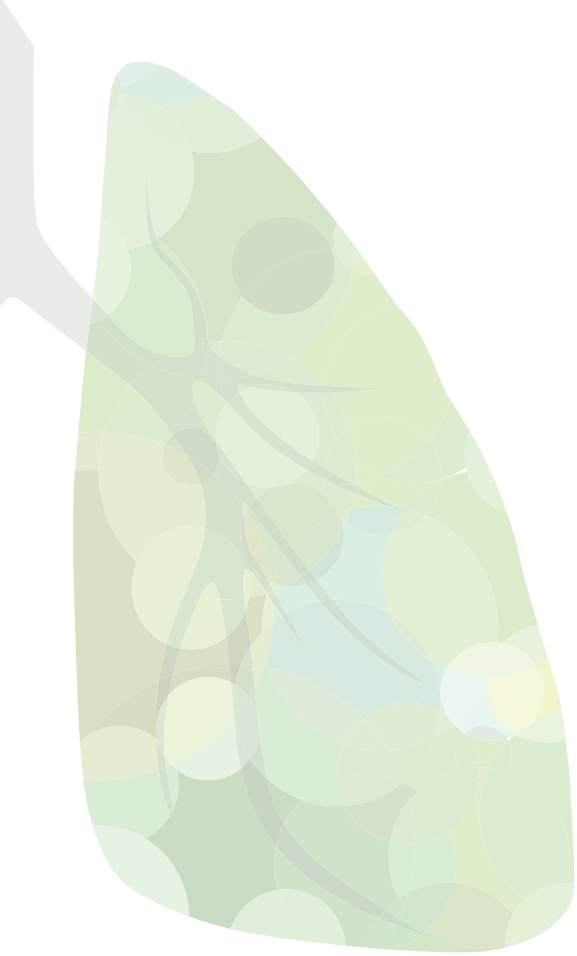

1



# CHAPTER 1

## General introduction





## COPD

Chronic Obstructive Pulmonary Disease (COPD) is a heterogeneous disease, characterized by a persistent airflow obstruction. Although COPD is largely a preventable disease, it is currently the third cause of death worldwide and is a major cause of chronic morbidity and mortality.<sup>1</sup> The chronic airway limitation is caused by a combination of small airways disease and parenchymal destruction with loss of alveoli (emphysema), due to chronic inflammation secondary to exposure to noxious stimuli.<sup>2,3</sup> This process leads to decrease of lung elastic recoil, increased airway resistance, collapse of airways in expiration and reduction in gas exchanging surface.<sup>1</sup>

Patients with COPD can suffer from many symptoms, including invalidating dyspnea, chronic cough and sputum production, recurrent lower respiratory tract infections, loss of energy and fatigue, all leading to a major impairment of their health-related quality of life.<sup>4</sup>

There are numerous pharmacological and non-pharmacological treatment options for COPD. Smoking cessation is essential; other non-pharmacological treatments include improvement of physical activity using physiotherapy, pulmonary rehabilitation, education and nutritional support. Optimal pharmacological treatments include the use of long acting bronchodilators (both muscarinic antagonists and beta agonists), inhaled corticosteroids and in frequent exacerbating patients maintenance antibiotics (macrolides).<sup>1</sup> However, it is important to realize that COPD is a 'mixed bag' of different phenotypes, with many different treatable traits which can be identified separately and treated accordingly.<sup>4</sup>

### Hyperinflation

Static hyperinflation is defined as an increased volume of residual air in the lungs at the end of spontaneous expiration, with increased residual volume (RV) and end-expiratory lung volume (EELV).<sup>5,6</sup> It is caused by the combination of the increased airways resistance and emphysematous destruction with reduced elastic recoil.<sup>5,6</sup> Dynamic hyperinflation means there is a temporary extra increase in EELV during periods of increased ventilation, for example during exercise.<sup>5</sup> As a result, both increased static and dynamic hyperinflation lead to dyspnea, a reduced exercise capacity and lower quality of life. Furthermore, increased hyperinflation is an independent predictor of respiratory and all-cause mortality in COPD.<sup>7</sup>

### Lung volume reduction treatment

In some patients with severe COPD, characterized by hyperinflation and emphysema, lung volume reduction therapy may be a treatment option. The purpose of this treatment is to reduce hyperinflation, which results in an increased elastic recoil pressure, improvement of airflow obstruction, decrease of ventilation and perfusion mismatch and improved inspiratory muscle mechanics. This can lead to a reduction in dyspnea, improvement of lung function, increase in exercise capacity and improvement of quality of life.<sup>8,9</sup>

There are several treatment options to reduce hyperinflation, both surgical and bronchoscopic. Bronchoscopic lung volume reduction options include treatment with one-way valves, coils, sealant or steam and airway bypass.<sup>8,10-13</sup> Multiple of these treatment options are currently



under investigation, or have been in the past. Treatment with valves has been investigated the most thoroughly, in multiple randomized controlled trials. This treatment has been incorporated in the COPD treatment guidelines and is covered by health insurance in the Netherlands since 2017.<sup>1</sup> The goal of this treatment is to bronchoscopically occlude the airways of the most emphysematous lobe with one-way valves, to induce an atelectasis of this lobe which leads to the desired lung volume reduction and therefore reduces hyperinflation. This approach has been proven successful in multiple clinical trials, showing an improved pulmonary function, exercise capacity and quality of life.<sup>8,14-17</sup> To achieve these beneficiary outcomes with endobronchial valves, careful patient selection is of crucial importance.

### **Patient selection**

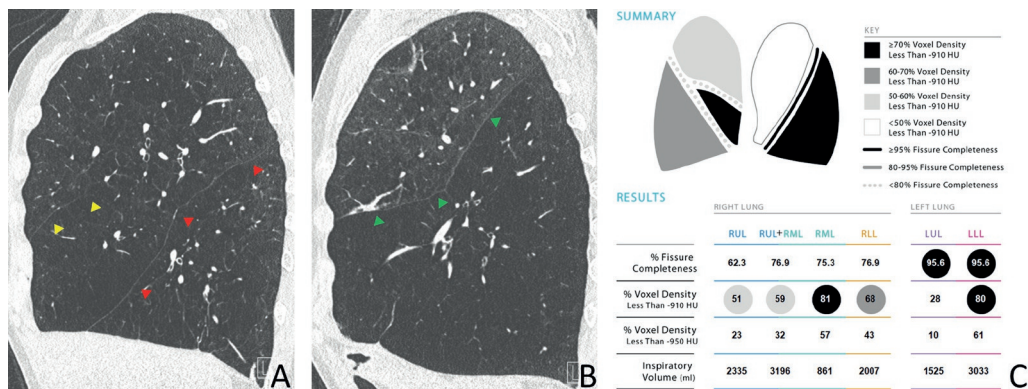
Treatment with valves is proven to be effective in symptomatic COPD patients with emphysema, hyperinflation and absence of collateral ventilation between the target lobe and the ipsilateral lobe(s).<sup>8,14</sup> The high resolution computed tomography (HRCT) scan of the lungs is the most important diagnostic tool to assess for eligibility for treatment. The HRCT-scan can be evaluated for emphysematous destruction of the lungs and lobes to select the treatment target lobe. Furthermore, the fissure integrity can be assessed to predict the presence of collateral ventilation, as treatment with valves is only successful if there is no collateral ventilation between the treatment target lobe and the ipsilateral lobe(s).<sup>8,18</sup>

This became relevant since the first randomized controlled trial for treatment with endobronchial valves (VENT) was published in 2010.<sup>19</sup> This study showed a significant but moderate improvement, however, post hoc analysis of the VENT data suggested that endobronchial valve treatment was much more effective in patients with a complete fissure between the treatment lobe and the adjacent lobe(s). This is due to the fact that in case of incomplete fissures there is collateral ventilation between the treatment target lobe and the ipsilateral lobe(s), resulting in no volume reduction despite endobronchial valve treatment, due to this 'backdoor' air flow which keeps the treated lobe inflated. Collateral ventilation can be measured directly during bronchoscopy (by using the Chartis assessment), but this requires a bronchoscopic intervention. Therefore, it is of importance to be able to predict the presence or absence of collateral ventilation and avoid bronchoscopies in patients who are not eligible for treatment.

Follow-up studies suggested that if a fissure is  $\geq 90\%$  complete, a patient could be treated with valves. However, a significant proportion of the treated patients with a  $>90\%$  complete fissure still showed no lung volume reduction effect due to collateral ventilation.<sup>20</sup> Furthermore, the percentage of fissure completeness is hard to predict based on visual examination of the HRCT and there is rather high interobserver variability.<sup>21</sup>

Therefore, there was need for the use of quantitative CT-scan (QCT) analysis to quantify the completeness of fissures with improved reliability and less interobserver variability and to investigate the predictive value of the fissure completeness score for the presence of collateral ventilation, which is an important part of this thesis.

Furthermore the QCT analysis can provide quantified information of the amount of emphysema per lobe to help select the lobe with most destruction and the volume per lobe (Figure 1). Currently, QCT analysis has a central place in the assessment of eligibility for treatment with valves and is recommended in all patients who are evaluated for lung volume reduction.



**Figure 1** - CT-scan and Quantitative CT-scan (QCT) analysis of a patient with severe COPD.

A. sagittal view of the right lung, showing emphysema and an incomplete fissure between the right upper lobe and middle lobe (yellow arrows). Red arrows represent the right major fissure. B. sagittal view of the left lung showing severe emphysema in the left lower lobe and a (near) complete fissure (green arrows). C. QCT of this CT-scan shows the % fissure completeness per lobe, % voxel density less than -910 and -950 Hounsfield Units (HU) and the volumes per lobe. In this case, the emphysematous destruction is most prominent in the left lower lobe and the fissure is near complete.

**Abbreviations:** RUL=right upper lobe; RML = right middle lob; RLL = right lower lobe; LUL = left upper lobe; LLL = left lower lobe (adapted from the StratX platform, PulmonX Inc., CA, USA).

## OUTLINE OF THIS THESIS

The main aim of this thesis is to improve the clinical use of the quantitative CT-scan analysis, the Chartis measurement of collateral ventilation in patient selection for treatment with one-way valves and to provide insight regarding the management of complications after treatment with valves.

In **chapter 2** we perform a review and update of the literature regarding the various bronchoscopic lung volume reduction treatment options.

As mentioned above, treatment with valves is only effective in patients without collateral ventilation, which can be measured during the bronchoscopy with a Chartis assessment, but can be predicted based on the fissure integrity on HRCT.<sup>19</sup> Measurement of collateral

ventilation and the fissure integrity is a crucial part of patient selection for treatment with valves. In **chapter 3** we describe in detail the concept of collateral ventilation and the importance of the fissures. **Chapter 4** and **5** are studies regarding the predictive value of the fissure completeness score in combination with the Chartis-assessment and how to incorporate this in clinical practice. In **chapter 6** and **7** we investigate methods to further optimize the Chartis assessment and its interpretation by using the VT20 feature (the amount of air released from the occluded lobe per 20 seconds).

Furthermore, measuring the perfusion of the lungs and individual lobes is an important additional tool for patient selection. To be able to reduce the number of diagnostic tests in de endobronchial valve work-up, in **chapter 8** we compare the quantitative approximation of perfusion from the HRCT to the perfusion measured with perfusion scintigraphy and SPECT-CT, this to potentially avoid future use of additional nuclear perfusion scanning.


After treatment with valves, there are various important aspects during follow up and possible complications that need to be accounted for. In **chapter 9**, we make an overview of valve related complications and its management and **chapter 10** is a case report of a rare complication.

Finally, in **chapter 11** we describe a study in which patients with severe COPD who were not eligible for treatment with valves, were treated with an alternative intervention: treatment with the AeriSeal system.

## REFERENCES

- 1 Singh, D., et al., Global Strategy for the Diagnosis, Management, and Prevention of Chronic Obstructive Lung Disease: the GOLD science committee report 2019. *Eur Respir J*, 2019. 53(5).
- 2 McDonough, J.E., et al., Small-airway obstruction and emphysema in chronic obstructive pulmonary disease. *N Engl J Med*, 2011. 365(17): p. 1567-75.
- 3 Hogg, J.C., et al., The nature of small-airway obstruction in chronic obstructive pulmonary disease. *N Engl J Med*, 2004. 350(26): p. 2645-53.
- 4 van Dijk, M., et al., Treatment of severe stable COPD: the multidimensional approach of treatable traits. *ERJ Open Res*, 2020. 6(3).
- 5 Gagnon, P., et al., Pathogenesis of hyperinflation in chronic obstructive pulmonary disease. *Int J Chron Obstruct Pulmon Dis*, 2014. 9: p. 187-201.
- 6 van Dijk, M., et al., Change in Dynamic Hyperinflation After Bronchoscopic Lung Volume Reduction in Patients with Emphysema. *Lung*, 2020. 198(5): p. 795-801.
- 7 Casanova, C., et al., Inspiratory-to-total lung capacity ratio predicts mortality in patients with chronic obstructive pulmonary disease. *Am J Respir Crit Care Med*, 2005. 171(6): p. 591-7.
- 8 Klooster, K., et al., Endobronchial Valves for Emphysema without Interlobar Collateral Ventilation. *N Engl J Med*, 2015. 373(24): p. 2325-35.
- 9 van Geffen, W.H., et al., Surgical and endoscopic interventions that reduce lung volume for emphysema: a systemic review and meta-analysis. *Lancet Respir Med*, 2019. 7(4): p. 313-324.
- 10 Come, C.E., et al., A randomised trial of lung sealant versus medical therapy for advanced emphysema. *Eur Respir J*, 2015. 46(3): p. 651-62.
- 11 Snell, G., et al., Bronchoscopic thermal vapour ablation therapy in the management of heterogeneous emphysema. *Eur Respir J*, 2012. 39(6): p. 1326-33.
- 12 Sciruba, F.C., et al., Effect of Endobronchial Coils vs Usual Care on Exercise Tolerance in Patients With Severe Emphysema: The RENEW Randomized Clinical Trial. *JAMA*, 2016. 315(20): p. 2178-89.
- 13 Shah, P.L., et al., Bronchoscopic lung-volume reduction with Exhale airway stents for emphysema (EASE trial): randomised, sham-controlled, multicentre trial. *Lancet*, 2011. 378(9795): p. 997-1005.
- 14 Valipour, A., et al., Endobronchial Valve Therapy in Patients with Homogeneous Emphysema. Results from the IMPACT Study. *Am J Respir Crit Care Med*, 2016. 194(9): p. 1073-1082.
- 15 Kemp, S.V., et al., A Multicenter Randomized Controlled Trial of Zephyr Endobronchial Valve Treatment in Heterogeneous Emphysema (TRANSFORM). *Am J Respir Crit Care Med*, 2017. 196(12): p. 1535-1543.
- 16 Davey, C., et al., Bronchoscopic lung volume reduction with endobronchial valves for patients with heterogeneous emphysema and intact interlobar fissures (the BeLieVeR-HiFi study): a randomised controlled trial. *Lancet*, 2015. 386(9998): p. 1066-73.
- 17 Criner, G.J., et al., A Multicenter Randomized Controlled Trial of Zephyr Endobronchial Valve Treatment in Heterogeneous Emphysema (LIBERATE). *Am J Respir Crit Care Med*, 2018. 198(9): p. 1151-1164.
- 18 Koster, T.D., et al., Predicting Lung Volume Reduction after Endobronchial Valve Therapy Is Maximized Using a Combination of Diagnostic Tools. *Respiration*, 2016. 92(3): p. 150-7.
- 19 Sciruba, F.C., et al., A randomized study of endobronchial valves for advanced emphysema. *N Engl J Med*, 2010. 363(13): p. 1233-44.
- 20 Gompelmann, D., et al., Diagnostic performance comparison of the Chartis System and high-resolution computerized tomography fissure analysis for planning endoscopic lung volume reduction. *Respirology*, 2014. 19(4): p. 524-30.
- 21 Koenigkam-Santos, M., et al., Incomplete fissures in severe emphysematous patients evaluated with MDCT: incidence and interobserver agreement among radiologists and pneumologists. *Eur J Radiol*, 2012. 81(12): p. 4161-6.

2



## CHAPTER 2

# Bronchoscopic Lung Volume Reduction for Emphysema: Review and Update



**T. David Koster**  
Marlies Van Dijk  
Dirk-Jan Slebos

*Adapted from Semin Respir Crit Care Med. 2022 Aug;43(4):541-551*

## **ABSTRACT**

In carefully selected patients with severe chronic obstructive pulmonary disease, characterized by emphysema and hyperinflation, lung volume reduction is an option to reduce lung hyperinflation, improve lung function, quality of life, and exercise capacity. Currently, there are several bronchoscopic and surgical treatment options to achieve lung volume reduction. It is important to carefully phenotype these patients, to select the optimal treatment option, with consideration of possible adverse events or contraindications, and it is highly recommended to discuss these treatment strategies in a multidisciplinary team. The treatment with one-way endobronchial valves has been investigated most extensively and more data are available regarding the treatment of more “marginal cases,” or subsequent lung volume reduction surgery. Other bronchoscopic lung volume reduction options include treatment with coils, thermal vapor ablation, and sclerosant agents. In this review, we aim to summarize the current clinical evidence on the bronchoscopic lung volume reduction therapies and important aspects regarding optimal patient selection.

## INTRODUCTION

For carefully selected patients with severe chronic obstructive pulmonary disease (COPD), characterized by advanced emphysema and hyperinflation, lung volume reduction may be an additional treatment option if patients remain symptomatic despite smoking cessation, pulmonary rehabilitation, and optimal pharmacological therapy.<sup>1</sup> Next to the known surgical lung volume reduction techniques, over the past decade, multiple innovative therapeutic bronchoscopic therapies have been developed, all of which are aimed at decreasing lung hyperinflation to improve lung function, ultimately leading to an improved exercise capacity and quality of life. Currently, there are a few options for bronchoscopic lung volume reduction, with all having different mechanisms of action based on different emphysema phenotypes. Therefore, it is crucial to phenotype the type of COPD and emphysema carefully to provide a personalized therapy for patients.<sup>2</sup>

The currently most widely used and most investigated treatment option is the placement of endobronchial one-way valves.<sup>3-5</sup> With this treatment, nitinol-silicone endobronchial valves are placed in all segmental bronchi of a treatment target lobe to achieve a lobar atelectasis, leading to the desired lung volume reduction.<sup>6,7</sup> Other possible options are bronchoscopic treatments with lung volume reduction coils, vapor ablation or biological lung volume reduction using AeriSeal. Moreover, lung volume reduction surgery (LVRS) might be an important additional treatment option if less invasive options fail or are not possible. A patient who is highly symptomatic despite optimal treatment with regular means, and has severe hyperinflation with reduced exercise tolerance, may be a candidate for further interventional therapy.<sup>4</sup> To optimally select the best treatment option with consideration of possible adverse events, it is highly recommended to present these patients in a multidisciplinary board including (interventional) pulmonologists, radiologists, and thoracic surgeons. This review will focus on the current most important lung volume reduction therapies and important aspects regarding patient selection.

## TREATMENT OPTIONS FOR EMPHYSEMA

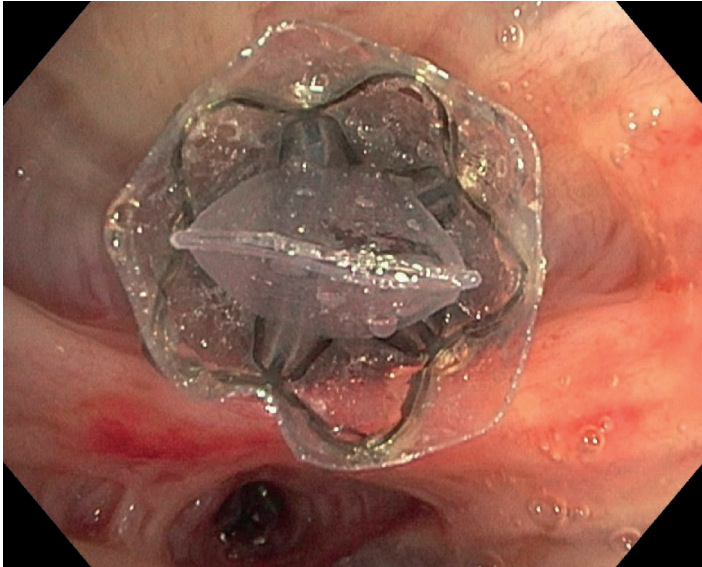
### Endobronchial Valves

Bronchoscopic lung volume reduction with one-way valves is a treatment option for carefully selected patients with severe emphysema and hyperinflation. In 2003, two studies were published regarding the treatment with one-way valves.<sup>8,9</sup> Since then, several RCTs have been performed regarding the treatment with one-way endobronchial valves (Zephyr EBV [Pulmonx, Redwood City, CA] or the Spiration Valve System [SVS, Olympus, Redmond, WA]) in patients with severe emphysema.<sup>7,10-17</sup> Based on these trials, treatment with valves is a GOLD-COPD guideline recommendation. This treatment is designed to occlude all segmental bronchi of a target lobe (**Figure 1**) and achieve atelectasis of the treated lobe, which leads to reduction in residual volume (RV) and improvements in lung function, exercise capacity, and quality of life (see **Table 1** for an overview of the published RCT results).



**Table 1** - Results of randomized controlled trials in bronchoscopic lung volume reduction therapy.

Trial	FU (months)	Group (N)	FEV <sub>1</sub> %	ml	RV ml	6MWD m	SGRQ points
<b>ONE-WAY VALVES (EBV / SVS)</b>							
<b>BELIEVER-HIFI</b> <sup>10</sup>	6	EBV (25)	+8.8	+60*	-260	+25*	-4.4
		SoC (25)	+2.9	+30	-80	+3	-3.6
<b>STELVIO</b> <sup>7</sup>	3	EBV (34)	+20.9	+161*	-865*	+60*	-17.4*
		SoC (34)	+3.1	+21	-34	-14	-2.7
<b>IMPACT</b> <sup>12</sup>	3	EBV (43)	+13.8	+100*	-420*	+22.6*	-8.63*
		SoC (50)	-3.5	-20	+50	-17.3	+1.01
<b>TRANSFORM</b> <sup>15</sup>	6	EBV (65)	+20.7	+140*	-660*	+36.2*	-7.2*
		SoC (32)	-8.6	-90	+10	-0.7	-0.7
<b>LIBERATE</b> <sup>14</sup>	12	EBV (128)	+17.2	104*	-490*	+13.0*	-7.55*
		SoC (62)	-0.8	-3	+30	-26.3	-0.50
<b>REACH</b> <sup>17</sup>	6	SVS (66)	-	+91	-420	+20.8*	-8.39*
		SoC (33)	-	-24	-50	-15.6	+2.11
<b>EMPROVE</b> <sup>13</sup>	6	SVS (113)	-	+101*	-402*	-4.4	-8.1*
		SoC (59)	-	-2	-42	-11.3	+4.8
<b>COILS</b>							
<b>RESET</b> <sup>50</sup>	3	Coils (23)	+14.2*	-	-510*	+51*	-8.1*
		SoC (23)	+3.6	-	-200	-12	+0.25
<b>REVOLENS</b> <sup>51</sup>	6	Coils (50)	+9*	+60*	-520*	+18	-11.1*
		SoC (50)	-3	-30	-150	+3	+2.3
<b>RENEW</b> <sup>48</sup>	12	Coils (155)	+3.8*	-	-410*	+10.3*	
		SoC (157)	-2.5	-	-100	-7.6	
<b>ELEVATE</b> <sup>45</sup>	6	Coils (57)	+7.9	+40*	-716*	-	-8.6*
		SoC (34)	-3.2	-20	-203	-	+2.1
<b>THERMAL VAPOR ABLATION</b>							
<b>STEP-UP</b> <sup>55</sup>	6	BTVA (46)	+11.0*	-	Δ-303*	Δ30.5*	-9.7*
		SoC (24)	-3.7	-			-0.0
<b>AERISEAL</b>							
<b>ASPIRE</b> <sup>59</sup>	6	AeriSeal (61)	+18.9	+100*	-	+31*	-12
		SoC (34)	+1.3	+10	-	-22	-3



**Figure 1** - Endobronchial view of an endobronchial valve (Zephyr EBV, Pulmonx, Redwood City, CA) placed in the anterior segment of the left lower lobe (LB8).

### *Target Lobe Selection*

Compared with other bronchoscopic lung volume reduction therapies, the treatment with endobronchial valves has been investigated most extensively, is most successful, and it is a reversible treatment.<sup>4</sup> For treatment with endobronchial valves, it is crucial to select the best treatment target lobe. If treatment with endobronchial valves is not possible due to collateral ventilation, absence of target lobe, or other reasons, the patient may be eligible for other treatments.<sup>3</sup> Selection of the target lobe is based on several aspects. Overall, there should be a significant emphysematous destruction of that lobe, the destruction should be  $>30\%$  at  $-950$  HU. Furthermore, there should be no interlobar collateral ventilation, meaning that on CT scan the fissures between the target lobe and the ipsilateral lobe(s) should be nearly complete as a surrogate marker.<sup>4,18,19</sup> Nevertheless, in case of a suitable target lobe, even with incomplete fissures, it might be possible that there is no collateral ventilation, and measurement of collateral ventilation with a Chartis assessment can confirm this during bronchoscopy.<sup>18</sup> If multiple lobes are eligible for treatment with endobronchial valves based on the destruction and fissure completeness score, other factors are important to select the best target lobe. The level of heterogeneity between ipsilateral lobes is important. A large difference of destruction between lobes is preferable. Furthermore, perfusion scintigraphy or single photon emission CT (SPECT) perfusion can help to choose the target lobe. In patients with severe emphysema, the perfusion of the lung parenchyma can be reduced due to

hypoxic pulmonary vasoconstriction and loss of vasculature.<sup>20,21</sup> Nevertheless, after collapse of a lobe with endobronchial valves, there is a ventilation perfusion mismatch, due to the loss of ventilation. Therefore, in patients with homogeneous disease distribution or patients with multiple suitable target lobes, the target lobe is the lobe with the most destruction and the lowest perfusion compared with ipsi- and contralateral lobes.<sup>5</sup> Finally, lobar volume might be a factor to consider before treating a target lobe. A very large target lobe and small ipsilateral lobe contains a higher risk of a pneumothorax after the treatment. Especially if the destruction in the ipsilateral lobe is also high, this may lead to a pneumothorax or compensatory hyperinflation of this lobe.<sup>4,22,23</sup>

### *Chartis*

Although the fissure completeness score is a predictor for the presence or absence of collateral ventilation, measuring the presence of collateral ventilation with the Chartis Pulmonary Assessment System (Pulmonx Corporation, Redwood City, CA) is advised in most cases.<sup>18,19</sup> The Chartis system consists of a catheter with a balloon at the distal tip. The catheter is inserted into the airways through the working channel of a bronchoscope. The open lumen at the distal tip is placed into the target airway. After inflation of the balloon, the airways of the lobe are sealed and the catheter is connected to the Chartis console that measures the air from the occluded lobe. If the air flow from the occluded lobe reaches zero with immediate return of air flow after deflating the balloon, absence of collateral ventilation is confirmed.<sup>3</sup> In case of persistent flow, there is presence of collateral ventilation and treatment with valves will most probably not be successful.<sup>6</sup> The Chartis measurement can be performed using general anesthesia (either closed-circuit ventilation or jet ventilation), or conscious sedation. Compared with sedation, both Chartis and the placement of the valves are more accurate and easier to perform using general anesthesia.<sup>24,25</sup>

In some cases, the Chartis measurement can be lengthy and more difficult to interpret due to the presence of low flow and spikes in flow pattern due to very small amounts of volume released from the measured lobe. Chartis can be effectively shortened by using the volume trend for the previous 20 seconds (VT20). This feature on the Chartis console continuously shows the total expired volume over the last 20 seconds. We validated the VT20 in a recent study showing that all CV negative patients reached a threshold of  $VT20 \leq 6$  mL, whereas all CV positive patients reached a  $VT20 \geq 7$  mL.<sup>26</sup> In patients measured with conscious sedation, a diagnostic algorithm has been proposed including measurement time, resistance, and expired volume to help interpret the Chartis measurement easier.<sup>27</sup> In case of homogeneous emphysema distribution, low diffusing capacity or lower emphysema destruction scores, the Chartis measurement can also be used to assess the contribution of the target lobe to the total gas-exchange. In case of significant desaturation after occluding a lobe with low  $FiO_2$ , treating this lobe should be reconsidered.<sup>4</sup>

### *Marginal Cases*

Although treatment with valves is very effective in selected patients, a large patient group has been excluded from treatment in previous studies due to comorbidities or the severity of emphysema. Nevertheless, more data are being collected about possible treatment of these marginal cases.

### *Low DL<sub>CO</sub> and Low FEV<sub>1</sub>*

Patients with low diffusing capacity of the lung for carbon monoxide (DL<sub>CO</sub>) and low FEV<sub>1</sub> have been excluded from most trials, based on the result of the National Emphysema Treatment Trials (NETT), that revealed higher mortality in patients with low FEV<sub>1</sub> ( $\leq 20\%$  of the predicted value) with either homogeneous emphysema or a DL<sub>CO</sub>  $\leq 20\%$  predicted value.<sup>28</sup> Recently, two studies were published regarding treatment in patients with a low DL<sub>CO</sub>. Both studies showed significant improvements in lung function, exercise capacity, and quality of life, with low complication rates.<sup>29,30</sup> Moreover, a review by van Dijk et al showed that lung volume reduction results in a small increase in DL<sub>CO</sub>.<sup>31</sup> Darwiche et al and Trudzinski et al performed a retrospective analysis of patients who were treated with endobronchial valves with FEV<sub>1</sub>  $\leq 20\%$  of the predicted value.<sup>32,33</sup> In the study by Darwiche et al, 50% of the 20 patients had homogeneous emphysema and the mean DL<sub>CO</sub> was 21.5%. Trudzinski et al described homogeneous emphysema in 45% of the 20 patients, and all patients had DL<sub>CO</sub>  $\leq 20\%$ . At 3 months follow-up, 55 to 60% had displayed a (partial) atelectasis and there was significant improvement in FEV<sub>1</sub> and RV.<sup>34</sup> This indicates that treatment with endobronchial valves in patients with a low DL<sub>CO</sub> or FEV<sub>1</sub> can be safe and effective in carefully selected patients.<sup>34</sup>

### *Hypercapnia*

Severe hypercapnia is also a relative contraindication for treatment with valves. Currently, no studies have been published regarding this subject. An abstract by Rötting et al reported the safety and efficacy of endobronchial valve treatment in 138 patients with a pCO<sub>2</sub>  $\geq 45$  mm Hg, along with a reduction in hypercapnia.<sup>35</sup> Alternatively, in case of significant hypercapnia, it can be considered to initiate non-invasive ventilation before the valve treatment.<sup>36</sup>

### *Moderate Hyperinflation*

As the treatment with endobronchial valves is designed to reduce hyperinflation, the inclusion criteria for treatment in most published trials is a postbronchodilator RV  $\geq 175\%$  of predicted and RV/total lung capacity (TLC)  $\geq 55\%$ .<sup>7,12-14</sup> In general, patients with a heterogeneous emphysema have better efficacy outcomes compared with homogeneous emphysema distribution.<sup>7,13</sup> In a recent retrospective analysis by Klooster et al, endobronchial valve therapy also proved to be effective in patients with a more moderate hyperinflation (median RV 161% of predicted, range 130–175%), but with clear heterogeneous emphysematous destruction.<sup>37</sup> Therefore, if a patient is limited due to hyperinflation, or dynamic hyperinflation, valve treatment can also be considered in these lower RV heterogeneous emphysema patients.

Although there seems to be some space to extend the inclusion criteria for treatment with endobronchial valves to treat emphysema patients (“marginal cases”), this is more the exception than the rule and it is strongly advised to discuss all qualified patients by an experienced multidisciplinary team and it is important to consider the risks in this patient group.<sup>3-5,22</sup>

### **Complications**

Effective endobronchial valve treatment can also lead to complications. The most important acute adverse event is a pneumothorax, with a reported prevalence of 4 to 34% in the treated patients.<sup>22,23</sup> Due to the volume reduction of the treated lobe, there is expansion of the ipsilateral nontreated lobe. This might lead to a parenchymal rupture due to pre-existing pleural adhesions, or rupture of blebs or bullae of the nontreated lobe. Possible risk factors for developing a pneumothorax are pleural adhesions, paraseptal emphysema, volume disbalance of the target lobe and the ipsilateral lobe and high emphysematous destruction of the ipsilateral lobe.<sup>22,43</sup> Adequate pneumothorax management is essential and may be complicated. Management recommendations and proposed timelines are described in the recently published expert statement by van Dijk et al.<sup>22</sup> Later onset complications include granulation tissue formation, which can lead to valve dysfunction, hemoptysis, infectious complications, and cough.<sup>23,38,39</sup> Dedicated follow-up is needed to monitor the treatment effect to effectively deal with the possible complications. In case of valve dysfunction and subsequent loss of effect, a revision bronchoscopy may be needed to try to regain the lung volume reduction effect.<sup>39</sup>

### **Lung Volume Reduction Surgery**

After bronchoscopic lung volume reduction, a significant proportion of patients may need a “revision bronchoscopy” due to loss of lung volume reduction effect or other complications.<sup>23,38,39</sup> Revision can lead to improvement in lung function after loss of initial treatment effect. However, if this is unsuccessful or if valves have to be removed permanently due to local granulation tissue formation, other options can be explored. LVRS can potentially achieve a similar effect to valve treatment, especially if patients initially experienced a beneficial effect of the valve treatment. A retrospective analysis by Eichhorn et al described LVRS by lobectomy with open anterolateral thoracotomy or video-assisted thoracoscopic surgery in 20 patients who were treated with valves first. There was a 30-day mortality of 5% (1 of 20 patients) and the remaining patients showed a significant increase in FEV<sub>1</sub> (+27.5%) and reduction in RV (–21%).<sup>40</sup> Caviezel et al also described a significant improvement in lung function (FEV<sub>1</sub> + 12.5%) after lobectomy for patients with failure of valve treatment (with or without initial effect), with no mortality.<sup>41</sup> This case series included a more heterogeneous patient group, including patients without initial treatment effect or surgery at the contralateral side.

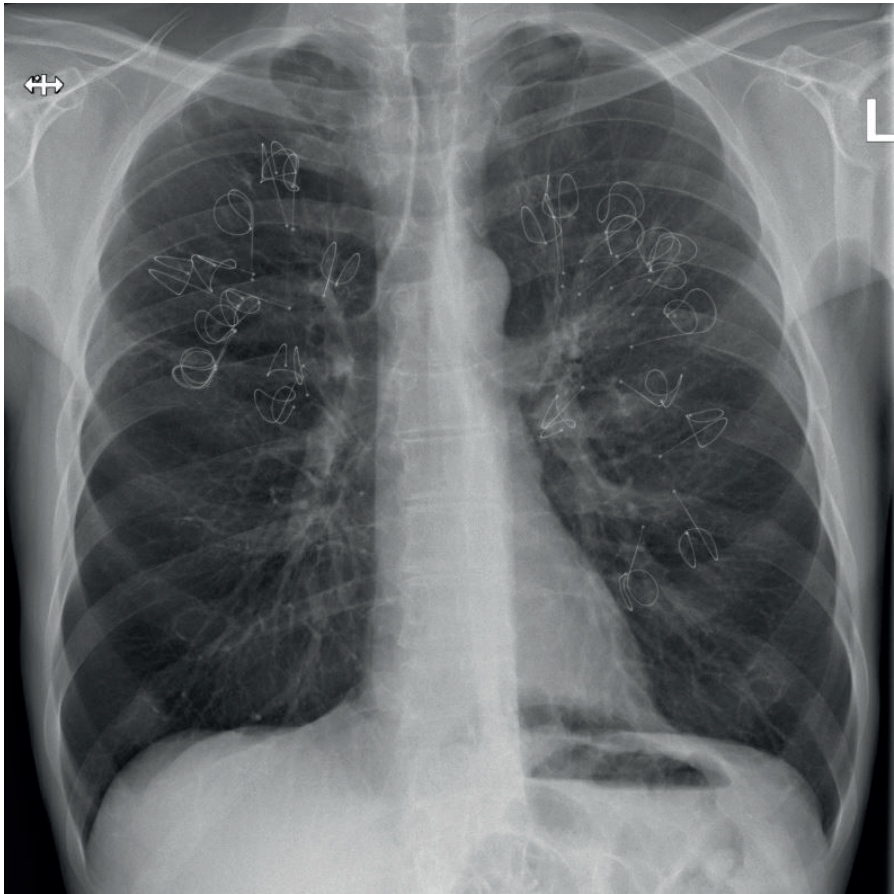
Surgery may also be considered as primary therapy, especially in patients with heterogeneous emphysema who are not eligible for valve treatment due to collateral ventilation and who are fit enough for surgery. Doooms et al performed a prospective study in which patients were evaluated for lung volume reduction therapy in a multidisciplinary board setting and were treated with endobronchial valves or surgery in case endobronchial therapy failed or in case of collateral ventilation.<sup>42</sup> Twenty patients were treated with endobronchial valves and 13 patients underwent LVRS. Three patients who received valves underwent LVRS after follow-up due to no response of the valve treatment. This combined approach also led to a significant improvement of lung function.

### Endobronchial Coils

The first feasibility trial investigating bronchoscopic lung volume reduction with endobronchial coils was published in 2010.<sup>44</sup> Since then, multiple RCT's have been performed and endobronchial coil treatment has been added to the COPD GOLD guidelines as an additional treatment option for patients with emphysema and severe hyperinflation.<sup>1</sup> Up until recently, the PneumRx endobronchial coil system (PneumRx/BTG, CA) was most commonly used for coil treatment. However, in 2020, after the acquirement of BTG by Boston Scientific, United States, the production of the PneumRx endobronchial coils has been terminated.<sup>45</sup> Other endobronchial coil systems are currently being investigated (NCT04520152, NCT03685526).

Endobronchial coils are made from nitinol, which is a shape-memory alloy of nickel-titanium. In contrast with one-way valve treatment, treatment with endobronchial coils is a “non-blocking technique,” which means no complete lobar atelectasis will be achieved. The presence of collateral ventilation between the target lobes and ipsilateral lobes is therefore irrelevant. The proposed mechanism of action is that the endobronchial coils increase lung tissue tension and improve airway tethering, which subsequently leads to a reduction in lobar volume and RV.<sup>46</sup> Usually, the two most diseased lobes are treated during two serial bronchoscopies in a 4- to 8-week interval. The treatment target lobes are selected on the basis of emphysematous destruction, which can be determined from the chest CT scan using quantitative CT analysis. It is preferable to perform this treatment under general anesthesia. Additionally, fluoroscopy is needed to guide coil placement. During each bronchoscopy, depending on the size of the lobe, 8 to 14 coils are placed at a subsegmental level (**Figure 2**). To accommodate for variations in airway length, there are three different coil sizes (length: 100, 125, and 150 mm).<sup>47</sup>

In line with other bronchoscopic lung volume reduction treatments, eligible patients should be symptomatic, with severe hyperinflation (preferably  $RV > 200\%pred$ ,  $RV/TLC > 0.58$  for coils) and emphysema ( $\geq 20\%$  destruction at  $-950$  Hounsfield Units in the target lobes). Special attention should be paid to selecting patients with absence of severe airway disease and frequent infectious exacerbations, to minimize the chance of inflammatory or infectious complications.<sup>47</sup>



**Figure 2** - Chest X-ray after bilateral treatment with lung volume reduction coils.

During the first treatment, 12 coils were placed in the right upper lobe. During the second treatment, approximately 8 weeks later, 12 coils were placed in the left upper lobe.

The most common “complications” of endobronchial coil treatment are coil-associated opacities (CAO), which can occur in up to 50% of the treated patients, and pneumonia, which occurs in up to 10% of treated cases. These two entities are difficult to distinguish, therefore patients should be treated with corticosteroids and antibiotics, to target both the inflammatory response and the possible infection. Patients who have CAO appear to have a better chance to be a treatment responder in the long run. Minor hemoptysis is a common occurrence during the first period after treatment, but fortunately major hemoptysis is uncommon (1%). Pneumothorax occurs in up to 10% of cases. However, there appears to be an important learning effect, with a pneumothorax prevalence of around 1% at experienced sites.<sup>48</sup> COPD exacerbations occur with a prevalence of 10%, and treatment of exacerbations does not differ from standard care.<sup>47,49</sup>

Multiple RCTs have demonstrated a statistically significant improvement in airflow obstruction ( $FEV_1$ ), static hyperinflation (RV), exercise tolerance (6-minute walk distance), and quality of life (St. Georges' Respiratory Questionnaire, SGRQ).<sup>45,48,50,51</sup> The main outcomes of these trials can be found in **Table 1**. The ELEVATE trial is the most recently published trial investigating endobronchial coils.<sup>46,52</sup> Unfortunately, this trial was terminated prematurely by the sponsor, which meant that only 120 patients (57% of the intended number) were included. Still, there were statistically significant differences in outcomes for patients in the treatment versus the control group:  $FEV_1 +70$  (+30 to +110) mL, RV  $-460$  ( $-716$  to  $-203$ ) mL, and SGRQ  $-10.6$  ( $-15.9$  to  $-5.4$ ) points. From subgroup analyses it is suggested that the presence of very severe hyperinflation (RV  $\geq 225\%$ ), heterogeneous emphysema, and bilateral treatment in the upper lobes is associated with the largest and consistent improvements following endobronchial coil treatment.<sup>45,48</sup>

### Bronchoscopic Thermal Vapor Ablation

Based on a single multicenter randomized controlled trial, the bronchoscopic thermal vapor ablation (BTVA) is acknowledged in the international COPD GOLD guidelines as a possible lung volume reduction treatment for patients with upper lobe predominant heterogeneous emphysema.<sup>1</sup> However, the availability for clinical practice is limited to a small number of centers. For this treatment modality, heated water vapor ( $100^\circ\text{C}$ ) is applied to the most emphysematous parts of the lungs, thereby inducing a local inflammatory reaction, which can subsequently lead to reduction of the lung volume.<sup>53,54</sup> One or two emphysematous segments of both upper lobes are normally targeted using this approach. The absence or presence of collateral ventilation is also irrelevant for this treatment. The BTVA treatment is performed using the InterVapor System (Uptake Medical Technology, Inc., Seattle, WA), which allows for the heated vapor to be delivered with a catheter. During the application of vapor, the segment is closed by an inflated balloon at the distal tip of the catheter. The entire treatment consists of two sequential bronchoscopies under general anesthesia or deep sedation with a 3-month interval, to avoid severe inflammatory treatment complications, which can occur if both upper lobes are targeted simultaneously. To determine which lung segments are the best treatment targets, and to calculate the necessary volume of vapor, a quantitative CT analysis is used to assess the emphysematous destruction and volume of each lung segment.<sup>54</sup> Inclusion criteria for BTVA are in line with those described in the section on patient selection above: symptomatic COPD (mMRC  $\geq 2$ ), severe airflow obstruction, and static hyperinflation ( $FEV_1$  20–45%pred, RV  $\geq 175\%$ pred).<sup>54</sup> Special attention should be paid to the history of frequent exacerbations, immune system disorders, and use of immune suppressants, since these are thought to increase the risk of complications. COPD exacerbations, pneumonia, and pneumonitis are the most common complications of BTVA. COPD exacerbations occur in 24% of cases and can be treated as regular COPD exacerbations. Pneumonia and pneumonitis occur in 18% of cases, and can be difficult to distinguish. Therefore, a combination of antibiotics and corticosteroids is often prescribed in these situations. In addition, to prevent infectious complications, it is advised to prescribe prophylactic antibiotics for at least 2 weeks post bronchoscopy. Hemoptysis and pneumothorax occur less often, with a prevalence of



1 to 3% and 3%, respectively.<sup>53-55</sup> There has been one open label randomized clinical trial investigating BTVA, which included 70 patients (46 BTVA, 24 control). Compared with the control group, patients treated with BTVA had a statistically significant improvement in airflow obstruction ( $FEV_1$  +131 [95% CI 64–198] mL), hyperinflation (RV –303 [95% CI –542 to –62] mL), quality of life (St Georges' Respiratory Questionnaire –9.7 [95% CI –15.7 to –3.7] points) at 6 months follow-up (Table 1).<sup>55</sup> Interestingly, an analysis of 44 patients treated with BTVA in two multicenter, single-arm trials, found that patients with respiratory adverse events requiring antibiotics and/or corticosteroids within 30 days after treatment were more likely to have long-term clinical benefits of BTVA.<sup>53</sup>

### AeriSeal

In patients with emphysema who are not eligible for valve treatment due to presence of collateral ventilation or other contraindications, treatment with AeriSeal has been shown to reduce lung volume, improve lung function, and improve quality of life. The AeriSeal System (PulmonX, Redwood City, CA) consists of two components (2.1% aminated polyvinyl alcohol and 1.25% glutaraldehyde mixed with 15 mL of air), creating a crosslink compound. It functions by occluding small airways and collateral air channels by creating an inflammatory reaction. This causes the treated area to collapse both via absorption atelectasis and inflammation, which leads to reduction in gas trapping and lung hyperinflation. Three open-label, single-arm, multicenter trials of the AeriSeal System have been conducted in Europe and Israel,<sup>56-58</sup> and a fourth randomized controlled trial was initiated.<sup>59</sup> Unfortunately, this last study (the ASPIRE Study) was discontinued due to funding limitations after 95 out of 300 planned patients were randomized.

Inclusion criteria included an upper lobe predominant emphysema on CT scan, severe airflow obstruction ( $FEV_1$  <50%pred), and hyperinflation (RV >150% pred). Exclusion criteria were frequent exacerbations and clinically relevant asthma or bronchiectasis and use of immunosuppressive agents. Treatment was performed under sedation or general anesthesia, during a prophylactic course of prednisolone and antibiotics. The treatment was performed bilaterally in four subsegments during one session, with a total of 80 mL of AeriSeal foam administered. In the ASPIRE study, 61 patients were randomized to treatment with AeriSeal, and 34 to standard of care. Improved lung function, exercise capacity, and quality of life were observed at 6 months in treatment versus control groups (Table 1). The change in  $FEV_1$  was 18.9% (–0.7 to 41.9%) in the treatment group versus 1.3% (–8.2 to 12.9%) in controls ( $p = 0.04$ ). Despite the fairly good efficacy, the extent of inflammation led to a relatively high incidence of adverse events. The most frequent adverse events after this treatment were “post-acute inflammatory response” (PAIR), pneumonia, and COPD exacerbation. A subsequent study with AeriSeal tried to assess the impact of a staged and lower dose treatment, but the adverse rate was similar to the single treatment.<sup>60</sup>

## PATIENT SELECTION

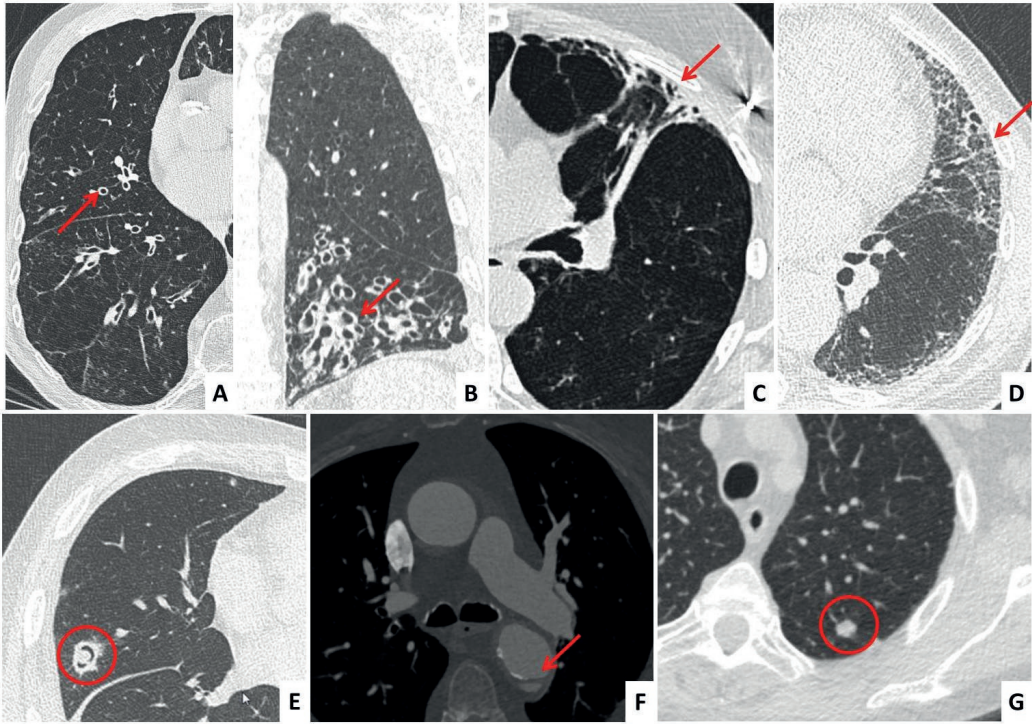
Precise phenotyping COPD patients for lung volume reduction options is extremely important to achieve optimal benefit and to avoid complications. Potential patients who are eligible for bronchoscopic lung volume reduction should be symptomatic despite optimal treatment, including guideline pharmacologic therapy, smoking cessation, pulmonary rehabilitation, nutrition support, and long-term oxygen therapy of noninvasive ventilation as appropriate.<sup>4,61,62</sup>

### *Lung Function*

Patients evaluated for bronchoscopic lung volume reduction must have severe COPD and hyperinflation as their limiting factors in exercise capacity.<sup>4,5</sup> For example, in case of severe heart failure or peripheral arterial occlusive disease, improvement of lung function might not improve symptoms. In general, postbronchodilator  $FEV_1/FVC < 70\%$  and  $FEV_1$  between 15 and 50% of predicted and an  $RV \geq 175\%$  of predicted and  $RV/TLC \geq 55\%$ , measured by body plethysmography are cut off values for patient selection. Nevertheless, in selected cases with optimal treatment targets, outcomes can be good despite lower or higher values.<sup>4</sup>

### *Contraindications*

To achieve lung volume reduction with endobronchial devices is not suitable for every patient, even if their emphysema phenotype is perfect for treatment. Some comorbidities are associated with increased side-effects, which should at least be appreciated before treatment, or might be an actual contraindication for treatment (**Figure 3**).



**Figure 3** - Possible contra-indications for lung volume reduction therapy.

(A) Bronchopathy/significant airway wall thickening of airways. (B) Severe bronchiectasis of the left lower lobe. (C) Severe pleural adhesions. (D) Pulmonary fibrosis. (E) Aspergilloma. (F) Dissection in descending aorta. (G) Pulmonary nodule.

### *Airway Disease*

Treatment with endobronchial valves or lung volume reduction coils, vapor or AeriSeal is contraindicated in patients with significant airway disease. Radiologically this means the presence of significant bronchial wall thickening, or bronchiectasis. Clinically this might be the production of significant amounts of mucus or frequent infectious exacerbations. Patients who show this phenotype with emphysema are not eligible to lung volume reduction therapy, due to an increased risk of exacerbations and pneumonias, and intolerance to the “foreign-body” implants. Alternatively, endobronchial treatments targeted to airways for these patients may be considered, mostly in clinical trials.<sup>63</sup> Patients with maintenance immunosuppressive agents or prednisolone  $\geq 10$  mg daily are more at risk of developing respiratory infections and probably will develop local bacterial and fungal colonization of the device.<sup>3,5</sup>

### *Comorbidities*

Several comorbidities might be a relative contraindication for lung volume reduction treatment. This is mainly for safety reasons, a patient should be able to endure the intervention and anesthesia or sedation itself, and to manage possible complications.<sup>4,62</sup> Patients with significant congestive heart failure (left ventricular ejection fraction <40%) are less eligible for treatment. Severe pulmonary hypertension (right ventricular systolic pressure >50 mm Hg) is generally an exclusion criterion for treatment with endobronchial valves or coils. However, individual cases have shown improvement in elevated right ventricular systolic pressure after endobronchial valve treatment.<sup>64</sup> An echocardiography may be prompted when pulmonary hypertension is suggested on CT. This can be the case if there is a main pulmonary artery dilatation greater than or equal to 29 mm, a pulmonary artery: ascending aorta ratio greater than or equal to 1.0, and/or a segmental artery: bronchus ratio greater than 1.0 in three or four lung lobes on CT.<sup>65</sup> Furthermore, it must be possible to discontinue maintenance anticoagulation temporarily in patients, for example to be able to manage complications (e.g., pneumothorax) and it is a contraindication for treatment with coils. Relative contraindications include severe hypercapnia and a low  $DL_{CO}$ , but as described above, successful outcomes have been reported in patients with hypercapnia and low diffusion after valve treatment.

### *Nodules*

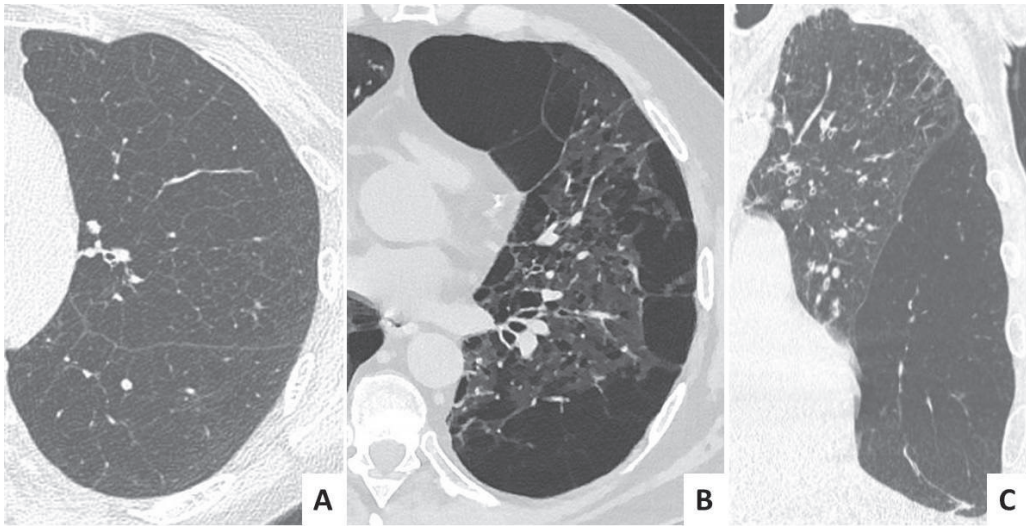
Patients with new and suspected nodules are generally excluded from endobronchial lung volume reduction therapy, until there is clarity about its origin and treatment, especially if this is in the area of interest for treatment.<sup>4,5</sup> If a patient is treated with endobronchial valves, the achieved atelectasis prevents adequate follow-up and possible treatment of the nodules in that lobe. Although coils do not primarily induce an atelectasis, local changes of the lung parenchyma may prevent an adequate follow-up, as is the case with treatment with vapor or AeriSeal. If definitive treatment of a nodule is necessary after follow-up and it is located in a treatment target lobe, a surgical lobectomy may be considered, as this may additionally achieve the desired lung volume reduction effect.

### *CT Scan Analysis*

The most important tool for phenotyping and selecting the optimal treatment for patients, is a chest high resolution computed tomography (HRCT).<sup>3,66</sup> Preferably, a thin sliced HRCT with inspiratory and expiratory views is performed. To check for eligibility for lung volume reduction therapy, it is important to characterize the type, distribution, and the severity of emphysema. Furthermore, the fissure completeness should be assessed for estimating the presence of collateral ventilation.

### Type

Classically, emphysema is categorized into three major subtypes, depending on its location and distribution: centrilobular, panlobular, and paraseptal emphysema (**Figure 4**).<sup>67-71</sup> In general, patients with predominant paraseptal emphysema are not easily eligible to receive endobronchial lung volume reduction therapy, as this generally seems to have less impact on the lung function. Furthermore, creating an atelectasis of the relatively healthy central lung tissue results a more prominent ventilation perfusion mismatch.<sup>4</sup> Moreover, paraseptal emphysema of the ipsilateral lobe leads to a higher risk of a complicated pneumothorax.<sup>22</sup>



**Figure 4** - Types of emphysema.

(A) Centrilobular emphysema of the left lower and the left upper lobe. (B) Paraseptal emphysema of the left lower lobe. (C) Panlobular emphysema of the left lower lobe.

### Distribution

The distribution of emphysema can be assessed visually but this is limited by a large interobserver variability.<sup>70</sup> Quantitative CT analysis measures the distribution of emphysema more accurately, using density measurements. Low attenuation areas are defined as a percentage of voxels below a certain threshold and a surrogate measurement of emphysema. Several thresholds have been investigated, but usually, for thin-sliced chest CT scans, the best emphysema quantification is achieved at  $-950$  HU.<sup>70-73</sup> The main advantage to use this method is its reproducibility and no interobserver variability. The percentage of heterogeneity is defined as the difference in lung tissue destruction between the target lobe and the ipsilateral adjacent non-target lobe. To date, no clear definition exists for heterogeneity. Current

literature varies from a difference of 10 to 25% between lobes to define heterogeneous emphysema and less than <10 to 25% defines as homogeneous distribution. Currently, there are no important treatment consequences of a heterogeneity threshold and defining a solid consensus on this is less relevant.

### *Destruction*

The amount of tissue destruction is important for the choice and expected effect of treatment. For treatment with endobronchial valves, a destruction score of >30% at -950 HU is necessary for a successful treatment, otherwise well preserved tissue, which contributes to often highly necessary gas-exchange, and presumably will mainly be small airways disease, will be occluded and cause ventilation perfusion mismatch which leads to desaturation.<sup>4,23</sup> Both patients with upper- or lower lobe predominant heterogeneous and homogeneous emphysema can be eligible for treatment with valves or coils. Nevertheless, heterogeneity helps to select the target lobe. Furthermore, the functional improvements are smaller in homogeneous compared with heterogeneous patients.<sup>7,12,15</sup>

### *Lobar Volumes*

Quantitative CT-analysis offers the possibility to measure the volume of lungs and lobes.<sup>70</sup> This can be used for selecting the target lobe as it might give an indication of the volume shifts in the thorax after achieving post treatment atelectasis and its risk of a pneumothorax.<sup>22,62,70</sup> Furthermore, the comparison of expiratory and inspiratory volumes might indicate the presence of air trapping in a lobe.

### *Fissures*

The interlobar fissure is currently one of the most distinctive factors in the choice of therapy. Endobronchial valve therapy is only effective if there is no collateral flow between the target lobe and the adjacent ipsilateral lobe(s).<sup>6,7,18,19</sup> Although the presence of collateral ventilation can be measured during bronchoscopy with the Chartis assessment, it has been proven that the completeness of the pulmonary fissures on CT scan correlates to the presence of collateral ventilation.<sup>18,19</sup> Quantitative CT scan for fissure analysis is recommended in all patients who appear eligible for endobronchial valve treatment. If the fissure completeness score is low (<80% for the left major fissure and <90% for the right major fissure), the chance of successful treatment is low and these patients must be excluded from valve treatment.<sup>18</sup> In patients with more complete fissures, an additional Chartis measurement is always recommended in the right lung. For the left lung, if the fissure is >95% complete, Chartis might optionally be passed.<sup>18</sup>

## **FUTURE STUDIES**

Currently, only a small proportion of patients referred for possible long volume reduction treatment are eligible for treatment and there is a need for new therapies. There are several new developments in this field. For example, in patients who are not eligible for valve treatment due to the presence of collateral ventilation, several alternative options are being investigated to make them suitable for valve treatment by blocking the collateral ventilation or complete the fissure. This includes treatment with a small dose of AeriSeal in patients with a relatively small fissure defect. If AeriSeal is delivered at the site of the fissure defect, this will block the collateral channels and create an inflammatory reaction and subsequent fibrosis at the place of the fissure defect. If the collateral ventilation is blocked, treatment with valves is possible. The approach to the fissure defect can be both endobronchial as well as transbronchial (NCT04559464; NCT04256408).<sup>75</sup> Furthermore, it is an option to complete the fissure surgically before treatment with valves (NCT04801108, NCT04465461). Finally, LVRS is being compared directly to treatment with valves (NCT04781582, NCT04537182). Alternative treatments being investigated for patients who are not eligible for valve treatment include new coil studies (NCT03685526) and the free flow medical lung tensioning device system (NCT04520152) and treatment with vapor (NCT04029077).

## **CONCLUSION**

Patients with severe emphysema and hyperinflation may be eligible for lung volume reduction therapy, of which treatment with endobronchial valves is currently the most important one. However, careful patient selection and phenotyping of the COPD is crucial for optimal treatment and a multidisciplinary approach is important.

## REFERENCES

- 1 Singh D, Agusti A, Anzueto A. et al. Global strategy for the diagnosis, management, and prevention of chronic obstructive lung disease: the GOLD science committee report 2019. *Eur Respir J* 2019; 53 (05) 1900164
- 2 van Geffen WH, Slebos DJ, Herth FJ, Kemp SV, Weder W, Shah PL. Surgical and endoscopic interventions that reduce lung volume for emphysema: a systemic review and meta-analysis. *Lancet Respir Med* 2019; 7 (04) 313-324
- 3 Herth FJF, Slebos DJ, Criner GJ, Valipour A, Scieurba F, Shah PL. Endoscopic lung volume reduction: an expert panel recommendation—update 2019. *Respiration* 2019; 97 (06) 548-557
- 4 Klooster K, Slebos DJ. Endobronchial valves for the treatment of advanced emphysema. *Chest* 2021; 159 (05) 1833-1842
- 5 Slebos DJ, Shah PL, Herth FJ, Valipour A. Endobronchial valves for endoscopic lung volume reduction: best practice recommendations from expert panel on endoscopic lung volume reduction. *Respiration* 2017; 93 (02) 138-150
- 6 Herth FJ, Eberhardt R, Gompelmann D. et al. Radiological and clinical outcomes of using Chartis™ to plan endobronchial valve treatment. *Eur Respir J* 2013; 41 (02) 302-308
- 7 Klooster K, ten Hacken NH, Hartman JE, Kerstjens HA, van Rikxoort EM, Slebos DJ. Endobronchial valves for emphysema without interlobar collateral ventilation. *N Engl J Med* 2015; 373 (24) 2325-2335
- 8 Toma TP, Hopkinson NS, Hillier J. et al. Bronchoscopic volume reduction with valve implants in patients with severe emphysema. *Lancet* 2003; 361 (9361): 931-933
- 9 Snell GI, Holsworth L, Borrill ZL. et al. The potential for bronchoscopic lung volume reduction using bronchial prostheses: a pilot study. *Chest* 2003; 124 (03) 1073-1080
- 10 Davey C, Zoumot Z, Jordan S. et al. Bronchoscopic lung volume reduction with endobronchial valves for patients with heterogeneous emphysema and intact interlobar fissures (the BeLieVeR-HiFi study): a randomised controlled trial. *Lancet* 2015; 386 (9998): 1066-1073
- 11 Herth FJ, Noppen M, Valipour A. et al; International VENT Study Group. Efficacy predictors of lung volume reduction with Zephyr valves in a European cohort. *Eur Respir J* 2012; 39 (06) 1334-1342
- 12 Valipour A, Slebos DJ, Herth F. et al; IMPACT Study Team. Endobronchial valve therapy in patients with homogeneous emphysema. results from the IMPACT study. *Am J Respir Crit Care Med* 2016; 194 (09) 1073-1082
- 13 Criner GJ, Delage A, Voelker K. et al. Improving lung function in Severe Heterogenous Emphysema with the Spiration Valve System (EMPROVE). A multicenter, open-label randomized controlled clinical trial. *Am J Respir Crit Care Med* 2019; 200 (11) 1354-1362
- 14 Criner GJ, Sue R, Wright S. et al; LIBERATE Study Group. A Multicenter randomized controlled trial of zephyr endobronchial valve treatment in heterogeneous emphysema (LIBERATE). *Am J Respir Crit Care Med* 2018; 198 (09) 1151-1164
- 15 Kemp SV, Slebos DJ, Kirk A. et al; TRANSFORM Study Team \*. A multicenter randomized controlled trial of zephyr endobronchial valve treatment in heterogeneous emphysema (TRANSFORM). *Am J Respir Crit Care Med* 2017; 196 (12) 1535-1543
- 16 Scieurba FC, Ernst A, Herth FJ. et al; VENT Study Research Group. A randomized study of endobronchial valves for advanced emphysema. *N Engl J Med* 2010; 363 (13) 1233-1244
- 17 Li S, Wang G, Wang C. et al. The REACH Trial: a randomized controlled trial assessing the safety and effectiveness of the Spiration® valve system in the treatment of severe emphysema. *Respiration* 2019; 97 (05) 416-427



- 18 Klooster K, Koster TD, Ruwwe-Glösenkamp C. et al. An integrative approach of the fissure completeness score and Chartis assessment in endobronchial valve treatment for emphysema. *Int J Chron Obstruct Pulmon Dis* 2020; 15: 1325-1334
- 19 Koster TD, van Rikxoort EM, Huebner RH. et al. Predicting lung volume reduction after endobronchial valve therapy is maximized using a combination of diagnostic tools. *Respiration* 2016; 92 (03) 150-157
- 20 Bryant M, Ley S, Eberhardt R. et al. Assessment of the relationship between morphological emphysema phenotype and corresponding pulmonary perfusion pattern on a segmental level. *Eur Radiol* 2015; 25 (01) 72-80
- 21 Eberhardt R, Gompelmann D, Herth FJ, Schuhmann M. Endoscopic bronchial valve treatment: patient selection and special considerations. *Int J Chron Obstruct Pulmon Dis* 2015; 10: 2147-2157
- 22 van Dijk M, Sue R, Criner GJ. et al. Expert statement: pneumothorax associated with one-way valve therapy for emphysema: 2020 update. *Respiration* 2021; 100 (10) 969-978
- 23 Koster TD, Klooster K, Ten Hacken NHT, van Dijk M, Slebos DJ. Endobronchial valve therapy for severe emphysema: an overview of valve-related complications and its management. *Expert Rev Respir Med* 2020; 14 (12) 1235-1247
- 24 Welling JBA, Hartman JE, Ten Hacken NHT. et al. Chartis measurement of collateral ventilation: conscious sedation versus general anesthesia—a retrospective comparison. *Respiration* 2018; 96 (05) 480-487
- 25 Welling JBA, Klooster K, Hartman JE. et al. Collateral ventilation measurement using Chartis: procedural sedation vs general anesthesia. *Chest* 2019; 156 (05) 984-990
- 26 Koster TD, Klooster K, McNamara H. et al. An adjusted and time-saving method to measure collateral ventilation with Chartis. *ERJ Open Res* 2021; 7 (03) 00191-2021
- 27 Herzog D, Thomsen C, Poellinger A. et al. Outcomes of endobronchial valve treatment based on the precise criteria of an endobronchial catheter for detection of collateral ventilation under spontaneous breathing. *Respiration* 2016; 91 (01) 69-78
- 28 Fishman A, Fessler H, Martinez F. et al; National Emphysema Treatment Trial Research Group. Patients at high risk of death after lung-volume-reduction surgery. *N Engl J Med* 2001; 345 (15) 1075-1083
- 29 van Dijk M, Hartman JE, Klooster K, Ten Hacken NHT, Kerstjens HAM, Slebos DJ. Endobronchial valve treatment in emphysema patients with a very low DLCO. *Respiration* 2020; 99 (02) 163-170
- 30 Lenga P, Ruwwe-Glösenkamp C, Grah C. et al. Endoscopic lung volume reduction with endobronchial valves in very low DLCO patients: results from the German Registry—Lungenemphysemregister e.V. *ERJ Open Res* 2021; 7 (01) 00449-2020
- 31 van Dijk M, Klooster K, Ten Hacken NHT, Sciruba F, Kerstjens HAM, Slebos DJ. The effects of lung volume reduction treatment on diffusing capacity and gas exchange. *Eur Respir Rev* 2020; 29 (158) 190171
- 32 Darwiche K, Karpf-Wissel R, Eisenmann S. et al. Bronchoscopic lung volume reduction with endobronchial valves in low-FEV1 patients. *Respiration* 2016; 92 (06) 414-419
- 33 Trudzinski FC, Höink AJ, Leppert D. et al. Endoscopic lung volume reduction using endobronchial valves in patients with severe emphysema and very low FEV1. *Respiration* 2016; 92 (04) 258-265
- 34 Zoumot Z, Kemp SV, Shah PL. Endobronchial valves for emphysema: time to push the envelope?. *Respiration* 2016; 92 (06) 359-361
- 35 Rötting M, Polke M, Kriegsmann K. et al. Impact of endoscopic valve therapy on hypercapnia in patients with chronic hypercapnic failure based on a severe lung emphysema. *Eur Respir J* 2020; 56 (Suppl. 64) 3777
- 37 Darwiche K, Aigner C. Clinical management of lung volume reduction in end stage emphysema patients. *J Thorac Dis* 2018; 10 (Suppl. 23) S2732-S2737

- 37 Klooster K, Hartman JE, van Dijk M, Koster TD, Slebos DJ. Response to endobronchial valve treatment in emphysema patients with moderate hyperinflation. *J Bronchology Interv Pulmonol* 2021; 28 (01) e14-e17
- 38 Roodenburg SA, Pouwels SD, Slebos DJ. Airway granulation response to lung-implantable medical devices: a concise overview. *Eur Respir Rev* 2021; 30 (161) 210066
- 39 Roodenburg SA, Klooster K, Hartman JE, Koster TD, van Dijk M, Slebos DJ. Revision bronchoscopy after endobronchial valve treatment for emphysema: indications, findings and outcomes. *Int J Chron Obstruct Pulmon Dis* 2021; 16: 1127-1136
- 40 Eichhorn ME, Gompelmann D, Hoffmann H. et al. Consolidating lung volume reduction surgery after endoscopic lung volume reduction failure. *Ann Thorac Surg* 2021; 111 (06) 1858-1865
- 41 Caviezel C, Guglielmetti LC, Ladan M. et al. Lung volume reduction surgery as salvage procedure after previous use of endobronchial valves. *Interact Cardiovasc Thorac Surg* 2021; 32 (02) 263-269
- 42 Dooms C, Blondeel A, Ceulemans LJ. et al. Lung volume reduction in emphysema: a pragmatic prospective cohort study. *ERJ Open Res* 2021; 7 (02) 00877-2020
- 43 van Geffen WH, Klooster K, Hartman JE. et al. Pleural adhesion assessment as a predictor for pneumothorax after endobronchial valve treatment. *Respiration* 2017; 94 (02) 224-231
- 44 Herth FJ, Eberhard R, Gompelmann D, Slebos DJ, Ernst A. Bronchoscopic lung volume reduction with a dedicated coil: a clinical pilot study. *Ther Adv Respir Dis* 2010; 4 (04) 225-231
- 45 Klooster K, Valipour A, Marquette CH. et al. Endobronchial coil system versus standard-of-care medical management in the treatment of subjects with severe emphysema. *Respiration* 2021; 100 (08) 804-810
- 46 Hartman JE, Shah PL, Sciruba F, Herth FJF, Slebos DJ, Group RS. RENEW Study Group. Endobronchial coils for emphysema: dual mechanism of action on lobar residual volume reduction. *Respirology* 2020; 25 (11) 1160-1166
- 47 Slebos DJ, Ten Hacken NH, Hetzel M, Herth FJF, Shah PL. Endobronchial coils for endoscopic lung volume reduction: best practice recommendations from an expert panel. *Respiration* 2018; 96 (01) 1-11
- 48 Sciruba FC, Criner GJ, Strange C. et al; RENEW Study Research Group. Effect of endobronchial coils vs usual care on exercise tolerance in patients with severe emphysema: the RENEW randomized clinical trial. *JAMA* 2016; 315 (20) 2178-2189
- 49 Slebos DJ, Hartman JE, Klooster K. et al. Bronchoscopic coil treatment for patients with severe emphysema: a meta-analysis. *Respiration* 2015; 90 (02) 136-145
- 50 Shah PL, Zoumot Z, Singh S. et al; RESET trial Study Group. Endobronchial coils for the treatment of severe emphysema with hyperinflation (RESET): a randomised controlled trial. *Lancet Respir Med* 2013; 1 (03) 233-240
- 51 Deslée G, Mal H, Dutau H. et al; REVOLENS Study Group. Lung volume reduction coil treatment vs usual care in patients with severe emphysema: the REVOLENS randomized clinical trial. *JAMA* 2016; 315 (02) 175-184
- 52 Herth FJF, Slebos DJ, Shah PL. et al. Protocol of a randomized controlled study of the PneumRx endobronchial coil system versus standard-of-care medical management in the treatment of subjects with severe emphysema (ELEVATE). *Respiration* 2019; 98 (06) 512-520
- 53 Gompelmann D, Eberhardt R, Ernst A. et al. The localized inflammatory response to bronchoscopic thermal vapor ablation. *Respiration* 2013; 86 (04) 324-331
- 54 Gompelmann D, Shah PL, Valipour A, Herth FJF. Bronchoscopic thermal vapor ablation: best practice recommendations from an expert panel on endoscopic lung volume reduction. *Respiration* 2018; 95 (06) 392-400

- 55 Herth FJ, Valipour A, Shah PL. et al. Segmental volume reduction using thermal vapour ablation in patients with severe emphysema: 6-month results of the multicentre, parallel-group, open-label, randomised controlled STEP-UP trial. *Lancet Respir Med* 2016; 4 (03) 185-193
- 56 Herth FJ, Gompelmann D, Stanzel F. et al. Treatment of advanced emphysema with emphysematous lung sealant (AeriSeal®). *Respiration* 2011; 82 (01) 36-45
- 57 Kramer MR, Refaely Y, Maimon N, Rosengarten D, Fruchter O. Bilateral endoscopic sealant lung volume reduction therapy for advanced emphysema. *Chest* 2012; 142 (05) 1111-1117
- 58 Refaely Y, Dransfield M, Kramer MR. et al. Biologic lung volume reduction therapy for advanced homogeneous emphysema. *Eur Respir J* 2010; 36 (01) 20-27
- 59 Come CE, Kramer MR, Dransfield MT. et al. A randomised trial of lung sealant versus medical therapy for advanced emphysema. *Eur Respir J* 2015; 46 (03) 651-662
- 60 Slebos DJ, Herth F, Koster TD. et al. A modified staged treatment algorithm using the AeriSeal System. *Eur Respir J* 2020; 56 (Suppl. 64) 1572
- 61 Shah PL, Slebos DJ. Bronchoscopic interventions for severe emphysema: where are we now?. *Respirology* 2020; 25 (09) 972-980 DOI: 10.1183/13993003.congress-2020.1572.
- 62 Herth FJF, Slebos DJ, Criner GJ, Shah PL. Endoscopic lung volume reduction: an expert panel recommendation—update 2017. *Respiration* 2017; 94 (04) 380-388
- 63 Hartman JE, Garner JL, Shah PL, Slebos DJ. New bronchoscopic treatment modalities for patients with chronic bronchitis. *Eur Respir Rev* 2021; 30 (159) 200281
- 64 Eberhardt R, Gerovasili V, Kontogianni K. et al. Endoscopic lung volume reduction with endobronchial valves in patients with severe emphysema and established pulmonary hypertension. *Respiration* 2015; 89 (01) 41-48
- 65 Goldberg AB, Mazur W, Kalra DK. Pulmonary hypertension: diagnosis, imaging techniques, and novel therapies. *Cardiovasc Diagn Ther* 2017; 7 (04) 405-417
- 66 van Agteren JE, Carson KV, Tiong LU, Smith BJ. Lung volume reduction surgery for diffuse emphysema. *Cochrane Database Syst Rev* 2016; 10: CD001001
- 67 van Agteren JE, Hnin K, Grosser D, Carson KV, Smith BJ. Bronchoscopic lung volume reduction procedures for chronic obstructive pulmonary disease. *Cochrane Database Syst Rev* 2017; 2: CD012158
- 68 Hansell DM, Bankier AA, MacMahon H, McCloud TC, Müller NL, Remy J. Fleischner Society: glossary of terms for thoracic imaging. *Radiology* 2008; 246 (03) 697-722
- 69 Takahashi M, Fukuoka J, Nitta N. et al. Imaging of pulmonary emphysema: a pictorial review. *Int J Chron Obstruct Pulmon Dis* 2008; 3 (02) 193-204
- 70 Herth FJF, Kirby M, Sieren J. et al. The modern art of reading computed tomography images of the lungs: quantitative CT. *Respiration* 2018; 95 (01) 8-17
- 71 Labaki WW, Martinez CH, Martinez FJ. et al. The role of chest computed tomography in the evaluation and management of the patient with chronic obstructive pulmonary disease. *Am J Respir Crit Care Med* 2017; 196 (11) 1372-1379
- 72 Friedman PJ. Imaging studies in emphysema. *Proc Am Thorac Soc* 2008; 5 (04) 494-500
- 73 Lynch DA, Newell JD. Quantitative imaging of COPD. *J Thorac Imaging* 2009; 24 (03) 189-194
- 74 Welling JBA, Hartman JE, Augustijn SWS. et al. Patient selection for bronchoscopic lung volume reduction. *Int J Chron Obstruct Pulmon Dis* 2020; 15: 871-881
- 75 Ing A, Sullivan C, Hersch N, Saghiaie T, Williamson J. Reversal of collateral ventilation using endobronchial polymer sealant in a patient with emphysema undergoing endoscopic lung volume reduction (ELVR) with valves: a case report and proof of concept. *J Bronchology Interv Pulmonol* 2020; 27 (01) e14-e16

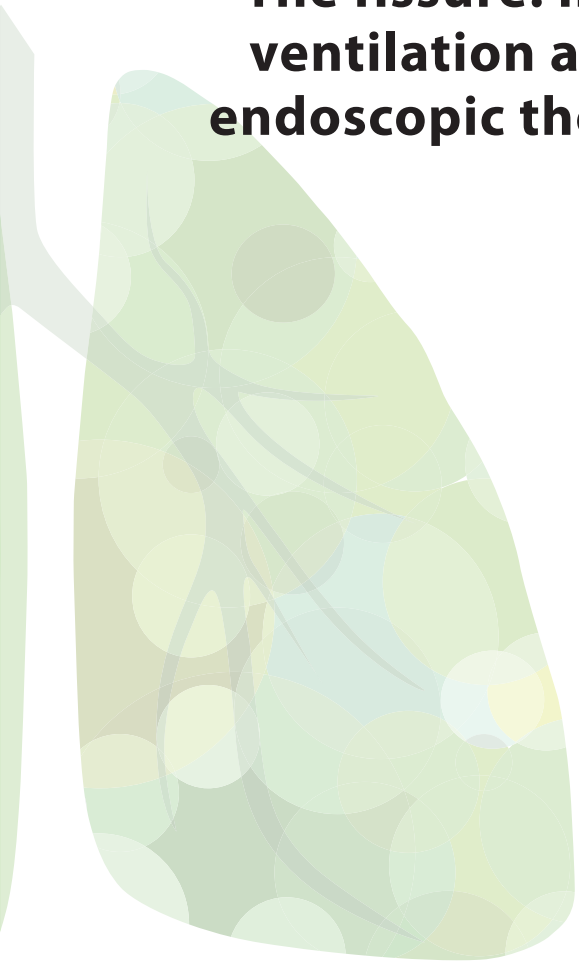


3



## CHAPTER 3

# The fissure: interlobar collateral ventilation and implications for endoscopic therapy in emphysema



T. David Koster  
Dirk-Jan Slebos

*Adapted from Int J Chron Obstruct Pulmon Dis, 2016 Apr 13;11:765-73*

## **ABSTRACT**

In patients with severe emphysema, bronchoscopic lung volume reduction using one-way valves is a promising therapeutic option to improve lung function and quality of life. The goal of this treatment is to achieve a complete lobar atelectasis. In a significant proportion of patients, this atelectasis cannot be achieved due to interlobar collateral ventilation. This collateral ventilation is generated through incomplete lobar fissures. Therefore, only patients with complete fissures and no collateral ventilation can be selected for endobronchial therapy with one-way valves. Incomplete fissures are very common and exhibit a great variation in anatomy. The reported prevalence is 17%–85% for the right major fissure, 19%–74% for the left major fissure, and 20%–90% for the minor fissure. There are several methods of measuring or predicting the presence of collateral ventilation, with computed tomography (CT) fissure analysis and the Chartis measurement being the most important. Fissure analysis on CT is an indirect method to measure the completeness of fissures as a surrogate for collateral ventilation. The Chartis system is an endobronchial method to directly measure the presence of collateral ventilation. Both methods have unique value, and the combination of both can accurately predict the treatment response to the bronchoscopic placement of endobronchial valves. This review provides an in-depth view of lung fissure and collateral ventilation to help understand its importance in selecting the appropriate patients for new emphysema treatments and thus avoid useless treatment in unsuitable patients.

## INTRODUCTION

In patients with severe emphysema, lung volume reduction surgery (LVRS) can improve the quality of life, exercise capacity and lung function.<sup>1</sup> However, LVRS is a highly invasive therapy and is associated with significant morbidity.<sup>1</sup> Therefore, other and less invasive techniques for reduction of lung volume have been studied. An emerging therapy for patients with severe emphysema is bronchoscopic lung volume reduction (BLVR). Several BLVR techniques have been investigated, including one-way endobronchial valves (EBVs) and lung volume reduction coils.<sup>2</sup> In patients with severe emphysema, treatment with one-way valves shows promising results.<sup>3</sup> The purpose of this technique is to induce an atelectasis in the most diseased lobe. Like LVRS, this might relieve symptoms in emphysema patients through a reduction in hyperinflation, with an improved function of diaphragm and chest wall mechanics. Furthermore, increase in elastic recoil pressure leads to increased expiratory airflow and the inhomogeneity of ventilation and perfusion is decreased, leading to an improvement in gas exchange.<sup>1,4</sup>

However, to achieve maximal clinical improvement with one-way valve treatment, it is important to achieve complete lobar atelectasis.<sup>4-6</sup> The most important factor that may prevent the development of this desired atelectasis after endobronchial one-way valve treatment is interlobar collateral ventilation (CV) through means of an incomplete interlobar fissure.<sup>4,6</sup> This led to the development of several methods to measure the CV and investigate the interlobar fissure integrity.

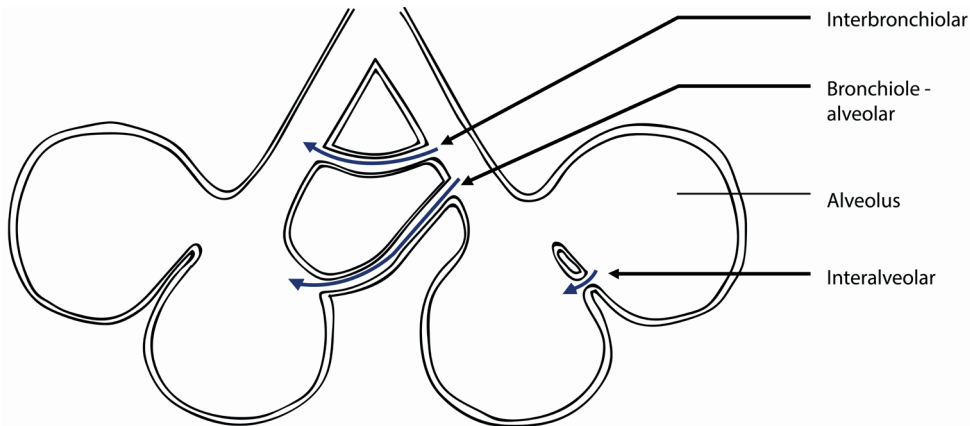
A combination of these measurements, together with endobronchial treatment using one-way valves, lead to a new and successful treatment of chronic obstructive pulmonary disease (COPD).<sup>3</sup> The use of the proper selection criteria enables customized care specifically applied to the individual patient, thereby showing real personalized medicine. This review will focus on the prevalence, assessment, and important role of CV and interlobar fissures with respect to BLVR.

### Collateral ventilation

CV is defined as “the ventilation of alveolar structures through passages or channels that bypass the normal airways”.<sup>7</sup> Intralobar CV (CV within a lobe, segment, or subsegment) was originally described as collateral respiration by Van Allen et al<sup>8</sup> in 1931. They observed that after obstruction of the bronchus of an airway, this was not always followed by alveolar collapse.

There are three main candidate pathways for CV to take place (**Figure 1**). The first described pathway consists of interalveolar communication of air through the pores of Kohn. These are situated in alveolar walls and should permit the passage of fluid and possibly air. However, these pores are small (<5 µm) and very high pressures (estimated 19.2 kPa or 196 cmH<sub>2</sub>O) would be necessary for air transport.<sup>9-13</sup> A second possible pathway is through accessory communication channels (30 µm in diameter) between distal bronchioles and alveoli, as described by Lambert.<sup>14</sup> The third pathway is described by Martin<sup>13</sup> and contains accessory respiratory bronchioles between the bronchioles of adjacent lung segments. This pathway is probably the most important pathway, due to the larger size (80–150 µm) of bronchioles and thus having a lower resistance when compared to the other pathways.<sup>12,13,15</sup>





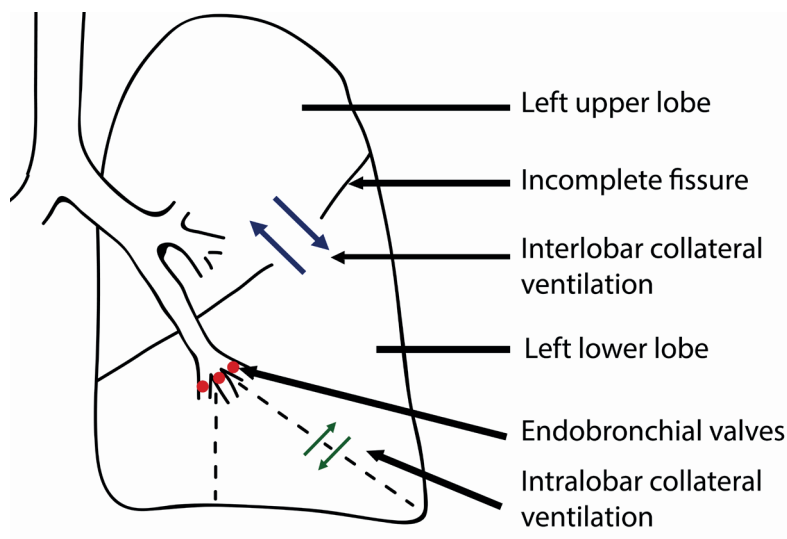
**Figure 1** - Three different pathways for collateral ventilation.

Interalveolar ventilation through the pores of Kohn. Bronchiole–alveolar ventilation through channels of Lambert. Interbronchiolar ventilation through channels of Martin.

In healthy persons, CV does not seem to play an important role, as the resistance of the collateral channels is much higher than the regular airways and large pressure gradients are needed for CV.<sup>12,16</sup> It is not exactly known why collateral channels exist or why they develop, but they all seem to originate after birth of both animals and humans.<sup>13</sup>

Despite their origin, CV may assume importance in several diseases. The prevention of atelectasis after obstruction is probably the most important function of CV. For example, obstruction of airways by mucus impaction, tumor or foreign bodies does not always lead to atelectasis due to CV.<sup>8</sup> Furthermore, in patients with emphysema, with increased airway resistance, collateral resistance is lower. This was demonstrated by Hogg et al,<sup>18</sup> who measured the resistance of CV in excised normal and emphysematous lungs. In normal lungs, the resistance of collateral channels was 260–330 cmH<sub>2</sub>O (25–324 kPa), whereas this was 5–20 cmH<sub>2</sub>O (0.5–2.0 kPa) in emphysematous lungs. Therefore, air flows much more easily through collateral channels in an emphysematous than a normal lung.<sup>17</sup> Although CV was first only described as intralobar ventilation, there is also interlobar (ie, between the lobes) CV across the fissures. Probably due to the same mechanism, the flow between different lobes is higher in patients with emphysema.<sup>15,17,18</sup>

Obviously, interlobar CV is an important factor in BLVR therapy, as this therapy is based on complete atelectasis of a lobe (**Figure 2**). Most probably, incomplete fissures are responsible for the interlobar collateral flow, although not found in every study regarding this subject.<sup>6,15</sup> There is no literature regarding the mechanism of CV in incomplete fissures between lobes. It can be assumed that the mechanism of collateral flow between lobes is the same as within a lobe.



**Figure 2** - Collateral ventilation.

Schematic figure illustrating the role of intra- and interlobar collateral ventilation, and the implications for bronchoscopic lung volume reduction using one-way endobronchial valves. The interlobar collateral ventilation from the left upper to the left lower lobe, impedes the desired atelectasis of the lower lobe. Because all segments of the left lower lobe have endobronchial valves, intralobar collateral ventilation does not influence the development of atelectasis.

### Embryology

Incomplete fissures are present in the majority of people and arise during fetal development. Approximately 4 weeks after conception, the airways start to develop. The respiratory diverticulum branches into two lung buds, which divide in the lobar bronchi.<sup>19</sup> During the development of the fetus, the coelomic cavity is divided into the pericardium, the pleural cavities and the peritoneal cavity. The pleural cavity is lined by a mesothelial membrane, the pleura. As the lung buds grow into the left and right pleural cavities, they are still covered by this membrane. The membrane covering the pleural cavity becomes the parietal pleura, whereas the mesothelial covering of the lung buds becomes the visceral pleura. As early as the visceral pleura has formed (after around 7 weeks), invaginations of the pleura start to separate the lobar bronchi. This gives rise to the lobar fissure and formation of the lung lobes. However, lobes can be fused if the pleura does not cover the complete lobe, leading to “incomplete fissures”. As the pleura invaginates from lateral, it can be assumed that the fissures are incomplete near the hilus most often, as will be described later.<sup>19,20</sup>

### Anatomy and prevalence of incomplete fissures

The anatomy of fissures and the completeness of fissures have been studied postmortem and by computed tomography (CT). Both the orientation (eg, medially, laterally) and the configuration (eg, concave, convex) exhibits a large variation. A large study performed by Aziz et al,<sup>21</sup> described the anatomy of the pulmonary fissures using high-resolution computed tomography (HRCT) in 662 patients without significant pulmonary disease. For the left major fissure, they found that, in most cases, the fissure faces medial in the superior zone (66%), lateral in the suprahilar zone (64%), and medial in the infrahilar and inferior zones (54% and 68%, respectively).<sup>21</sup> For the right major fissure, the fissure faces medial in the superior zone (85%) and lateral in the lower zones (63% suprahilar, 55% infrahilar, and 62% inferior). Other studies partly describe the same orientations, but individual variation is large.<sup>22–25</sup>

There is also some variation in the reported degree of incompleteness of the fissures. Some studies were based on autopsies. For example, Raasch et al<sup>22</sup> studied 100 lung specimens and found that incomplete fissures are very common. The incidence ranged from 70% in the right major fissure (mainly superior), 46% across the left major fissure (mainly inferior) and 94% across the minor fissure.<sup>22</sup> Other cadaver studies reported incomplete horizontal fissures in 47%–63% of cases, 36%–47% incomplete left oblique fissures, and 37%–39% incomplete right oblique fissures.<sup>26,27</sup>

Studies using CT also mention variable numbers, which are summarized in **Table 1**. The reported prevalence of incomplete fissures is 17%–85% for the right major fissure, 19%–74% for the left major fissure, and 20%–90% for the minor fissure.<sup>21,23,28–35</sup> These studies consistently find that compared to the other fissures, the minor fissure is incomplete most frequently. Furthermore fissures are incomplete near the hilus most frequently.<sup>21,30</sup> The reported prevalence exhibits a great variation. Possible explanations are the varying patient groups with and without pulmonary disease, different kind of reviewers, various or no criteria to define an incomplete fissure, or used CT-scan technique (eg, slice thickness).<sup>34</sup>

### Measurement of CV

There are several methods to assess the presence of CV. Invasive measurement methods include nuclear techniques and an endobronchial pulmonary assessment system. Noninvasive methods for measurement of CV include imaging techniques such as hyperpolarized gas magnetic resonance imaging (MRI) or CT-fissure analysis, which is an indirect method.

**Table 1** - Prevalence of incomplete fissures.

Author (year)	Subjects (N)	Research	Measurement	Incomplete (%)	Patient group/remarks
Aziz et al <sup>21</sup> (2004)	622	HRCT	Not described	RMF: 48 LMF: 43 MF: 63	No pulmonary disease
Koenigkam-Santos et al <sup>28</sup> (2013)	247	MDCT	<ul style="list-style-type: none"> <li>• Two radiologists</li> <li>• Consensus<sup>#</sup></li> </ul>	RMF: 81 LMF: 50 MF: 89	Varying population. No statistical difference between GOLD stages
Koenigkam-Santos et al <sup>29</sup> (2012)	35	MDCT	<ul style="list-style-type: none"> <li>• Two pneumologists and three radiologists</li> <li>• Consensus<sup>#</sup></li> </ul>	RMF: 85 LMF: 65–74 MF: 88–91	COPD GOLD III/IV
Gülsün et al <sup>23</sup> (2006)	144	HRCT	<ul style="list-style-type: none"> <li>• Two radiologists</li> <li>• Consensus<sup>#</sup></li> </ul>	RMF: 63 LMF: 60 MF: –	No pulmonary disease
Heřmanová et al <sup>30</sup> (2014)	250	HRCT	<ul style="list-style-type: none"> <li>• Medical student</li> <li>• Diagnostic criteria<sup>*</sup></li> </ul>	RMF: 35 LMF: 24 MF: 74	Varying population, no significant pathological changes
Cronin et al <sup>31</sup> (2010)	150	MDCT	<ul style="list-style-type: none"> <li>• Two radiologists</li> <li>• Consensus<sup>#</sup></li> </ul>	RMF: 34 LMF: 25 MF: 48	No pulmonary disease
Mahmut and Nishitani <sup>32</sup> (2007)	1.000	MDCT	<ul style="list-style-type: none"> <li>• Medical student</li> <li>• Diagnostic criteria<sup>*</sup></li> </ul>	RMF: 17 LMF: 19 MF: 20	Exclusion: lung lesions around interlobar fissures
Ozmen et al <sup>33</sup> (2010)	307	MDCT	<ul style="list-style-type: none"> <li>• Two radiologists</li> <li>• Consensus<sup>#</sup></li> </ul>	RMF: 70 LMF: 48 MF: 87	Exclusion: advanced fibrosis, kyphoscoliosis, chest deformity, massive pleural fluid, atelectasis, consolidation, or giant pleural bullae
Guan et al <sup>34</sup> (2015)	208	MDCT	<ul style="list-style-type: none"> <li>• Two radiologists</li> <li>• Diagnostic criteria<sup>*</sup></li> </ul>	RMF: 41 LMF: 46 MF: 62	No pulmonary disease
Pu et al <sup>35</sup> (2014)	573	HRCT	<ul style="list-style-type: none"> <li>• Computerized</li> </ul>	RMF: 74 LMF: 75 MF: 86	Healthy population and COPD-patients

<sup>\*</sup>Diagnostic criteria: 1) neither a clear avascular zone nor interlobar line is observed; 2) vascular images in adjacent lobes cross over the interlobar region; 3) pulmonary blood vessels, particularly the pulmonary vein, penetrate the interlobar region; 4) the pulmonary vein is observed in the interlobar region and is related to the vascular images in adjacent lobes. <sup>#</sup>Consensus: individual evaluation of fissure and classified as complete or incomplete, consensus with colleagues.

**Abbreviations:** HRCT, high-resolution computed tomography; MDCT, multidetector computed tomography; RMF, right major fissure/right oblique fissure; LMF, left major fissure/left oblique fissure; MF, minor fissure/horizontal fissure; COPD, chronic obstructive pulmonary disease; GOLD, Global initiative for chronic Obstructive Lung Disease.

### Endobronchial CV assessment

Although several endobronchial methods have been described for endobronchial assessment of CV, the study of Aljuri and Freitag<sup>36</sup> in 2009 was the first to present a method assessing collateral flow to predict the clinical response to BLVR treatment. Based on this technique the Chartis System® (PulmonX Inc., Redwood City, CA, USA) was developed, and is described and used in several articles regarding this topic.<sup>3,37–41</sup> The Chartis system consists of a catheter with a balloon component at the distal tip (**Figure 3A**). After inflation of the balloon, the airway is blocked and air from the targeted segment or lobe can flow only through the catheter (**Figure 3B**). The air is directed to the Chartis console, which can assess both expiratory air flow, pressure, and resistance (**Figure 3C–E**). If expiratory airflow persists after occlusion of a lobe, this indicates the presence of collateral airflow. In contrast, if there is no more flow, this indicates high collateral resistance and thus no collateral airflow, indicating a suitable candidate for BLVR therapy (**Figures 2 and 3**).<sup>42</sup>

Gompelmann et al<sup>43</sup> performed the first clinical trial with the Chartis system in 2010 and showed that in 90% of the patients, the measurements correctly predicted if atelectasis on chest radiograph would occur. A subsequent larger study by Herth et al<sup>44</sup> investigated the diagnostic value of the Chartis pulmonary assessment system to predict treatment response, defined as a target lung volume reduction (TLVR) of 350 mL or more. There was a total accuracy of 75%, with a positive predictive value of 71% and negative predictive value of 83%.

For optimal result and reliability of the Chartis measurement, there are several technical aspects to consider. For example, coughing or multiple mucus plugs might impede the measurement. Furthermore, especially in the lower lobes, the balloon might occlude a segment – for example, B6 in the left lower lobe – so that this segment may not get included in the assessment of CV. Moreover, dynamic airway collapse can occur, which might show as an abrupt or gradual ending of flow, with <100 mL of total exhaled air. To maximize the chance of a successful and reliable measurement, adequate training is required.<sup>37,43,45,46</sup> Furthermore, the measurement can be performed under general anesthesia with positive pressure support (**Figure 3E**), or high frequency jet ventilation. This creates optimal circumstances for a reliable and fast measurement, and if there is no CV, the treatment with EBVs can take place immediately, in the same treatment session (**Figure 4**).

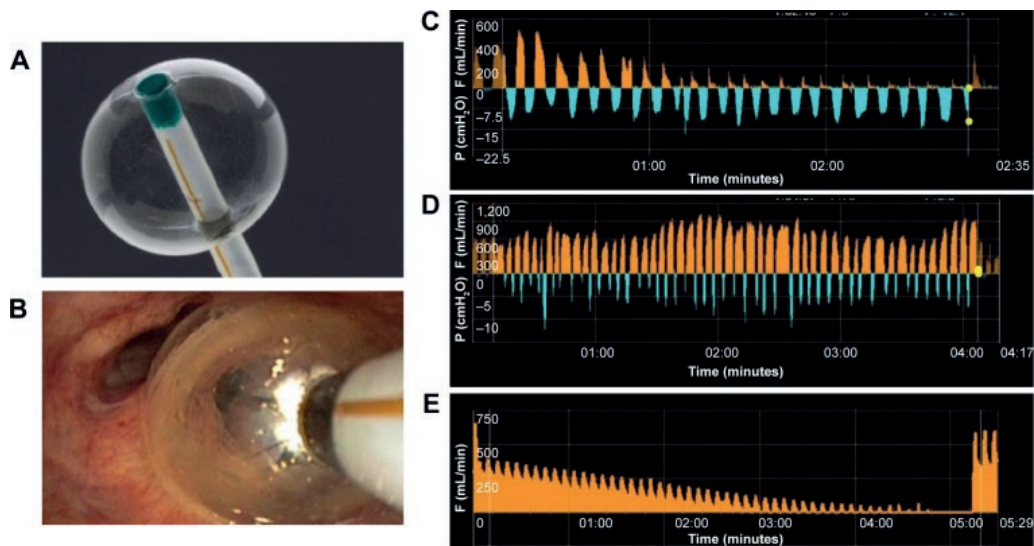
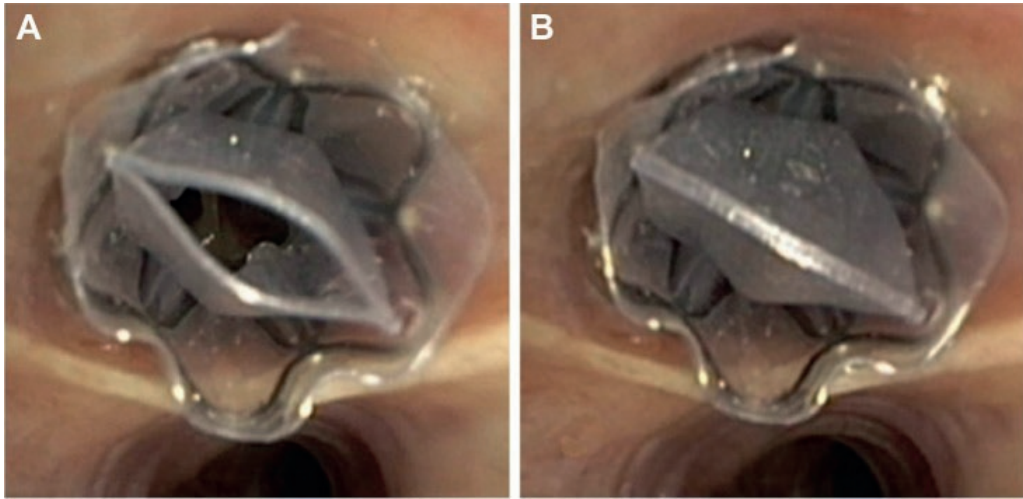


Figure 3 - Chartis measurement.

**A.** The Chartis balloon at the distal tip of the catheter. **B.** Bronchoscopic view of the Chartis balloon blocking the entrance to the right lower lobe to measure collateral ventilation to this lobe. **C.** Example of a negative Chartis measurement with absence of collateral ventilation, measured in spontaneous breathing patient. The orange pattern shows the expired flow (mL/min). The decrease of the flow pattern indicates there is no collateral flow. The blue pattern shows the negative intrapleural pressure (cmH<sub>2</sub>O) and indicates the quality of the occlusion by the balloon. **D.** Example of a positive Chartis measurement with collateral ventilation, as there is no decline in the expired flow. **E.** Example of a negative Chartis measurement with absence of collateral ventilation, measured in a sedated patient with positive pressure ventilation. Therefore, only the decreasing flow pattern is shown, indicating there is no collateral flow.

**Abbreviations:** F, flow; P, pressure.



**Figure 4** - Implanted one-way endobronchial valve.

A. Open valve, allowing trapped air and fluids to escape. B. Closed valve, no air or fluids can enter the valve.

### Nuclear techniques

Nuclear imaging can be used to demonstrate the presence of CV. For example, Morrell et al.<sup>47</sup> measured CV using a balloon-tipped catheter, to occlude segmental bronchi. Subjects then breathed heliox (79% helium, 21% oxygen) and the rise of helium concentration in the occluded segment was used as index for CV. Another study used <sup>133</sup>Xenon ventilation scintigraphy to prove the presence of interlobar CV, by selectively intubating a lobe and measuring the ventilation of the adjacent lobes.<sup>48</sup> Currently, there are no studies that compared the use of nuclear technique with Chartis measurement or CT-fissure analysis, nor their predictive values for developing atelectasis after endobronchial lung volume reduction therapy.

Another noninvasive method to measure CV was described by Marshall et al.<sup>49</sup> In this study, a mix of hyperpolarized <sup>3</sup>He and N<sub>2</sub> was inhaled and <sup>3</sup>He images were acquired using MRI during a single breath-hold. They found ventilation defects with delayed filling in a large proportion of patients. Although this delayed filling may be due to several causes (eg, CV, air trapping), the specific pattern of <sup>3</sup>He filling from the edges of the ventilation defect toward the centre was believed to be due to CV. However, although CV may be demonstrated by this method, it demonstrates intersegmental and not the interlobar CV. Therefore, this method is less valuable to predict the response to BLVR. Moreover, its availability is probably less than the other measurement methods in most clinics.

### CT-fissure analysis

A surrogate or indirect method for the measurement of CV is by using CT-fissure analysis. CT can be used to assess the completeness of the fissure. If a fissure is complete, there is most probably no CV. However, if the fissures are incomplete and lobes are fused, CV is very likely. Usually, the analysis is done by experienced radiologists or pulmonologists, but it is prone for interobserver variability.

Several authors described the following diagnostic criteria for incomplete interlobar fissures: "1) neither a clear avascular zone nor interlobar line is observed; 2) vascular images in adjacent lobes cross over the interlobar region; 3) pulmonary blood vessels, particularly the pulmonary vein, penetrate the interlobar region; 4) the pulmonary vein is observed in the interlobar region and is related to the vascular images in adjacent lobes."<sup>30,32,34</sup> Other authors did not use predefined diagnostic criteria, but they used consensus or experts opinion to describe the fissures as complete or incomplete.<sup>23,28,29,31,33</sup> Interobserver agreement was investigated by several authors. Koenigkam-Santos et al<sup>29</sup> described a high agreement between experienced radiologists for the major fissures, but rather moderate for the minor fissure ( $k=0.53$ ). Cronin et al<sup>31</sup> described a greater than 90% agreement for all fissures, Guan et al<sup>34</sup> found a fair to nearly perfect agreement between two radiologists ( $k=0.593-0.652$ ) and Koenigkam-Santos et al<sup>28</sup> described a reported interobserver agreement of 0.70–0.76. This is the case with experienced radiologists or pneumologists; inexperienced readers most probably have lower agreement. Several studies compared the results of CT to intraoperative assessment of the fissures. For example, Diso et al<sup>38</sup> evaluated a group of 21 patients undergoing surgery for lung cancer and then compared the intraoperative assessment of fissures to both the Chartis and HRCT measurement of fissures. Compared to inspection at surgery, Chartis measurement had an accuracy of 71% and HRCT of 76%; there was no significant difference between them. Kent et al<sup>50</sup> compared CT to intraoperative assessment and also found high predictive values for both major fissures but a positive predictive value of only 33% for the minor fissure. More recently, automatic methods have been developed to quantify the completeness of the fissures. Several of these methods have been described and used in literature, and the results are comparable to the interpretation of radiologists.<sup>35,37,51</sup>

### Studies comparing CT-fissure analysis and Chartis

The response of valve-based lung volume reduction can be predicted by both the Chartis measurement and the CT-fissure analysis. An interesting question is which of these methods is better to predict this response, or if a combination of both is better.

Currently, there are few studies that compare these methods. Schuhmann et al<sup>37</sup> retrospectively compared CT to the Chartis measurement in a testing dataset of 33 patients. A positive response to treatment was defined as a target lung volume reduction of 350 mL or more. The authors concluded that CT-fissure was comparable with Chartis ( $p=0.55$ ) with an accuracy of 75.8% for Chartis and 78.8% for CT. In this study, both methods disagreed in eleven



of 33 subjects, and the proportion of misclassifications was equal between both methods. However, in 22 of 33 subjects, the methods agreed and the classification into responders and nonresponders was 90.9% correct. There were no false negatives in subjects classified as nonresponders by both Chartis and CT. Two patients were misclassified as responders, but that was due to valve procedural errors in these patients. These results suggest that an agreement of both methods leads to few false positives or false negatives. Comparison of the combination of predictors (Chartis and CT) and CT alone resulted in a small but nonsignificant difference in favor of the combined model.

Gompelmann et al<sup>40</sup> also retrospectively compared Chartis to CT-fissure analysis in 69 patients. A complete fissure was defined as >90% of the fissure present. A positive result was defined as a TLVR  $\geq$ 350 mL. The Chartis method had an accuracy of 74% and the HRCT fissure analysis an accuracy of 77%, meaning both methods are similar in classifying patients to respond or not respond to EBV treatment. Both methods were concordant in two-thirds of the patients, similar to the study of Schuhmann et al.<sup>37</sup>

Reymond et al<sup>41</sup> compared CT-fissure analysis to the Chartis measurement in patients with severe emphysema, but not its clinical response. This retrospective study showed an agreement of 73% between the two methods, with a high sensitivity and few false negatives. Although these studies were retrospective and originally not designed to compare these methods, Chartis and CT-fissure analysis appear to be equivalent to correctly predict a positive or negative response to EBV. New and preferably prospective studies are required to confirm this conclusion and see if the combination of the two methods is superior to a single method to successfully predict the response to EBV.

### Clinical application

Another question is whether the measurement of CV is indeed correlated with the results of BLVR. The first study to correlate the success of EBV placement to CV was the Endobronchial Valve for Emphysema Palliation Trial (VENT), performed by Sciruba et al.<sup>6</sup> They randomly assigned patients to endobronchial therapy, independent of CV or fissure completeness. Although there was a significant improvement of pulmonary function in the treated patients, in a post hoc analysis, they found an enhanced effect of therapy in patients with complete fissures (>90% complete) on CT.

A European multicenter study by Herth et al,<sup>44</sup> designed as a validation study for the Chartis system, compared patients with and without CV. There were significantly more responders in the group without CV (target lung volume reduction of 350 mL or more). The TLVR was 743 versus 99 mL in favor of the group without CV. Furthermore, the FEV<sub>1</sub> increased (mean percentage 16 vs 1). The 6 minutes walking distance and St George's Respiratory Questionnaire were in favor of the collateral negative group, but not significant.

An important study is the BeLieVeR-HiFi study by Davey et al;<sup>39</sup> a double-blind sham controlled trial. Patients were selected for bronchoscopic intervention based on the CT-scan alone. They found an increase of the FEV<sub>1</sub> of 8.77%. However, the CV was also measured to compare these two methods. Of the 25 patients with intact fissures and who received EBVs, CV was found in four patients. These patients had no benefit or less benefit from the treatment.

More recently, Klooster et al<sup>3</sup> published the STELVIO-trial, a randomized controlled trial to compare endobronchial-valve treatment with standard medical care. Only patients with a complete or near complete fissure were included. CV was measured using the Chartis measurement system. Patients without interlobar CV were randomized to treatment with EBVs or as control. The EBV group improved significantly in FEV<sub>1</sub> (+22.7%), FVC (+442 mL), and 6 minutes walking distance (+106 m).<sup>3</sup>

An important question is whether the HRCT and Chartis measurement should always be used to determine if a patient is a potential responder to EBVs. Schuhmann et al<sup>37</sup> reported a high response rate of almost 65% if the fissure was >90% complete. Nevertheless, this means there is a significant proportion of patients without response. This is also shown by the studies by Klooster et al<sup>3</sup> and Davey et al.<sup>39</sup> As shown in both studies, an HRCT with complete or near complete fissure (>90%) does not predict the presence of CV in all patients. Therefore, the Chartis measurement is probably useful in all patients who are eligible for treatment with EBVs based on fissure completeness.

However, if the fissure is not (near) complete (<80%–90%), the chance of success is very small, and it is probably not necessary to perform a Chartis measurement.<sup>37</sup> The combination of a complete fissure on HRCT and no CV with Chartis measurement should result in an atelectasis of the target lobe. If nevertheless, there is no response, there is most likely a problem at the endobronchial level (forgotten subsegment, misplaced valve, wrong sizing), and a re-bronchoscopy might resolve the problem.<sup>6,46</sup>

### Airway bypass

Although this review mainly focuses on BLVR using EBVs, the concept of CV has also been used in the treatment of emphysema with so called “airway bypasses”.<sup>52</sup> With this method, a direct passage between the lung parenchyma and large airways or a transthoracic bypass is created, allowing air to exit the lung, and thus bypassing the expiratory flow limitation. CV then should ensure the exit of air and clinical benefit. Two approaches using the airway bypass have been investigated. The transthoracic airway bypass approach has been described by Saad Junior et al<sup>53</sup> and Moore et al.<sup>54</sup> Saad Junior et al<sup>53</sup> performed this procedure in three patients with emphysema. These patients reported improvement of symptoms. However, due to the small number treated, no statistical analysis was performed.<sup>53</sup> Moore et al<sup>54</sup> first performed an *ex vivo* study and found an increase in the expiratory flow (169–235 mL;  $P < 0.05$ ) after insertion of an extrapulmonary airway bypass in seven explanted emphysematous lungs. After that, an *in vivo* study was performed in four patients. There was a reduction of total lung capacity in all patients and an increase of the FEV<sub>1</sub> in three patients.<sup>54</sup> A larger study (trial ID: ACTRN12610000190000) using the transthoracic airway bypass approach was prematurely stopped due to lack of funding.<sup>55</sup>

The bronchoscopic approach to create airway bypasses using drug-eluting transbronchial airway stents has been extensively studied in severe emphysema patients. In the “EASE-trial” by Shah et al,<sup>56</sup> a multicentre, randomized, full sham bronchoscopy controlled trial, 319 patients were randomized and 212 were assigned to airway bypasses. Although after 1 day the pulmonary function significantly improved, showing a strong signal for proof of concept,

there was no sustained long-term effect at 6 months or 1 year due to closure of the created bypasses.<sup>56</sup> There are no other larger studies regarding this subject, and currently not much more is known about the optimal patient selection criteria, number of airway bypasses, and optimal target areas.

## **CONCLUSION**

Endobronchial lung volume reduction is a promising and proven effective therapy for selected patients with emphysema. The absence of interlobar CV is the most discriminating factor for therapeutic success, as collateral ventilation may prevent the intended lobar atelectasis after valve placement. CV is generated through incomplete lobar fissures. Therefore, only patients with complete fissures and no CV can be selected for endobronchial therapy. Both CT-fissure analysis (indirect) and Chartis measurement (direct) appear to successfully predict the presence of CV and thus the success rate of endobronchial therapy. Both methods have specific pros and cons. However, a combination of the two methods most probably provides the highest accuracy and has proven to successfully predict a positive or negative treatment response. This approach enables personalized medicine and provides an excellent treatment strategy in selected patients with the right phenotype of emphysema, whilst it avoids the possibility of unsuitable patients with the wrong phenotype undergoing useless treatment.

## REFERENCES

- 1 Tiong LU, Davies R, Gibson PG, et al. Lung volume reduction surgery for diffuse emphysema. *Cochrane Database Syst Rev.* 2006;18(4).
- 2 Mineshita M, Slebos D. Bronchoscopic interventions for chronic obstructive pulmonary disease. *Respirology.* 2014;19:1126–1137.
- 3 Klooster K, Ten Hacken N, Hartman J, Kerstjens H, van Rikxoort E, Slebos D. Endobronchial valves for emphysema without interlobar collateral ventilation. *N Engl J Med.* 2015;373(24):2325–2335.
- 4 Shah PL, Herth FJ. Current status of bronchoscopic lung volume reduction with endobronchial valves. *Thorax.* 2014;69(3):280–286.
- 5 Eberhardt R, Gompelmann D, Schuhmann M, Heussel CP, Herth FJ. Complete unilateral vs partial bilateral endoscopic lung volume reduction in patients with bilateral lung emphysema. *Chest.* 2012;142(4):900–908.
- 6 Sciruba FC, Ernst A, Herth FJ, et al; VENT Study Research Group. A randomized study of endobronchial valves for advanced emphysema. *N Engl J Med.* 2010;363(13):1233–1244.
- 7 Cetti E, Moore A, Geddes D. Collateral ventilation. *Thorax.* 2006;61(5):371–373.
- 8 Van Allen C, Lindskog G, Richter H. Collateral respiration. Transfer of air collaterally between pulmonary lobules. *J Clin Invest.* 1931;10(3):559–590.
- 9 Macklem P. Airway obstruction and collateral ventilation. *Physiol Rev.* 1971;51(2):368–436.
- 10 Menkes H, Traystman R. Collateral ventilation. *Am Rev Respir Dis.* 1977;116(2):287–309.
- 11 Gompelmann D, Eberhardt R, Herth F. Collateral ventilation. *Respiration.* 2013;85(6):515–520.
- 12 Delaunoy L. Anatomy and physiology of collateral respiratory pathways. *Eur Respir J.* 1989;2(9):893–904.
- 13 Martin H. Respiratory bronchioles as the pathway for collateral ventilation. *J Appl Physiol.* 1966;21(5):1443–1447.
- 14 Lambert M. Accessory bronchiolealveolar communications. *J Pathol Bacteriol.* 1955;70(2):311–314.
- 15 Higuchi T, Reed A, Oto T, et al. Relation of interlobar collaterals to radiological heterogeneity in severe emphysema. *Thorax.* 2006;61(5):409–413.
- 16 Terry P, Traystman R, Newball H, Batra G, Menkes H. Collateral ventilation in man. *N Engl J Med.* 1978;298(1):10–15.
- 17 Tsai L, Hoffman A, Mazan M, Ingenito E. Bronchoscopic measurement of collateral ventilation in a sheep model of emphysema. *Respiration.* 2007;74(5):565–571.
- 18 Hogg J, Macklem P, Thurlbeck W. The resistance of collateral channels in excised human lungs. *J Clin Invest.* 1969;48(3):421–431.
- 19 Fishman A, Elias J, Fishman J, Grippi M, Senior R, Pack A. *Fishman's Pulmonary Diseases and Disorders.* 4th ed. New York: McGraw-Hill Professional; 2008:123–127.
- 20 Light RW. Chapter 1. Anatomy of the pleura. In: *Pleural Diseases.* 5th ed. Philadelphia: Lippincott Williams & Wilkins; 2007:1–6.
- 21 Aziz A, Ashizawa K, Nagaoki K, Hayashi K. High resolution CT anatomy of the pulmonary fissures. *J Thorac Imaging.* 2004;19(3):186–191.
- 22 Raasch B, Carsky E, Lane E, O'Callaghan J, Heitzman E. Radiographic anatomy of the interlobar fissures: a study of 100 specimens. *AJR Am J Roentgenol.* 1982;138(6):1043–1049.
- 23 Gülsün M, Ariyürek O, Cömert R, Karabulut N. Variability of the pulmonary oblique fissures presented by high-resolution computed tomography. *Surg Radiol Anat.* 2006;28(3):293–299.
- 24 Proto A, Ball JJ. Computed tomography of the major and minor fissures. *AJR Am J Roentgenol.* 1983;140(3):439–448.

- 25 Hayashi K, Aziz A, Ashizawa K, Hayashi H, Nagaoki K, Otsuji H. Radiographic and CT appearances of the major fissures. *Radiographics*. 2001;21(4):861–874.
- 26 Meenakshi S, Manjunath K, Balasubramanyam V. Morphological variations of the lung fissures and lobes. *Indian J Chest Dis Allied Sci*. 2004;46(3):179–182.
- 27 Prakash B, Shashirekha M, Suma H, Krishna C, Singh G. Lung morphology: a cadaver study in Indian population. *Ital J Anat Embryol*. 2010;115(3):235–240.
- 28 Koenigkam-Santos M, de Paula WD, Owsijewitsch M, et al. Incomplete pulmonary fissures evaluated by volumetric thin-section CT: semi-quantitative evaluation for small fissure gaps identification, description of prevalence and severity of fissural defects. *Eur J Radiol*. 2013;82(12):2365–2370.
- 29 Koenigkam-Santos M, Puderbach M, Gompelmann D, et al. Incomplete fissures in severe emphysematous patients evaluated with MDCT: incidence and interobserver agreement among radiologists and pneumologists. *Eur J Radiol*. 2012;81(12):4161–4166.
- 30 Heřmanová Z, Ctvrtlík F, Heřman M. Incomplete and accessory fissures of the lung evaluated by high-resolution computed tomography. *Eur J Radiol*. 2014;83(3):595–599.
- 31 Cronin P, Gross BH, Kelly AM, Patel S, Kazerooni EA, Carlos RC. Normal and accessory fissures of the lung: evaluation with contiguous volumetric thin-section multidetector CT. *Eur J Radiol*. 2010;75(2):e1–e8.
- 32 Mahmut M, Nishitani H. Evaluation of pulmonary lobe variations using multidetector row computed tomography. *J Comput Assist Tomogr*. 2007;31(6):956–960.
- 33 Ozmen CA, Nazaroglu H, Bayrak AH, Senturk S, Akay HO. Evaluation of interlobar and accessory pulmonary fissures on 64-row MDCT. *Clin Anat*. 2010;23(5):552–558.
- 34 Guan CS, Xu Y, Han D, Chen JH, Wang XL, Ma DQ. Volumetric thin-section CT: evaluation of pulmonary interlobar fissures. *Diagn Interv Radiol*. 2015;21(6):466–470.
- 35 Pu J, Wang Z, Gu S, et al. Pulmonary fissure integrity and collateral ventilation in COPD patients. *PLoS One*. 2014;9(5):e96631.
- 36 Aljuri N, Freitag L. Validation and pilot clinical study of a new bronchoscopic method to measure collateral ventilation before endobronchial lung volume reduction. *J Appl Physiol*. 2009;106(3):774–783.
- 37 Schuhmann M, Raffy P, Yin Y, et al. Computed tomography predictors of response to endobronchial valve lung reduction treatment. Comparison with Chartis. *Am J Respir Crit Care Med*. 2015;191(7):767–774.
- 38 Diso D, Anile M, Carillo C, et al. Correlation between collateral ventilation and interlobar lung fissures. *Respiration*. 2014;88(4):315–319.
- 39 Davey C, Zoumot Z, Jordan S, et al. Bronchoscopic lung volume reduction with endobronchial valves for patients with heterogeneous emphysema and intact interlobar fissures (the BeLieVeR-HiFi study): a randomised controlled trial. *Lancet*. 2015;386(9998):1066–1073.
- 40 Gompelmann D, Eberhardt R, Slebos DJ, et al. Diagnostic performance comparison of the Chartis System and high-resolution computerized tomography fissure analysis for planning endoscopic lung volume reduction. *Respirology*. 2014;19(4):524–530.
- 41 Reymond E, Jankowski A, Pison C, et al. Prediction of lobar collateral ventilation in 25 patients with severe emphysema by fissure analysis with CT. *AJR Am J Roentgenol*. 2013;201(4):571–575.
- 42 Mantri S, Macaraeg C, Shetty S, et al. Technical advances: measurement of collateral flow in the lung with a dedicated endobronchial catheter system. *J Bronchology Interv Pulmonol*. 2009;16(2):141–144.
- 43 Gompelmann D, Eberhardt R, Michaud G, Ernst A, Herth FJ. Predicting atelectasis by assessment of collateral ventilation prior to endobronchial lung volume reduction: a feasibility study. *Respiration*. 2010;80(5):419–425.
- 44 Herth F, Eberhardt R, Gompelmann D, et al. Radiological and clinical outcomes of using Chartis™ to plan endobronchial valve treatment. *Eur Respir J*. 2013;41(2):302–308.


- 45 Gesierich W, Samita K, Behr J. Determining collateral ventilation during bronchoscopy: unanswered questions. *Thorax*. 2014;69(3):289–290.
- 46 Shah PL, Herth F. Dynamic expiratory airway collapse and evaluation of collateral ventilation with Chartis. *Thorax*. 2014;69(3):290–291.
- 47 Morrell NW, Wignall BK, Biggs T, Seed WA. Collateral ventilation and gas exchange in emphysema. *Am J Respir Crit Care Med*. 1994;150(3):635–641.
- 48 Salanitri J, Kalff V, Kelly M, Holsworth L, Williams T, Snell G. 133Xenon ventilation scintigraphy applied to bronchoscopic lung volume reduction techniques for emphysema: relevance of interlobar collaterals. *Intern Med J*. 2005;35(2):97–103.
- 49 Marshall H, Deppe M, Parra-Robles J, et al. Direct visualisation of collateral ventilation in COPD with hyperpolarised gas MRI. *Thorax*. 2012;67(7):613–617.
- 50 Kent MS, Ridge C, O'Dell D, Lo P, Whyte R, Gangadharan SP. The accuracy of computed tomography to predict completeness of pulmonary fissures. A prospective study. *Ann Am Thorac Soc*. 2015;12(5):696–700.
- 51 van Rikxoort E, Goldin JG, Galperin-Aizenberg M, et al. A method for the automatic quantification of the completeness of pulmonary fissures: evaluation in a database of subjects with severe emphysema. *Eur Radiol*. 2012;22(2):302–309.
- 52 Lausberg HF, Chino K, Patterson GA, Meyers BF, Toeniskoetter PD, Cooper JD. Bronchial fenestration improves expiratory flow in emphysematous human lung. *Ann Thorac Surg*. 2003;75(2):393–398.
- 53 Saad Junior R, Dorgan Neto V, Botter M, Stibulov R, Rivaben JH, Gonçalves R. Therapeutic application of collateral ventilation with pulmonary drainage in the treatment of diffuse emphysema: report of the first three cases. *J Bras Pneumol*. 2009;35:14–19.
- 54 Moore AJ, Cetti E, Haj-Yahia S, et al. Unilateral extrapulmonary airway bypass in advanced emphysema. *Ann Thorac Surg*. 2010;89:899–906.
- 55 Slebos D, Klooster K, Erasmus M. Emphysema! *Am J Respir Crit Care Med*. 2012;186(2):197.
- 56 Shah P, Slebos D, Cardoso P, et al. Bronchoscopic lung-volume reduction with Exhale airway stents for emphysema (EASE trial): randomised, sham-controlled, multicentre trial. *Lancet*. 2011;(378):997–1005.

4



## CHAPTER 4

# Predicting Lung Volume Reduction after Endobronchial Valve Therapy Is Maximized Using a Combination of Diagnostic Tools



**T. David Koster**

Eva M van Rikxoort

Ralf-Harto Huebner

Felix Doellinger

Karin Klooster

Jean-Paul Charbonnier

Sri Radhakrishnan

Felix J.F. Herth

Dirk-Jan Slebos



## **ABSTRACT**

### **Background**

Bronchoscopic lung volume reduction using one-way endobronchial valves (EBVs) has been proven to be effective in patients with severe emphysema. However, the selection of patients without collateral ventilation prior to treatment is critical for procedural success. Collateral ventilation can be assessed directly with the Chartis system or indirectly using computed tomography (CT) fissure analysis.

### **Objectives**

We retrospectively evaluated the diagnostic value of a combination of the quantitative CT interlobar fissure completeness score (FCS) and Chartis in predicting responders to EBV therapy.

### **Methods**

CT data from four prospective studies were pooled and analyzed using semiautomated software to quantify the completeness of interlobar fissures. These FCSs were compared to a reference standard of achieving  $\geq 350$  ml of target lobe volume reduction after EBV treatment. Using a receiver operating characteristic curve, optimal thresholds predictive of complete fissures (responders) and incomplete fissures (non-responders) were determined. A subgroup of patients with partially complete fissures was identified, where software had lower accuracy. The complementary value of Chartis was investigated in this group.

### **Results**

A fissure was defined as complete (FCS  $> 95\%$ ), incomplete (FCS  $< 80\%$ ), or partially complete ( $80\% < \text{FCS} < 95\%$ ). The positive predictive value (PPV) of complete fissures is 88.1%, and the negative predictive value (NPV) is 92.9%, with an overall accuracy of 89.2%. Chartis was utilized in patients with partially complete fissures, with a PPV of 82.3%, an NPV of 84.6%, and an accuracy of 83.3%.

### **Conclusion**

Combining diagnostic tools could reduce the burden on patients and the healthcare system while providing clinicians with a better means for patient selection for EBV therapy.

## INTRODUCTION

Approximately 8% of the global population suffers from chronic obstructive pulmonary disease (COPD).<sup>1</sup> Severe emphysema is a subpopulation of highly symptomatic COPD patients suffering from dyspnea due to lung hyperinflation, with a reduced life expectancy and with very few effective therapeutic alternatives.<sup>1</sup> Bronchoscopic lung volume reduction using endobronchial valves (EBVs) has recently been shown to deliver substantial, clinically relevant improvements to emphysema patients with hyperinflation. In this therapy, one-way EBVs are delivered via a bronchoscope, with the goal of occluding a lobe and collapsing hyperinflated lung regions by allowing trapped gas to exit while preventing inflow during inhalation.<sup>2</sup> The key predictor for response to EBV therapy has been shown to be the selection of patients, with low collateral ventilation between the target lobe to be occluded and the adjacent lobe(s).<sup>3,4</sup> There are several methods to measure the presence of collateral ventilation.<sup>5</sup> A well-studied direct measurement of collateral airflow is the Chartis system® (Pulmonx, Redwood City, Calif., USA), which is an endobronchial pulmonary assessment system.<sup>6,7</sup> However, performing this measurement requires a bronchoscopy, can include procedural challenges, and, when used in a broader population, will result in a substantial number of patients undergoing a bronchoscopy who will not receive EBVs.<sup>6-9</sup> Alternately, an indirect assessment of collateral ventilation is anatomical fissure analysis using computed tomography (CT). A complete fissure on CT is considered a surrogate for the absence of collateral ventilation. Goldin and Abtin<sup>10</sup> proposed that, if >90% of the fissure could be visualized on at least one axis (sagittal, axial, or coronal view), the fissure should be considered complete, implying the absence of significant collateral ventilation between the adjoining lobes. Several studies have adopted this, without subsequent refinement of this ad hoc threshold.<sup>3,8,11,12</sup> However, outside the experienced radiology core lab setting, visual estimation of fissure completeness has been associated with a rather poor interobserver agreement.<sup>13</sup> Several computerized semiautomated methods to quantify the completeness of fissures have been developed, which claim to reduce the interobserver variability or complement the visual read of an experienced radiologist.<sup>14,15</sup> These methods are more efficient and have an improved reliability over visual methods. A recent study concluded that the optimal treatment algorithm might be a combination approach, using radiology for an anatomical classification based on fissure completeness, and a physiologic measure of airflow in patients with partially complete fissures.<sup>16</sup> In this study, we evaluated the diagnostic value of the combination of a quantitative CT (QCT) interlobar fissure completeness score (FCS) and Chartis in predicting responders to EBV therapy, with the aim to develop a diagnostic workflow providing clinicians with a better tool for patient selection.

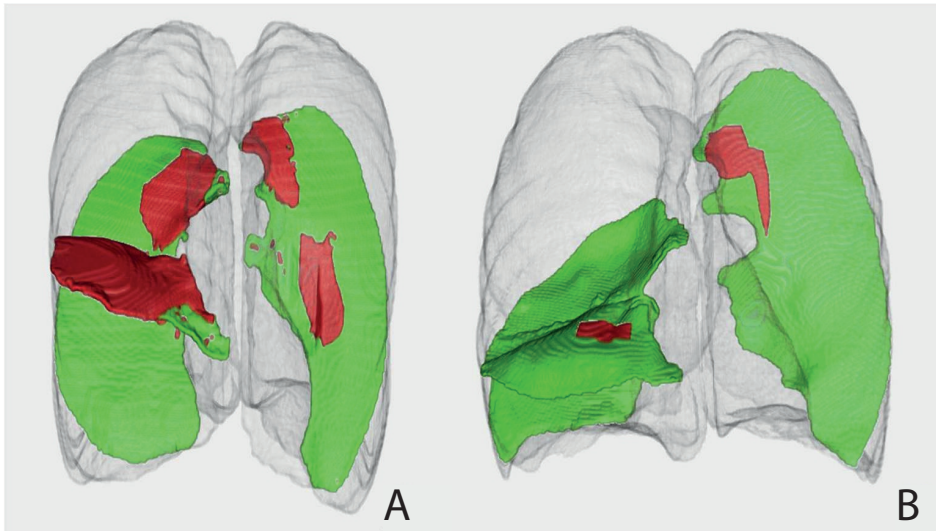
## METHODS

### Subjects and Study Design

This study is a retrospective analysis of 547 patients based on pooled data collected from four prospective studies. The clinical trial registrations and procedures of these studies have been described in detail before.<sup>3,4,6,12,17</sup> One dataset is derived from a postmarketing registration study with the goal to evaluate the outcome after endoscopic lung volume reduction, which has not been previously published but has been approved by the Ethics Committee of Charité University Hospital, Berlin, Germany (EA1/136/13). A part of this German dataset has been used to retrospectively assess the occurrence of pneumothorax after EBV treatment.<sup>18</sup> Prior to the analysis, all patient records and information were deidentified and rendered anonymous, and the analysts performing the QCT evaluation were provided baseline scans only and were blinded to the posttreatment clinical outcomes. Cases were deemed eligible if they received EBV therapy and if follow-up CT scans were performed. To reflect routine clinical practice, CT scans from 16 sites in the United States and 17 European sites collected from 2004 through 2015 were considered for analysis. Cases were excluded if there was a lack of procedural success placing valves, as confirmed by bronchoscopy or an independent radiology core lab, since this is a confounding variable for the predictive ability of any diagnostic tool used. Cases were also excluded if the quality of the scans were insufficient for QCT analysis, for example thick slices or missing slices, resulting in an incomplete reconstruction.

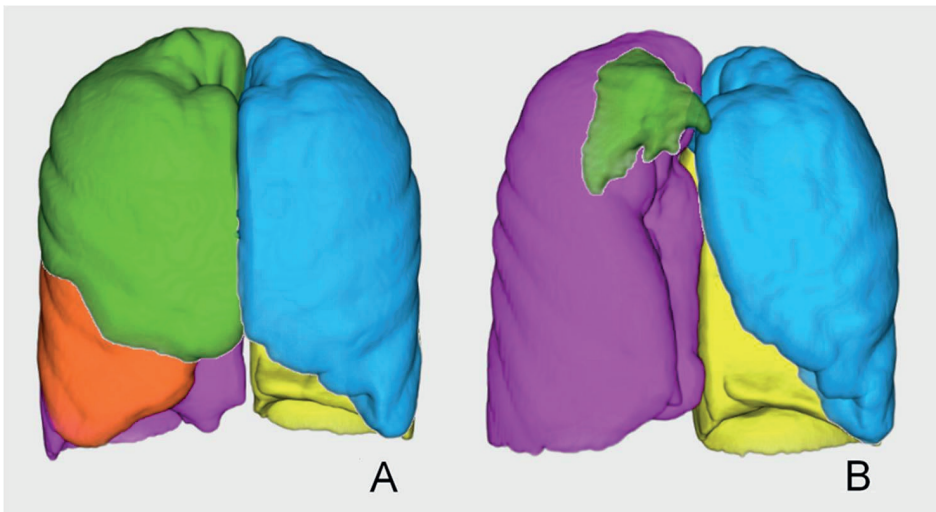
### Image Analysis

Since the goal of QCT used in conjunction with EBV therapy is lung volume reduction, target lobe volume reduction (TLVR) was considered the gold standard for determining the accuracy of predicting response. A TLVR of  $\geq 350$  ml has previously been established as a measure of procedural success.<sup>6</sup> QCT analysis was performed on all baseline CT scans at Thirona (Thirona BV, Nijmegen, The Netherlands) using Thirona LungQ version 1.0.0 to assess fissure completeness and lobar tissue destruction at baseline for each subject. In each scan, the lungs, pulmonary fissures, and pulmonary lobes were automatically segmented, visually checked, and edited by trained medical analysts.<sup>19,20,21,22</sup> Each scan was read by two medical analysts, with the first analyst editing the segmentation results where needed and the second analyst checking the results. Based on the results of the lobe and fissure segmentations, an FCS (**Figure 1**) was computed for each lobe as the percentage of the lobar boundaries defined by a fissure.<sup>15</sup> Within the segmented lobes, attenuation thresholding (in Hounsfield units, HU) was performed to quantify the emphysema severity as the percentage of voxels below  $-910$  HU, as previously defined.<sup>15</sup> Once the FCSs were finalized, precalculated TLVR scores, determined from the change in volume of the target lobe before and after EBV therapy (**Figure 2**), were utilized to dichotomize all subjects into responders and non-responders, with a non-responder defined as a subject with  $< 350$  ml reduction and a responder defined as a subject with  $\geq 350$  ml volume reduction.



**Figure 1** - 3D rendering of the FCS, where the red areas reflect incomplete portions of the interlobar fissure, and the green areas reflect the complete portions.

**A.** Target left upper lobe with 80% FCS. **B.** Target right upper lobe with 96.5% FCS for the major and minor fissures combined.



**Figure 2** - 3D rendering of lobes.

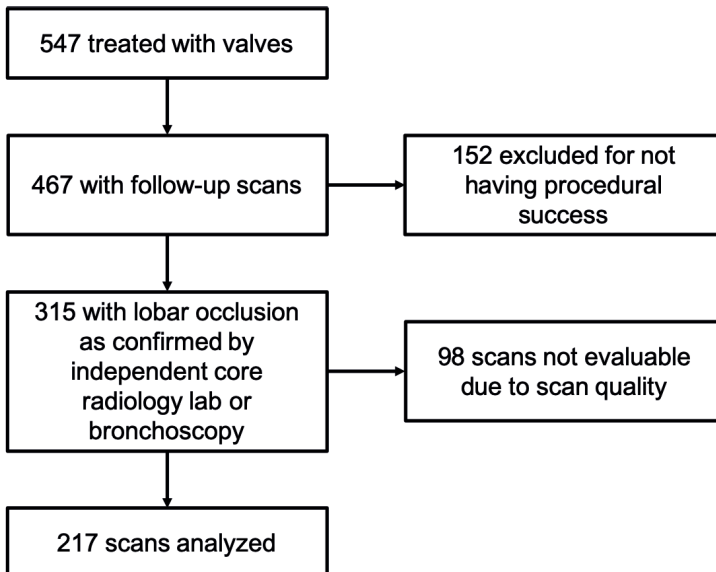
**A.** Pretreatment with EBVs. **B.** Posttreatment with EBVs, displaying 2,121 ml of volume reduction with a combined right upper lobe and right middle lobe treatment with subsequent right lower lobe expansion. Green = Right upper lobe; orange = right middle lobe; purple = right lower lobe; blue = left upper lobe; yellow = left lower lobe.

### Statistical Analysis

The FCS was evaluated for its ability to predict a responder (TLVR  $\geq 350$  ml), using a receiver operating characteristics (ROC) curve. Sensitivity and specificity were calculated for specific FCSs in 5% increments to identify the optimal threshold which maximized the sensitivity and specificity. The positive predictive value (PPV), negative predictive value (NPV), sensitivity, specificity, and accuracy of the QCT system were computed by applying the optimal FCS threshold. To investigate the combined use of QCT and Chartis, a lower FCS threshold was determined, minimizing false negatives below this threshold. The application of both FCS thresholds results in three groups: complete fissures (FCS > optimal threshold), incomplete fissures (FCS < lower threshold), and partially complete fissures (optimal threshold < FCS < lower threshold). In the partially complete fissure group, where sensitivity and specificity of QCT are suboptimal, the use of Chartis for decision to treat is analyzed.

### RESULTS

Valve treatment was initially performed in 547 subjects, and, as shown in **Figure 3**, we eventually included 217 subjects in our analysis. The baseline characteristics of the included subjects are presented in **Table 1**. In the 217 patients, the right lower lobe was targeted in 7% of the cases, the right upper lobe in 33%, the left upper lobe in 28%, the left lower lobe in 27%, the middle lobe in 0.5%, and the right upper or lower lobe together with the middle lobe in 4.6 and 0.5%, respectively. The ROC curve showed an area under the curve of 0.86. The best cutoff to maximize sensitivity and specificity was an FCS of 95% (**Figure 4**).

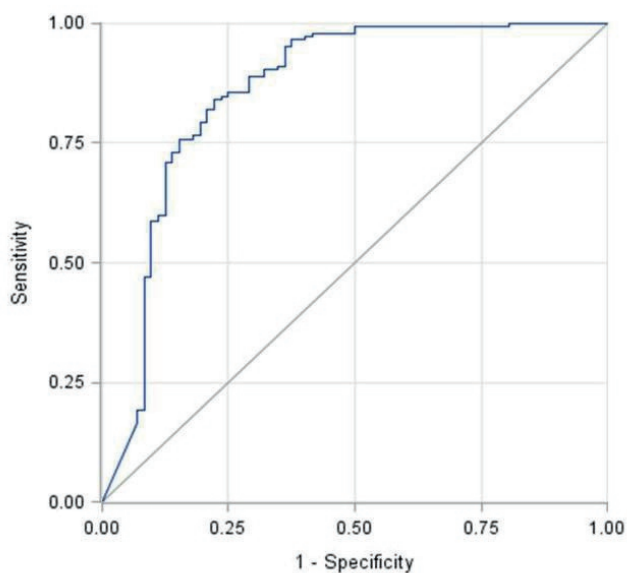


**Figure 3** - Patient flow diagram.

**Table 1** - Baseline demographics and disease characteristics.

Age	62.3 ( $\pm$ 7.9)
Male (%)	51
FEV <sub>1</sub> (%pred)	29.8 ( $\pm$ 8.0)
FVC (%pred)	72.2 ( $\pm$ 17.1)
TLC (%pred)	127.3 ( $\pm$ 16.1)
RV (%pred)	220.7 ( $\pm$ 46.1)
6MWT (m)	327.7 ( $\pm$ 106)
Emphysema Destruction Score in target lobe @-910 HU (%)	67.5 ( $\pm$ 10.9)

**Abbreviations:** FEV<sub>1</sub>: forced expiratory volume in 1 second; FVC: forced vital capacity; TLC: total lung capacity; RV: residual volume; 6MWT: six minute walking test; HU: Hounsfield units



Fissure Score Cut Off	Se	Sp
>95%	84%	78%
>90%	91%	65%
>85%	97%	61%
>80%	98%	53%
>75%	99%	35%

**Figure 4** - ROC curve for predicting response based on FCS, with an AUC of 0.8602, together with the accompanying sensitivity and specificity in predicting responders to treatment with EBVs. Se = Sensitivity; Sp = specificity.

The PPV, NPV, sensitivity, specificity, and accuracy of the QCT system using the FCS >95% were computed and are provided in table 2. Based on the ROC curve (**Figure 4**), the lower threshold representing incomplete fissures was determined to be FCS <80%. Applying a <80% do-not-treat and a >95% treat algorithm to the entire dataset, the algorithm had an overall accuracy of 89.2%, not including the 80% < FCS < 95% population (**Table 2**).

To explore the possibility of combining diagnostic tools, all subjects with partially complete fissures (i.e. 80% < FCS < 95%) were further evaluated for the presence of a baseline Chartis assessment, and 30 subjects, all from one study, had evaluable Chartis assessments.<sup>6</sup> Applying previously described waveform analysis criteria for predicting responders and applying the same criteria as above ( $\geq 350$  ml TLVR) for defining a responder,<sup>18,23</sup> Chartis was found to have an accuracy of 83.3% in this subgroup of partially complete fissures, as shown in **Table 2**.

**Table 2** - Predictive values of FCS and Chartis.

	Responder	Non-responder	Prevalence	
<b>FCS threshold of 95%<sup>1</sup></b>				
FCS>95%	119	16	135	PPV = 88.1%
FCS<95%	26	56	82	NPV = 68.3%
	Se = 82.1%	Sp = 77.8%		Accuracy = 80.1%
<b>FCS threshold of 80%<sup>2</sup></b>				
FCS>80%	142	33	175	PPV = 81.1%
FCS<80%	3	39	42	NPV = 92.9%
	Se = 97.9%	Sp = 54.1%		Accuracy = 83.4%
<b>80%&lt;FCS&lt;95%<sup>3</sup></b>				
FCS>95%	119	16	135	PPV = 88.1%
FCS<80%	3	39	42	NPV = 92.9%
	Se = 97.5%	Sp = 70.9%		Accuracy = 89.2%
<b>Chartis system<sup>4</sup></b>				
CV-	14	3	17	PPV = 82.3%
CV+	2	11	13	NPV = 84.6%
	Se = 87.5%	Sp = 78.6%		Accuracy = 83.3%

Responder: TLVR  $\geq 350$  mL; non-responder: TLVR < 350 mL. <sup>1</sup> Predictive values and accuracy for an FCS threshold of 95%. <sup>2</sup> Predictive values and accuracy for an FCS threshold of 80%. <sup>3</sup> Predictive values and accuracy for an 80% < FCS > 95%. <sup>4</sup> Predictive values and accuracy for an FCS threshold of 95%. Abbreviations: Se: sensitivity; Sp: specificity; CV-: no collateral ventilation measured by Chartis; CV+: collateral ventilation measured by Chartis.

## DISCUSSION

### Interpretation

The treatment of severe emphysema with EBV therapy has been proven effective in randomized controlled trials.<sup>4,11</sup> However, optimal patient selection continues to be an area of clinical research. QCT analysis is a rapidly emerging field in pulmonary diagnosis and a potential powerful tool in emphysema disease staging for advanced therapies.

In this study, we identified thresholds for applying a proprietary QCT algorithm for classifying patients, and a strategy for selectively using Chartis for increased diagnostic yield. In patients with complete fissures (>95% FCS), the algorithm provides an 88.1% PPV; therefore, there may be little diagnostic value in subjecting these patients to an additional physiological Chartis assessment, and these patients may be treated with EBV without further evaluation. Since for patients with incomplete fissures (<80% FCS) the algorithm provides a 92.9% NPV, these patients can be excluded from further EBV treatment or additional invasive diagnostics without denying treatment to a large group of patients. Thus, QCT can be used as a prescreening tool for all patients, and Chartis can be used selectively, only on patients with partially complete fissures.

### Comparison to the Literature

A few studies have investigated the diagnostic value of fissure completeness for prescreening prior to EBV therapy. Gompelmann et al.<sup>12</sup> visually reviewed CT scans for evaluating fissure completeness above or below a 90% threshold. A similar reference standard of volume reduction  $\geq 350$  ml was applied to define responders. They found an accuracy of 77%, a sensitivity of 75%, and a specificity of 78.8%, which were slightly lower than those in our experience. This could be due to multiple factors - the fissure threshold applied or the variability in visually assessing the fissures, though these scans were reviewed at a radiology core lab. This study may indicate the issues with nonexperienced readers in the clinical setting, estimating the completeness of the fissure while manually scrolling through the 300-500 slices of a high-resolution CT. Schumann et al.<sup>8</sup> used quantitative imaging software to retrospectively compare its accuracy to the Chartis system in 134 patients using the same reference standard of TLVR  $\geq 350$  ml. Based on regression analysis of 34 QCT variables, three predictors for successful lung volume reduction were identified: fissure completeness, low attenuation clusters, and a vascular index. Using fissure completeness as a single feature yielded an area under the ROC curve of 0.75, which was not statistically different from using all three features (area under the ROC curve of 0.80). Applying a bimodal distribution of patients above and below a single threshold of 90% fissure completeness, the overall accuracy was 75.8%, with a sensitivity of 83.3% and a specificity of 66.7%, which was similar to the results of QCT alone in our study. The third study was performed by de Oliveira et al.<sup>16</sup>, who retrospectively analyzed 38 treated patients. They investigated the relationship



between fissure completeness and clinically relevant lobar volume reduction ( $\geq 350$  ml), using a QCT analysis. A fissure completeness  $>90\%$  was found to have a PPV of 90.5%, whereas  $<75\%$  fissures had an NPV of 100%. The accuracy of the QCT in the middle zone (between 75 and 90% fissure completeness) was lower, and the authors suggested the use of the Chartis system in this middle zone.

### Limitations of the Study

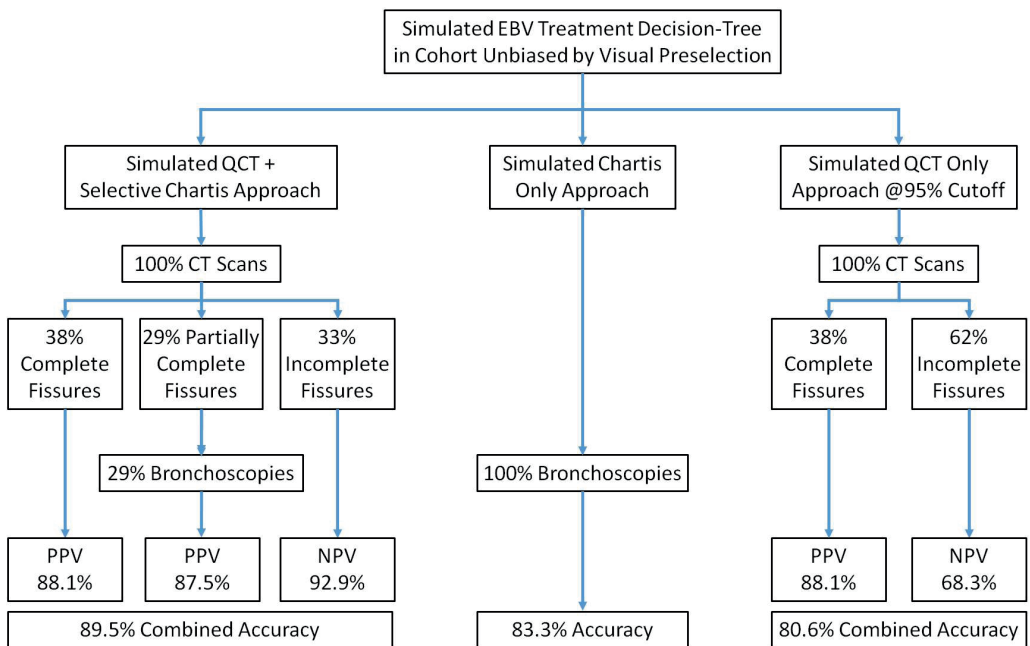
One of the limitations of this study is that it is a retrospective study pooling multiple trials with slightly different inclusion criteria. The more recent studies only included patients with visually complete fissures on CT to avoid diagnostic bronchoscopies with the Chartis system, whereas the earlier studies did not use fissure completeness for patient selection. Depending on the FCS threshold used, our dataset had anywhere from 62% (with FCS  $>95\%$ ) to 79% (with FCS  $>80\%$ ) patients with complete fissures, which is not representative of the overall population.<sup>5</sup> Using the FSC thresholds of 95% and 80% in the subgroup of 123 patients from two studies, where patients were not visually preselected based on their fissure status, we found the distribution to be 38% complete fissures, 33% incomplete fissures, and 29% partially complete fissures.<sup>3,6,17</sup> This further strengthens the argument that the number of the patients with partially complete fissures in a nonselected cohort is not insignificant and should be evaluated with the Chartis to confirm the absence of collateral ventilation, prior to EBV therapy.

The entire population can thus be divided into three groups - complete fissures (treat), incomplete fissures (do not treat), and partially complete fissure (perform Chartis to confirm the absence of collateral ventilation). Applying the PPV, NPV, and accuracies from **Table 2** to the patient distribution described above results in a diagnostic workflow with an overall accuracy of 89.5% which is higher than Chartis or QCT alone. It results in fewer potential responders being denied treatment, and as many as 71% fewer diagnostic bronchoscopies compared to a Chartis-only screening strategy. This is visualized in **Figure 5**, which is a hypothetical reproduction of the work flow. We used the 123 patients from two studies<sup>3,6,17</sup> and their distribution to simulate three different possible diagnostic approaches for treatment selection: Chartis only, QCT only, or the combination of Chartis and QCT. As shown in **Figure 5**, there are some important differences: the combined approach results in higher accuracy, the Chartis approach requires all patients to undergo bronchoscopies, and using only QCT will result in significantly more potential responders being denied treatment.

The chosen reference standard for establishing the accuracy of fissure completeness is the achievement of  $\geq 350$  ml of volume reduction. This value has been used by several other studies on this subject and is considered a clinically significant and meaningful lung volume reduction compared to controls without an intervention.<sup>4,6,8,12</sup> An alternate reference standard is surgical inspection of the fissure or a completely collapsed lobe, both of which were not

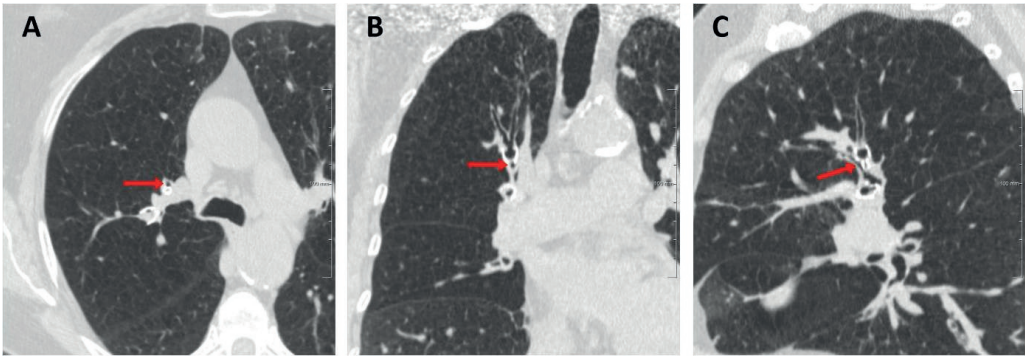
realistic in this retrospective study. Moreover, since the goal of the treatment is lung volume reduction, this reference standard is clinically relevant and quantifiable. Given the various studies involved and the retrospective nature of this study, follow-up scans to calculate TLVR were acquired at various time points from 1 to 6 months. This, however, was not considered a bias, since the occurrence of significant TLVR, irrespective of the time to follow-up, is considered a successful response.

Another potential source of bias is the lack of technical success in placing valves. A misplaced valve or missed segmental airway compromises the entire treatment and is unlikely to cause lobar volume reduction, thus unfairly penalizing the accuracy of the diagnostic prediction. An example of a misplaced valve is shown in **Figure 6**. To account for this, CT scans from four studies were checked for procedural errors by two authors (E.M.v.R. and J.P.C.), with discordant cases being verified by T.D.K. and D.J.S.<sup>3,4,6,17</sup> A total of 23 cases were found to have procedural errors, leaving 194 patients. Of this group, there were 135 responders. Removing the procedural errors leads to better predictive values of the QCT fissure analysis: the PPV with FCS >95% is 94.1%, the NPV with FCS <80% is 92.1%.



**Figure 5** - Hypothetical diagnostic work flow based on the study results, comparing Chartis only to QCT only and to the combination of Chartis and QCT.

4



**Figure 6** - Example of an ideal valve placement and lack of lobar occlusion as visualized on CT. Red arrows indicate a segmental airway, where valve placement was missed in axial (A), coronal (B), and sagittal (C) view.

Finally, since we have applied a different QCT software algorithm and have challenged the status quo of the previously assumed 90% fissure completeness threshold with a larger dataset, our thresholds are not directly comparable to historical references, and further research is required to prospectively validate them. Nevertheless, this is the largest dataset of patients treated with EBV evaluated with QCT software, covering a broad range of CT scan acquisition protocols, geographic locations, and scanners over a long time period and incorporates data from the largest prospective trials of EBV therapy to date. Although a prospective diagnostic study is preferred, we believe that these results are relevant and robust.

## CONCLUSION

QCT analysis can be utilized to classify severe emphysema patients into three ‘fissure status’ groups. This can be used to thereafter only perform a functional assessment of collateral flow with the Chartis system on those patients with partially complete fissures.

**REFERENCES**

- 1 Halbert R, Natoli J, Gano A, Badamgarav E, Buist A, Mannino D: Global burden of COPD: systematic review and meta-analysis. *Eur Respir J* 2006;28:523-532.
- 2 Valipour A, Burghuber O: An update on the efficacy of endobronchial valve therapy in the management of hyperinflation in patients with chronic obstructive pulmonary disease. *Ther Adv Respir Dis* 2015;9:294-301.
- 3 Sciruba FC, Ernst A, Herth FJ, Strange C, Criner GJ, Marquette CH, Kovitz KL, Chiacchierini RP, Goldin J, McLennan G, et al: A randomized study of endobronchial valves for advanced emphysema. *N Engl J Med* 2010;363:1233-1244.
- 4 Klooster K, Ten Hacken N, Hartman J, Kerstjens H, van Rikxoort E, Slebos D: Endobronchial valves for emphysema without interlobar collateral ventilation. *N Engl J Med* 2015;373:2325-2335.
- 5 Koster T, Slebos D: The fissure: interlobar collateral ventilation and implications for endoscopic therapy in emphysema. *Int J Chron Obstruct Pulmon Dis* 2016;11:765-773.
- 6 Herth F, Eberhardt R, Gompelmann D, Ficker J, Wagner M, Ek L, et al: Radiological and clinical outcomes of using Chartis™ to plan endobronchial valve treatment. *Eur Respir J* 2013;41:302-308.
- 7 Gompelmann D, Eberhardt R, Michaud G, Ernst A, Herth F: Predicting atelectasis by assessment of collateral ventilation prior to endobronchial lung volume reduction: a feasibility study. *Respiration* 2010;80:419-425.
- 8 Schuhmann M, Raffy P, Yin Y, Gompelmann D, Oguz I, Eberhardt R, et al: Computed tomography predictors of response to endobronchial valve lung reduction treatment. Comparison with Chartis. *Am J Respir Crit Care Med* 2015;191:767-774.
- 9 Gesierich W, Samita K, Behr J: Determining collateral ventilation during bronchoscopy: unanswered questions. *Thorax* 2014;69:289-290.
- 10 Goldin J, Abtin F: Update on radiology of emphysema and therapeutic implications. *Thorac Surg Clin* 2009;19:149-167.
- 11 Davey C, Zoumot Z, Jordan S, McNulty W, Carr D, Hind M, et al: Bronchoscopic lung volume reduction with endobronchial valves for patients with heterogeneous emphysema and intact interlobar fissures (the BeLieVeR-HiFi study): a randomised controlled trial. *Lancet* 2015;386:1066-1073.
- 12 Gompelmann D, Eberhardt R, Slebos D, Brown M, Abtin F, Kim H, et al: Diagnostic performance comparison of the Chartis system and high-resolution computerized tomography fissure analysis for planning endoscopic lung volume reduction. *Respirology* 2014;19:524-530.
- 13 Koenigkam-Santos M, Puderbach M, Gompelmann D, Eberhardt R, Herth F, Kauczor H, et al: Incomplete fissures in severe emphysematous patients evaluated with MDCT: incidence and interobserver agreement among radiologists and pneumologists. *Eur J Radiol* 2012;81:4161-4166.
- 14 Pu J, Wang Z, Gu S, Fuhrman C, Leader J, Meng X, et al: Pulmonary fissure integrity and collateral ventilation in COPD patients. *PLoS One* 2014;9:e96631.
- 15 van Rikxoort E, Goldin J, Galperin-Aizenberg M, Abtin F, Kim H, Lu P, et al: A method for the automatic quantification of the completeness of pulmonary fissures: evaluation in a database of subjects with severe emphysema. *Eur Radiol* 2012;22:302-309.
- 16 de Oliveira H, de Oliveira S, Rambo R, de Macedo Neto A: Fissure integrity and volume reduction in emphysema: a retrospective study. *Respiration* 2016;91:471-479.
- 17 Herth F, Noppen M, Valipour A, Leroy S, Vergnon J, Ficker J, et al: Efficacy predictors of lung volume reduction with Zephyr valves in a European cohort. *Eur Respir J* 2012;39:1334-1342.

- 18 Herzog D, Thomsen C, Poellinger A, Doellinger F, Schreiter N, Froeling V, et al: Outcomes of endobronchial valve treatment based on the precise criteria of an endobronchial catheter for detection of collateral ventilation under spontaneous breathing. *Respiration* 2016;91:69-78.
- 19 van Rikxoort E, van Ginneken G, Klik M, Prokop M: Supervised enhancement filters: application to fissure detection in chest CT scans. *IEEE Trans Med Imaging* 2008;27:1-10.
- 20 van Rikxoort E, de Hoop B, Viergever M, Prokop M, van Ginneken G: Automatic lung segmentation from thoracic computed tomography scans using a hybrid approach with error detection. *Med Phys* 2009;36:2934-2947.
- 21 van Rikxoort E, Prokop M, de Hoop B, Viergever M, Pluim J, van Ginneken B: Automatic segmentation of pulmonary lobes robust against incomplete fissures. *IEEE Trans Med Imaging* 2010;29:1286-1296.
- 22 Lassen B, van Rikxoort E, Schmidt M, Kerkstra S, van Ginneken B, Kuhnigk J: Automatic segmentation of the pulmonary lobes from chest CT scans based on fissures, vessels, and bronchi. *IEEE Trans Med Imaging* 2013;32:210-222.
- 23 Gesierich W, Samitas K, Reicheberger F, Behr J: Collapse phenomenon during Chartis collateral ventilation assessment. *Eur Respir J* 2016;47:1657-1667.



5



## CHAPTER 5

# An Integrative Approach of the Fissure Completeness Score and Chartis Assessment in Endobronchial Valve Treatment for Emphysema

Karin Klooster\*

**T. David Koster\***

Christoph Ruwwe-Glösenkamp

Dorothea Theilig

Felix Doellinger

Jacopo Saccomanno

Huib A.M. Kerstjens

Dirk-Jan Slebos

Ralf-Harto Huebner

*\*These authors contributed equally to this work*

*Adapted from Int J Chron Obstruct Pulmon Dis. 2020 Jun 9;15:1325-1334*



## **ABSTRACT**

### **Purpose**

Lung volume reduction using one-way endobronchial valves is a bronchoscopic treatment for patients with severe emphysema without collateral ventilation between the treatment target lobe and the ipsilateral lobe(s). CT-scan fissure analysis is often used as a surrogate to predict the absence of collateral ventilation. We aimed to evaluate the predictive value of the fissure completeness score (FCS) compared to the functional Chartis measurement of collateral ventilation and to provide cut-off values of the FCS in patient selection.

### **Patients and Methods**

Multicenter study in patients eligible for treatment with one-way valves. The FCS was calculated by quantitative CT analysis (Thirona, the Netherlands) and compared to status of interlobar collateral ventilation measured with Chartis system (PulmonX, USA). Thresholds were calculated for the predictive values of the presence of collateral ventilation.

### **Results**

An FCS > 95% of the left major fissure had a positive predictive value (PPV) of 91%, with 1 in 11 fissures demonstrating collateral ventilation with Chartis measurement, whereas an FCS of ≤ 80% had a negative predictive value (NPV) of 100% for the presence of collateral ventilation. For the right major fissure, the NPV was 100% for an FCS ≤ 90%, but 69.7% for the right upper lobe fissure.

### **Conclusion**

Quantitative CT analysis is recommended in all patients evaluated for endobronchial valves. Patients with incomplete fissures (left major fissure: FCS < 80%; right major fissure: < 90%) can be excluded from Chartis measurement and endobronchial valve treatment. In patients with more complete fissures, the FCS is not specific enough for endobronchial valve treatment decisions. In this case, additional Chartis measurements are always recommended in the right lung. For the left lung, Chartis assessments may be omitted if the FCS is > 95%.

## INTRODUCTION

Bronchoscopic lung volume reduction with endobronchial valves (EBV) is an additional treatment option for patients with severe emphysema and hyperinflation. The purpose of this treatment is to achieve volume reduction of the most diseased lobe. During this treatment, one-way endobronchial valves are placed in all (sub-)segments of the most diseased lobe to achieve lobar occlusion. This treatment has been proven effective in multiple studies, and provides clinically meaningful benefits in lung function, dyspnea, quality of life and exercise tolerance in a selected group of patients with chronic obstructive pulmonary disease (COPD).<sup>1-8</sup>

However, treatment is only effective in carefully selected patients. The most important factor for an effective treatment is the absence of interlobar collateral ventilation. If collateral ventilation is present between the target lobe and adjacent ipsilateral lobe(s), the placement of one-way valves will not achieve the desired atelectasis, resulting in no clinically meaningful benefit.<sup>9-13</sup>

Collateral ventilation can be functionally measured using the Chartis system® (PulmonX Inc., Redwood City, CA, USA).<sup>12,14,15</sup> With this method, a catheter with a balloon component at the end is inflated in the entrance of the airways of the treatment target lobe. The Chartis console then measures the expiratory airflow from this lobe. If airflow persists after balloon occlusion, this indicates that there is collateral ventilation. However, if the flow decreases over time and gradually stops, this indicates the absence of collateral ventilation and these patients are suitable for treatment with valves.

Although Chartis measurement proved to be a valuable and reliable tool, it is a time-consuming bronchoscopic procedure if used in all patients with severe hyperinflation regardless if they will receive valves, as many have collateral ventilation. If this measurement could be avoided in patients with certain presence (or absence) of collateral ventilation, this would save burden, time and costs.

An indirect and non-invasive method for assessment of collateral ventilation is the fissure completeness score (FCS) calculated on high-resolution computed tomography (HRCT) using quantitative CT analysis (QCT). A high score indicates that an interlobar fissure is (nearly) complete and that the likelihood of having collateral ventilation is small, though not absent.<sup>15</sup> Until recently, a fissure was defined as complete on HRCT scan if the fissure integrity was more than 90 percent.<sup>1-3,14,16-18</sup> This value is relatively arbitrary and studies found rather variable relations between the FCS and treatment outcome. A recent study supports the use of combining the fissure completeness scores and Chartis measurements and advised a Chartis measurement in patients with FCS between 80% and 95%, exclude patients with FCS<80% and treat patients with FCS>95%.<sup>15</sup> There is a need for confirmation regarding these cut-offs, given the importance of accurately selecting the responder patients.<sup>12,13</sup> Although Chartis measurement is clinical practice in many clinics, there are recent studies that advocate the use of the fissure cut-off score of 90% only.<sup>19,20</sup> However, more accurate selection of responder

patients prevents unnecessary procedures, non-beneficial treatments and extra costs in patients with collateral ventilation. Therefore, we performed a study to correlate the FCS to the Chartis assessment. In this study, we investigated in which patients additional Chartis assessments are recommended or can be avoided with detailed quantitative assessment of the FCS on HRCT. Additionally, we evaluated costs involved in adding Chartis assessment.

## **PATIENTS AND METHODS**

### **Study Design**

This is a retrospective multicenter study comparing outcomes of the quantitative assessment of the FCS on HRCT with Chartis measurements in a routine clinical care setting in the University Medical Center Groningen, the Netherlands and in the Charité University Clinic, Berlin, Germany. The study was conducted in accordance with the declaration of Helsinki, and all patients provided written informed consent regarding their treatment and use of their data for future scientific purposes, which was approved by the medical ethics committee of the University Medical Center Groningen (METc2016.483) and of the Charité University Clinic (EA2/149/17). All data was anonymized and treated with confidentiality according to GCP guidelines.

Patients were selected for treatment based on their primary assessment and work-up including a pulmonary function test, high-resolution CT scan (maximum 1 mm slice thickness) and QCT analysis with a target lobe for treatment with (near) complete fissures between the target lobe and the ipsilateral lobe. During the valve procedure, Chartis is performed and if there is no collateral ventilation, valves are placed. All patients who were scheduled for a valve treatment procedure and who have signed an informed consent form were included in this study. The Chartis measurement was performed for the target lobe fissure first, and preferably all other fissures to gather information regarding the presence or absence of collateral ventilation over the other fissures.

### **Assessment of FCS on HRCT**

QCT analysis was performed on all baseline scans using Thirona LungQ version 1.0.0 (Thirona BV, Nijmegen, the Netherlands) to assess fissure completeness and lobar tissue destruction at baseline for each subject. The methods for QCT analysis and calculation of the FCS have been described previously.<sup>15</sup> In each chest CT scan, the lungs, fissures and lobes were automatically segmented and afterwards visually checked and edited by trained medical analysts. Based on these results, FCS was computed for each lobe. This is defined as the percentage of the lobar boundaries defined by a fissure.

## Chartis Measurement

Collateral ventilation was assessed as previously described using the Chartis system.<sup>21</sup> The measurements were performed under either spontaneous breathing with conscious sedation (Berlin) or under general anesthesia (Groningen) using a flexible therapeutic bronchoscope. The Chartis balloon was placed in the entrance of the upper lobe and/or the lower lobe from the right lung and the left lung.

In the right lung, the major fissure can be measured in the lower lobe or in the upper lobe while blocking the middle lobe with a Fogarty balloon or Watanabe spigot. The right upper lobe fissure consists of the minor fissure and a part of the major fissure (**Figure 1**) and is measured with Chartis in the right upper lobe. In the left lung, the major fissure can be measured in the lower lobe or in the upper lobe. Preferably, the target lobe was chosen to be measured first. Chartis results were defined as presence of collateral ventilation ( $CV_{pos}$ ), absence of collateral ventilation ( $CV_{neg}$ ), or “not conclusive”, if the status of collateral ventilation could not be concluded. These assessments include the “low flow” or “no flow phenotype” (also known as “collapse phenotype”) and the “low plateau phenotype” as recently reported.<sup>22,23</sup>

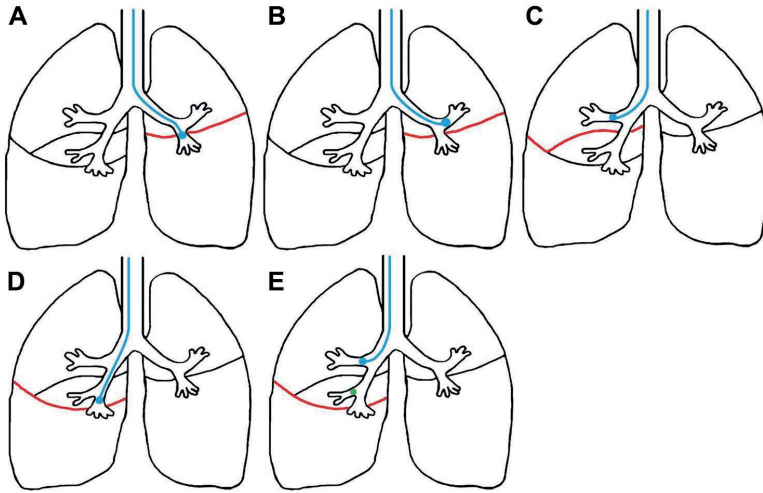
## Statistical analyses

Patients were included in the analysis if they underwent Chartis assessments and had an evaluable baseline HRCT. The FCS was evaluated for its ability to predict the Chartis outcome, for which a receiver operating characteristics (ROC) curve was created. Sensitivity, specificity, positive and negative predictive values were calculated for each FCS. We aimed to calculate two FCS thresholds for both major fissures and the right upper lobe fissure. The first lower threshold of FCS was set to minimize the number of false negatives (incomplete FCS without presence of collateral ventilation). The second higher threshold of FCS was defined to minimize the number of false positives (complete FCS but presence of collateral ventilation). This will result in three groups for each fissure: 1) incomplete fissure (less than lower FCS threshold); 2) complete fissure (more than higher FCS threshold); 3) partially complete fissure (FCS between two thresholds). IBM SPSS Statistics, version 23.0 (Armonk, USA) was used for all analyses.

## RESULTS

### Study Patients

In total, 240 patients with COPD and eligible for EBV treatment were included, and the FCS of the right major fissure, right upper lobe fissure and left major fissure (**Figure 1**) were measured with QCT analysis. In these patients, 429 fissures were categorized as “presence of collateral ventilation between EBV target lobe and ipsilateral lobe” ( $CV_{pos}$ ) or “absence of collateral ventilation between EBV target lobe and ipsilateral lobe” ( $CV_{neg}$ ) with Chartis assessments. The baseline characteristics of the included subjects are presented in **Table 1**.



**Figure 1** - Measurement of collateral flow with Chartist.

A and B. Collateral flow over the left major fissure (red) is measured by a balloon occluding the entrance of the left lower lobe (A) or the left upper lobe (B). C. Collateral flow over the right upper lobe fissure is measured in the right upper lobe. This fissure consists of the minor fissure and a part of the right major fissure (red). D. Collateral flow over the right major fissure (red) is measured by a balloon occluding the entrance of the right lower lobe. If this is unsuccessful, E. collateral flow can be measured in the right upper lobe while the middle lobe is also occluded with a Fogarty balloon or a Watanabe spigot (green).

**Table 1** - Baseline Characteristics

Patients (N)		240
Female (N)		142 (59%)
Age (years)		66 ± 8
BMI (kg/m <sup>2</sup> )		24 ± 4
Pack years		45 ± 24
Lung function	FEV <sub>1</sub> (%pred)	27 ± 7
	RV (%pred)	232 ± 51
	TLC (%pred)	131 ± 18
	DLCO (%pred)	30 ± 12

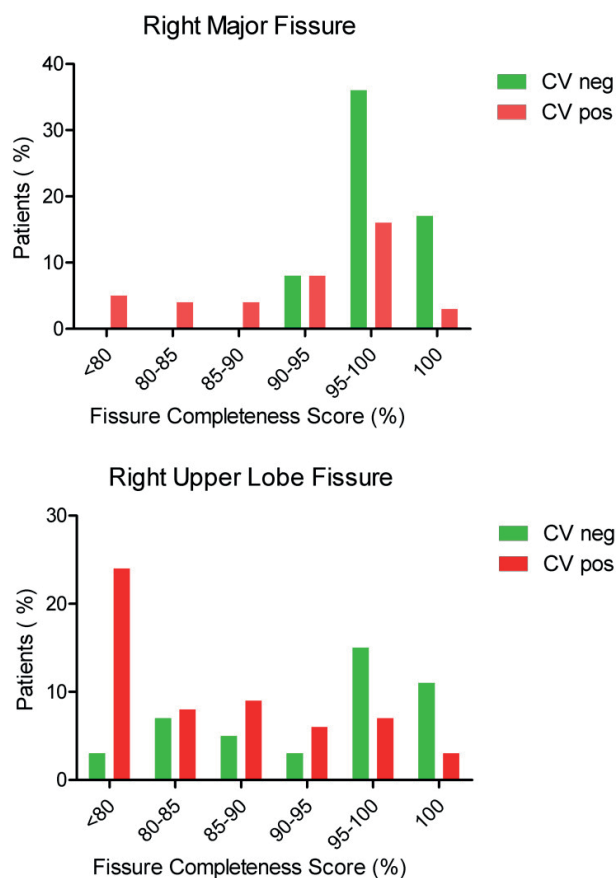
**Abbreviations:** BMI: body mass index; FEV<sub>1</sub>: Forced Expiratory Volume; RV: Residual Volume; TLC: Total Lung Capacity; DLCO: Diffusing Capacity of the Lung for Carbon Monoxide

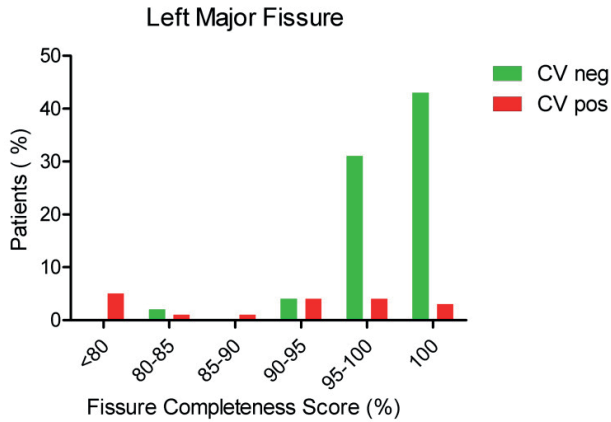
### Assessment of the Fissure Completeness Score on HRCT and Chartis Assessment

The median FCS of the right major fissure was 97.1% (range 60.2–100%), right upper lobe fissure 85.3% (range 23.4–100%) left major fissure 99.9% (range 49.7–100%). Chartis measurement was performed under conscious sedation in 113 patients and under general anesthesia in 127 patients. Chartis assessment of the right major fissure was performed in 106 patients (44%). Of these, 41 patients (39%) had presence of collateral ventilation and 65 patients (61%) had absence of collateral ventilation. The right upper lobe fissure was conclusively measured in 115 patients: 65 patients (57%) were CV<sub>pos</sub> and 50 patients (43%) were CV<sub>neg</sub>. Chartis assessment over the left major fissure was successfully performed in 208 patients of whom 40 were CV<sub>pos</sub> (19%) and 168 were CV<sub>neg</sub> (81%).

### Fissure Completeness Score versus Chartis Outcome

The median FCS was significantly higher in patients without collateral ventilation ( $p < 0.001$ ) in all groups, see **Table 2**. **Figure 2** shows the percentage of patients with or without collateral ventilation per fissure divided into subgroups of FCS. The predictive values per fissure and FCS are shown in **Table 3**.

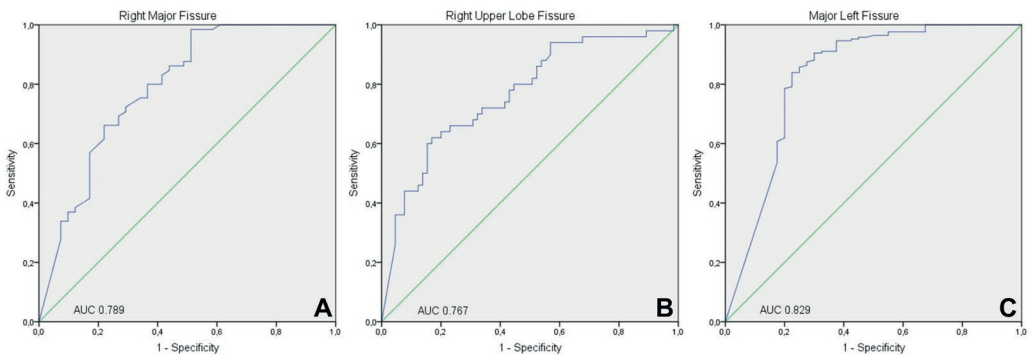




**Figure 2** - Distribution of collateral ventilation.

Percentage of patients with CV<sub>neg</sub> or CV<sub>pos</sub> compared to the fissure completeness score of the right major fissure, the right upper lobe fissure and the left major fissure. Number of patients: Right Major Fissure: 106; Right Upper Lobe Fissure: 115; Left Major Fissure: 208.

**Abbreviations:** CV<sub>pos</sub>, presence of collateral ventilation; CV<sub>neg</sub>, absence of collateral ventilation.



**Figure 3** - Receiver Operating Characteristic Curves

(A) Right major fissure: The area under the curve (AUC) is 0.789. (B) Right upper lobe fissure: The AUC is 0.767. (C) Left major fissure: The AUC is 0.829.

Right major fissure: The area under the curve (AUC) of the ROC-curve is 0.789 (Figure 3A). Lower cut off: FCS of  $\le 90\%$  has a negative predictive value of 100%. Upper Cut off: patients with FCS  $>95\%$  have a positive predictive value of 73.7%, compared to 85.7% in patients with a fissure integrity of 100%.

Right Upper Lobe Fissure: The AUC of the ROC-curve is 0.767 (Figure 3B). Lower Cut off: of the 24 patients with FCS  $\le 75\%$ , 3 were CV negative. The FCS of these patients were 75.0%, 55.6%

and 25.1%. Upper Cut off: the positive predictive value of FCS >95% is 73.2%, and 81.3% with an FCS of 100%. Even with an FCS of 100%, 18.8% of the patients showed evidence of collateral ventilation, compared to 26.8% with an FCS of >95%.

Left Major Fissure: The AUC of the ROC-curve is 0.829 (**Figure 3C**). Lower Cut off: an FCS of  $\leq 80\%$  has a negative predictive value of 100%. Upper Cut off: patients with FCS >95% have a positive predictive value of 91.1%, compared to 92.8% with a fissure integrity of 100%.

**Table 2** - Fissure Completeness Score Compared to Chartis Measurement.

FCS	CV positive		CV negative	
	Median	Range	Median	Range
Right Major Fissure	94.8	60.2-100	98.9	91.1-100
Right Upper Lobe Fissure	83.4	23.4-76.6	97.2	25.1-100
Left Major Fissure	91.4	49.7-100	100	82.9-100

**Abbreviations:** FCS: fissure completeness score; CV positive: presence of collateral ventilation; CV negative: absence of collateral ventilation.



**Table 3** - Predictive Values per Fissure Completeness Score.

<b>Right Major Fissure (N=106)</b>							
FCS	CV <sub>neg</sub>	CV <sub>pos</sub>	Sens	Spec	PPV	NPV	Number of Chartis needed*
>80	64.4%	35.6%	12.2	96.0	64.4	100.0	2.8
>83	65.0%	35.0%	14.6	100.0	65.0	100.0	2.9
>85	67.0%	33.0%	22.0	100.0	67.0	100.0	3.0
>90	69.9%	30.1%	31.7	100.0	69.9	100.0	3.3
>93	74.7%	25.3%	48.8	95.4	74.7	87.0	4.0
>95	73.7%	26.3%	51.2	86.2	73.7	70.0	3.8
>96	76.5%	23.5%	61.0	80.0	76.5	65.8	4.3
>97	77.8%	22.2%	65.9	75.4	77.8	62.8	4.5
>98	81.6%	18.4%	78.0	61.5	81.6	56.1	5.4
>99	80.0%	20.0%	82.9	43.1	80.0	47.9	5.0
100	85.7%	14.3%	92.7	27.7	85.7	44.7	7.0

<b>Right Upper Lobe Fissure (N=115)</b>							
FCS	CV <sub>neg</sub>	CV <sub>pos</sub>	Sens	Spec	PPV	NPV	Number of Chartis needed*
>75	40.9%	59.1%	32.3	94.0	51.6	87.5	1.7
>80	56.0%	44.0%	43.1	96.1	56.0	90.3	2.3
>83	54.7%	45.3%	47.7	82.0	54.7	77.5	2.2
>85	58.2%	41.8%	56.9	78.0	58.2	77.1	2.4
>90	66.0%	34.0%	73.8	66.0	66.0	73.8	2.9
>93	69.6%	30.4%	78.5	64.0	69.6	73.9	3.3
>95	73.2%	26.8%	83.1	60.0	73.2	73.0	3.7
>96	73.0%	27.0%	84.6	54.0	73.0	70.5	3.7
>97	71.4%	28.6%	84.6	50.0	71.4	68.8	3.5
>98	73.3%	26.7%	87.7	44.0	73.3	67.1	3.8
>99	80.8%	19.2%	92.3	42.0	80.8	67.4	5.2
100	81.3%	18.8%	95.4	26.0	81.3	62.6	5.3

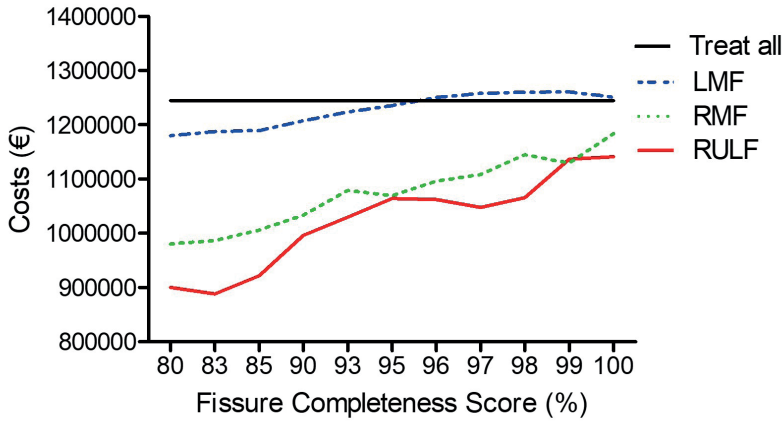
Left Major Fissure (N=208)							
FCS	CV <sub>neg</sub>	CV <sub>pos</sub>	Sens	Spec	PPV	NPV	Number of Chartis needed*
>80	85.3%	14.7%	27.5	98.8	85.3	100.0	6.8
>83	86.1%	13.9%	32.5	99.4	86.1	92.9	7.2
>85	86.3%	13.7%	35.0	97.6	86.3	77.8	7.3
>90	88.2%	11.8%	45.0	97.6	88.2	81.8	8.5
>93	89.9%	10.1%	55.0	95.2	89.9	73.3	9.9
>95	91.1%	8.9%	62.5	91.7	91.1	64.1	11.3
>96	92.7%	7.3%	70.0	90.5	92.7	63.6	13.7
>97	93.5%	6.5%	75.0	85.7	93.5	55.6	15.4
>98	93.7%	6.3%	77.5	79.8	93.7	47.7	15.9
>99	93.8%	6.2%	80.0	72.0	93.8	40.5	16.1
100	92.8%	7.2%	82.5	53.6	92.8	29.7	13.9

Statistics per fissure and fissure completeness score regarding the sensitivity, specificity, positive and negative predictive value. Number of Chartis needed\*: Number of Chartis measurements needed to identify one additional patient with collateral ventilation while applying this FCS.

**Abbreviations:** FCS: fissure completeness score; CV<sub>pos</sub>: presence of collateral ventilation; CV<sub>neg</sub>: absence of collateral ventilation; sens: sensitivity; spec: specificity; PPV: Positive Predictive Value; NPV: Negative Predictive Value

### Costs

To analyze the cost effectiveness of treating patients based on FCS alone or in combination with additional Chartis measurements, a costs-analysis was performed based on published data by Hartman et al, assuming 100 hypothetical patients.<sup>24</sup> Based on the predictive values of the FCS, combining FCS and Chartis assessments before endobronchial valve treatment is always cost-effective in both fissures in the right lung (**Figure 4**). However, in regard to the left major fissure, it is cost-effective to treat without an additional Chartis measurement using an FCS >95%.



**Figure 4** - Cost analysis

Hypothetical graph of the costs of 100 patients for treatment with endobronchial valves. Costs: Endobronchial valve treatment in all patients without Chartis assessment: € 12.447 per patient. Chartis measurement followed by treatment with valves: € 13.197 per patient; Chartis assessment not followed by treatment: € 3670.61 per patient.<sup>24</sup> The "treat all" group indicates the costs of treating all 100 patients with a high FCS (indicated on x-axis) and without Chartis assessment. In the other groups (RULF, LMF and RMF), Chartis measurement is performed in all patients, but patients are only treated with endobronchial valves if they are  $CV_{neg}$ .

**Abbreviations:** RULF, Right Upper Lobe Fissure; LMF, Left Major Fissure; RMF, Right Major Fissure.

## DISCUSSION

Patients with severe emphysema can be successfully treated with endobronchial valves.<sup>1,2,6-8,18</sup> Careful patient selection is crucial, and the absence of collateral ventilation is one of the most important predictive factors for a successful treatment. Valves placed in patients who turn out to have collateral ventilation are a burden to patients, treating teams and healthcare costs. We show in which patients additional assessments of collateral ventilation can lead to improved outcomes and cost savings.

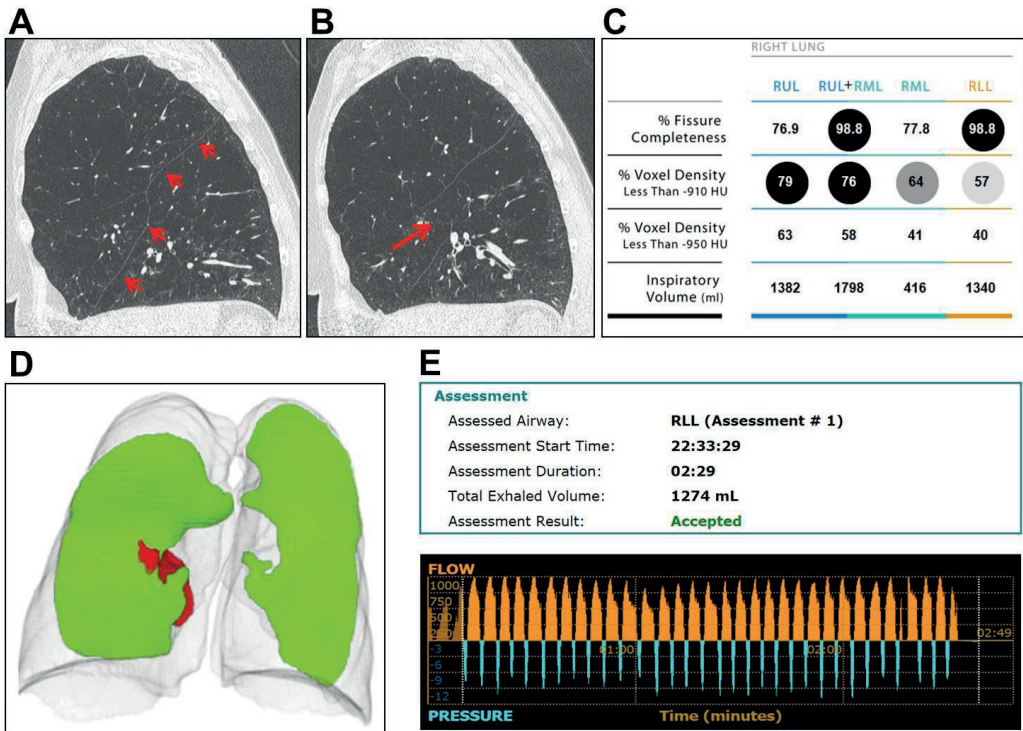
The importance of collateral ventilation and the role of the FCS was acknowledged soon after the first treatments with endobronchial valves.<sup>18</sup> QCT analysis provides an easy and non-invasive tool to assess the FCS as a surrogate for collateral ventilation. The FCS is predictive for the presence or absence of collateral ventilation, which is frequently used to preselect patients for treatment. However, although a correlation of FCS with the likelihood of collateral ventilation is evident, the degree of the correlation remains subject to discussion. Various studies used a cut-off value of 90% to define a fissure as complete.<sup>3,14,16,18,20</sup> However, as our study shows, even with a fissure integrity of over 90%, a significant number of patients still have collateral ventilation and will not benefit from endobronchial valve treatment.

Two recently published randomized controlled trials treated patients based on FCS >90% alone, the EMPROVE and the REACH trial.<sup>19,20</sup> They showed an FEV<sub>1</sub> improvement of >15% in 37.2% and 41% of the patients, an RV reduction of 402 and 420 mL and a target lobe volume reduction of >350 mL reduction in 74.5 and 66.1%, respectively. However, the mean FCS in the REACH trial was 97.8% and the mean FCS of the EMPROVE trial is not known. The effect in a subgroup of patients with fissures between 90% and 95% or how much of these patients are treated are not given. The LIBERATE and the TRANSFORM trial treated patients based on the presence of collateral ventilation measured by Chartis and showed an improvement of FEV<sub>1</sub> >15% in 47.7% and >12% in 56.3%, the TLV-reduction >350 mL was 89.9% at 12 months and 89.9 at 6 weeks, respectively.<sup>5,8</sup> Furthermore, there is a difference in the occurrence of pneumothorax between these methods. The trials that treated patients only after the exclusion of collateral ventilation based on Chartis measurement reported a pneumothorax incidence between 26% and 29%,<sup>5,6,8</sup> which is significantly higher than the rate of 4–14% reported in studies using only the 90% FCS cutoff.<sup>19,20,25</sup> A higher pneumothorax incidence might indicate a larger treatment effect. Therefore, the effect appears to be more pronounced in studies using the Chartis measurement as the ultimate patient selection tool.

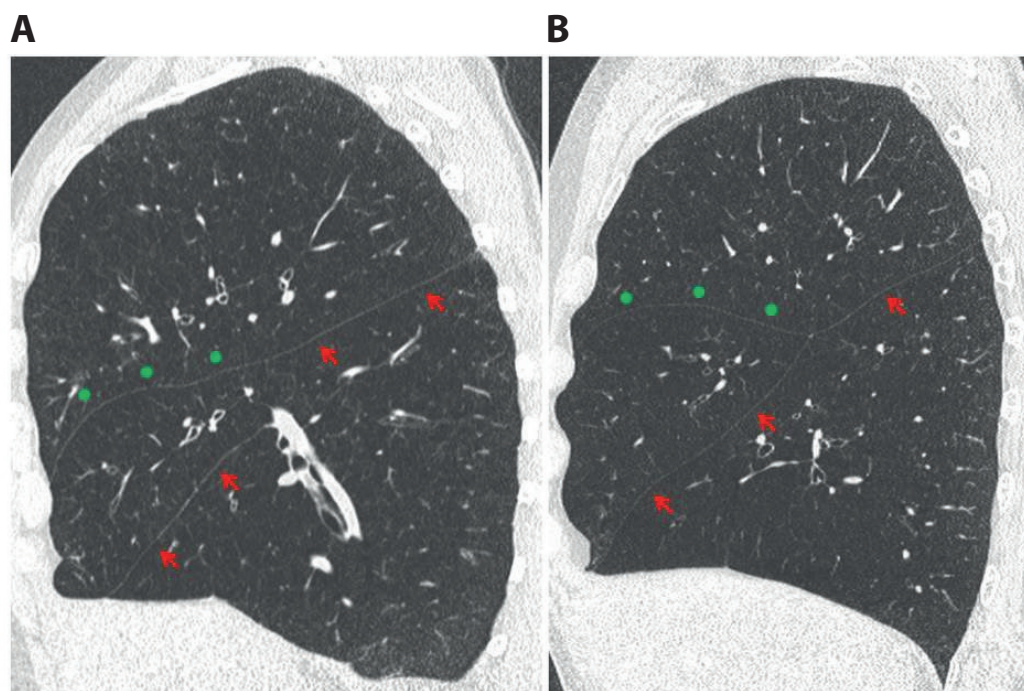
An earlier study suggested that the combination of Chartis and fissure analysis provides a useful workflow in patients eligible for endobronchial lung volume reduction by division in three groups.<sup>15</sup> Patients with incomplete fissures (FCS <80%) can be excluded from further valve treatment evaluation. Partially complete fissures (FCS between 80% and 95%) should be assessed with Chartis prior to treatment and high FCS (>95%) can be treated without additional Chartis measurement. However, the outlined algorithm does not take into account any possible differences between the fissures. Our current study indicates that the left major fissure, being the only boundary between the two lobes, is more predictive than the FCS of the right pulmonary fissures for the presence of collateral ventilation. Only a very high FCS of

at least 95%, and this only for the left major fissure, should actually be used to abstain from Chartis measurement. An individual example of a patient with a near-complete right major fissure and still collateral ventilation is provided in **Figure 5**.

Our data indicates that for the left major fissure, patients with FCS <80% should be excluded from endobronchial valve treatment in the left lung without the need for further Chartis assessment. Regarding the right major fissure, all patients with an FCS below 90% had evidence of collateral ventilation and do not benefit from additional Chartis measurement. This is particularly interesting in the context that the FCS cut off of 90% suggested in previous clinical studies is too low to define a fissure as complete.<sup>2,14,18-20</sup>



The right upper lobe fissure is anatomically different from both major fissures, consisting of the minor and a part of the right major fissure. Our data shows that a few numbers of patients had no collateral ventilation with Chartis assessment even with an FCS of the right upper lobe below 75%. It is not known why this difference exists between the right lung and the left lung. Possibly, the mechanism of collateral ventilation is slightly different. One possible explanation is the way the major and minor fissures are shaped. There is a lot of variation in the way the fissures are formed, as is indicated by two examples in **Figure 6**. Even with a near-complete fissure on quantitative CT scan, the way the fissures are merged may lead to a small gap and collateral ventilation.



**Figure 6** - Formation of the right fissures

A. The minor fissure (green dots) merges with a part of the right major fissure (red arrows). There is a gap between the superior and inferior part of the right major fissure, but the minor fissure is continuous with the superior part of the major fissure. B. The major fissure is complete, the minor fissure merges with the major fissure.

The reason why there is no collateral ventilation, even with incomplete fissure may be due to the extent of disease of the pulmonary tissue. In emphysematous lungs, the resistance of the airways is much higher compared to healthy lungs. On the other hand, the resistance of the collateral channels is much lower in emphysematous lungs. Therefore, in emphysematous lungs, there is much more collateral flow over the collateral channels compared to healthy lungs.<sup>26</sup> The mechanism of collateral ventilation between lobes through parenchymal bridges

is unknown, but it is assumed that the mechanism might be the same as intralobar collateral ventilation.<sup>9,27,28</sup> Therefore, it can be hypothesized that in relatively healthy lung tissue there is no presence of collateral ventilation due to the high resistance of the collateral channels, but only in emphysematous lobes, with a low resistance of the collateral challenge. Thus, if collateral ventilation is measured in a relatively healthy right upper lobe, there may be no collateral ventilation due to the high resistance, even if the fissure is incomplete. This may also be the case in an emphysematous right upper lobe, but healthier middle and lower lobe. More research is needed to clarify this issue.

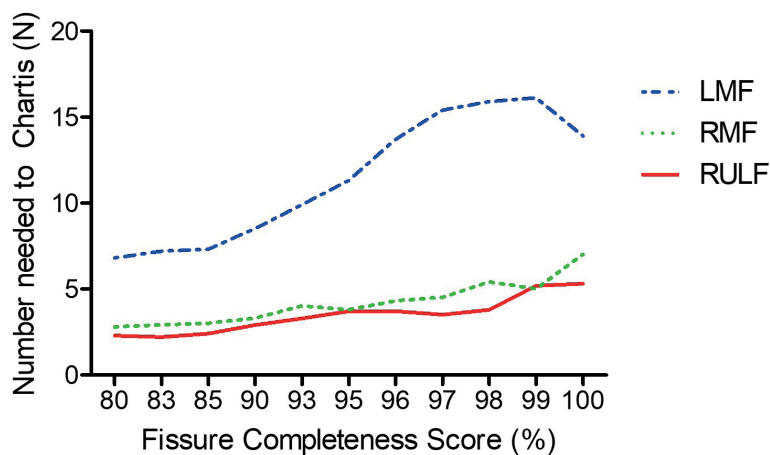
Nevertheless, for the right upper lobe, this means that a lower threshold for the FCS should be employed to guide treatment decisions regarding the right upper lobe, and additional Chartis assessments are strongly encouraged if the right upper lobe is a good target but the fissures are incomplete. For the upper limit threshold for the FCS, the necessity of an additional Chartis measurement can be based on two major considerations.

### **Cost Aspect**

If patients with an FCS above a certain threshold would all be treated with endobronchial valves without performing an additional Chartis assessment, costs for the Chartis catheter would be saved. On the other hand, without Chartis measurement, a high number of patients would receive valves without effect, which is costly. Moreover, these valves may have to be removed, resulting in further bronchoscopies and hospital admissions. For more clarification, we performed a costs-analysis to compare the selection for treatment based on the fissure score alone to the combination of the FCS with Chartis measurement. For the right lung, all FCS should be combined with a Chartis measurement. For the left lung, patients can be treated based on an FCS >95%, without Chartis assessment. Basis for the calculations is costs and reimbursements in the Netherlands and will yield different thresholds in other countries.

### **Number of Chartis Needed**

This represents the number of patients presumed to have complete fissures according to FCS, but have evidence of collateral ventilation in Chartis measurement. With the data from Table 3, it is shown in how many patients a Chartis needs to be performed to prevent one patient from inadvertently receiving valves while there is collateral ventilation. This consequence should be discussed with patients. We believe Chartis should always be performed in the right lung and for the left lung an FCS > 95% could be acceptable (**Figure 7**).



**Figure 7** - Number of Chartis measurements needed to identify one patient with collateral ventilation, by level of fissure completeness score.

This score ranges from the indicated value on the x-axis to 100%.

Abbreviations: RULF, Right Upper Lobe Fissure; LMF, Left Major Fissure; RMF, Right Major Fissure.

A low FCS indicates a high likelihood of presence of collateral ventilation. Potential target lobes with incomplete fissures are rarely chosen for endobronchial valve treatment. Therefore, outcome data in this setting are lacking. It has already been shown that treatment of patients with presence of collateral ventilation is not effective.<sup>18,21</sup> We defined Chartis measurement as the most reliable predictor of success in endobronchial valve treatment since it functionally measures the collateral ventilation. Future studies may evaluate whether patients with a high FCS and low collateral flow may still benefit from treatment after treatment with endobronchial valves.

## CONCLUSION

In conclusion, if a patient appears to be eligible for endobronchial valve treatment based on their CT scan, lung function and other characteristics, quantitative CT analysis for the FCS is a useful but imperfect tool to further select patients for endobronchial valve treatment. We strongly encourage the use of both the FCS and Chartis measurement as patient selection tools, and not the FCS alone, as is suggested in some recent literature. Patients with incomplete fissures (FCS <80% for left major fissure and FCS <90% for right major fissure) can be excluded from endobronchial valve treatment and no Chartis measurement is needed. In patients with (more) complete fissures, Chartis is always recommended in the right lung. For the left lung, Chartis assessments can optionally be omitted if the FCS is >95%.



**REFERENCES**

- 1 Valipour A, Slebos D, Herth F, et al. Endobronchial valve therapy in patients with homogeneous emphysema. results from the IMPACT study. *Am J Respir Crit Care Med*. 2016;194(9):1073–1082.
- 2 Davey C, Zoumot Z, Jordan S, et al. Bronchoscopic lung volume reduction with endobronchial valves for patients with heterogeneous emphysema and intact interlobar fissures (the BeLieVeR-HiFi study): a randomised controlled trial. *Lancet*. 2015;386(9998):1066–1073.
- 3 Herth F, Noppen M, Valipour A, et al. Efficacy predictors of lung volume reduction with zephyr valves in a european cohort. *Eur Respir J*. 2012;39(6):1334–1342.
- 4 Klooster K, Slebos DJ, Zoumot Z, Davey C, Shah PL, Hopkinson NS. Endobronchial valves for emphysema: an individual patient-level reanalysis of randomised controlled trials. *BMJ Open Respir Res*. 2017;4(1):e000214.
- 5 Criner GJ, Sue R, Wright S, et al. A multicenter RCT of zephyr(R) endobronchial valve treatment in heterogeneous emphysema (LIBERATE). *Am J Respir Crit Care Med*. 2018;198(9):1151–1164.
- 6 Klooster K, Ten Hacken N, Hartman J, Kerstjens H, van Rikxoort E, Slebos D. Endobronchial valves for emphysema without interlobar collateral ventilation. *N Engl J Med*. 2015;373(24):2325–2335.
- 7 Klooster K, Hartman JE, Ten Hacken NH, Slebos DJ. One-year follow-up after endobronchial valve treatment in patients with emphysema without collateral ventilation treated in the STELVIO trial. *Respiration*. 2017;93(2):112–121.
- 8 Kemp S, Slebos D, Kirk A, et al. A multicenter RCT of zephyr® endobronchial valve treatment in heterogeneous emphysema (TRANSFORM). *Am J Respir Crit Care Med*. 2017;196(12):1535–1543.
- 9 Koster T, Slebos D. The fissure: interlobar collateral ventilation and implications for endoscopic therapy in emphysema. *Int J Chron Obstruct Pulmon Dis*. 2016;11:765–773.
- 10 Hartman JE, Vanfleteren LEGW, van Rikxoort EM, Slebos DJ, on behalf of the SOLVE consortium. Bronchoscopic lung volume reduction treatment using endobronchial valves for emphysema: emerging questions. *Respiration*. 2018;96(6):588–589.
- 11 Van Der Molen MC, Klooster K, Hartman JE, Slebos DJ. Lung volume reduction with endobronchial valves in patients with emphysema. *Expert Rev Med Devices*. 2018;15(11):847–857.
- 12 Herth F, Slebos D, Criner G, Shah P. Endoscopic lung volume reduction: an expert panel recommendation -update 2017. *Respiration*. 2017;94(4):380–388.
- 13 Slebos D, Shah P, Herth F, Valipour A. Endobronchial valves for endoscopic lung volume reduction: best practice recommendations from expert panel on endoscopic lung volume reduction. *Respiration*. 2017;93(2):138–150.
- 14 Schuhmann M, Raffy P, Yin Y, et al. Computed tomography predictors of response to endobronchial valve lung reduction treatment. Comparison with chartis. *Am J Respir Crit Care Med*. 2015;191(7):767–774.
- 15 Koster T, van Rikxoort E, Huebner R, et al. Predicting lung volume reduction after endobronchial valve therapy is maximized using a combination of diagnostic tools. *Respiration*. 2016;92(3):150–157.
- 16 Gompelmann D, Eberhardt R, Slebos D, et al. Diagnostic performance comparison of the Chartis system and high-resolution computerized tomography fissure analysis for planning endoscopic lung volume reduction. *Respirology*. 2014;19(4):524–530.
- 17 Reymond E, Jankowski A, Pison C, et al. Prediction of lobar collateral ventilation in 25 patients with severe emphysema by fissure analysis with CT. *AJR Am J Roentgenol*. 2013;201(4):571–575.
- 18 Sciruba FC, Ernst A, Herth FJ, et al. A randomized study of endobronchial valves for advanced emphysema. *N Engl J Med*. 2010;363(13):1233–1244.

- 19 Criner GJ, Delage A, Voelker K, et al. Improving lung function in severe heterogenous emphysema with the spiration(R) valve system (EMPROVE): a multicenter, open-label, randomized, controlled trial. *Am J Respir Crit Care Med.* 2019;200(11):1354–1362.
- 20 Li S, Wang G, Wang C, et al. The REACH trial: a randomized controlled trial assessing the safety and effectiveness of the spiration(R) valve system in the treatment of severe emphysema. *Respiration.* 2018;1–12.
- 21 Herth F, Eberhardt R, Gompelmann D, et al. Radiological and clinical outcomes of using chartis™ to plan endobronchial valve treatment. *Eur Respir J.* 2013;41(2):302–308.
- 22 Herzog D, Thomsen C, Poellinger A, et al. Outcomes of endobronchial valve treatment based on the precise criteria of an endobronchial catheter for detection of collateral ventilation under spontaneous breathing. *Respiration.* 2016;91(1):69–78.
- 23 Gesierich W, Samitas K, Reicheberger F, Behr J. Collapse phenomenon during chartis collateral ventilation assessment. *Eur Respir J.* 2016;47(6):1657–1667.
- 24 Hartman JE, Klooster K, Groen H, Ten Hacken NHT, Slebos DJ. Cost-effectiveness of endobronchial valve treatment in patients with severe emphysema compared to standard medical care. *Respirology.* 2018;23(9):835–841.
- 25 Valipour A, Herth FJ, Burghuber OC, et al. Target lobe volume reduction and COPD outcome measures after endobronchial valve therapy. *Eur Respir J.* 2014;43(2):387–396.
- 26 Hogg J, Macklem P, Thurlbeck W. The resistance of collateral channels in excised human lungs. *J Clin Invest.* 1969;48(3):421–431.
- 27 Gompelmann D, Eberhardt R, Herth F. Collateral ventilation. *Respiration.* 2013;85(6):515–520.
- 28 Menkes H, Traystman R. Collateral ventilation. *Am Rev Respir Dis.* 1977;116(2):287–309.

6



## CHAPTER 6

# **An adjusted and time-saving method to measure collateral ventilation with Chartis**



**T. David Koster**  
Karin Klooster  
Hallie McNamara  
Narinder S. Shargill  
Sri Radhakrishnan  
Ryan Olivera  
Dirk-Jan Slebos

*Adapted from ERJ Open Res. 2021 Jul; 7(3): 00191-2021.*

## **ABSTRACT**

### **Introduction**

Bronchoscopic lung volume reduction with endobronchial valves is an important treatment option in selected patients with severe emphysema and absence of collateral ventilation in the treatment target lobe. The Chartis system provides an important physiological assessment of the presence or absence of collateral ventilation. We aimed to evaluate a new feature and determine whether low flow during a Chartis measurement is predictive for the absence of collateral ventilation, and whether this allows for a procedure to be shortened by earlier terminating the Chartis measurement. This is measured with the “volume trend for the previous 20 s” (VT20).

### **Methods**

We retrospectively evaluated 249 Chartis assessments of patients scheduled for bronchoscopic lung volume reduction procedures. The VT20 was calculated, and several thresholds were compared between patients with collateral ventilation (CV positive) and without collateral ventilation (CV negative).

### **Results**

100% of the CV negative patients reached a threshold of  $VT20 \leq 6$  mL, whereas all CV positive patients reached a  $VT20 \geq 7$  mL. The median “time saved” between  $VT20=6$  mL and end of assessment was 60 s (range 5–354 s).

### **Conclusion**

The threshold of  $VT20 \leq 6$  mL is a reliable method to exclude the presence of collateral ventilation when air flow rates are low and can therefore reduce bronchoscopic lung volume procedure times.

## INTRODUCTION

Bronchoscopic lung volume reduction (BLVR) with endobronchial valves is an effective treatment for patients with severe emphysema and hyperinflation.<sup>1-4</sup> One of the key factors for response is the absence of collateral ventilation between the treatment target lobe and the ipsilateral lobe(s).<sup>2,3,5-7</sup> The presence or absence of collateral ventilation can be predicted based on the fissure completeness between lobes.<sup>7,8</sup> However, a more accurate assessment can be performed using the Chartis Pulmonary Assessment System (Pulmonx Inc., Redwood City, CA, USA), which provides a physiological assessment of airflow through the target lobe.<sup>5,9</sup> The Chartis system consists of a catheter with a balloon at the distal tip, designed to be inserted into the airways through the working channel of a bronchoscope. The open lumen at the distal tip of the Chartis catheter can be placed into the target airway, and inflation of the balloon causes the airway to become sealed and isolated. The catheter is connected to the Chartis console that measures the air flow and pressure from the occluded lobe and quantifies the collateral ventilation status.<sup>5,10,11</sup> The Chartis assessment can be performed in patients breathing spontaneously with procedural sedation, or under general anesthesia. Compared to sedation, Chartis measurement performed under general anesthesia is more feasible with shorter procedure times.<sup>12,13</sup> Absence of collateral ventilation in patients under general anesthesia is confirmed if the air flow from the occluded lobe reaches zero, with an immediate return of airway flow after deflating and removing the balloon catheter.<sup>6,13</sup> In many cases, there may be an evident reduction of flow, suggesting absence of collateral ventilation; however, because of the very low flow rate, it can take a significant amount of time for the flow rate to reach “zero”.<sup>10</sup> During some Chartis assessments, the momentary appearance of sudden spikes in the flow rate can confound the assessment. Integration of the flow rate over a fixed period of time during this situation can attenuate this artefact. Therefore, the Chartis software (version 6.0.5) has been updated to continually measure and display the total expired volume over the last 20 seconds: the “volume trend for the previous 20 seconds” (VT20). With this feature, the expired volume in the last 20 seconds is measured, and this is shown continuously on the Chartis console, next to the currently used flow curve (**Figure 1**). The VT20 value is shown after the first 20 seconds of the Chartis assessment. The present study aimed to validate whether there is a threshold of the VT20 which is predictive for the absence of collateral ventilation in situations where the flow rate during a Chartis measurement is low, and potentially shortening the Chartis procedure by earlier termination of the Chartis measurement. For this, we measured and continuously monitored VT20 based on the hypothesis that if a low flow is predictive of the absence of collateral ventilation, it would lead to shorter procedure time. This results in an easier procedure, with less manipulation of the airway wall by the Chartis balloon and catheter.

## METHODS

### Study design and population

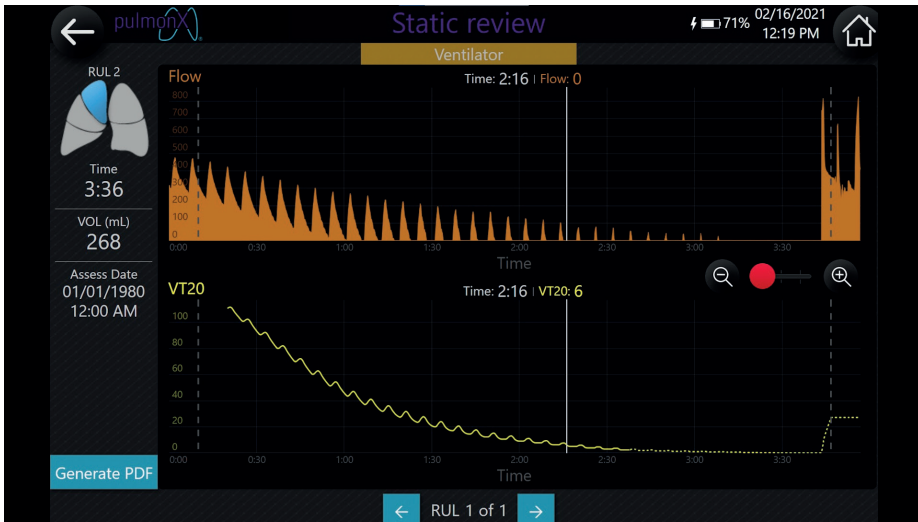
This is a single-centre retrospective study conducted at the University Medical Center Groningen, the Netherlands. Anonymized Chartis assessments previously performed in a routine clinical care setting were analyzed. Patients with severe emphysema and hyperinflation who were eligible for valve treatment and were scheduled for Chartis assessment as part of regular care in the Bronchoscopic Emphysema Treatment in the Netherlands registry (BREATHE-NL) were included. All patients provided informed consent regarding their treatment and use of their data for future scientific purposes (BREATHE-NL Registry; ClinicalTrials.gov Identifier: NCT02815683).

### Chartis measurements

All Chartis assessments included in the analysis were performed under general anesthesia with patients intubated with a flexible 9-mm endotracheal tube. Positive pressure ventilation was applied in all patients as per routine practice, with low ventilation frequency (8–10 times per minute), with an inspiratory/expiratory ratio of 1:3 to 1:4 and preferably a positive end-expiratory pressure of 3 cmH<sub>2</sub>O.<sup>10,13</sup> Collateral ventilation over the fissure of the target lobe was measured and scored as presence of collateral ventilation (CV positive), absence of collateral ventilation (CV negative) or inconclusive. In some patients, multiple measurements were performed in several lobes, e.g. when there was more than one treatment target.

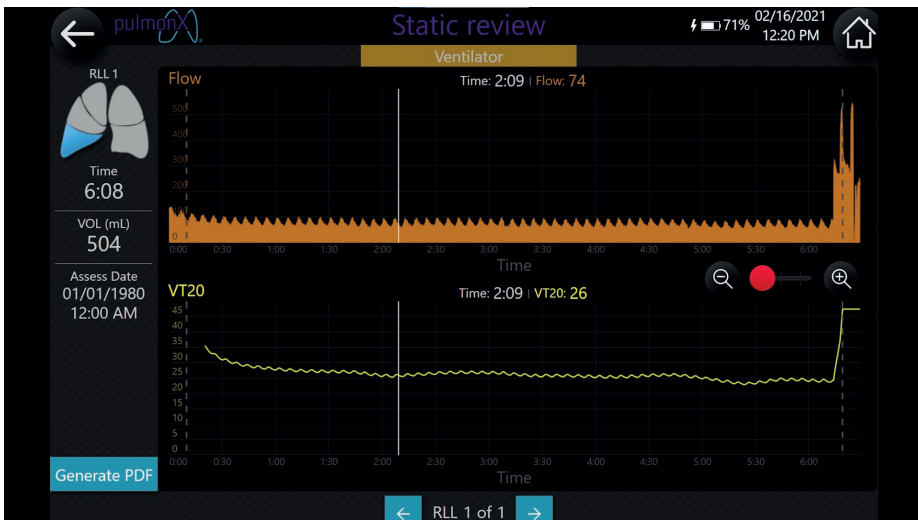
### Chartis VT20 measurements

The original raw output data of the Chartis assessments performed during bronchoscopy was used to evaluate the effectiveness of the new VT20 feature on the Chartis 6.0.5 software. An example of a CV negative and a CV positive Chartis assessment is shown in **Figures 1** and **2**, respectively. The selection of Chartis assessments for inclusion in the analysis was based on the algorithm shown in **Table 1**, to indicate whether an assessment was valid or inconclusive. The valid Chartis assessments were evaluated to determine whether the VT20 data were valid or invalid. For VT20 data to be valid, there should be presence of air flow at the end of the assessment (in CV positive patients) or the presence of air flow when the VT20 reached a value of 6 mL and below so that the VT20 could reasonably be used to indicate the end of an assessment. The time of the end of the assessment was recorded. The lowest VT20 value was recorded in all assessments and for CV negative assessments, the time point at which the VT20 was 6 mL, 5 mL, 4 mL, 3 mL, 2 mL, 1 mL or 0 mL.



**Figure 1** - Chartis measurement screen image showing the actual flow and the “volume trend for the previous 20 s” (VT20) plotted for a collateral ventilation (CV) negative patient phenotype in the right upper lobe. This assessment reached VT20=6 mL at the 2 min 16 s mark, whereas the total measurement was 3 min 36 s.

6



**Figure 2** - Chartis measurement screen image showing the actual flow and the “volume trend for the previous 20 s” (VT20) plotted for a collateral ventilation (CV) positive patient phenotype. This assessment never reaches a VT20 value below VT20=23 mL.



**Table 1** - Selection criteria for valid Chartis measurements to calculate the optimal VT20 threshold

1.	Presence of positive flow prior to start of assessment.
2.	The flow should be consistent. * This flow may be decreasing over the course of the assessment, but there should be no extended duration of missing flow. This indicates proper catheter balloon positioning and sealing of the airways and that the catheter has not been clogged. * There should be no sudden increases in flow to a much higher level. This could indicate that the catheter balloon seal was lost. * During the assessment, if there is an instantaneous loss or drop in flow within the first 30 seconds and flow does not resume, the assessment should be abandoned and a new one should be re-initiated
3.	At the end of the assessment, the total volume of air exhaled by the patient during the assessment should have been greater than 50 ml.

### Statistical analysis

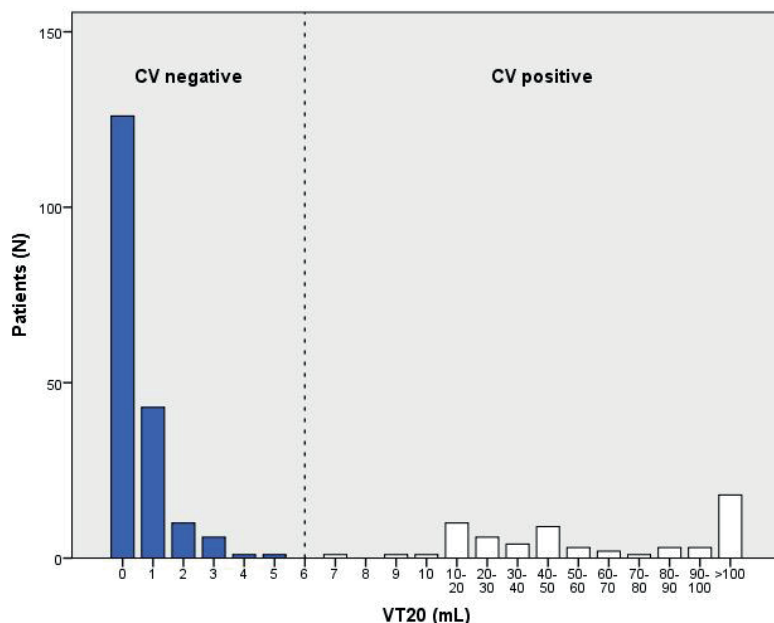
To compare outcomes between the CV negative and CV positive groups, we used an independent-samples t-test in case of normal distribution and a Mann–Whitney U test in case of non-normal distribution, p-values below 0.05 were considered statistically significant and mean or median data were calculated per group. All statistical analyses were performed using SPSS version 22 (IBM, New York, NY, USA).

## RESULTS

A total of 279 Chartis assessments were evaluated. Thirty assessments were excluded because the VT20 values were invalid to use, as described in the Methods section. Ultimately, 249 Chartis assessments were analyzed (187 CV negative and 62 CV positive).

### VT20

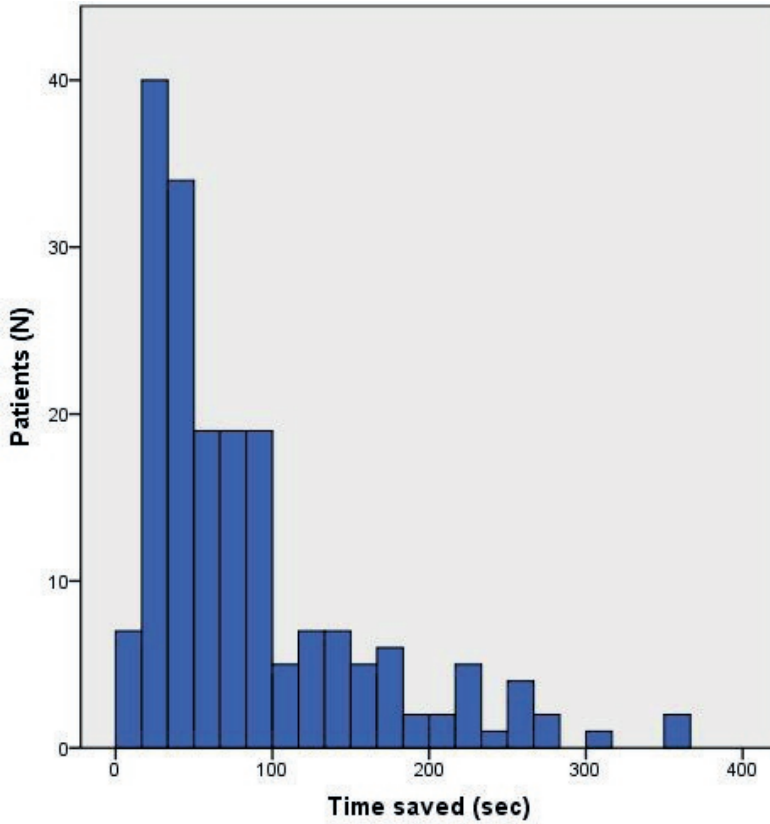
Of the 187 CV negative patients, 100% reached a minimum value of  $VT_{20} \leq 6$  mL during the last 2 minutes of assessment. Additionally, 98.9% reached a value of  $VT_{20} \leq 3$  mL and 90.4% a  $VT_{20} \leq 1$  mL. Of the 62 CV positive patients, 100% did not reach a  $VT_{20} \leq 6$  mL, and the lowest VT20 was 7 mL. The distribution is shown in **Figure 3**.



**Figure 3** - Distribution of minimum "volume trend for the previous 20 s" (VT20) values in collateral ventilation (CV) negative and CV positive measurements.

### Time assessment

The median time of the Chartis measurements was 240 s (range 77–864) in all patients. In CV positive patients the median time was 304 s (range 122–533) and in CV negative patients, 226 s (range 77–864) ( $p=0.021$ ) (see **Table 2**). The median time to VT20=6 mL was 168 s (range 36–546). The median time difference between the end of measurement and the VT20=6 mL time point ("time saved") was 60 s (range 5 to 354), as shown in **Figure 4**.



**Figure 4** - Distribution of “time saved” between “volume trend for the previous 20 s” (VT20)=6 mL and total measurement in collateral ventilation (CV) negative patients.

### Volume

The median measured expiratory volume was 320 mL (range 15–1780) in all patients (Table 2). In CV negative patients this was 240 mL (range 15–983), compared to 1014 mL (range 115–1780) in CV positive patients ( $p < 0.005$ ). The median difference between the total expired volume and the expired volume in CV negative patients at VT20=6 mL was 5 mL (range 0–120).

**Table 2** - Results of Chartis assessment: duration of measurement and expiratory volume during measurement.

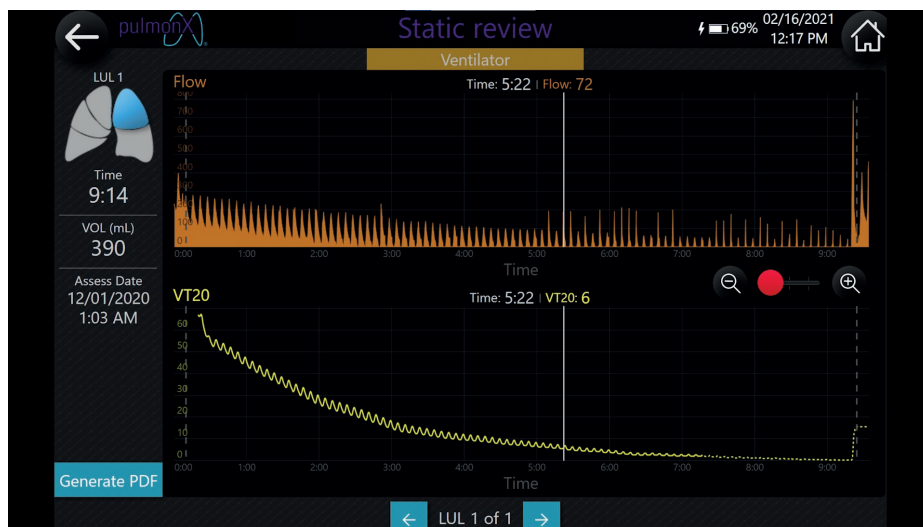
	Total (N=249)	CV negative (N=187)	CV positive (N=62)	P-value
<b>Duration of Chartis assessment</b>				
Total time (sec)	240 (77-864)	226 (77-864)	304 (122-533)	0.021
Time to VT20 = 6 mL (sec)	-	168 (36-546)	-	-
Difference (sec)	-	60 (5-354)	-	-
<b>Expiratory volume during Chartis assessment</b>				
Expiratory volume (mL)	320 (15-1780)	240 (15-983)	1014 (115-1780)	P<0.005
Expiratory volume at VT20 = 6 (mL)	-	235 (11-991)	-	-
Difference (mL)	-	5 (0-120)	-	-

## DISCUSSION

Multiple clinical trials have demonstrated the benefits of BLVR with one-way endobronchial valves in patients with severe emphysema who have little to no collateral ventilation in the target lobe.<sup>1-4</sup> The assessment of collateral ventilation status (presence or absence of collateral ventilation) is crucial in determining the eligibility of a patient for valve treatment for BLVR. The Chartis system provides a physiological assessment of airway under simulated conditions of valve placement in the target lobe to confirm the presence or absence of collateral ventilation.<sup>5,7,9,13</sup> It is important to get a valid Chartis assessment, but sometimes the measurement can be challenging.<sup>10,14,15</sup> For example, if there is no flow due to obstruction of the Chartis catheter with mucus plugs or contact of the distal tip with the mucosa, or a no-flow pattern of the lower lobes, this can be interpreted falsely as absence of collateral ventilation.<sup>14-16</sup> Furthermore, Chartis assessments can show a low flow pattern, and it can take a long time before the flow actually reaches “zero”.<sup>14</sup> In order to reduce the Chartis assessment time in cases where very low air flow persists for a longer period of time, the VT20 measure that integrates the flow for the last 20 s has been incorporated into the Chartis software. We evaluated the effectiveness of the new VT20 feature through a review of 187 CV negative and 62 CV positive Chartis assessments. This analysis shows that when the VT20 value was  $\leq 6$  mL, all patients are CV negative. Therefore, if this threshold is achieved, an assessment can be terminated before the air flow actually reaches zero while still being confident that there is no collateral ventilation. This may shorten the Chartis assessment time by minutes and will significantly shorten the total procedure time. As a result, there is less manipulation of the airways, and this may facilitate an easier valve-treatment procedure. Although this

is a retrospective study, the previously obtained Chartis measurements were re-analysed prospectively using the raw output data and run again with the new software feature and hence reflect the actual measurements. The VT20 feature may not be applicable in all Chartis assessments, especially if the procedure is challenging. It is important that there is a continuous flow during the Chartis measurement to use the VT20 cut-off value. Therefore, the assessment should be evaluated critically during the procedure, and if the measurement does not fulfil the criteria described in the methods section, the VT20 value should not be used. A limitation of this study is that the VT20 assessments analyzed included only Chartis measurements performed under general anesthesia with standard ventilator settings. As such, these results cannot be extrapolated to measurements in patients under conscious sedation and spontaneous breathing. Although this may yield comparable results, there is no positive pressure ventilation and the methods of measurement differ. Therefore, the cut-off value of  $VT_{20} \leq 6$  mL should only be used in Chartis measurements in patients under general anesthesia. Herzog et al.<sup>17</sup> have previously shown the additional value of adding a diagnostic algorithm including the expiratory flow, resistance and expired volume in patients measured under spontaneous breathing to shorten the measurement time.

There may be variations in ventilator settings between patients and between hospitals. This could impact the utility of the cut-off of 6 mL in the last 20 s. Nevertheless, if standard settings are used as described, a measurement of the total volume integrated for the last 20 s is valuable in avoiding confusion resulting from the spikes in flow patterns that some patients may exhibit. The probable cause for this pattern is the release of very low amounts of volume from the targeted lobe, maybe due to airway collapse. Nevertheless, this leads to small spikes in flow, and this pattern usually results in a longer measurement time, as it takes more time for the flow to reach “zero”, even though the total flow is very low (**Figure 5**).



**Figure 5** - Chartis measurement output image showing the “volume trend for the previous 20 s” (VT20) value plotted for an assessment with continued high spikes in air flow (flow of  $72 \text{ mL}\cdot\text{min}^{-1}$  at 5:22 min) values for the duration of the assessment.

These spikes cause confounding peak flow trend values, while the VT20 is a good indicator of the continued decline in the amount of total exhaled volume. The VT20 is 6 mL at 5:22 min, whereas the total measurement was 9:14 min (difference: 232 s).

## CONCLUSION

We found that the VT20 threshold of 6 mL or less during Chartis assessments provides a valuable and reliable method to identify the absence of collateral ventilation while reducing procedure time. This may lead to less manipulation of the airways and less anesthesia time and facilitates the endobronchial valve treatment procedure.

**REFERENCES**

- 1 Kemp SV, Slebos DJ, Kirk A, et al.. A multicenter randomized controlled trial of zephyr endobronchial valve treatment in heterogeneous emphysema (TRANSFORM). *Am J Respir Crit Care Med* 2017; 196: 1535–1543.
- 2 Klooster K, ten Hacken NH, Hartman JE, et al.. Endobronchial valves for emphysema without interlobar collateral ventilation. *N Engl J Med* 2015; 373: 2325–2335.
- 3 Criner GJ, Sue R, Wright S, et al.. A multicenter randomized controlled trial of zephyr endobronchial valve treatment in heterogeneous emphysema (LIBERATE). *Am J Respir Crit Care Med* 2018; 198: 1151–1164.
- 4 Valipour A, Slebos DJ, Herth F, et al.. Endobronchial valve therapy in patients with homogeneous emphysema. Results from the IMPACT Study. *Am J Respir Crit Care Med* 2016; 194: 1073–1082.
- 5 Herth FJ, Eberhardt R, Gompelmann D, et al.. Radiological and clinical outcomes of using Chartis to plan endobronchial valve treatment. *Eur Respir J* 2013; 41: 302–308.
- 6 Slebos DJ, Shah PL, Herth FJ, et al.. Endobronchial valves for endoscopic lung volume reduction: best practice recommendations from expert panel on endoscopic lung volume reduction. *Respiration* 2017; 93: 138–150.
- 7 Klooster K, Koster TD, Ruwwe-Glosenkamp C, et al.. An integrative approach of the fissure completeness score and Chartis assessment in endobronchial valve treatment for emphysema. *Int J Chron Obstruct Pulmon Dis* 2020; 15: 1325–1334.
- 8 Koster TD, van Rikxoort EM, Huebner RH, et al.. Predicting lung volume reduction after endobronchial valve therapy is maximized using a combination of diagnostic tools. *Respiration* 2016; 92: 150–157.
- 9 Klooster K, Slebos DJ. Endobronchial valves for the treatment of advanced emphysema. *Chest* 2021; 159: 1833–1842.
- 10 Herth FJF, Slebos DJ, Criner GJ, et al.. Endoscopic lung volume reduction: an expert panel recommendation – update 2017. *Respiration* 2017; 94: 380–388.
- 11 Herth FJF, Slebos DJ, Criner GJ, et al.. Endoscopic lung volume reduction: an expert panel recommendation – update 2019. *Respiration* 2019; 97: 548–557.
- 12 Welling JBA, Hartman JE, Ten Hacken NHT, et al.. Chartis measurement of collateral ventilation: conscious sedation versus general anesthesia – a retrospective comparison. *Respiration* 2018; 96: 480–487.
- 13 Welling JBA, Klooster K, Hartman JE, et al.. Collateral ventilation measurement using Chartis: procedural sedation vs general anesthesia. *Chest* 2019; 156: 984–990.
- 14 Gesierich W, Samitas K, Reichenberger F, et al.. Collapse phenomenon during Chartis collateral ventilation assessment. *Eur Respir J* 2016; 47: 1657–1667.
- 15 Welling JBA, Koster TD, Hartman JE, et al.. Temporary right middle lobe occlusion with a blocking device to enable collateral ventilation measurement of the right major fissure. *Respiration* 2020; 99: 516–520.
- 16 Koster TD, Klooster K, Ten Hacken NHT, et al.. Endobronchial valve therapy for severe emphysema: an overview of valve-related complications and its management. *Expert Rev Respir Med* 2020; 14: 1235–1247.
- 17 Herzog D, Thomsen C, Poellinger A, et al.. Outcomes of endobronchial valve treatment based on the precise criteria of an endobronchial catheter for detection of collateral ventilation under spontaneous breathing. *Respiration* 2016; 91: 69–78.





7



## CHAPTER 7

# Temporary Right Middle Lobe Occlusion with a Blocking Device to Enable Collateral Ventilation Measurement of the Right Major Fissure

Jorrit B.A. Welling

**T. David Koster**

Jorine E. Hartman

Marlies van Dijk M

Huib A.M. Kerstjens

Karin Klooster

Dirk-Jan Slebos

*Adapted from Respiration 2020;99:516–520*

## **ABSTRACT**

### **Background**

Absence of interlobar collateral ventilation is essential to achieve lobar volume reduction after endobronchial valve (EBV) treatment and can be assessed using the Chartis measurement. However, especially in lower lobe measurements, Chartis can be complicated by the “no-flow phenomenon”, during which a sudden cessation of flow is observed, leading to an unreliable measurement. If this phenomenon occurs in the right lower lobe, when measuring collateral flow over the right major fissure, the entrance to the right middle lobe should be occluded, and the Chartis balloon should be placed in the right upper lobe. Both Watanabe spigots and balloon catheters can be used to achieve occlusion.

### **Objective**

Our aim was to demonstrate that right middle lobe occlusion with a blocking device is helpful in obtaining a reliable Chartis outcome in case of the no-flow phenomenon in the right lower lobe. Methods: We performed a retrospective analysis of patients scheduled for EBV treatment in an EBV registry between September 2016 and September 2019.

### **Results**

We included 15 patients with severe emphysema (median age 63 years [range 47–73], 73% female, and FEV<sub>1</sub> 24% [range 19–36] of predicted), who required temporary middle lobe occlusion (12 Watanabe spigot, 3 balloon catheter). After occlusion, a reliable Chartis outcome was obtained in all patients.

### **Conclusion**


Temporary middle lobe occlusion using a blocking device is helpful in obtaining a reliable Chartis outcome in case of a right lower lobe no-flow phenomenon.

## INTRODUCTION

The absence of interlobar collateral ventilation is essential to achieve lobar volume reduction with endobronchial valve (EBV) treatment in patients with severe emphysema and can be assessed using the Chartis® (Pulmonx, USA) measurement.<sup>1-4</sup> Chartis measurement can be complicated by the “no-flow phenomenon”, in which dynamic expiratory airway collapse is believed to cause a sudden cessation of flow during measurement, leading to an unreliable Chartis measurement.<sup>5</sup> Literature shows that this can occur in up to one-third of all measurements and most frequently affects the lower lobes.<sup>5-7</sup> Normally, Chartis measurement is performed in the lobe selected for treatment with EBV. When the no-flow phenomenon occurs during measurement in the left lung, measurement in the adjacent lobe can easily be performed to assess the integrity of the left major fissure.<sup>8</sup> However, in case of no flow in the right lower lobe, measurement of the right upper lobe may not be reliable because collateral flow originating from the right middle lobe, due to common incompleteness of the right minor fissure, can result in false-positive Chartis outcomes.<sup>1</sup> If the middle lobe is not occluded, the measurement in the right upper lobe only measures the collateral flow over the right upper lobe fissure (part of the major fissure and minor fissure) and not the right major fissure.

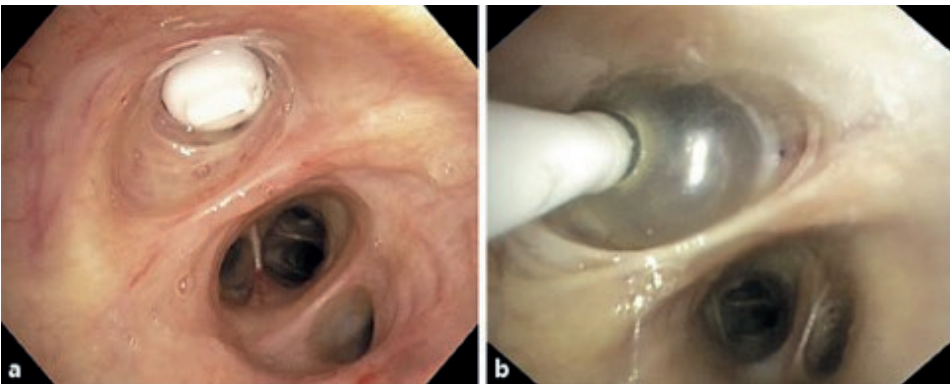
## METHODS

We performed a retrospective analysis in which we included all patients with the right lower lobe as primary EBV target and in which the no-flow phenomenon occurred during Chartis measurement in the right lower lobe. All patients were scheduled for treatment in the Dutch national EBV treatment registry (BREATH-NL) between September 2016 and September 2019 (Clinicaltrials.gov identifier: NCT02815683). Chartis measurements were performed in all patients regardless of fissure integrity scores. The presence of collateral ventilation was confirmed when a continuous, non-decreasing, expiratory airway flow was observed during >6 min or earlier with a similar pattern when totaling >1 L.<sup>8</sup> Every patient underwent Chartis measurement under general anesthesia using a previously described approach.<sup>9</sup> Target lobe volume and fissure integrity were assessed using the StratX quantitative CT Platform (Pulmonx). To achieve the desired temporary occlusion of the right middle lobe, both Watanabe spigots® (Novatech, France) and Extractor® Pro retrieval balloon catheters (Boston Scientific, USA), were used. The Watanabe spigot (**Figure 1**) is a silicon bronchial filler, which is frequently used for persistent pneumothorax, hemoptysis, and bronchopleural fistula, and is available in three sizes: 5, 6 and 7 mm in diameter.<sup>10</sup> The retrieval balloon (**Figure 2**) can be inflated to any desired diameter between 5 and 20 mm and can be replaced by any locally available alternative balloon. Our primary outcome was the success rate of right upper lobe Chartis measurement of the right major fissure after occlusion of the right middle lobe and placement of the Chartis balloon in the right upper lobe. Our secondary outcome was the amount of target lobe volume reduction after EBV treatment.



**Figure 1**

A. Watanabe spigot. B. Watanabe spigot held by a biopsy forceps, which can be used for both placement and removal of the spigot.



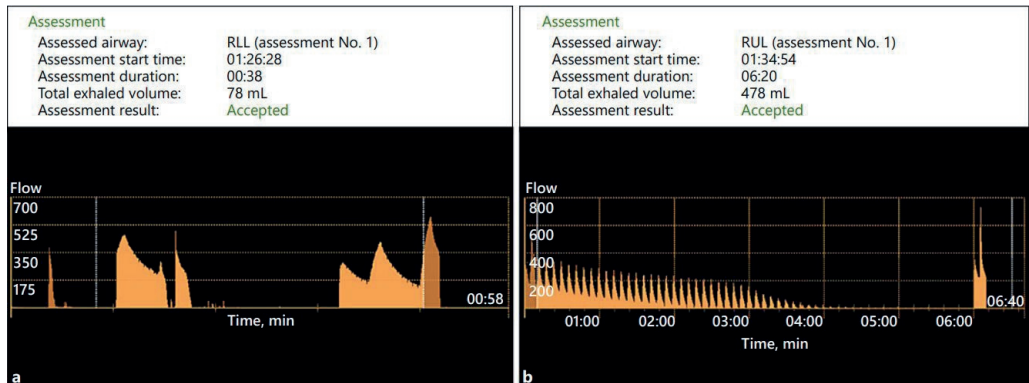
**Figure 2**

A. Watanabe spigot occluding the entrance of the right middle lobe. B. Balloon catheter occluding the entrance of the right middle lobe.

### Case Report

A 63-year-old female with severe emphysema (forced expiratory volume in 1 s [FEV<sub>1</sub>] 25% of predicted and residual volume [RV] 214% of predicted) was scheduled for EBV treatment in our hospital. The predetermined target for treatment was the right lower lobe (51% of voxels less than -950 Hounsfield Units). We were initially unable to obtain a reliable Chartis measurement in the right lower lobe, as we encountered the no-flow phenomenon (**Figure 3a**). After the occlusion of the right middle lobe with a Watanabe spigot, we performed a Chartis measurement in the right upper lobe, which indicated absence of interlobar collateral

ventilation of the right major fissure (**Figure 3b**). Subsequently, five endobronchial valves were placed in the right lower lobe. Six weeks after treatment, the patient achieved a target lobe volume reduction of 1,201 mL, had an FEV<sub>1</sub> of 40% of predicted (69% relative increase), and an RV of 148% of predicted (31% relative reduction).



**Figure 3**

A. Chartis measurement output indicating the no-flow phenomenon in the right lower lobe. The initially present flow becomes zero after the balloon seal is achieved, flow returns when the catheter is withdrawn with subsequent loss of the balloon seal, ruling out other potential causes of no flow. B. Chartis measurement output of the right upper lobe in the same patient, indicating absence of interlobar collateral ventilation after occlusion of the right middle lobe with a Watanabe spigot.

### Case Series

Out of the 220 EBV cases, 36 patients (16%) had the right lower lobe as primary target for EBV. In 15 out of these 36 cases (42%), we performed a temporary right middle lobe occlusion with either a Watanabe spigot or balloon catheter in order to perform Chartis measurement of the right major fissure.

Therefore, 15 patients were included in the analysis (73% female, median FEV<sub>1</sub> 24% of predicted) (baseline characteristics are presented in Table 1). Temporary right middle lobe occlusion was successful in all patients. The Watanabe spigot was used in 12 cases. In 3 cases, the balloon catheter was used because the use of the Watanabe spigot was not possible due to a relatively large diameter entrance to the right middle lobe. In all patients a reliable Chartis measurement could be performed after we placed the blocking device, and we did not observe a no-flow phenomenon. In 13 out of 15 patients (87%), the Chartis measurement in the right upper lobe indicated absence of collateral ventilation of the right major fissure. Six weeks after treatment, the median reduction in the target lobe volume was 863 mL, and 9 out of 13 patients (69%) had achieved the minimal important difference for target lobe volume reduction of 563 mL.<sup>11</sup> See **Table 2** for Chartis measurement outcomes.

**Table 1** - Patient characteristics.

Patients (n)	15
Female/male (%)	73/27
Age (years)	63 (47–73)
BMI	22 (19–30)
Pack years	43 (10–85)
FEV1 (% predicted)	24 (19–36)
RV (% predicted)	229 (187–317)
RV/TLC ratio	0.65 (0.58–0.76)
6MWD (m)	320 (15–484)

Data are presented as median (range), unless otherwise indicated.

**Abbreviations:** BMI, body mass index; FEV1, forced expiratory volume in 1 s; RV, residual volume; TLC, total lung capacity; 6MWD, 6-min walking distance.

**Table 2** - Chartis measurement outcomes.

Total EBV cases (n)	220
Cases with RLL as primary EBV target (n)	36
Cases where temporary RML occlusion was indicated (n) (%)	15 (42)
Blocking device used	
Watanabe Spigot (n)	12
Balloon catheter (n)	3
Chartis measurement outcome right major fissure (CV negative/CV positive) (n)	13/2
Target lobe volume at baseline (mL)	1.625 (1.027 to 3.001)
Target lobe volume reduction at 6 weeks after treatment (mL)	–863 (–3.001 to 5)
Right major fissure integrity (%)	99 (95 to 100)
Right minor fissure integrity (%)	91 (58 to 98)

Data are presented as median (range), unless otherwise indicated. RLL, right lower lobe; RML, right middle lobe; EBV, endobronchial valve; CV, collateral ventilation.

## DISCUSSION

This case series provides insight in the use of two different approaches to temporary right middle lobe occlusion, Watanabe spigots and balloon catheters, to achieve reliable Chartis measurement outcomes. Using this technique, we were able to confirm the presence or absence of interlobar collateral ventilation of the right major fissure in all our patients after initial measurement of the right lower lobe had failed. We considered both the insertion and removal of the Watanabe spigot and balloon catheter very feasible (see [www.karger.com/doi/10.1159/000507401](http://www.karger.com/doi/10.1159/000507401) for online suppl. video). While not structurally assessed in this case series, use of the blocking devices did not prolong Chartis measurement for more than several minutes. Although both blocking device approaches were feasible, in our practice, we generally reserve the use of a balloon catheter for patients with a relatively wide right middle lobe entrance, given its larger potential diameter (5–20 mm) than the Watanabe spigot (5–7 mm).

While temporary right middle lobe occlusion was already recommended by the 2017 expert panel recommendations on EBV treatment, to the best of our knowledge, no data has previously been published on this technique.<sup>8</sup> Before the absence of flow during Chartis measurement is attributed to the no-flow phenomenon, we recommend excluding other causes of absent flow: mucus impaction of the Chartis catheter should first be ruled out by flushing of the catheter, and in addition, correct catheter positioning should be verified. The catheter tip should not be in direct contact with the airway wall. While different terminology is used in the literature to describe the no-flow phenomenon, for example “low flow” and “collapse phenomenon”, we suggest describing this problem as the no-flow phenomenon, as this description describes the clinical observation during measurement.<sup>5,7</sup>

Previous studies have attributed the no-flow phenomenon to dynamic expiratory airway collapse, in which airway collapse distal to the inflated Chartis balloon prevents expiratory airflow.<sup>5,7</sup> While we consider this to be a valid explanation, the question remains why the lower lobes are more often affected by this phenomenon. A possible explanation may be the transpulmonary pressure gradient from the apical zones to the basal zones in combination with the emphysematous lung tissue. More research is required to confirm the exact physiological mechanism causing this phenomenon and its lower-lobe predominance.

## CONCLUSION

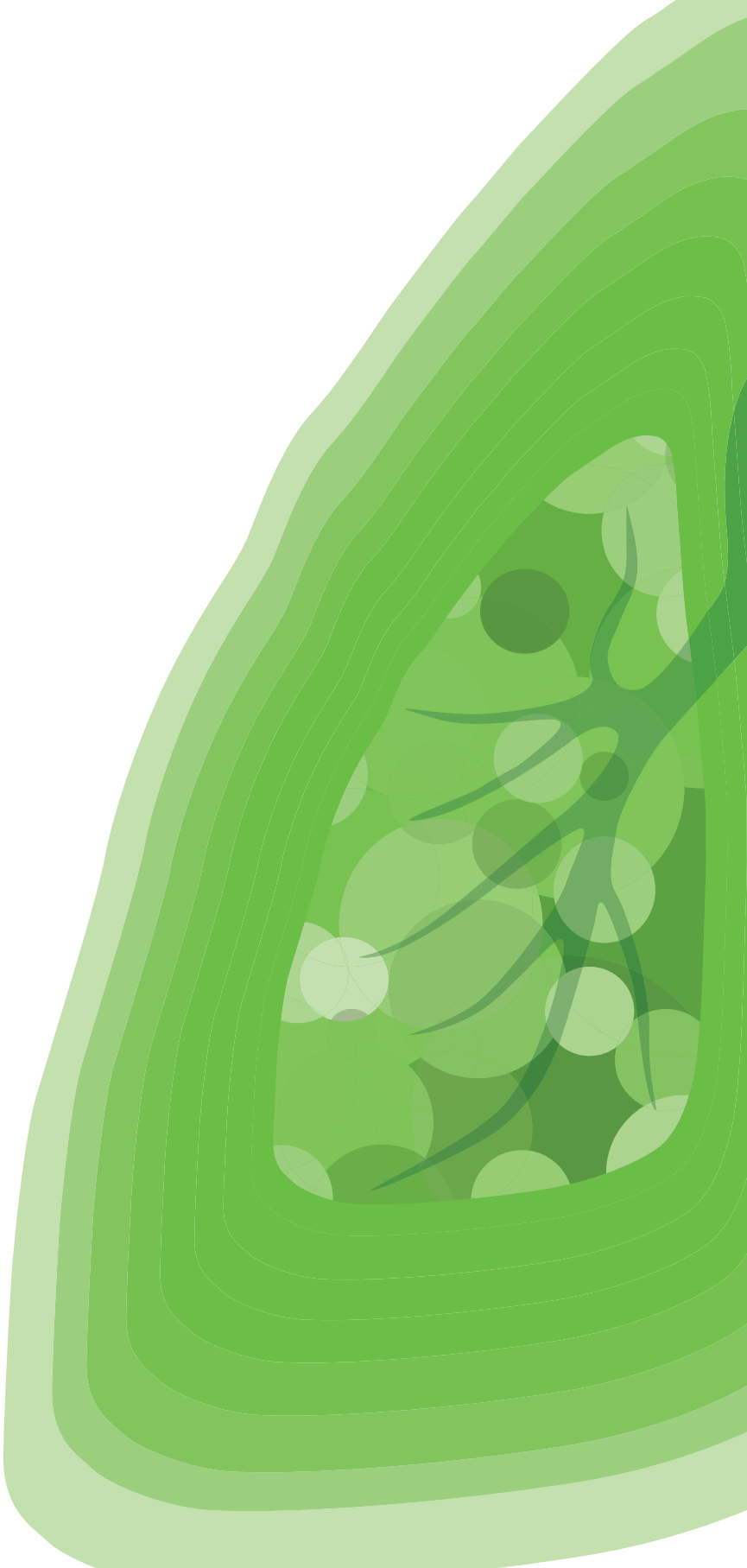Selective temporary occlusion of the right middle lobe using a blocking device is helpful in obtaining a reliable Chartis outcome in case of the no-flow phenomenon in the right lower lobe. The application of this simple technique may improve patient selection and outcomes for EBV treatment.



**REFERENCES**

- 1 Koster TD, Slebos DJ. The fissure: interlobar collateral ventilation and implications for endoscopic therapy in emphysema. *Int J Chron Obstruct Pulmon Dis*. 2016 Apr;11:765–73.
- 2 Klooster K, ten Hacken NH, Hartman JE, Kerstjens HA, van Rikxoort EM, Slebos DJ. Endobronchial Valves for Emphysema without Interlobar Collateral Ventilation. *N Engl J Med*. 2015 Dec;373(24):2325–35.
- 3 Criner GJ, Sue R, Wright S, Dransfield M, Rivas-Perez H, Wiese T, et al.; LIBERATE Study Group. A Multicenter Randomized Controlled Trial of Zephyr Endobronchial Valve Treatment in Heterogeneous Emphysema (LIBERATE). *Am J Respir Crit Care Med*. 2018 Nov;198(9):1151–64.
- 4 Herth FJ, Eberhardt R, Gompelmann D, Ficker JH, Wagner M, Ek L, et al. Radiological and clinical outcomes of using Chartis™ to plan endobronchial valve treatment. *Eur Respir J*. 2013 Feb;41(2):302–8.
- 5 Gesierich W, Samitas K, Reichenberger F, Behr J. Collapse phenomenon during Chartis collateral ventilation assessment. *Eur Respir J*. 2016 Jun;47(6):1657–67.
- 6 Gesierich W, Samitas K, Behr J. Determining collateral ventilation during bronchoscopy: unanswered questions. *Thorax*. 2014 Mar;69(3):289–90.
- 7 Herzog D, Thomsen C, Poellinger A, Doellinger F, Schreiter N, Froeling V, et al. Outcomes of Endobronchial Valve Treatment Based on the Precise Criteria of an Endobronchial Catheter for Detection of Collateral Ventilation under Spontaneous Breathing. *Respiration*. 2016;91(1):69–78.
- 8 Slebos DJ, Shah PL, Herth FJ, Valipour A. Endobronchial Valves for Endoscopic Lung Volume Reduction: Best Practice Recommendations from Expert Panel on Endoscopic Lung Volume Reduction. *Respiration*. 2017;93(2):138–50.
- 9 Welling JB, Klooster K, Hartman JE, Kerstjens HA, Franz I, Struys MM, et al. Collateral Ventilation Measurement Using Chartis: Procedural Sedation vs General Anesthesia. *Chest*. 2019 Nov;156(5):984–90.
- 10 Watanabe Y, Matsuo K, Tamaoki A, Komoto R, Hiraki S. Bronchial Occlusion With Endobronchial Watanabe Spigot. *J Bronchology Interv Pulmonol*. 2003;10:264–7.
- 11 Welling JB, Hartman JE, van Rikxoort EM, Ten Hacken NH, Kerstjens HA, Klooster K, et al. Minimal important difference of target lobar volume reduction after endobronchial valve treatment for emphysema. *Respirology*. 2018 Mar;23(3):306–10.





## CHAPTER 8

# HRCT-Approximated Perfusion is Comparable to Nuclear Perfusion Imaging in Severe COPD

**T. David Koster**

Jean-Paul Charbonnier

Jan Pruim

Hester A. Gietema

Rein Posthuma

Lowie E.G.W. Vanfleteren

Marlies van Dijk

Karin Klooster

Dirk-Jan Slebos

*Adapted from Am J Respir Crit Care Med, 2023 May 16. Online ahead of print.*



## TO THE EDITOR

Bronchoscopic lung volume reduction with one-way endobronchial valves (EBV) in patients with severe hyperinflation and emphysema has shown to significantly improve lung function, quality of life and exercise capacity.<sup>1,2</sup> With this therapy, the most diseased lobe is occluded with EBVs to induce a lobar atelectasis, thus reducing hyperinflation. Using quantitative computed tomography (CT)-scan analysis, the key features of a treatment target lobe can be accurately assessed: emphysema distribution and severity, and fissure completeness score as surrogate of absent interlobar collateral ventilation.<sup>3-5</sup> Additionally, assessment of lung and lobar perfusion is important to select the optimal treatment target lobe, especially in case of a homogeneous emphysema distribution, or multiple potential targets.<sup>3</sup> Patients with low target lobe perfusion and high perfusion in the ipsilateral lobe are better responders of EBV therapy with regard to exercise capacity.<sup>6</sup> Perfusion distribution can be estimated using regular scintigraphy with Technetium-99m (Tc-99m) labeled microalbumin aggregates (MAA). However, this planar technique does not accurately assess the lobar distribution. Lobar perfusion can also be quantified with single photon-emission computed tomography (SPECT) or dual-energy contrast-enhanced CT-scans (DCE-CT).<sup>7,8</sup> Nevertheless, these perfusion techniques require additional scans, radiation exposure and costs. A significant relationship between the pulmonary small vessels as assessed with quantitative CT-scan analysis and perfusion scintigraphy has already been described.<sup>9</sup> New artificial intelligence (AI) based algorithms can quantify lobar perfusion distribution from the available high resolution CT (HRCT) and provide a complete information package for optimal EBV target lobe selection in just one diagnostic procedure.<sup>3</sup> Therefore, in this study, we investigated whether AI perfusion distribution approximated from an inspiratory HRCT provides similar information as compared to perfusion scintigraphy and SPECT-CT.

## METHODS

We included all patients with severe chronic obstructive pulmonary disease (COPD) who were screened for EBV treatment and who underwent both HRCT and planar perfusion scintigraphy (time frame 2014-2019) or SPECT-CT (time frame 2019-2022). We performed two separate analyses to compare both planar perfusion scintigraphy and SPECT-CT to approximated CT perfusion. All patients provided written informed consent regarding the use of their data for future scientific purposes, which was approved by the medical ethics committee of the University Medical Center Groningen (METC2016.483) and Maastricht University Medical Center (METC2018-0868). Thirona's CT perfusion approximation analysis (PXT; Patent Application No. 17/004,073) was performed to estimate pulmonary perfusion from HRCT scans (LungQ v3.0.0, Thirona, Nijmegen, The Netherlands).<sup>10</sup> PXT is an AI-based deep learning algorithm designed to recognize pulmonary perfusion and detect chronic perfusion defects from a single non-contrast CT scan by automatically combining information regarding the parenchymal tissue, pulmonary arteries and veins and it can provide anatomical

quantification (i.e. perfusion per lung, lobe or (sub-)segmental). In this study, PXT scores were quantified for the left and right lung, and each of the individual lobes. Perfusion scintigraphy and SPECT-CT were performed after injection of Tc-99m macroaggregated albumin. For perfusion measured with SPECT-CT, scans were processed with quantitative lung application software (GE Healthcare NM/CT 87 or Siemens Symbia T Series with LungVQ algorithm, Lung Analysis Suite v1.0), to provide perfusion per lobe. To compare the two methods, the Intraclass Correlation Coefficient (Two-Way Mixed, absolute agreement, average measures) was computed. The Bland-Altman method was used to calculate the mean difference of PXT and the perfusion in each lung (for perfusion scintigraphy) and each lung and all lobes separately (for SPECT-CT) and calculate the 95% limits of agreement.

## RESULTS

We included 292 patients with severe COPD (69% female, mean age  $62\pm 23$  years, BMI  $24\pm 4$  kg/m<sup>2</sup>, FEV<sub>1</sub>  $27\pm 8\%$  predicted, Residual Volume  $237\pm 49\%$  predicted). Of these, 207 underwent perfusion scintigraphy plus HRCT and 85 underwent SPECT-CT plus HRCT.

### Perfusion scintigraphy vs PXT comparison

The mean percentage of perfusion of the left lung was  $49\pm 9\%$  compared to  $48\pm 8\%$  with the PXT method, and for the right lung  $51\pm 9\%$  versus  $52\pm 8\%$  (**Table 1**). The mean difference between perfusion and PXT for both lungs was  $0.6\pm 3.5\%$  ( $p=0.018$ ). The Intraclass Correlation Coefficient was 0.92 ( $p<0.01$ ) and the 95% Limits of Agreement ranged from -6.19 to 7.33% (**Table 1**).

### SPECT-CT vs PXT comparison

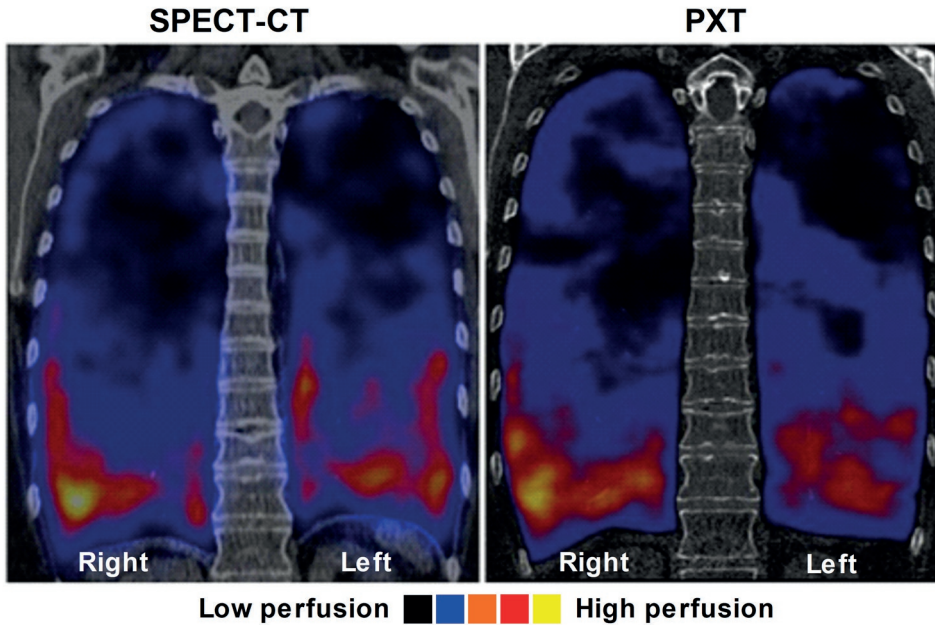
The perfusion measured with SPECT-CT of the separate lobes varied from  $6\pm 4\%$  to  $28\pm 12\%$  and with PXT  $6\pm 4\%$  to  $27\pm 10\%$ . The intraclass Correlation Coefficient varied from 0.88 in the middle lobe to 0.97 in the left lower lobe (**Table 1**). An example of an individual case that shows the perfusion with both SPECT-CT and PXT is provided in **Figure 1**.

**Table 1** - Results of comparison between perfusion scintigraphy and PXT, and SPECT-CT and PXT.

	Perfusion scintigraphy	PXT				
<b>N=207</b>	<b>Perfusion</b>	<b>Perfusion</b>	<b>Difference (%)</b>	<b>p-value</b>	<b>95% Limits of</b>	<b>Intraclass correlation</b>
	<b>Mean ± SD (%)</b>	<b>Mean ± SD (%)</b>	<b>± SD (%)</b>		<b>Agreement</b>	<b>coefficient (95%-CI)</b>
<b>Left Lung</b>	49 ± 9	48 ± 8	0.6 ± 3.5	<b>0.02</b>	-6.19 to 7.33	0.96 (0.94 – 0.97)
<b>Right Lung</b>	51 ± 9	52 ± 8	-0.6 ± 3.5	<b>0.02</b>	-7.33 – 6.19	0.96 (0.94 – 0.97)
	SPECT	PXT				
<b>N=85</b>	<b>Perfusion</b>	<b>Perfusion</b>	<b>Difference (%)</b>	<b>p-value</b>	<b>95% Limits of</b>	<b>Intraclass correlation</b>
	<b>Mean ± SD (%)</b>	<b>Mean ± SD (%)</b>	<b>± SD (%)</b>		<b>Agreement</b>	<b>coefficient (95%-CI)</b>
<b>Left Lung</b>	48 ± 9	46 ± 8	1.5 ± 3.5	<b>&lt;0.01</b>	-5.4 – 8.5	0.95 (0.91 – 0.97)
<b>Right Lung</b>	52 ± 9	54 ± 8	-1.5 ± 3.5	<b>&lt;0.01</b>	-8.5 – 5.4	0.95 (0.91 – 0.97)
<b>LUL</b>	23 ± 10	22 ± 9	1.6 ± 3.4	<b>&lt;0.01</b>	-5.1 – 8.3	0.96 (0.92 – 0.98)
<b>LLL</b>	25 ± 11	25 ± 9	0 ± 3.2	0.46	-6.4 – 6.3	0.97 (0.96 – 0.98)
<b>RUL</b>	22 ± 12	21 ± 10	1.4 ± 3.9	<b>&lt;0.01</b>	-6.2 – 8.9	0.96 (0.94 – 0.98)
<b>RML</b>	6 ± 4	6 ± 4	0 ± 2.5	0.49	-4.9 – 4.9	0.88 (0.82 – 0.93)
<b>RUL + RML</b>	28 ± 12	27 ± 10	1.4 ± 3.4	<b>&lt;0.01</b>	-5.3 – 8.1	0.97 (0.95 – 0.98)
<b>RLL</b>	24 ± 10	27 ± 9	-2.9 ± 3.2	<b>&lt;0.01</b>	-9.0 – 3.2	0.95 (0.70 – 0.98)

**Abbreviations:** SD: Standard Deviation. CI: Confidence Interval; SPECT: single photon-emission computed tomography; PXT: Thirona's CT perfusion approximation analysis; LUL: Left Upper Lobe; LLL: Left Lower Lobe. RUL: Right Upper Lobe. RML: Right Middle Lobe. RLL: Right Lower Lobe.





**Figure 1** - Example of a patient with the results of perfusion on a lobar level measured with both SPECT-CT and PXT.

Figure shows the coronal view of matched SPECT and CT (left) and the comparable image of the heatmap acquired with PXT (right). Perfusion is distributed mainly in the lower lobes. Lobar data of SPECT vs PXT: Right Upper Lobe: 11% vs 12%; Right Middle Lobe: 3% vs 6%; Right Lower Lobe: 37% vs 37%; Left Upper Lobe: 9% vs 10%; Left Lower Lobe: 40% vs 35%.

**Abbreviations:** SPECT: single photon-emission computed tomography; PXT: Thirona's CT perfusion approximation analysis.

**Clinical usability of PXT compared to SPECT-CT**

Of the 85 patients who underwent SPECT-CT analysis for lung volume reduction evaluation, 38 patients actually underwent a lung volume reduction treatment (33 treatments with one-way valves, 5 patients underwent surgical lobectomy). The treatment target lobe identified by SPECT-CT and PXT was identical in all these patients.

## DISCUSSION

Pulmonary perfusion distribution approximated from an HRCT scan using the novel AI based PXT method provides similar information as the current perfusion standard of care using either regular perfusion scintigraphy or SPECT-CT. There is a high correlation between the perfusion scintigraphy and PXT for the left and right lung separately and between SPECT-CT and PXT for all lobes separately. To our knowledge, this current study is the first study to compare quantitative CT-perfusion to perfusion scintigraphy for both the left and right lung and on a lobar level. The high correlation and small mean difference between PXT and SPECT-CT makes this novel quantitative analysis a valuable addition to the already used quantitative HRCT-scan analysis with information regarding the fissure completeness, lobar volumes and emphysema destruction score. We found a slight difference in perfusion per lung and per lobe. This may be due to the fact that both methods are quite different. Perfusion measured by PXT uses information from pulmonary arteries, veins and parenchymal tissue to provide information about chronic perfusion defects whereas nuclear perfusion imaging is a dynamic method and provides the actual distribution of the blood throughout the lung. Furthermore, for lobar comparison, SPECT-CT is the reference test in this study. However, the automated software used to identify lungs and lobes may also exhibit a certain margin of error.

The use of PTX has not yet been prospectively validated for use in clinical practice. In our patient group, there was no difference in target lobe selection of the patients who were treated. We expect that the reported differences between perfusion scores are not clinically relevant as the differences are small and perfusion is generally used as addition to other quantitative measurements. We therefore think that the selection of the treatment target lobe will not be different. However, this is an important subject that should be confirmed in other studies.

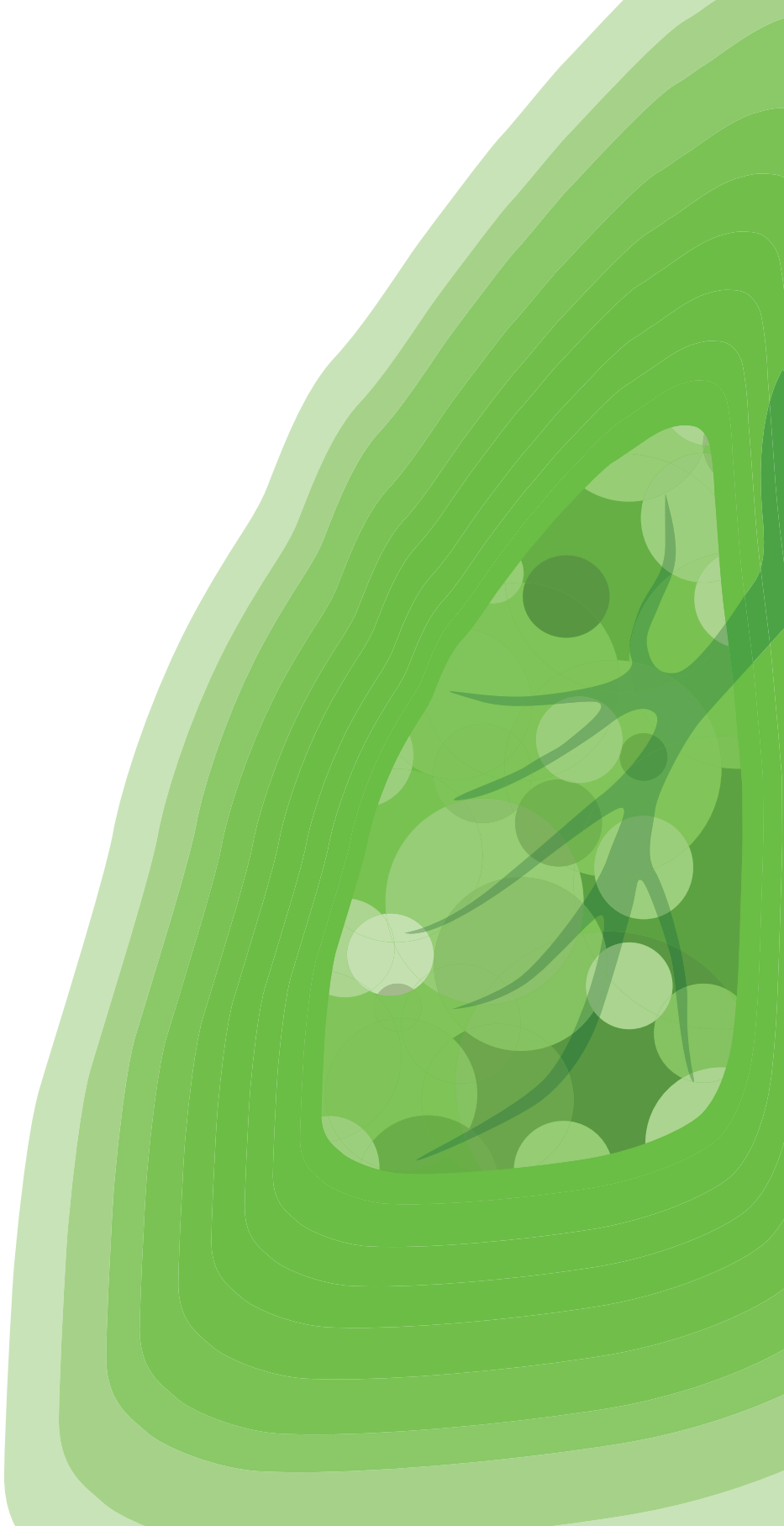
## CONCLUSION

Quantitative CT approximated perfusion using artificial intelligence based software (PXT) is highly comparable to perfusion scintigraphy and SPECT-CT to determine the perfusion per lung and on a lobar level. This novel technique is a valuable addition to the current reports of quantitative CT-scan analysis in patients eligible for lung volume reduction treatment to guide optimal treatment target lobe selection and save additional testing, radiation and costs.

**REFERENCES**

- 1 Klooster K, ten Hacken NH, Hartman JE, Kerstjens HA, van Rikxoort EM, Slebos DJ. Endobronchial Valves for Emphysema without Interlobar Collateral Ventilation. *N Engl J Med* 2015; 373:2325-2335.
- 2 Criner GJ, Sue R, Wright S, Dransfield M, Rivas-Perez H, Wiese T, Sciurba FC, Shah PL, Wahidi MM, de Oliveira HG, Morrissey B, Cardoso PFG, Hays S, Majid A, Pastis N, Jr., Kopas L, Vollenweider M, McFadden PM, Machuzak M, Hsia DW, Sung A, Jarad N, Kornaszewska M, Hazelrigg S, Krishna G, Armstrong B, Shargill NS, Slebos DJ, Group LS. A Multicenter Randomized Controlled Trial of Zephyr Endobronchial Valve Treatment in Heterogeneous Emphysema (LIBERATE). *Am J Respir Crit Care Med* 2018; 198: 1151-1164.
- 3 Klooster K, Slebos DJ. Endobronchial Valves for the Treatment of Advanced Emphysema. *Chest* 2021; 159: 1833-1842.
- 4 Klooster K, Koster TD, Ruwwe-Glosenkamp C, Theilig D, Doellinger F, Saccomanno J, Kerstjens HAM, Slebos DJ, Hubner RH. An Integrative Approach of the Fissure Completeness Score and Chartis Assessment in Endobronchial Valve Treatment for Emphysema. *Int J Chron Obstruct Pulmon Dis* 2020; 15: 1325-1334.
- 5 Koster TD, van Rikxoort EM, Huebner RH, Doellinger F, Klooster K, Charbonnier JP, Radhakrishnan S, Herth FJ, Slebos DJ. Predicting Lung Volume Reduction after Endobronchial Valve Therapy Is Maximized Using a Combination of Diagnostic Tools. *Respiration* 2016; 92: 150-157.
- 6 Thomsen C, Theilig D, Herzog D, Poellinger A, Doellinger F, Schreiter N, Schreiter V, Schurmann D, Temmesfeld-Wollbrueck B, Hippenstiel S, Suttorp N, Hubner RH. Lung perfusion and emphysema distribution affect the outcome of endobronchial valve therapy. *Int J Chron Obstruct Pulmon Dis* 2016; 11: 1245-1259.
- 7 Jeyin N, Desai SR, Padley SPG, Wechalekar K, Gregg S, Sousa T, Shah PL, Allinson JP, Hopkinson NS, Begum S, Jordan S, Kemp SV, Ridge CA. Dual-energy Computed Tomographic Pulmonary Angiography Accurately Estimates Lobar Perfusion Before Lung Volume Reduction for Severe Emphysema. *J Thorac Imaging* 2022.
- 8 Gietema HA, Walraven KHM, Posthuma R, Mitea C, Slebos DJ, Vanfleteren L. Dual-Energy Computed Tomography Compared to Lung Perfusion Scintigraphy to Assess Pulmonary Perfusion in Patients Screened for Endoscopic Lung Volume Reduction. *Respiration* 2021; 100: 1186-1195.
- 9 Matsuoka S, Yamashiro T, Matsushita S, Fujikawa A, Yagihashi K, Kurihara Y, Nakajima Y. Relationship between quantitative CT of pulmonary small vessels and pulmonary perfusion. *AJR Am J Roentgenol* 2014; 202: 719-724.
- 10 Charbonnier JP, Rikxoort EM. Computer Implemented Method for Estimating Lung Perfusion from Thoracic Computed Tomography Images. Available from: <https://patents.google.com/patent/US20210059624A1/en>. Accessed at May 9th 2023.





## CHAPTER 9

# **Endobronchial valve therapy for severe emphysema: an overview of valve-related complications and its management**

T. David Koster  
Karin Klooster  
Nick H.T. Ten Hacken  
Marlies van Dijk  
Dirk-Jan Slebos

*Adapted from Expert Rev Respir Med. 2020 Dec;14(12):1235-1247*

## **ABSTRACT**

### **Introduction**

Bronchoscopic lung volume reduction treatment with one-way valves is an effective guideline treatment option for patients with severe emphysema. However, important challenges and adverse reactions may occur after treatment.

### **Areas covered**

This review summarizes the complications after endobronchial and intrabronchial valve treatment that have been described by the currently published randomized controlled trials and other relevant papers regarding the complications and its management. In case there was no relevant literature regarding these subjects, recommendations are based on expert opinion. Complications include pneumothorax, post-obstruction pneumonia and hemoptysis. Also, the treatment may not be effective due to the presence of collateral ventilation or misplaced valves. Furthermore, an initial beneficial effect may vanish due to granulation tissue formation, valve dysfunction or valve migration. Careful follow-up after treatment with valves is important. Evaluation with a CT-scan and/or bronchoscopy is needed if there is no improvement after treatment, loss of benefit, or occurrence of important adverse events during follow-up.

### **Expert opinion**

Treating severe emphysema patients with one-way valves requires continuous dedication and expertise, especially to achieve an optimal outcome and elegantly deal with the various complications after treatment.

## INTRODUCTION

Patients with chronic obstructive pulmonary disease may suffer from severe emphysema and hyperinflation.<sup>1</sup> In carefully selected patients, lung volume reduction surgery or bronchoscopic lung volume reduction can be a successful addition to the treatment of this very disabled patient group. Bronchoscopic lung volume reduction treatment with one-way endobronchial valves (Zephyr EBV (Pulmonx, Redwood City, CA, USA) or the Spiration® Valve System (SVS, Olympus, Redmond, WA, USA)) has developed into an important treatment strategy for carefully selected emphysema patients.<sup>2-12</sup> The goal of bronchoscopic lung volume reduction treatment (BLVR) is to achieve a complete occlusion of the most diseased lobe with valves, which induces a lobar atelectasis, thereby causing reduction of hyperinflation. This results in clinically relevant improvements in quality of life, lung function, and exercise capacity, which has been proven by various randomized controlled trials (**Table 1**).<sup>2-10</sup>

Valve treatment is a valuable enrichment in the therapy of this severely diseased end-stage patient group who have limited treatment options, and is included in the GOLD COPD treatment recommendations.<sup>13</sup> However, patient selection, treatment, logistics and follow-up need to be very dedicated and requires sufficient expertise to achieve full benefit of the valve treatment.<sup>12</sup> Current recommendations regarding these subjects are described in the best practice recommendations by Slebos et al.<sup>12</sup> After placement of valves, there are potential future challenges such as lack of benefit after treatment, or loss of benefit during follow-up. Furthermore, adverse events like pneumothorax and granulation tissue formation can occur. Although most adverse events are reported in the published papers, there is no extensive overview of these problems and its dedicated management.

After valve treatment, it is recommended to monitor the patient for clinical, radiological, and lung functional improvement (or deterioration). Generally, a patient should be reevaluated if there is no improvement after initial treatment, or if there is loss of the initially observed benefit during the follow-up. Furthermore, clinical signs like persistent cough, recurrent pneumonias and hemoptysis require an additional evaluation with computed tomography (CT) scan and/or bronchoscopy.

In this review, we will discuss challenges and common adverse events effects following bronchoscopic valve treatment and share our experience in the management of these situations. We used all published randomized controlled trials regarding the treatment with endobronchial (Zephyr) and intrabronchial (SVS system) valves and screened these for complications. The PubMed database was searched using the terms 'COPD', 'emphysema', 'hyperinflation', and other synonyms, combined with 'bronchoscopic lung volume reduction' and synonyms, combined with 'complications' and all frequently described complications and synonyms (e.g. 'pneumothorax', 'granulation tissue formation'). As the current available literature does not always provide definite evidence regarding these problems and its management, a part of this review is based on expert opinion.



**Table 1** - Efficacy outcomes and reported serious adverse events (SAE) for the seven published randomized controlled trials using valves for emphysema.

Study	Davey Lancet, 2015 BELIEVER-HIFI <sup>[4]</sup>		Klooster NEJM, 2015 STELVIO <sup>[7]</sup>		Valipour AJRCCM, 2016 IMPACT <sup>[10]</sup>		Kemp AJRCCM, 2017 TRANSFORM <sup>[8]</sup>		Criner AJRCCM, 2018 LIBERATE <sup>[9]</sup>		Li Respiration, 2019 REACH <sup>[6]</sup>		Criner AJRCCM, 2019 EMPROVE <sup>[2]</sup>		
<b>Efficacy</b>															
Follow up time	6 months		3 months		3 months		6 months		12 months		6 months		6 months		
6MWD change	%	-	-	+19.6	-3.6	+10.6	-3.9	-	-	-	-	-	-	-	
	m	+25	+3	+60	-14	+22.6	-17.3	+36.2	-0.7	+13.0	-26.3	+20.8	-15.6	-4.4	-11.3
FEV <sub>1</sub> change	%	+8.8	+2.9	+20.9	+3.1	+13.8	-3.5	+20.7	-8.6	+17.2	-0.8	-	-	-	-
	ml	+60	+30	+161	+21	+100	-20	+140	-90	104	-3	+91	-24	+90	+2
RV change	%	-6.6	-2.1	-	-	-21.1	-0.3	-	-	-	-	-	-	-	-
	ml	-260	-80	-865	-34	-420	-50	-660	+10	-490	+30	-420	-50	-402	-42
SGRQ change	-4.4	-3.6	-17.4	-2.7	-8.63	+1.01	-7.2	-0.7	-7.55	-0.50	-8.39	+2.11	-8.1	+4.8	
<b>Complications reported as SAE</b>															
Valve type	EBV		EBV		EBV		EBV		EBV		SVS		SVS		
Follow up time	3 months		6 months		3 months		Variable <sup>*</sup>		Variable <sup>#</sup>		6 months		Variable <sup>§</sup>		
	EBV N=25	Control N=25	EBV N=34	Control N=34	EBV N=43	Control N=50	EBV N=65	Control N=32	EBV N=128	Control N=62	EBV N=66	Control N=33	EBV N=113	Control N=59	
Pneumothorax (%)	8	3	18	0	25.6	0	20.0	0	26.6	0	7.6	0	12.4	0	
Pneumonia (%)	8	0	6	3	0	2.0	3.1	0	6.6	0	1.5	0	0	0	
							4.6	0	0.8	0			8.9	1.7	
COPD exacerbation (%)	20	12	12	6	16.3	12	4.6	0	7.8	4.8	19.7	12.1	16.8	10.2	
							4.6	6.3	23.0	30.6			13.6	8.5	
Death (%)	8	0	3	0	0	2	1.5	0	3.1	0	0	3.0	0	0	
							0	0	0.8	1.6			1	0	
Valve migration or dislocation (%)	20	0	9	0	4.6	0	-	-	-	-	-	-	-	-	

<sup>\*</sup> follow-up: 0–30 days and 30 days – 6 months; <sup>#</sup> follow-up: 0–45 days and 45 days – 12 months; <sup>§</sup> follow-up: 0–6 months and 6–12 months.

**Abbreviations:** SVS: Spiration Valve System; EBV: Endobronchial valves; FEV<sub>1</sub>: Forced Expiratory Volume in the first second; RV: Residual Volume; SGRQ: St George's Respiratory Questionnaire; 6MWD: 6 minute walking distance.

## FOLLOW-UP

Follow-up after treatment is important to monitor for treatment effect, loss of effect or complications. Most patients will be treated by their own pulmonologist and collaboration with the treating center and the primary pulmonologist is essential. Some complications can be managed by the patient's pulmonologist; however, valve-specific problems will require more specific expertise.

In our center, our follow-up after valve treatment is arranged as follows: At 1 week, a brief consultation by telephone. After approximately 6–8 weeks, the patient will visit the outpatient clinic with a low dose chest CT-scan, pulmonary function tests and health status update. If a patient experiences clinical benefit, the follow-up is after 6 months and yearly after the procedure up to 5 years. All this data is captured in our registry ('BREATH-NL'; NCT0281568). If there is no clinical benefit or no volume reduction, earlier follow-up is indicated. Patients are instructed to contact their pulmonologist or us in case of clinical deterioration or emergencies. In this case, earlier visit to the outpatient clinic, with CT-scan and/or lung function is indicated.

## LACK OF EFFICACY AFTER INITIAL VALVE TREATMENT

After valve treatment, the first follow-up is recommended at approximately 6–8 weeks to assess the initial outcome, as the treatment effect is not immediate in all patients. If there is no clinical benefit, it is important to review the patient carefully. The two most common causes of lack of effect are the presence of collateral ventilation and valve misplacement or migration. Follow-up may consist of a (low dose) chest CT, pulmonary function test (spirometry and body plethysmography) and health status of the patient.

### Presence of collateral ventilation

An important predictor of effect is the absence of collateral ventilation between the target lobe and the ipsilateral lobe(s). If a patient does not have clinical effect after treatment, it is important to review the possibility of collateral ventilation. The presence or absence of collateral ventilation can be assessed with a Chartis (Pulmonx, Redwood City, CA, USA) measurement during bronchoscopy.<sup>14</sup> If collateral ventilation is present, valve therapy will not be effective as air leakage from the ipsilateral lobe will prevent substantial volume reduction of the treated lobe.<sup>7</sup>

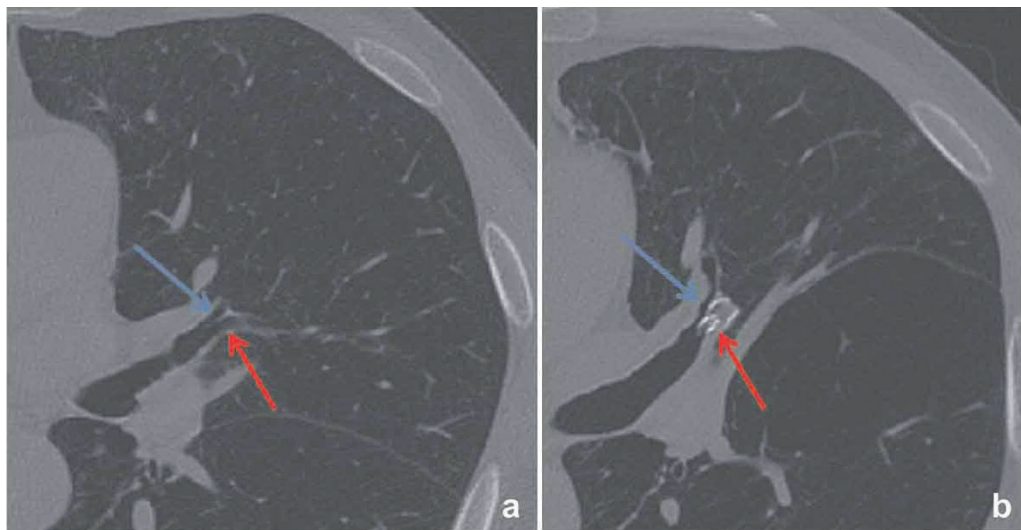
An alternative method to predict the presence of potential collateral ventilation is the fissure completeness score (FCS) as determined by quantitative CT-analysis. Using quantitative CT analysis by the StratX platform (PulmonX, CA, USA), the FCS has shown good correlations with functionally assessed air leakage assessed with Chartis.<sup>15,16</sup>

In patients with (nearly) complete fissures between the target lobe and ipsilateral lobe(s) (>95%), there is frequently no collateral ventilation. However, a part of the patients may still have collateral ventilation and thus no lung volume reduction effect.<sup>16</sup> Recent evidence shows that there is also a difference between the right and left fissures. In patients with a

left major fissure completeness score of 95–100%, approximately 10% of the patients will still have collateral ventilation, whereas for the right major fissure, with fissure completeness score of 95–100%, approximately 25% of the patients will still have collateral ventilation.<sup>15</sup> Therefore, if Chartis measurement was not performed, the presence of collateral ventilation may well be the cause of the lack of effect, particularly in patients with lower FSC scores. However, even Chartis measurements may fail to predict absence of collateral ventilation and thus successful valve treatment. Such a failure may be due to a challenging measurement. For example, if the Chartis catheter is obstructed by mucus plugs or due to contact with the mucosa of the airways, this can incorrectly be interpreted as absence of collateral ventilation. Another example is if the lower lobes exhibit a low-flow or no-flow pattern, which may also be falsely interpreted as absence of collateral ventilation.<sup>17</sup> If this is the case, collateral ventilation over the major fissure can be measured in the left upper lobe for the left major fissure, or the right upper lobe with temporary occlusion of the middle lobe with a Watanabe spigot or balloon for the right major fissure.<sup>12,18</sup> However, a small defect in the right major fissure at the middle lobe level can be hard to detect with Chartis and provide false-negative results. If there is no radiological lung volume reduction effect in patients, the fissures on CT scan and the results of the Chartis measurement should be critically reviewed. A bronchoscopy may prove collateral ventilation by demonstrating a clear picture of continuous opening and closing ('venting') of the valves. A Chartis measurement may yet be performed or repeated, but if collateral ventilation is proven in a patient without effect, the valves have to be removed, as there will not be effect in the future, and they may cause complications as granulation tissue formation, hemoptysis, and bacterial colonization.<sup>19,20</sup> In this case, other therapies can be considered, for example, lung volume reduction surgery or coils. However, before removing valves, proper placement of the valves needs to be confirmed.

### Valve misplacement

Complete lobar occlusion of the treatment target is obligatory to achieve successful lung volume reduction. Due to collateral ventilation between lobar segments, a complete lobar occlusion is only guaranteed if every valve is placed optimally. If there is no significant lung volume reduction visible on the CT scan, it is recommended to carefully evaluate on CT-scan the position of every valve and search for the presence of untreated airways (**Figure 1**). In case of an untreated airway or valve dislocation, it is recommended to perform a revision bronchoscopy. However, if the CT-scan does not give a clue for the lack of effect, a revision bronchoscopy might still be considered to assess for small missed subsegments or a slightly misplaced valve. Furthermore, it is important that the sizing of the valves has been done correctly. There are several available sizes of both the SVS and the EBV, adequate placement of the valves depends on the size and anatomy of the airways. Undersized valves will lead to leakage and incomplete lobar occlusion, oversizing might lead to pressure necrosis of the local airway and granulation tissue formation. During the procedure, airway edema may arise due to suctioning or airway manipulation (e.g. Chartis measurement). If this is the case, it may adversely affect the valve sizing decisions.<sup>12</sup>



**Figure 1** - Example of an incomplete occlusion of the lingula.

**A.** LB4 (red arrow) and LB5 (blue arrow) before treatment. **B.** The EBV was supposed to occlude both segments, but occluded only LB4, thus preventing the occurrence of a full lobar atelectasis.

### Adhesions

Extensive adhesions between the target lobe and the parietal pleura may prevent the lobe from collapsing. From the NETT trial publications, we know that 18% of 552 evaluable patients had 'marked' adhesions.<sup>21</sup> The presence of adhesions is also the reason that patients with prior surgery on the same side as the target lobe (e.g. pleurodesis or pleurectomy) are most often excluded for endobronchial valve treatment.<sup>22</sup> Adhesions may be visible on CT-scan, but currently it is not known whether this correlates to treatment success or the ability to achieve an atelectasis.<sup>23</sup> If there is no effect after treatment with valves, there is no presence of collateral ventilation and revision bronchoscopy did not show evidence of valve dysfunction, adhesions may be the cause of the treatment failure. In this case, removal of valves can be considered.

Removal of valves is bronchoscopically best performed via a rigid or flexible intubation to prevent damage to the vocal cords. However, this can also be done very cautiously without endobronchial tube. Removal will be easier by using rat-tooth graspers or alligator jaw grasping forceps and slowly apply pulling pressure. Some local airway bleeding may occur. It has been shown that endobronchial valves can be removed safely.<sup>24</sup>

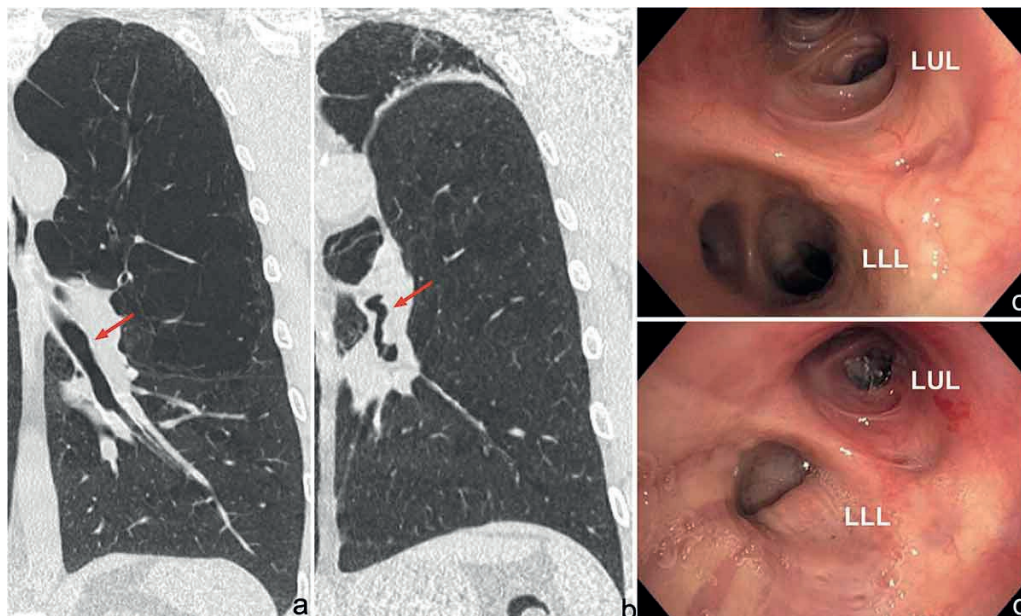
### **Temporary shunting**

After a successful lung volume reduction treatment with atelectasis of the treated lobe, shunting and subsequent hypoxemia may develop directly after treatment due to decreased ventilation in combination with intact perfusion. In most cases, the hypoxemia is temporary and self-resolving because the alveolar hypoxemia causes pulmonary vasoconstriction.<sup>25</sup> However, sometimes hypoxemia may persist because the patient uses medication that inhibits the desired vasoconstriction, such as calcium channel blockers.<sup>26</sup> If this is the case, discontinuation of this medication may be considered. If the hypoxemia due to shunting does not resolve and the patient has no clinical benefit after treatment, or needs excessive amounts of oxygen, it may be necessary to remove the valves.

### **Central airway ‘folding’**

Due to the desired valve-induced atelectasis, there will be a change in the position of the remaining lobe(s) and airways. Very rarely this may lead to bronchial folding, airway narrowing and even torsion of the non-treated lobe. These problems have been described after surgical lobectomy, and mainly after treatment of the upper lobes.<sup>27,28</sup>

The occurrence of bronchial angulation after valve treatment has been reported in less than 5% of treated patients.<sup>29-31</sup> The clinical presentation may be relatively mild, but due to the narrowing or folding of airways there may be complaints of dyspnea caused by a ventilation/perfusion mismatch and mucus retention with persistent cough (**Figure 2**). Especially in a patient with a perfect treatment and subsequent radiological response, but worsening of clinical parameters and symptoms, this problem should be acknowledged. A CT-scan and bronchoscopy can be performed to confirm this diagnosis. Depending on the magnitude of symptoms a patient exhibits, airway folding can be accepted in combination with sputum expectoration techniques. However, if there is no clinical effect after treatment, the valves can be removed, to regain the original position of the airways.<sup>30</sup>



**Figure 2** - Bronchial angulation of the non-treated lobe left lower lobe.

The red arrows indicate the airways before (A and C) and after (B and D) treatment, and shows the folding of the airway of the left lower lobe. Abbreviations: LUL; Left Upper Lobe, LLL; Left Lower Lobe.

## LOSS OF BENEFIT AFTER VALVE TREATMENT

After initially successful valve treatment, patients may complain about a deterioration in their clinical situation over time. This loss of benefit can be temporarily due to intercurrent problems such as a COPD exacerbation or pneumonia. However, when this decline persists despite being recovered from these events, it is important to evaluate whether there are other underlying causes. Both a (low dose) CT scan and bronchoscopy can be performed in these situations.

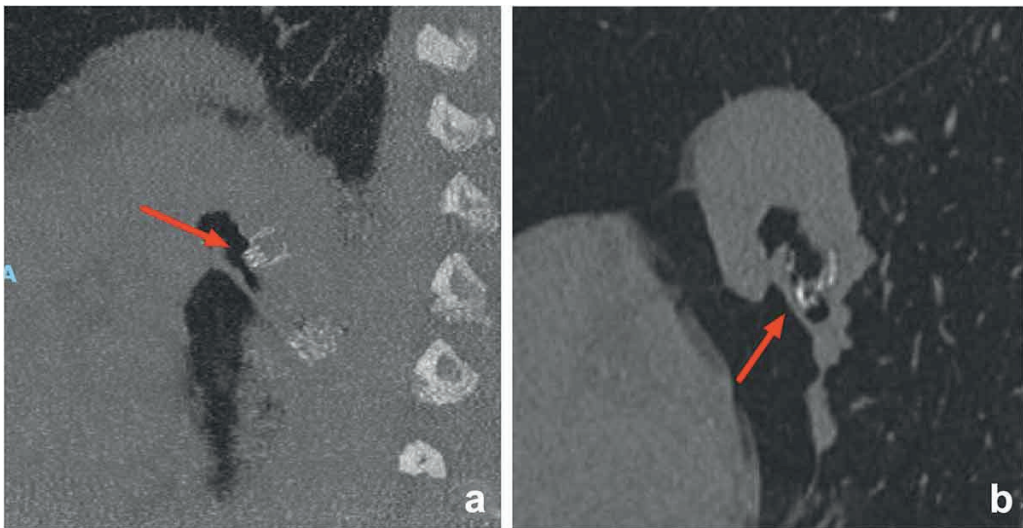
In case the desired complete atelectasis is still visible on the CT scan, the decline of the patients' condition may possibly be explained as a result of either ongoing progression of COPD, or due to compensatory expansion of the adjacent lobe.<sup>32</sup>

Significant lobar volume reduction after treatment will lead to volume redistribution to the ipsilateral lobe(s). The expansion of the ipsilateral lobe involves the relatively less diseased tissues.<sup>33,34</sup> Nevertheless, there is still a significant improvement of the expiratory low attenuation area and air trapping with an improvement of lung mechanisms.<sup>33,34</sup> However, in some cases there may be an over-hyperinflation of the non-treated ipsilateral lobe, leading to less (and sometimes zero) effect on lung function even with a complete atelectasis. This compensatory overexpansion of residual lung lobes has been described after surgery,

but for lung volume reduction in patients with severe emphysema this is currently mainly observational and there are currently no studies to further characterize the patients at risk for compensatory overexpansion.<sup>35,36</sup>

Other causes of decline may be concurrent local issues like a foreign body aspiration, or new underlying diseases such a pulmonary embolism, pulmonary hypertension or cardiac pathology.

If the obtained lung volume reduction after treatment has disappeared on the follow-up scan, the decline is probably caused by local airway wall reaction to the valves, leading to malfunctioning of the valves and re-expansion of the treated lobe. In this case, it is recommended to perform a 'revision bronchoscopy' after thorough evaluation of the valve position on CT scan. Detection of valve-related issues on CT scan (and even during bronchoscopy) can however be very challenging and frequently needs a very precise comparison with previous valve positions on CT-scan (**Figure 3**). There are several valve-related causes for the loss of lung volume reduction, which will be described in more detail below.

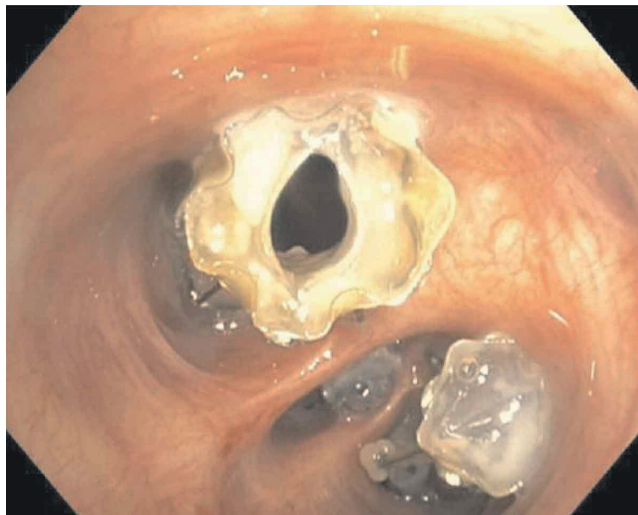


**Figure 3** - Images of thorax CT scan showing valve migration.

In this case, the left lower lobe was treated with endobronchial valves and 6 weeks after treatment a complete atelectasis of the target lobe was achieved with a significant clinical benefit. After six months, there was loss of clinical benefit and no more lung volume reduction. **A.** EBV well positioned in LB6. **B.** Complete re-expansion of the treated lobe, the valve in LB6 is dislocated and now in a different position compared to the follow-up scan at six weeks.

### Valve malfunction

One-way valve function can be compromised due to abundant mucus impaction and bacterial or fungal colonization (**Figure 4**). In this situation, the valve will be in 'open' position continuously, and during inhalation air will flow into the target lobe, resulting in re-expansion. This cannot be detected by CT-scan easily. The affected valve(s) can be removed bronchoscopically and new valve(s) can be replaced during the same session. Furthermore, antibiotics can be prescribed based on culture samples obtained in the same session.



**Figure 4** - Malfunction of EBV due to mucus impaction.

The valve mechanism is compromised and constant flow over the valve prevents target lobe volume reduction.

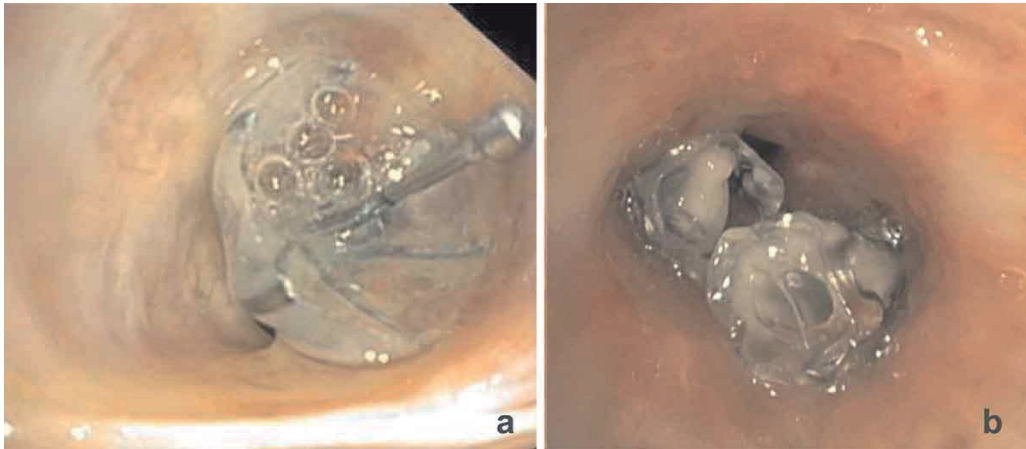
### Incomplete occlusion of airway

Dislocation of a valve may lead to an incomplete occlusion of the airway. Subsequently, air can leak alongside the valve, resulting in re-expansion of the target lobe. Sometimes, this incomplete occlusion of the airways only takes place during inspiration, when the airways tend to distend. This may be difficult to detect during bronchoscopy, with minor variations in airway movements. Dislocation can be caused by the formation of granulation tissue, significant local bronchomalacia, bronchitis and other local factors. Also, hyperdynamic airways, or excessive dynamic airway collapse (even of segmental bronchi)—often present in emphysema—may promote migration of the valves over time due to excessive variations in airway diameter.

During revision bronchoscopy it is recommended to evaluate the position of each valve. Due to the presence of excessive granulation tissue it can be very challenging to detect which valve is responsible for the incomplete occlusion of a (sub)segment (**Figure 5**). Partial patent airway lumen alongside the valve is not always directly visible. Investigation of possible



leakage can be performed by carefully flushing saline at the valve location and check for air bubbles appearing outside the valve mechanism itself, proving the presence of air leakage. Another way to demonstrate incomplete occlusion, is by flushing saline or air into the treated segment. If the valve is undersized, this will easily pass the valve. Affected valves can be removed and replaced during the same procedure. Depending on the local situation the size of the valves may be adjusted or they can be replaced more distally.<sup>12,37</sup> A more proximal valve positioning using a larger sized valve is not recommended in these cases.



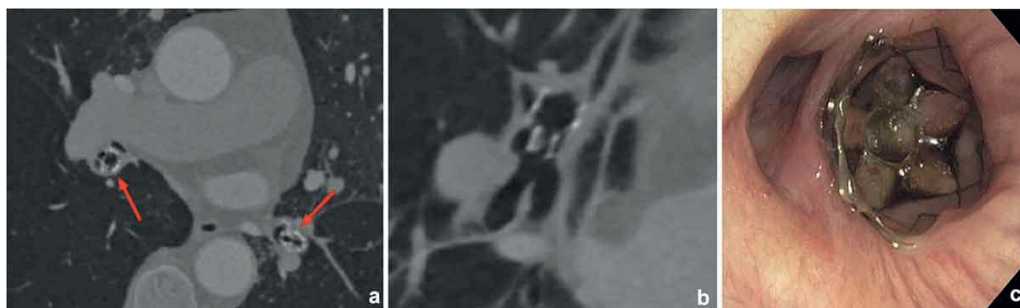
**Figure 5** - Loss of effect due to valve dislocation which causes leakage along the Spiration Valve System (A) and Endobronchial Valve (B).

### Valve migration

Valve migration may occur spontaneously and in particular when sizing or placement of the valves has been done incorrectly. Valve migration has been described in the lower lobes more often, probably due to more collapse of the bronchi compared to the upper lobes.<sup>38</sup> Therefore, although it might be tempting to place a single valve in the lower lobes, it is recommended to place more valves distally in the individual segments.<sup>12</sup>

The extent of the valve migration is most often limited to minor changes in the original position; however, sometimes the valves may migrate to the ipsilateral lobe(s), the contralateral lung or be expectorated. Clinical signs that are suggestive of valve migration are sudden loss of beneficial effect, increased coughing and sudden chest discomfort.<sup>12,29</sup> Also, the history may reveal a whistling sound on inspiration.<sup>39</sup> It is important that patients with acute loss of initial benefit and increased dyspnea are evaluated carefully and in short-term. A chest X-ray should be used to exclude a pneumothorax, valve migration can sometimes also be observed. Using a CT scan in these situations, valve position, migration, and target lobe volume reduction can be examined much more precisely. Seldomly, a migrated valve can occlude another, non-treated segment or lobe, potentially leading to (obstruction-) pneumonia, or even a pneumothorax. Furthermore, if the valve is migrated into a reversed

position, hyperinflation of the obstructed lung part may follow due to a reversed one-way valve mechanism, potentially leading to a pneumothorax (**Figure 6**). If there is (suspicion of) dislocation or migration of valves, a bronchoscopy can be performed to evaluate and replace the affected valves.<sup>12</sup>



**Figure 6** - Migration of EBV to the contralateral lung.

Endobronchial valves were placed into the left lower lobe resulting in a complete atelectasis and clinical benefit. One year after the treatment, the patient presented with complaints of progressive dyspnea. **A.** The CT-scan showed migration of a valve from the left lower lobe to the right lower lobe, the arrows indicate the position of the valves on both sides. **B.** The valve in the entrance of the non-target right lower lobe in reversed position. **C.** Endoscopic image of the valve position in reversed position, which was removed and replaced by a new valve in the original left lower lobe position.

## 5. COMPLICATIONS DIRECTLY RELATED TO VALVE TREATMENT

### Granulation tissue

The formation of granulation tissue is a medium to longer term complication of the treatment with valves (both EBV and SVS). It is hypothesized that the cause of the granulation tissue formation is the contact of the foreign body with the airway mucosa, where both shape, pressure and repetitive motion will cause an inflammatory response, with granulation tissue formation as result (**Figure 7**).<sup>30</sup> Furthermore, contact of the valve with the adjacent or opposite bronchial wall during movement or coughing may also induce granulation tissue. Granulation tissue formation is described in approximately 40–50% of patients that need valve removal or revision bronchoscopy.<sup>30</sup>

The occurrence of airway granulation may also be associated with an increased bacterial load.<sup>20,40</sup> In a single-center study, it has been reported that there is an increased bacterial colonization after valve implantation. Treatment with valves, acting as a foreign body, can promote fungal colonization and impede mucociliary clearance, subsequently leading to retention of secretions, stimulating the bacterial colonization.<sup>40</sup> It is currently not known whether maintenance antibiotics, prednisolone, or high-dose inhaled corticosteroids prevents or reduces the formation of granulation tissue in patients with valves.

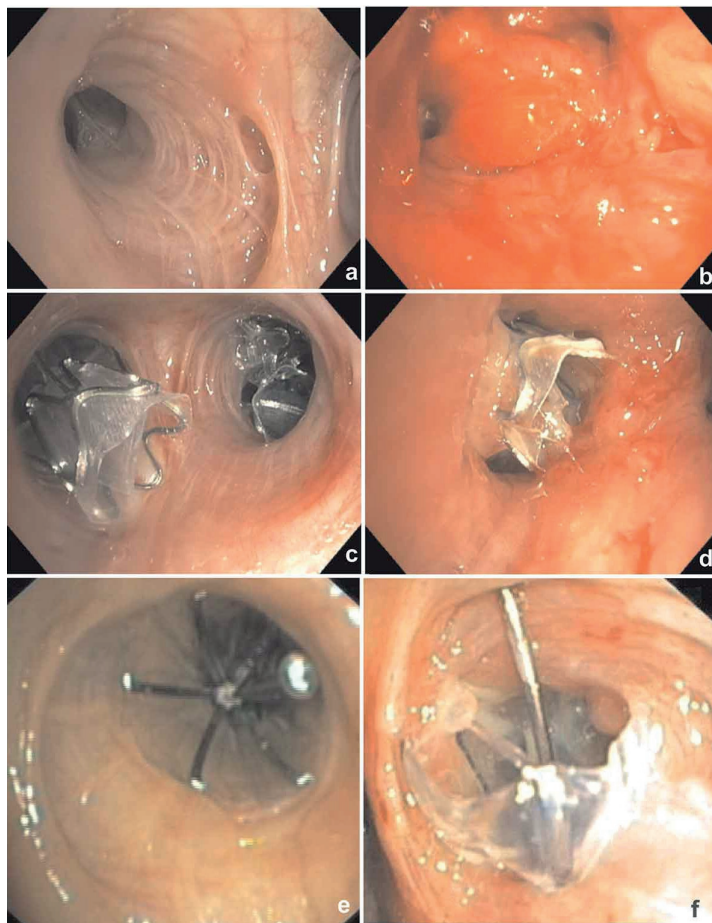
Due to the granulation tissue, a valve might (slightly) dislocate, leading to loss of the lung

volume reduction effect. In case of loss of benefit due to the formation of granulation tissue, it is advisable to bronchoscopically remove this valve. In case of mild to moderate granulation tissue formation, valves can be replaced during the same procedure. If possible, a valve can be replaced more distally to prevent the formation of granulation tissue at the same site. More proximal replacement may be possible, but in our opinion this should be avoided as granulation tissue may be more likely to develop due to more movement of the valves in the larger airways.

In case of severe granulation tissue formation, we recommend to remove the valves and wait for approximately 10–12 weeks before revision and re-treatment, to promote the recovery of the airways. Earlier treatment is possible, but with the risk of granulation tissue still being present, thus causing the treatment to be more difficult to perform.

In addition, it is our practice to prescribe a course of corticosteroids (30 mg prednisolone) a few days before valve removal (to facilitate ease of removal) and approximately 1 week after (to facilitate airway healing) in case of severe granulation tissue formation. Macrolide antibiotics (azithromycin) or 'culture-based' antibiotics can be prescribed after the treatment. In general, there is no need for other interventional treatment with laser, cryoablation, or coagulation, as the underlying cause has already been removed.

If there is a re-occurrence of granulation tissue formation or if the granulation reaction was very severe, it is an option not to replace but to remove all valves. As an alternative, a VATS (video-assisted thoracic surgery) lobectomy can be considered, especially if the treatment was initially very beneficial for the patient (and confirmed by radiological and pulmonary function improvement), and the patient is still fit for this intervention.<sup>41</sup>



**Figure 7** - Endoscopic images showing granulation tissue in the segmental airways.

A. RB3 (anterior segment of the right upper lobe) before treatment. B. Same segment (RB3), after removal of the valve, which shows an extensive granulation reaction behind the valve. C. RB3 and RB2 (posterior segment of the right upper lobe) directly after placement of EBVs. D. Same position as in C with granulation tissue. E. Endobronchial view of an SVS directly after placement. F. Endobronchial view of the SVS being displaced with granulation tissue formation.

## Pneumothorax

A pneumothorax is a common complication after valve treatment and occurs in 4.2–26.6% of the treated patients.<sup>2,3,5–10</sup> After treatment with valves, the volume of the emphysematous target lobe is reduced. Part of this volume reduction is compensated by the expansion of the untreated ipsilateral lobe.<sup>34,42</sup> Due to the volume reduction, the negative pleural pressure may change significantly and promote bullae or bleb rupture in the expanded ipsilateral lung tissue. Furthermore, the shifts of the lung may lead to ruptures of bullae or blebs due to preexisting pleural adhesions (**Figure 8**).<sup>42</sup> Symptomatic pneumothoraces may constitute life-threatening conditions in severe emphysema patients, requiring immediate drainage with a chest tube.

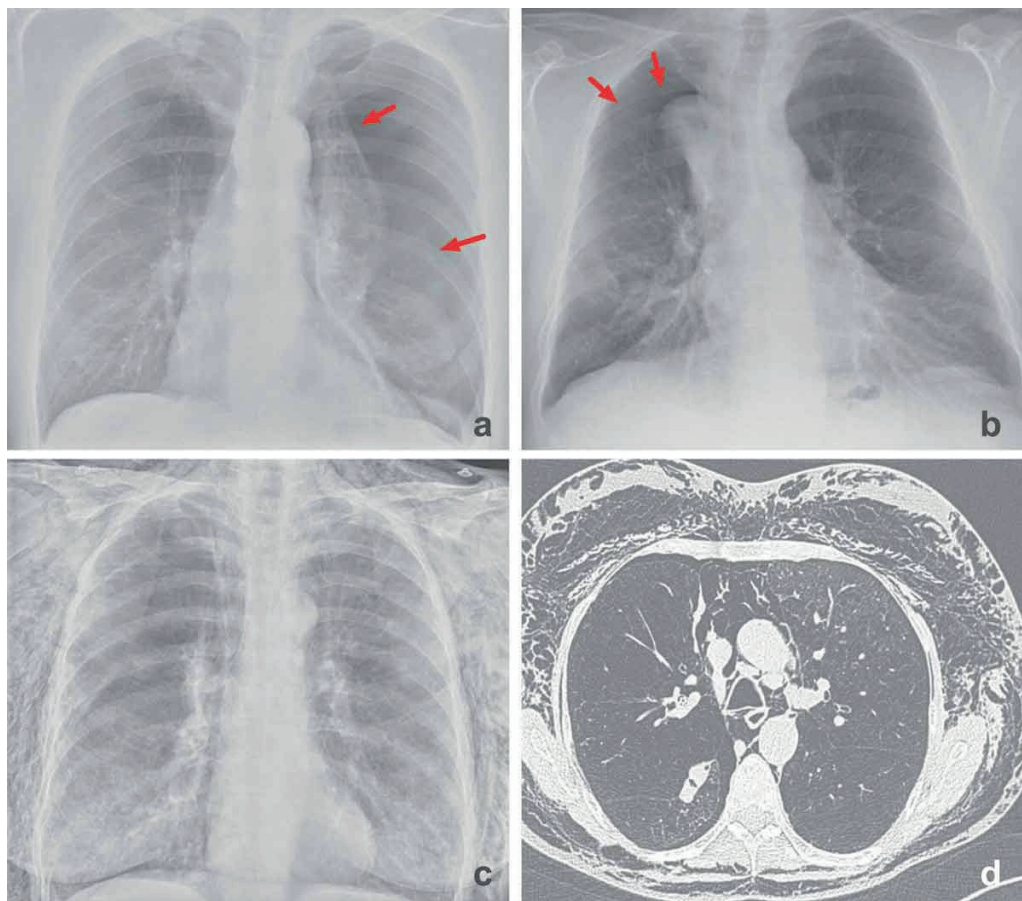
Another potential manifestation is the ‘pneumothorax ex vacuo’, which means there is air in the pleural space, but no active air leak. There are two hypotheses as to how this develops. It is possible that there is a trauma of the treated lobe in which a part of the volume expands to the pleural cavity, but the valves prevent an active air leak. Most often, the size of the pneumothorax is small.<sup>42</sup> Another hypothesis is that due to the increase in negative intrapleural pressure after the acute lobar collapse, air from the surrounding tissue and blood is drawn into the pleural space. In this case, the pleura remains intact and there is no bronchopleural fistula.<sup>42,43</sup> In case of a pneumothorax ex vacuo, drainage is normally not necessary and a ‘wait-and-see’ policy can be successful in these patients as the pneumothorax will slowly resolve (**Figure 8**).

In case of a small pneumothorax without dyspnea or pain, prolonged observation is recommended. However, if the symptoms deteriorate or the size of the pneumothorax is increasing, a chest tube should be placed. Normally, a 14 French chest tube should suffice, but in case of a non-re-expanding pneumothorax or the development of subcutaneous emphysema, a large-bore chest tube should be considered.<sup>44</sup>

In most situations, chest tube drainage is sufficient to treat the pneumothorax.<sup>7,10</sup> In case the lung does not expand and/or there is a persistent or significant air leak, removal of valves can be considered after a few days. The removal of one or more valves will lead to re-expansion of the treated lobe and improve the contact of the pleural surfaces to promote healing of the pneumothorax. If the air leak stops and pneumothorax resolves after valve removal, the chest tube can be removed. Because valve removal can be performed rather easily, general anesthesia is not necessary in most cases. An extra reason to avoid general anesthesia is that positive pressure ventilation of emphysema patients with a pneumothorax is considered less safe. Not all valves have to be removed to re-expand the treated lobe and to recover from a pneumothorax. It is sufficient to remove only those valves that are most easy to reach. Valves can be replaced after approximately 6–8 weeks after removal of the chest tube, as it has been shown that these patients can experience significant functional improvements.<sup>42,45</sup>

In case of a persistent air leak despite the removal of valves, other options should be considered, comparable to the standard care of a pneumothorax. However, in the majority of the patients this is not necessary. This includes mechanical or chemical pleurodesis or use of a Heimlich valve. Furthermore, one-way valves can be used to treat persistent air leaks. In

this case, valve insertion in the targeted airways leading to the region of the air leakage may lead to a resolution or reduction of the air leak.<sup>42,46</sup> Furthermore, video-assisted thoracoscopic surgery (VATS) with bullectomy can be performed to treat the air leak.<sup>42</sup> However, the choice and timing of therapy are dependent on both clinical parameters, patient preference, and the availability of several options within the institution.<sup>42</sup>

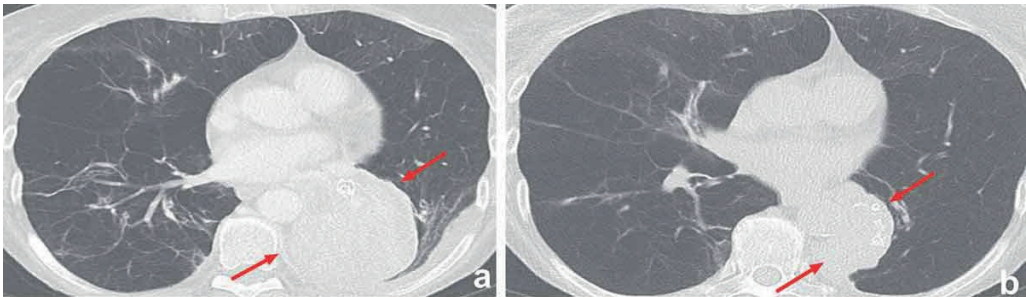


**Figure 8** - **A.** Pneumothorax 1 day after treatment with endobronchial valves in the left upper lobe (indicated by arrows). There is a mediastinal shift to the right, indicating volume expansion due to the pneumothorax. This patient was treated with a chest tube only. **B.** Pneumothorax ex vacuo (indicated by arrows) 1 day after treatment with endobronchial valves in the right upper lobe, the pneumothorax resolved spontaneously. Note: there is still volume loss on the site of the pneumothorax. **C.** and **D.** Extensive subcutaneous emphysema and pneumomediastinum due to a large air leak after treatment of the left lower lobe. This patient was successfully treated with surgical bullectomy to treat the air leak.

After valve placement, approximately 0–8% of the patients develop a pneumonia in the first year.<sup>2–10</sup> This is reported in both the treated lobe (0.9–3.6% of the patients<sup>2,5,7,9</sup>) as in the non-treated lobes (2.3%–7.1% of patients<sup>2,5,9</sup>).

To potentially decrease the incidence of respiratory exacerbations, a course of prophylactic antibiotics and steroids are often prescribed around the bronchoscopy according to local guidelines. This intervention is mainly pragmatic and not evidence based.

In case of a bacterial pneumonia, a broad-spectrum oral antibiotic is advised. In case the pneumonia is located distal to the valves, removal of the valves should strongly be considered if the pneumonia does not clearly respond to treatment with (intravenous) broad-spectrum antibiotics (**Figure 9**). Approximately 6 weeks after treatment, the valves can be replaced.<sup>12</sup> A COPD exacerbation should be treated in accordance with standard care, with oral corticosteroids and inhaled bronchodilators. The LIBERATE study showed a strong trend toward a reduction of serious COPD exacerbations requiring hospitalization in patients treated with endobronchial valves in long-term follow-up.<sup>3</sup>



**Figure 9** - This patient was successfully treated with endobronchial valves in the left lower lobe.

Two years later the patient presented with a postobstruction pneumonia. **A**. The CT-scan showed an increased volume of the atelectasis of the left lower lobe. **B**. After treatment with antibiotics and removal of two of the valves, there was clinical improvement and partial resolution of the consolidation. Due to the important initial clinical benefit of the valve treatment, this patient was treated by VATS lobectomy after full recovery of the pneumonia, rather than removal of the valves and experienced persistent clinical benefit.

## Hemoptysis

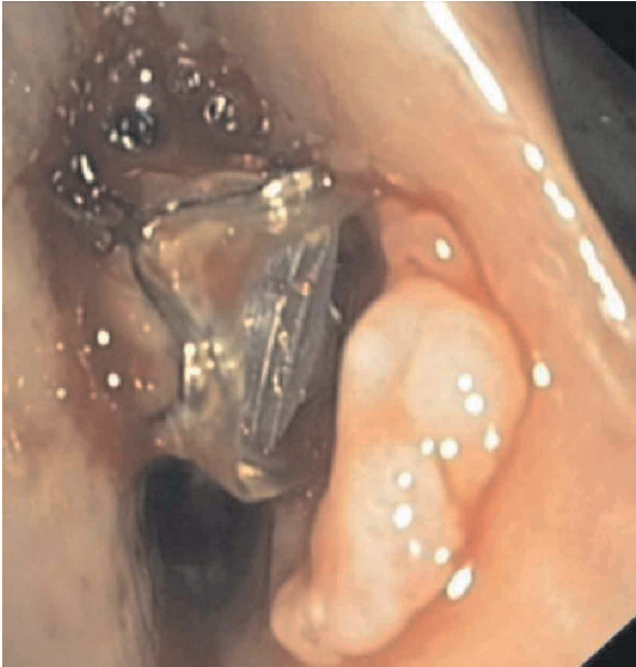Directly after treatment, many patients may experience minor hemoptysis for a few days which is related to the procedure. This is self-limiting in most patients and in this case no further evaluation is required. However, during follow-up hemoptysis is reported in 1.5–5.6% of treated patients.<sup>5,6,9,47</sup> In most cases, the cause of hemoptysis is granulation tissue at the site of the valves or mucosal damage/ulceration due to valve movements (**Figure 10**), and might be more prevalent in patients on systemic anticoagulation.

In patients with minor hemoptysis, a bronchoscopic evaluation is warranted to assess the possible causes and precise location.<sup>12</sup> In case of minor mucosal damage or granulation tissue, a wait and see policy can be justified. A culture sample can guide treatment with antibiotics and a course of prednisolone is advised to treat granulation tissue formation. Small focused local lesions can be treated with coagulation therapy. However, if the hemoptysis is more pronounced, or the granulation reaction is more severe, valve removal is indicated. In these cases, direct replacement is not recommended, to allow full recovery of the bronchus. Furthermore, future treatment at the same position is most often not rational. A more distal replacement can be considered in those situations.

Next to local hemoptysis guidelines, there are several treatment options in case of severe hemoptysis.<sup>48</sup> Pharmacological treatment includes prednisolone and antibiotics, and tranexamic acid may be considered. If a patient uses anticoagulants, these should be discontinued or antagonized. Primarily, a bronchoscopy should be performed. Valves can be removed to treat the cause of the granulomatous reaction. If there is a severe granulomatous reaction, this can be treated with coagulation therapy. It is advised to have a bronchus blocker readily available during the procedure in case of extensive hemoptysis after valve removal. Endovascular interventions may also be considered in case of severe hemoptysis. A CT-scan with intravenous contrast can show pathologically altered bronchial arteries and bronchial artery embolization may be successful if a bronchial artery is thought to be the cause of the hemoptysis.

If it is not possible to regain local control of the bleeding, a thoracic surgeon may be consulted for a lobectomy. If a patient with hemoptysis had a favorable outcome after the valve treatment, a lobectomy can be even more feasible for the patient's outcome, with preservation of the lung volume reduction effects.<sup>12</sup>





**Figure 10** - Airway ulceration due to contact of the valve with the opposite airway wall which led to hemoptysis. In this case valve removal was sufficient to treat the hemoptysis

### Cough

Some patients may exhibit a persistent cough after treatment.<sup>4,7</sup> The cause of coughing is probably the local reaction of the airways to the valves and can be related to the formation of granulation tissue.<sup>30</sup> However, even in patients without evidence of granulation tissue there may be coughing. Furthermore, it may be due to an incomplete atelectasis after valve insertion. Also, airway folding of the untreated lobe can lead to coughing and decreased sputum expectoration (**Figure 2**).

A bronchoscopy can be performed to review local irritation or granulation tissue, perform local cleaning of secretions and take a culture to guide antibiotic treatment. A trial period of antibiotics and prednisolone may be prescribed, but this is not always effective. If, despite these efforts, the cough is persistent in time and invalidating, removal of valves may be considered. However, if there is lung volume reduction and clinical benefit regarding the exercise tolerance and dyspnea, it is very important to discuss the treatment options with the patient as removal of the valves will lead to a relapse of the hyperinflation and thus increase in symptoms, often back to baseline.

## CONCLUSION

In conclusion, treatment with one-way valves is a successful treatment option in carefully selected patients with severe emphysema, with benefits on lung function, quality of life, and exercise tolerance. After treatment, both acute (e.g. pneumothorax) and late-onset (e.g. granulation tissue) manageable complications do occur. It is important to be aware of the possible complications, perform adequate follow-up and handle various complications. The most important tools to identify and manage complications are a dedicated review of the CT-scan and revision bronchoscopies.

## EXPERT OPINION

Patients with severe emphysema are severely disabled and have very limited treatment options. Endobronchial lung volume reduction is an additional treatment for this patient group, and this treatment option is becoming more and more important as worldwide awareness and acceptance in the pulmonary field increases driven by solid science, guidelines, and reimbursement. Treatment with one-way valves is currently the most effective treatment, but only suitable in a small percentage of the patients. Careful patient selection is important to treat only patients that will benefit from the valves. However, even if successful, these patients need dedicated follow-up to monitor treatment effect, and in case of deterioration or complications, a critical reevaluation should be performed to try to regain the effect or treat the complication.

Patients with COPD are a very heterogeneous group and bronchoscopic treatment options are not suitable for all. In the upcoming years, new treatment options will hopefully be developed or become more widely available. Coils, vapor, biologic lung volume reduction or airway bypass can be alternative options for patients with the presence of collateral ventilation.<sup>41,49-51</sup> Further, the presence of collateral ventilation could be blocked by completing the fissure surgically, or endobronchially by delivering a blocking substance at the incomplete part of the fissure.<sup>52,53</sup> An important issue is the biocompatibility of the devices in the lung. A frequent complication of all endobronchial devices (e.g. silicon and metal stents, EBV, and SVS valves and also the former examined airway bypass) is the formation of granulation tissue. If this can be prevented, this would increase the treatment success, treatment options, and decrease the number of complications and need for revision bronchoscopies. Furthermore, in patients with chronic bronchitis, hopefully there will be more successful endobronchial treatment options as targeted lung denervation or nitrogen therapy.<sup>54,55</sup>

**REFERENCES**

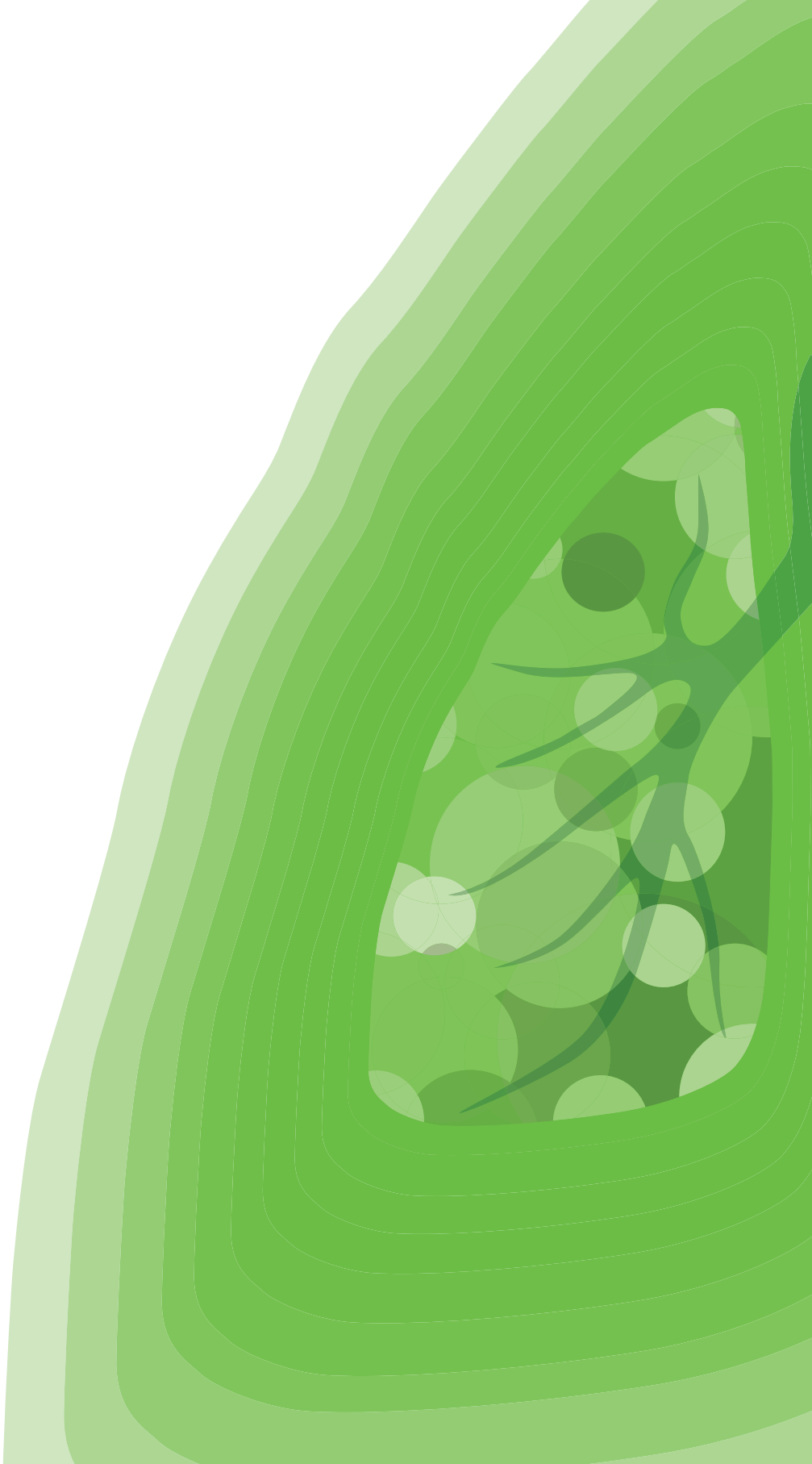
- 1 Gagnon P, Guenette JA, Langer D, et al. Pathogenesis of hyperinflation in chronic obstructive pulmonary disease. *Int J Chron Obstruct Pulmon Dis*. 2014;9:187–201.
- 2 Criner GJ, Delage A, Voelker K, et al. Improving lung function in severe heterogeneous emphysema with the Spiration Valve System (EMPROVE). A multicenter, open-label randomized controlled clinical trial. *Am J Respir Care*. 2019 Jul 31;200(11):1354–1362.
- 3 Criner GJ, Sue R, Wright S, et al. A Multicenter Randomized Controlled Trial of Zephyr Endobronchial Valve Treatment in Heterogeneous Emphysema (LIBERATE). *Am J Respir Crit Care Med*. 2018 Nov 1;198(9):1151–1164.
- 4 Davey C, Zoumot Z, Jordan S, et al. Bronchoscopic lung volume reduction with endobronchial valves for patients with heterogeneous emphysema and intact interlobar fissures (the BeLieVeR-HiFi study): a randomised controlled trial. *Lancet*. 2015 Sep 12;386(9998):1066–1073.
- 5 Herth FJ, Noppen M, Valipour A, et al. Efficacy predictors of lung volume reduction with Zephyr valves in a European cohort. *Eur Respir J*. 2012 Jun;39(6):1334–1342.
- 6 Kemp SV, Slebos DJ, Kirk A, et al. A multicenter randomized controlled trial of zephyr endobronchial valve Treatment in Heterogeneous Emphysema (TRANSFORM). *Am J Respir Crit Care Med*. 2017 Dec 15;196(12):1535–1543.
- 7 Klooster K, Ten Hacken NH, Hartman JE, et al. Endobronchial valves for emphysema without interlobar collateral ventilation. *N Engl J Med*. 2015 Dec 10;373(24):2325–2335.
- 8 Li S, Wang G, Wang C, et al. The REACH trial: A randomized controlled trial assessing the safety and effectiveness of the Spiration(R) valve system in the treatment of severe emphysema. *Respiration*. 2019;97(5):416–427.
- 9 Sciruba FC, Ernst A, Herth FJ, et al. A randomized study of endobronchial valves for advanced emphysema. *N Engl J Med*. 2010 Sep 23;363(13):1233–1244.
- 10 Valipour A, Slebos DJ, Herth F, et al. Endobronchial valve therapy in patients with homogeneous emphysema. Results from the IMPACT study. *Am J Respir Crit Care Med*. 2016 Nov 1;194(9):1073–1082.
- 11 Shah PL, Slebos DJ. Bronchoscopic interventions for severe emphysema: where are we now? *Respirology*. 2020 May 3. DOI:10.1111/resp.13835
- 12 Slebos DJ, Shah PL, Herth FJ, et al. Endobronchial valves for endoscopic lung volume reduction: best practice recommendations from expert panel on endoscopic lung volume reduction. *Respiration*. 2017;93(2):138–150.
- 13 Singh D, Agusti A, Anzueto A, et al. Global Strategy for the diagnosis, management, and prevention of chronic obstructive lung disease: the GOLD science committee report 2019. *Eur Respir J*. 2019 May;53(5). DOI:10.1183/13993003.00164-2019
- 14 Herth FJ, Eberhardt R, Gompelmann D, et al. Radiological and clinical outcomes of using Chartis to plan endobronchial valve treatment. *Eur Respir J*. 2013 Feb;41(2):302–308.
- 15 Klooster K, Koster TD, Ruwwe-Glosenkamp C, et al. An integrative approach of the fissure completeness score and chartis assessment in endobronchial valve treatment for emphysema. *Int J Chron Obstruct Pulmon Dis*. 2020;15:1325–1334.
- 16 Koster TD, van Rikxoort EM, Huebner RH, et al. Predicting lung volume reduction after endobronchial valve therapy is maximized using a combination of diagnostic tools. *Respiration*. 2016;92(3):150–157.
- 17 Gesierich W, Samitas K, Reichenberger F, et al. Collapse phenomenon during Chartis collateral ventilation assessment. *Eur Respir J*. 2016 Jun;47(6):1657–1667.
- 18 Welling JBA, Koster TD, Hartman JE, et al. Temporary right middle lobe occlusion with a blocking device to enable collateral ventilation measurement of the right major fissure. *Respiration*. 2020;99(6):516–520.

- 19 Nouraei SA, Petrou MA, Randhawa PS, et al. Bacterial colonization of airway stents: a promoter of granulation tissue formation following laryngotracheal reconstruction. *Arch Otolaryngol Head Neck Surg.* 2006 Oct;132(10):1086–1090.
- 20 Sarmand N, Gompelmann D, Kontogianni K, et al. New bacterial growth in bronchial secretions after bronchoscopic valve implantation. *Int J Chron Obstruct Pulmon Dis.* 2018;13:565–570.
- 21 DeCamp MM, Blackstone EH, Naunheim KS, et al. Patient and surgical factors influencing air leak after lung volume reduction surgery: lessons learned from the National Emphysema Treatment Trial. *Ann Thorac Surg.* 2006 Jul;82(1):197–206;discussion 206–7.
- 22 Valipour A. Valve therapy in patients with emphysematous type of chronic obstructive pulmonary disease (COPD): from randomized trials to patient selection in clinical practice. *J Thorac Dis.* 2018 Aug;10(Suppl 23):S2780–S2796.
- 23 van Geffen WH, Klooster K, Hartman JE, et al. Pleural adhesion assessment as a predictor for pneumothorax after endobronchial valve treatment. *Respiration.* 2017;94(2):224–231.
- 24 Hubner RH, Ruwwe-Glosenkamp C, Saccomanno J, et al. Endoscopic lung volume reduction: can endobronchial valves be safely removed? *Respiration.* 2020;99(5):459–460.
- 25 Sylvester JT, Shimoda LA, Aaronson PI, et al. Hypoxic pulmonary vasoconstriction. *Physiol Rev.* 2012 Jan;92(1):367–520.
- 26 Mishra A, Reed RM, Eberlein M. Severe, rapidly reversible hypoxemia in the early period after bilateral lung transplantation. *Ann Am Thorac Soc.* 2016 Jun;13(6):979–985.
- 27 Cable DG, Deschamps C, Allen MS, et al. Lobar torsion after pulmonary resection: presentation and outcome. *J Thorac Cardiovasc Surg.* 2001 Dec;122(6):1091–1093.
- 28 Seok Y, Cho S, Lee JY, et al. The effect of postoperative change in bronchial angle on postoperative pulmonary function after upper lobectomy in lung cancer patients. *Interact Cardiovasc Thorac Surg.* 2014 Feb;18(2):183–188.
- 29 Fiorelli A, D'Andrilli A, Bezzi M, et al. Complications related to endoscopic lung volume reduction for emphysema with endobronchial valves: results of a multicenter study. *J Thorac Dis.* 2018 Oct;10(Suppl 27):S3315–S3325.
- 30 Klooster K, Hartman JE, Ten Hacken NH, et al. One-year follow-up after endobronchial valve treatment in patients with emphysema without collateral ventilation treated in the STELVIO Trial. *Respiration.* 2017;93(2):112–121.
- 31 Caviedes IR, Labarca G, de Oliveira HG, et al. Non-answered questions in patients with endobronchial valve placement for lung volume reduction. *Respiration.* 2018;95(4):269–272.
- 32 Gompelmann D, Heinhold T, Rotting M, et al. Long-term follow up after endoscopic valve therapy in patients with severe emphysema. *Ther Adv Respir Dis.* 2019 Jan-Dec;13:1753466619866101.
- 33 Becker MD, Berkmen YM, Austin JH, et al. Lung volumes before and after lung volume reduction surgery: quantitative CT analysis. *Am J Respir Crit Care Med.* 1998 May;157(5 Pt 1):1593–1599.
- 34 Brown MS, Kim HJ, Abtin FG, et al. Emphysema lung lobe volume reduction: effects on the ipsilateral and contralateral lobes. *Eur Radiol.* 2012 Jul;22(7):1547–1555.
- 35 Ueda K, Tanaka T, Hayashi M, et al. Compensation of pulmonary function after upper lobectomy versus lower lobectomy. *J Thorac Cardiovasc Surg.* 2011 Oct;142(4):762–767.
- 36 Ueda K, Tanaka T, Hayashi M, et al. Computed tomography-defined functional lung volume after segmentectomy versus lobectomy. *Eur J Cardiothorac Surg.* 2010 Jun;37(6):1433–1437.
- 37 Klooster K, van Dijk M, Koster TD, et al. First in human experience of the performance of the new 5.5-LP size zephyr endobronchial valve. *Respiration.* 2020;99(1):50–55.
- 38 Kontogianni K, Gompelmann D, Valipour A, et al. Efficacy and safety of the 9-mm Intrabronchial valve in patients with advanced emphysema. *Respiration.* 2020;99(4):333–343.

- 39 Fiorelli A, Reginelli A, Santini M. Endobronchial valve migration: A "Whistle Blower". *J Bronchology Interv Pulmonol*. 2016 Jul;23(3):e24–6.
- 40 Gompelmann D, Gerovasili V, Kontogianni K, et al. Endoscopic valve removal >180 days since implantation in patients with severe emphysema. *Respiration*. 2018;96(4):348–354.
- 41 Hornemann K, Gompelmann D, Herth FJF, et al. Lung volume reduction surgery (LVRS) after endoscopic lung volume reduction (ELVR) in severe emphysema - A case series. *Eur Respir J*. 2012 Sep 1; 40. DOI:10.1183/09031936.00213711
- 42 Valipour A, Slebos DJ, de Oliveira HG, et al. Expert statement: pneumothorax associated with endoscopic valve therapy for emphysema—potential mechanisms, treatment algorithm, and case examples. *Respiration*. 2014;87(6):513–521.
- 43 Woodring JH, Baker MD, Stark P. Pneumothorax ex vacuo. *Chest*. 1996 Oct;110(4):1102–1105.
- 44 MacDuff A, Arnold A, Harvey J. Group BTSPDG. Management of spontaneous pneumothorax: British thoracic society pleural disease guideline 2010. *Thorax*. 2010 Aug;65(Suppl 2):ii18–31.
- 45 Gompelmann D, Herth FJ, Slebos DJ, et al. Pneumothorax following endobronchial valve therapy and its impact on clinical outcomes in severe emphysema. *Respiration*. 2014;87(6):485–491.
- 46 Travaline JM, McKenna RJ Jr., De Giacomo T, et al. Treatment of persistent pulmonary air leaks using endobronchial valves. *Chest*. 2009 Aug;136(2):355–360.
- 47 Franzen D, Straub G, Freitag L. Complications after bronchoscopic lung volume reduction. *J Thorac Dis*. 2018 Aug;10(Suppl 23):S2811–S2815.
- 48 Radchenko C, Alraiyes AH, Shojaee S. A systematic approach to the management of massive hemoptysis. *J Thorac Dis*. 2017 Sep;9(Suppl 10):S1069–S1086.
- 49 Herth FJF, Slebos DJ, Shah PL, et al. Protocol of a randomized controlled study of the PneumRx Endobronchial Coil System versus Standard-of-Care Medical Management in the Treatment of Subjects with Severe Emphysema (ELEVATE). *Respiration*. 2019;98(6):512–520.
- 50 Snell G, Herth FJ, Hopkins P, et al. Bronchoscopic thermal vapour ablation therapy in the management of heterogeneous emphysema. *Eur Respir J*. 2012 Jun;39(6):1326–1333.
- 51 Shah PL, Slebos DJ, Cardoso PF, et al. Bronchoscopic lung-volume reduction with Exhale airway stents for emphysema (EASE trial): randomised, sham-controlled, multicentre trial. *Lancet*. 2011 Sep 10;378(9795):997–1005.
- 52 Ing A, Sullivan C, Hersch N, et al. Reversal of Collateral Ventilation Using Endobronchial Polymer Sealant in a Patient With Emphysema Undergoing Endoscopic Lung Volume Reduction (ELVR) With Valves: A Case Report and Proof of Concept. *J Bronchology Interv Pulmonol*. 2020 Jan;27(1):e14–e16.
- 53 Majid A, Kheir F, Alape D, et al. Combined thoracoscopic surgical stapling and endobronchial valve placement for lung volume reduction with incomplete lobar fissures: an experimental pilot animal study. *J Bronchology Interv Pulmonol*. 2020 Apr;27(2):128–134.
- 54 Slebos DJ, Breen D, Coad J, et al. Safety and histological effect of liquid nitrogen metered spray cryotherapy in the lung. *Am J Respir Crit Care Med*. 2017 Nov 15;196(10):1351–1352.
- 55 Slebos DJ, Shah PL, Herth FJF, et al. Safety and Adverse Events after Targeted Lung Denervation for Symptomatic Moderate to Severe Chronic Obstructive Pulmonary Disease (AIRFLOW). A multicenter randomized controlled clinical trial. *Am J Respir Crit Care Med*. 2019 Dec 15;200(12):1477–1486.



10



## CHAPTER 10

# Biodegradable stent placement for airway kinking after bronchoscopic lung volume reduction treatment

T. David Koster  
Karin Klooster  
Marlies van Dijk  
Dirk-Jan Slebos

*Adapted from Ann Thorac Surg. 2022 May;113(5):e375-e377*



## **ABSTRACT**

Symptomatic airway kinking after bronchoscopic lung volume reduction with endobronchial valves is rare. Owing to the development of the desired lobar atelectasis, the position of the airways of the nontreated lobe changes, and that might lead to invalidating symptoms. We present a case of a patient with symptomatic airway kinking after treatment with endobronchial valves, who was successfully treated with a single placement of a biodegradable stent. Placement of a biodegradable stent can be considered for symptomatic patients with airway kinking.

## INTRODUCTION

Bronchoscopic lung volume reduction with one-way valves is an important treatment option for selected patients with severe emphysema, hyperinflation and absence of collateral ventilation.<sup>1</sup> Because of the development of the desired atelectasis of the treated lobe after bronchoscopic lung volume reduction with valves, the position of the airways of the nontreated lobes changes. In very rare cases (0% to 6%), that might lead to symptomatic airway kinking,<sup>1,2</sup> which has been described more often after surgical lobectomy and might lead to decreased pulmonary function and increased complaints of coughing, wheezing, and dyspnea.<sup>3-5</sup> Here, we describe a case of a patient with airway kinking after treatment with endobronchial valves that resolved using successful placement of a biodegradable airway stent.

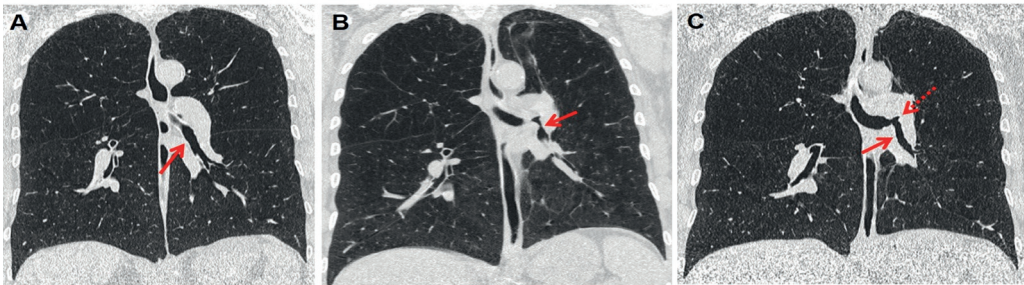
A 59-year-old woman with advanced emphysema and severe hyperinflation was found eligible for bronchoscopic lung volume reduction with endobronchial valves. Before treatment she had a forced expiratory volume in 1 second of 1.12 L (45% of predicted value), residual volume was 3.80 L (203% of predicted value), and residual volume to total lung capacity ratio was 56%. Computed tomography (CT) showed an upper lobe predominant heterogeneous centrilobular emphysema. The left upper lobe was defined as the treatment target lobe. Quantitative CT scan analysis showed a destruction score (percent voxel density less than -950 Hounsfield Units) of 42% for the left upper lobe and 18% for the left lower lobe, with a lobar volume, respectively, of 1642 mL and 1715 mL.

The bronchoscopic lung volume reduction treatment was performed under general anesthesia, absence of collateral flow in the target lobe was confirmed with a Chartis measurement and four endobronchial valves were placed in the left upper lobe. The procedure was uncomplicated.

In the days after the valve treatment, the patient had a significant increase in coughing. Pharmacologic treatment with codeine and a course of prednisolone and amoxicillin did not have any effect on these symptoms. At 2-month follow-up, her complaints persisted and were experienced as invalidating.

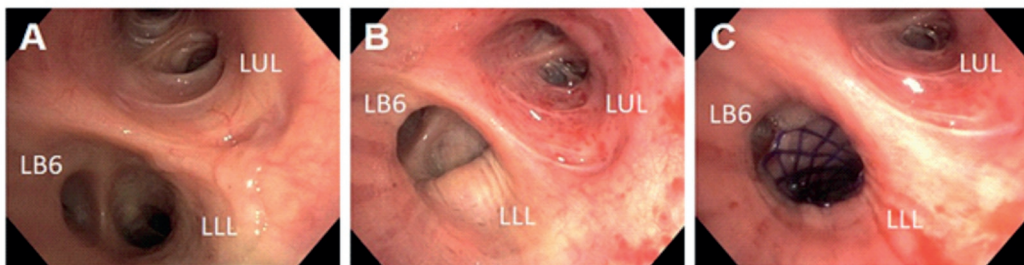
Pulmonary function test showed a significant reduction in residual volume with 850 mL (-22.4% improvement from baseline); however, only a small increase in forced expiratory volume in 1 second (40 mL, +3.6% improvement from baseline) was observed. The CT scan showed complete atelectasis of the left upper lobe with airway kinking of the left lower lobe bronchus (**Figure 1**). Bronchoscopy was performed again and confirmed the left lower lobe airway kinking (**Figures 2A, 2B**). A custom-made biodegradable polydioxanone stent (ELLA-CS, Hradec Králové, Czech Republic) with a diameter of 10 mm and a length of 15 mm was placed between the apex of the left lower lobe (LB6) and the basal segments (LB8, LB9, and LB10; **Figure 2C**). The procedure was performed under general anesthesia with endotracheal tube. The self-expandable custom-made stent was advanced over a guidewire to the correct position. After deployment under direct bronchoscopic visualization, in-stent balloon dilation was performed to secure the position of the stent.

Directly after stent placement, the patient's complaints improved, and 1 day after stent placement the forced expiratory volume in 1 second improved significantly (+18% from baseline). At 6-month follow-up after endobronchial valve treatment (and 2 months after stent placement), she had consistent improvement with minor coughing complaints (chronic obstructive pulmonary disease assessment test improved from 27 to 15 points) and had an increased exercise capacity (6-minute walking distance improved from 350 m to 405 m). The CT scan showed sustained atelectasis of the left upper lobe, and the airway kinking of the left lower bronchus was no longer present (Figure 1C).



**Figure 1**

A. Coronal view of baseline computed tomography scan shows heterogeneous emphysema, with most destruction of upper lobes. Arrow indicates left lower lobe bronchus. B. Follow-up computed tomography scan after treatment with endobronchial valves of left upper lobe, which is not visible owing to lung volume reduction. The left lower lobe bronchus has been displaced superiorly; there is kinking of airway (arrow) between superior segment (LB6) and inferior segments (LB8-10) of left lower lobe. C. Airway stent (arrow) has been placed between LB6 (dashed arrow) and inferior segments; kinking between LB6 and LB8-10 is no longer visible.



**Figure 2**

A. Endoscopic view of entrances to left upper lobe (LUL) and left lower lobe (LLL) before endobronchial valve treatment of LUL with normal anatomy. B. Endoscopic view of entrances to LUL and LLL 2 months after endobronchial valve treatment of LUL, with visible airway kinking of LLL bronchus and endobronchial valve visible in lingular segment (LB4/LB5) of LUL. C. Endoscopic view of entrances to LUL and LLL 149 days after endobronchial valve treatment of LUL, with endobronchial valve visible in lingular segment (LB4/LB5), and biodegradable stent in situ in LLL bronchus (LB6, apical segment of left lower lobe).

## COMMENT

Symptomatic airway kinking after bronchoscopic lung volume reduction with endobronchial valves is rare. If a patient has significant coughing complaints or decreased oxygen saturation, despite the desired atelectasis of the treated lobe, CT evaluation and bronchoscopy are recommended. Valve removal may be necessary to undo the airway kinking, but stent placement may be an alternative and more attractive option to allow sustained lung volume reduction effect.

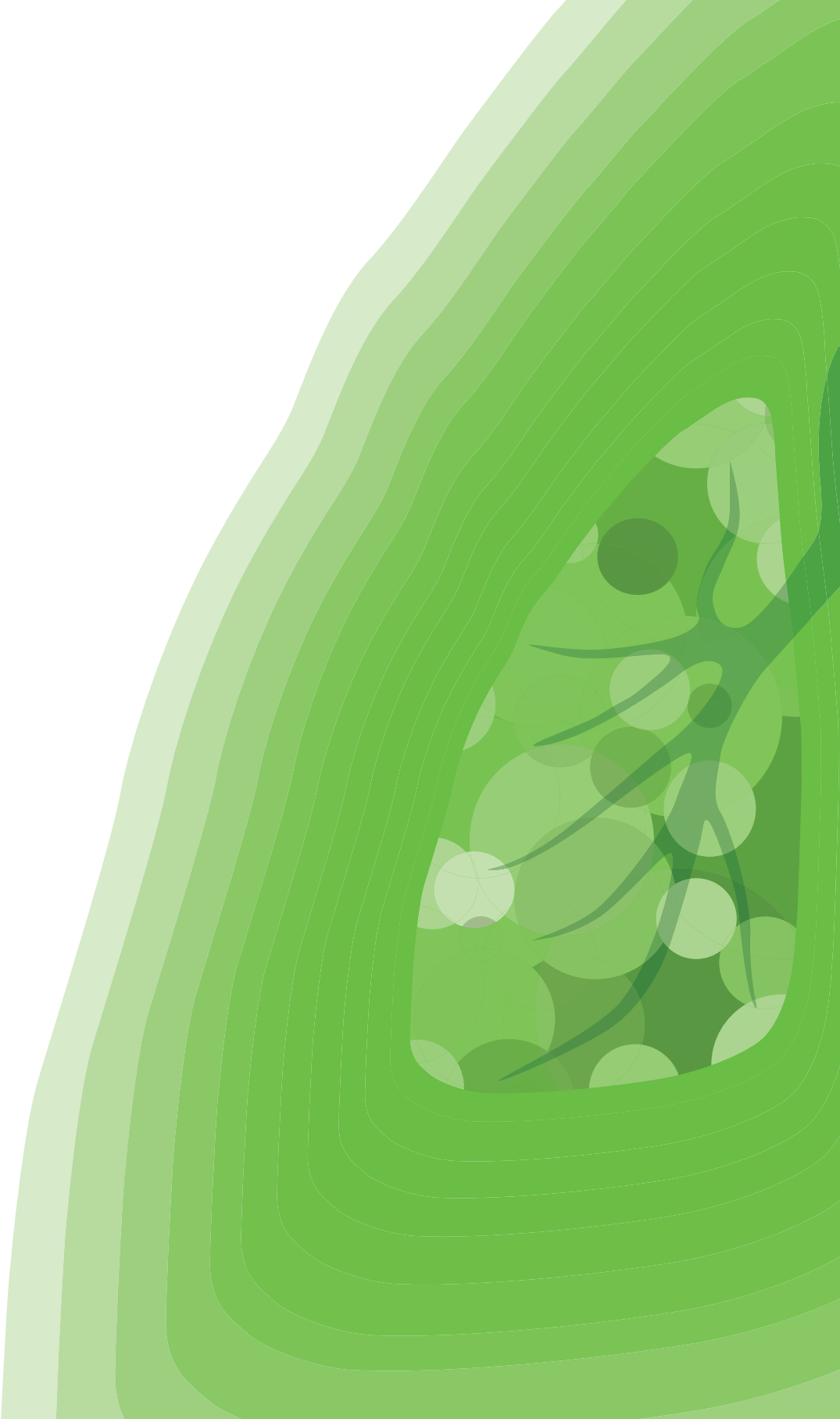
This is the first case published in which an airway stent had been placed for this specific indication. There are some case reports that describe metallic and silicone stent placement for kinking after surgical lobectomy in patients with lung cancer. However, metallic and silicone stents may lead to granulation tissue formation, microbial colonization, and repeated bronchoscopies.<sup>3,6</sup> In this case, a biodegradable stent was used and this may lead to less granulation tissue and biofilm formation. Furthermore, biodegradable stents may avoid the need for permanent stenting. After approximately 4 months, the stent is degraded. It is not always necessary to place a new stent once the stent has degraded.<sup>7,8</sup> In this case, the effect persisted at 8 months of follow-up after stent placement and no revision bronchoscopy was needed, even though the stent was fully degraded at this time. Unfortunately, we have no longer follow-up available because the patient died of a SARS-CoV-2 infection.

In conclusion, placement of a biodegradable airway stent can be considered for symptomatic patients with airway kinking after bronchoscopic lung volume reduction treatment with endobronchial valves. It may also be an option for patients with airway kinking after surgical lobectomy.

**REFERENCES**

- 1 K. Klooster, N.H. ten Hacken, J.E. Hartman, H.A. Kerstjens, E.M. van Rikxoort, D.J. Slebos. Endobronchial valves for emphysema without interlobar collateral ventilation. *N Engl J Med*, 373 (2015), pp. 2325-2335
- 2 T.D. Koster, K. Klooster, N.H.T. Ten Hacken, M. van Dijk, D.J. Slebos. Endobronchial valve therapy for severe emphysema: an overview of valve-related complications and its management. *Expert Rev Respir Med*, 14 (2020), pp. 1235-1247
- 3 C.T. Hutchinson, D. DiBardino, K. Ma, D. Jarrar, S. Singhal, A. Haas. Airway stenting for treatment of left lower lobe airway obstruction after left upper lobectomy. *Ann Am Thorac Soc*, 16 (2019), pp. 1444-1446
- 4 H.G. Oliveira, D.M. Oliveira, C. Greggianin, C.F. Andrade, F.M. Svartman. Biodegradable stent in a patient with recurrent stenosis after lung transplantation. *J Bras Pneumol*, 45 (2019), Article e20190078
- 5 Y. Seok, S. Cho, J.Y. Lee, H.C. Yang, K. Kim, S. Jheon. The effect of postoperative change in bronchial angle on postoperative pulmonary function after upper lobectomy in lung cancer patients. *Interact Cardiovasc Thorac Surg*, 18 (2014), pp. 183-188
- 6 M. Van Leuven, J.A. Clayman, N. Snow. Bronchial obstruction after upper lobectomy: kinked bronchus relieved by stenting. *Ann Thorac Surg*, 68 (1999), pp. 235-237
- 7 H. Dutau, A.I. Musani, S. Laroumagne, K. Darwiche, L. Freitag, P. Astoul. Biodegradable airway stents—bench to bedside: a comprehensive review. *Respiration*, 90 (2015), pp. 512-521
- 8 R. Lischke, J. Pozniak, D. Vondrys, M.J. Elliott. Novel biodegradable stents in the treatment of bronchial stenosis after lung transplantation. *Eur J Cardiothorac Surg*, 40 (2011), pp. 619-624





# CHAPTER 11

## **A multicenter, prospective, single-arm clinical investigation of a modified staged treatment algorithm using the AeriSeal system - The STAGE trial**

**T. David Koster**

Ralf Eberhardt

Ralf-Harto Huebner

Arschang Valipour

Felix Herth

Karin Klooster

Narinder S. Shargill

Sri Radhakrishnan

Dirk-Jan Slebos

*Adapted from Respir Med. 2022 Nov;203:106989.*



## **ABSTRACT**

### **Introduction**

Treatment with AeriSeal is an alternate treatment option to achieve lung volume reduction in patients with severe COPD and emphysema who are not eligible for valve treatment. This study aimed to assess the safety and mode of action of a modified staged treatment algorithm with a staged treatment with lower dose of AeriSeal.

### **Methods**

We performed a prospective, multicenter feasibility study. AeriSeal was administered during two sequential bronchoscopies: 2 subsegments of a lobe treated with two 5 mL doses, followed by two 10 mL doses in a contralateral lobe after 6 weeks.

### **Results**

A total of 14 patients (36% male, mean FEV<sub>1</sub> 28.4% ± 6.7% of predicted) were enrolled. Ten patients completed both treatments, four were treated unilaterally. AeriSeal treatment resulted in significant TLVR (median 220.5 mL) at 3 months follow up. There were no significant changes from baseline at 12 months in lung function, exercise capacity and quality of life. During the 3-month post-treatment period, respiratory SAEs included 5 COPD exacerbations in 4 (28.6%) subjects, post-treatment acute inflammatory response (PAIR) in 2 (14.3%) subjects, and 1 respiratory failure event in 1 (7.1%) subject.

### **Conclusion**

The staged and lower dosed administration of AeriSeal does not impact the overall safety profile in terms of reducing the type and frequency of respiratory SAEs previously reported for a single-stage treatment. A larger volume of AeriSeal than used in this study may be necessary to provide meaningful clinical benefits.

## INTRODUCTION

Bronchoscopic lung volume reduction (BLVR) with endobronchial valves is an established treatment option in patients with severe emphysema and hyperinflation without interlobar collateral ventilation.<sup>1-3</sup> Endobronchial valves are not effective in patients with collateral ventilation and therefore there remains a need for an alternate treatment option for these patients.<sup>4</sup> The AeriSeal System (PulmonX Corp., CA, USA), a cross-linked foam (2.1% aminated polyvinyl alcohol, 1,25% glutaraldehyde, and air) bronchoscopically delivered is a therapeutic device that has the potential for providing multiple severe emphysema treatment approaches. AeriSeal foam has been shown to significantly improve lung function and quality of life in patients with advanced emphysema.<sup>5-8</sup> The foam functions by blocking both small airways and collateral channels causing absorption atelectasis in the treated regions resulting in reduction of hyperinflation.<sup>5</sup> The ASPIRE study, which was discontinued for non-regulatory reasons, showed clinically meaningful and statistically significant improvements in lung function, exercise capacity and quality of life at 6-months post-treatment compared to the standard-of-care control group; however, the overall incidence of adverse events in the AeriSeal treated patients was also prominent.<sup>5</sup> The crosslinking of AeriSeal foam to surrounding tissue yields a subacute inflammation that is hypothesized to be a function of the volume of AeriSeal delivered.<sup>5</sup> Most patients have historically been treated with a fixed volume of 20 mL foam in each target subsegment (80 mL in total). The current study was designed to evaluate the short-term and long-term safety and mode of action of a modified staged treatment algorithm with an escalation of volume of AeriSeal foam. Specifically, it assessed whether lowering the volume of tissue treated in a single session combined with a staged treatment has an impact on the intensity of the inflammatory response and associated adverse events.

## METHODS

This was a prospective multicenter (4 centers) study (STAGE trial NCT02877459) that included patients with emphysema and hyperinflation (Residual Volume >175% of predicted). The primary treatment targets were regions with the highest emphysema destruction scores and lowest perfusion. Emphysema scores on a segmental level were based on quantitative CT-scan analysis by the StratX<sup>®</sup> platform (Pulmonx Inc, Redwood City, CA, USA), perfusion was measured with perfusion scintigraphy. Treatment with AeriSeal foam was staged i.e., the desired amount of AeriSeal was delivered over 2 treatment session separated by at least 8 weeks. During the first treatment with AeriSeal, two non-adjacent subsegments in one lobe were treated with 5 mL of AeriSeal each (total volume of 10 mL for the lobe). During the second treatment, approximately 2 months after the first treatment, 2 non-adjacent subsegments in a contralateral lobe were treated with 10 mL of AeriSeal each (total volume of 20 mL for the lobe). An HRCT scan was acquired after three months to determine target lobar volume reduction (TLVR). Lung function, exercise capacity, quality of life, and solicitation of

adverse events were evaluated up to 12-months after the second treatment. Results A total of 14 patients (36% male, mean age  $64 \pm 6.2$  years; mean FEV1  $28.4\% \pm 6.7\%$  of predicted; RV  $237\% \pm 54\%$  of predicted) were enrolled. Ten completed both treatments, four completed the first treatment. The patients not receiving the second treatment experienced a serious adverse event (SAE) after the first treatment and either did not want to have the second treatment ( $n = 1$ ) or the Investigator decided not to continue ( $n = 3$ ). AeriSeal treatment resulted in significant TLVR at 3 months follow up. The median TLVR was 111 mL (range  $-39$  to  $-280$ ) ( $p = 0.005$ ) after the first treatment with AeriSeal with  $2 \times 5$  mL and 117.5 mL (range 1 to  $-651$ ) ( $p = 0.002$ ), after the second treatment with  $2 \times 10$  mL (Table 1). For the patients who received both treatments, median TLVR was 220.5 mL (range  $-38$  to  $-775$ ). There were no significant changes from baseline at 12 months in lung function, exercise capacity and quality of life (Table 2). During the 3-month post-treatment period, respiratory SAEs included 5 COPD exacerbations in 4 (28.6%) subjects, post-treatment acute inflammatory response (PAIR) in 2 (14.3%) subjects, and 1 respiratory failure event in 1 (7.1%) subject. No patients experienced a pneumothorax. All but one event occurred after the first treatment. Between 3 months and 12 months after the last treatment, there were a total of 5 respiratory SAEs with 3 COPD exacerbations in 3 (21.4%) subjects, formation of a lung cavity in 1 (7.1%) subject and hypercapnia in 1 (7.1%) subject. Three of these events were deemed as “not related” to the device, one COPD exacerbation was “possible”, and the lung cavity was “probable” for relatedness to the device. There were no device-related or procedure-related deaths during the course of the study.

## DISCUSSION

Our data shows that AeriSeal treatment produces a dose dependent reduction in hyperinflation of the treated areas in the lung with a 10 mL dose causing a lobar volume reduction of approximately 100 mL. Because the administered doses of AeriSeal were rather small compared to the previously used volumes, the overall changes in TLVR were not large enough to have an impact on any clinical outcome measure. Our data suggest that a larger volume of AeriSeal would be required to achieve a meaningful target lobar volume reduction and associated clinical benefit.<sup>5</sup> The frequency of observed SAEs in this study were comparable to what had been previously observed. COPD exacerbations were seen in 15–40% compared to 42% in this present study, pneumonia was reported between 6 and 24% compared to 0% and PAIR 8.5% compared to 14%.<sup>5-8</sup> Most of the SAEs in this study occurred after the first treatment ( $2 \times 5$  mL administration AeriSeal). These data suggest that changing the treatment algorithm to a lower dose or 2 treatment sessions may not change the safety profile from what has been previously reported. The overall incidence of SAEs seen in this study and ASPIRE is not different from the rate of SAEs seen for the endobronchial valves or vapor.<sup>5,9</sup> An alternative treatment approach using AeriSeal is currently being evaluated in patients who are not eligible for valve treatment due to the presence of collateral ventilation with small fissure gaps. A small dose of AeriSeal (up to 40 mL) is administered in subsegments

feeding the defined fissure gap to close the airway and block the collateral ventilation to potentially make these patients eligible for valve treatment (NCT04559464).

In conclusion, the staged administration of AeriSeal does not impact the overall safety profile in terms of reducing the type and frequency of respiratory SAEs previously reported for a single-stage treatment. Based on the observed decrease in CT derived hyperinflation, there is a dose-dependent effect of AeriSeal, with a larger volume of AeriSeal than used in this study may be necessary to provide meaningful clinical benefits.

**Table 1** - Baseline characteristics.

Gender	5 Males (36%) 9 Females (64%)
Age (years)	64.3 ± 6.2
BMI (kg/m <sup>2</sup> )	23.7 ± 4.5
Pack Years	37.5 ± 10.4
FEV <sub>1</sub> (%pred)	28.4 ± 6.7
RV (%pred)	237 ± 54
RV/TLC (%)	64.9 ± 7.3
DL <sub>CO</sub> (% predicted)	31.1 ± 7.0
6MWD (m)	312 ± 54
SGRQ Total score ‡	57.5 ± 13.2
mMRC Dyspnea Score §	2.8 ± 0.6

Values are means ± SD; ‡ St. George's Respiratory Questionnaire (SGRQ) scores range from 0 to 100, with higher scores indicating worse quality of life. § Modified Medical Research Council dyspnea (mMRC) scores scale ranges from 0 to 4, with higher scores indicating more severe dyspnea.

**Abbreviations:** BMI = Body Mass Index; FEV<sub>1</sub> = Forced Expiratory Volume in 1 s; RV = Residual volume; FVC = Forced Vital Capacity; DL<sub>CO</sub> = Carbon monoxide diffusing capacity; 6MWD = six-minute walk test; SGRQ = St George's Respiratory Questionnaire; mMRC = Modified Medical Research Council Dyspnea Score.

**Table 2** - Treatment Results.

TREATMENT SITES		
Lobes Treated	Treatment #1 (n)	Treatment #2 (n)
Right Upper Lobe (RUL)	7	4
Right Lower Lobe (RLL)	0	1
Left Upper Lobe (LUL)	6	5
Left Lower Lobe (LLL)	1	0

CT RESULTS		
Target Lobe Volume Reduction <sup>#</sup>	Median (Min, Max)	P-value
First treatment (mL) (n=14)	111.0 (-39, 280)	0.005
Second treatment (mL) (n=10)	117.5 (1, 651)	0.002
Total TLVR (combined) (n=10)	220.5 (-38, 775)	0.004

EFFICACY		
Change from Baseline to 12 months follow up	Median (Min, Max) (n=10)	P-value
Percent FEV <sub>1</sub> (L)	-9.4 ( -20.6, 57.0)	0.083
Percent RV (L)	1.77 ( -22.0, 30.9)	0.492
6MWD (m)	34 ( -50, 136)	0.266
SGRQ (points)	2.4 ( -35.3, 12.3)	0.770
mMRC (points)	0 (-2, 1)	0.531

<sup>#</sup> Follow-up volume assessments performed 3-months after Treatment #2. Thus, the Treatment #1 follow-up volume is at 5 months post-Treatment #1. Total TLVR reflects a pooling of 5-month for first treated lobe and 3-months for the second treated lobe.

**Abbreviations:** FEV<sub>1</sub> = Forced Expiratory Volume in 1 s; RV = Residual volume; 6MWD = Six-minute walk test; SGRQ = St George's Respiratory Questionnaire; mMRC = Modified Medical Research Council Dyspnea Score; TLVR = target lobe volume reduction.

## REFERENCES

- 1 G.J. Criner, et al., A multicenter randomized controlled trial of zephyr endobronchial valve treatment in heterogeneous emphysema (LIBERATE), *Am. J. Respir. Crit. Care Med.* 198 (9) (2018) 1151–1164.
- 2 K. Klooster, et al., Endobronchial valves for emphysema without interlobar collateral ventilation, *N. Engl. J. Med.* 373 (24) (2015) 2325–2335.
- 3 A. Valipour, et al., Endobronchial valve therapy in patients with homogeneous emphysema. Results from the IMPACT study, *Am. J. Respir. Crit. Care Med.* 194 (9) (2016) 1073–1082.
- 4 F.J. Herth, et al., Radiological and clinical outcomes of using Chartist to plan endobronchial valve treatment, *Eur. Respir. J.* 41 (2) (2013) 302–308.
- 5 C.E. Come, et al., A randomised trial of lung sealant versus medical therapy for advanced emphysema, *Eur. Respir. J.* 46 (3) (2015) 651–662.
- 6 F.J. Herth, et al., Treatment of advanced emphysema with emphysematous lung sealant (AeriSeal(R)), *Respiration* 82 (1) (2011) 36–45.
- 7 M.R. Kramer, et al., Bilateral endoscopic sealant lung volume reduction therapy for advanced emphysema, *Chest* 142 (5) (2012) 1111–1117.
- 8 Y. Refaely, et al., Biologic lung volume reduction therapy for advanced homogeneous emphysema, *Eur. Respir. J.* 36 (1) (2010) 20–27.
- 9 G. Snell, et al., Bronchoscopic thermal vapour ablation therapy in the management of heterogeneous emphysema, *Eur. Respir. J.* 39 (6) (2012) 1326–1333.

12



# CHAPTER 12

## Summary







The main aim of this thesis was to improve the clinical use of the quantitative CT-scan analysis, the Chartis measurement of collateral ventilation in patient selection for treatment with one-way valves and to provide insight regarding the management of complications after treatment with valves.

The studies that are part of this thesis are summarized below.

In **chapter 2**, we performed a review and update of the current bronchoscopic lung volume reduction options for severe emphysema patients and describe important aspects regarding optimal patient selection. Currently, the treatment with one-way valves is the most important treatment option and significantly improves lung function, exercise capacity and quality of life. Also, there is growing evidence that this treatment can be effective in patients who were excluded from earlier randomized controlled trials, for example patients with a very low diffusing capacity or hypercapnia can be also suitable candidates for treatment. Treatment with endobronchial coils, thermal vapor ablation and sclerosant agents can also improve patient outcomes. To select the optimal treatment option, careful phenotyping is essential, including the emphysema phenotype, amount of emphysema and fissure integrity.

The goal of the treatment with valves is to induce a complete lobar atelectasis. In a significant proportion of patients, this atelectasis cannot be achieved due to interlobar collateral ventilation. The fissure integrity has a central role in the treatment with one-way valves, as collateral ventilation between lobes is generated through incomplete lobar fissures. Incomplete fissures are very common (to up to 90 percent of the population). There are several methods of measuring or predicting the presence of collateral ventilation, with computed tomography (CT) analysis and the Chartis measurement being the most important. In **chapter 3**, we provide an in-depth view of lung fissures and the concept of intra- and interlobar collateral ventilation to help understand its importance in selecting the appropriate patients for new emphysema treatments and its role in predicting collateral ventilation.

In chapter 4 and 5, we evaluated the predictive value of the fissure completeness score for the presence of collateral ventilation. In **chapter 4**, we performed a retrospective study to evaluate the diagnostic value of the combination of fissure completeness score (FCS) with quantitative CT-scan (QCT) analysis and the Chartis assessment during bronchoscopy. CT data from four prospective studies were pooled and analyzed using semiautomated software to quantify the completeness of interlobar fissures. These scores were compared to a reference standard of achieving  $\geq 350$  ml of target lobe volume reduction after EBV treatment. A fissure was defined as complete (FCS  $>95\%$ ), incomplete (FCS  $<80\%$ ), or partially complete ( $80\% < \text{FCS} < 95\%$ ). Using a receiver operating characteristic curve, optimal thresholds predictive of complete fissures (responders) and incomplete fissures (non-responders) were determined. A subgroup of patients with partially complete fissures was identified, where software had lower accuracy. The complementary value of Chartis was investigated in this group. The positive predictive value (PPV) of complete fissures on CT is 88.1%, and the negative predictive value

(NPV) is 92.9%, with an overall accuracy of 89.2%. Chartis was utilized in patients with partially complete fissures, with a PPV of 82.3%, an NPV of 84.6%, and an accuracy of 83.3%. In conclusion, combining diagnostic tools provides clinicians with a better means for patient selection for EBV therapy.

As addition to chapter 4, we performed a multi-center study in **chapter 5**, in which we aimed to evaluate the predictive value of the FCS for the presence of collateral ventilation compared to the Chartis assessment. The FCS was calculated by QCT and compared to the status of interlobar collateral ventilation measured with the Chartis system. We found that an FCS >95% of the left major fissure had a PPV of 91%, with 1 in 11 fissures demonstrating collateral ventilation with Chartis measurement, whereas an FCS of  $\leq 80\%$  had an NPV of 100% for the presence of collateral ventilation. For the right major fissure, the NPV was 100% for an FCS  $\leq 90\%$ , but 69.7% for the right upper lobe fissure. We recommend that QCT should be implemented in all patients evaluated for endobronchial valves. Patients with incomplete fissures (left major fissure: FCS <80%; right major fissure: <90%) can be excluded from Chartis measurement and endobronchial valve treatment. In patients with more complete fissures, the FCS is not specific enough for endobronchial valve treatment decisions. In this case, additional Chartis measurements are always recommended in the right lung. For the left lung, Chartis assessments may be omitted if the FCS is >95%.

The Chartis assessment is a very important tool in determining the presence of collateral ventilation and treatment with valves is based on the outcome of this measurement. In **chapter 6**, we aimed to evaluate a new feature and determine whether low flow during a Chartis measurement is predictive for the absence of collateral ventilation, and whether this allows for a procedure to be shortened by terminating the Chartis measurement earlier. This is measured with the “volume trend for the previous 20 seconds” (VT20). We retrospectively evaluated 249 Chartis assessments of patients scheduled for bronchoscopic lung volume reduction procedures. The VT20 was calculated, and several thresholds were compared between patients with collateral ventilation (CV positive) and without collateral ventilation (CV negative). We found that 100% of the CV negative patients reached a threshold of VT20  $\leq 6$  mL, whereas all CV positive patients reached a VT20  $\geq 7$  mL. The median “time saved” between VT20 =6 mL and end of assessment was 60 seconds (range 5-354 seconds). We concluded that the threshold of VT20  $\leq 6$  mL is a reliable method to exclude the presence of collateral ventilation when air flow rates are low. Currently, this feature is implemented in the Chartis system software worldwide.

The Chartis assessment may be challenging and an adequate measurement is essential for the treatment decision. However, especially in lower lobe measurements, Chartis can be challenging due to the “no-flow phenomenon”, which means there is no flow from the start of the measurement or a sudden cessation of flow during the measurement, leading

to an unreliable measurement. If this occurs in the right lower lobe, a solution is to occlude the entrance of the right middle lobe and perform the Chartis measurement in the right upper lobe. In **chapter 7**, we performed a retrospective analysis of 15 patients with severe emphysema (median FEV<sub>1</sub> 24% [range 19-36] of predicted) and demonstrated that temporary middle lobe occlusion using a blocking device is helpful in obtaining a reliable Chartis outcome in case of a right lower lobe no-flow phenomenon.

An additional tool for target lobe selection for lung volume reduction treatment is assessment of the perfusion per lung or per lobe with perfusion scintigraphy or single photon-emission computed tomography (SPECT-CT). Currently, perfusion scintigraphy is performed as an additional test to the already performed HRCT. For **Chapter 8**, we compared pulmonary perfusion approximated from an HRCT scan using artificial intelligence based quantitative CT analysis (PXT) to nuclear perfusion scintigraphy and SPECT-CT. In this study we compared the PXT to perfusion scintigraphy for left and right lung perfusion in 207 patient and to SPECT-CT for comparison on a lobar level in 85 patients. We found a very high intraclass correlation coefficient for both groups with small differences. We concluded that pulmonary perfusion can be estimated by HRCT-based artificial intelligence approximation with high accuracy. This can prevent additional examinations and costs beyond CT to quantify pulmonary perfusion.

After treatment with valves, careful monitoring and follow up is important to monitor for treatment effect and possible complications or side-effects of the treatment. In **chapter 9**, we aimed to summarize and review the complications after treatment with valves and its management. The main complications are pneumothorax (4-26%), post-obstruction pneumonia (1-4%) and hemoptysis (1-6%). Another challenge during follow up after treatment is when there is no initial benefit due to the presence of collateral ventilation or misplaced valves. Furthermore, an initial beneficial effect may vanish due to granulation tissue formation, valve dysfunction or valve migration. Evaluation with a CT-scan and/or bronchoscopy is needed if there is no improvement after treatment, loss of benefit, or occurrence of important adverse events during follow-up.

In **chapter 10**, we describe an interventional pulmonology solution of symptomatic airway kinking after bronchoscopic lung volume reduction with endobronchial valves. Owing to the development of the desired lobar atelectasis, the position of the airways of the nontreated lobe changes, and this occasionally leads to invalidating symptoms. We present a case of a patient with symptomatic airway kinking after treatment with endobronchial valves of the left upper lobe who was successfully treated with a single placement of a biodegradable stent in the left lower lobe bronchus. Placement of a biodegradable stent can be considered for symptomatic patients with airway kinking.

In **chapter 11**, we describe an alternative treatment for patients who are not eligible for treatment with valves. Treatment with a sclerosant agent (AeriSeal) is an option to achieve lung volume reduction and we performed a prospective, multicenter feasibility study to assess the safety and mode of action of a modified treatment algorithm with a staged treatment with lower dose of AeriSeal. AeriSeal was administered during two sequential bronchoscopies: 2 subsegments of a lobe treated with two 5 mL doses, followed by two 10 mL doses in a contralateral lobe after 6 weeks. A total of 14 patients (36% male, mean FEV<sub>1</sub> 28.4% ± 6.7% of predicted) were enrolled. AeriSeal treatment resulted in significant target lobe volume reduction (median 220.5 mL) at 3 months follow up. There were no significant changes from baseline at 12 months in lung function, exercise capacity and quality of life. The staged and lower dosed administration of AeriSeal does not impact the overall safety profile in terms of reducing the type and frequency of respiratory SAEs previously reported for a single-staged treatment.



13



# CHAPTER 13

## **General discussion and future perspective**







## IMPROVING COPD PATIENT CARE

In this thesis we set out and achieved to further improve both patient and target lobe selection for bronchoscopic lung volume reduction in severe emphysema patients. During the process of actually selecting hundreds and hundreds of patients it became apparent that patients with severe COPD have many more potential treatable traits than LVR options only. COPD is a highly prevalent disease and many patients experience severe dyspnea, fatigue, impaired exercise capacity and reduced quality of life. Treatment options have been limited for a long period of time. Pulmonary rehabilitation, chronic non-invasive ventilation and lung transplantation have been important treatment options in patients with severe COPD, and over recent years, additional lung volume reduction treatment options have become available for the predominant emphysematous phenotypes. In 2017, bronchoscopic lung volume reduction treatment with one-way endobronchial valves became a treatment recommended in the guideline and reimbursed in our country.

It is important to realize that COPD is a heterogeneous disease and patients should receive personalized care. Treatment with valves is an important additional treatment option for carefully selected patients, but unfortunately in most patients, this is not a treatment option. The main challenge for physicians who treat patients with severe COPD is to evaluate treatable traits and optimize personalized treatment. Both standard and specialized third-line treatments for COPD can be optimized in these patients. For example, in our severe COPD service we perform second opinions for patients with severe COPD to evaluate whether there are additional (third-line treatment) options (third-line pulmonary rehabilitation, lung transplantation, non-invasive ventilation and bronchoscopic interventions). An analysis of the 152 patients who visited our severe COPD service between September 2018 and March 2022 showed that additional treatment options were advised in 91% of the patients, including one or more of the third-line options, but also many other (non) pharmacological options (unpublished data).

Therefore, general evaluation in patients with uncontrolled or severe COPD should be more standardized and more attention should be paid to personalized treatment and treatable traits (for example co-morbidities, nutritional state, physical activity, smoking and inhalation technique).

Furthermore, there should be more focus on palliative care for patients with COPD. Compared to advanced lung cancer, the symptoms in patients with COPD are at least comparable or even significantly worse for breathlessness and health related quality of life.<sup>1</sup> Interestingly, the access and attention for specialist treatments and palliative care in COPD is very limited compared to patients with lung cancer, who receive substantially more formal palliative care services and medication for symptom management.<sup>1,2</sup>

To facilitate the necessary improvement of the quality of care for patients with severe or uncontrolled COPD, additional analysis should be initiated (e.g. HRCT, lung function) and discussed in a team with physicians who have COPD expertise to check for treatable traits, improvement of pharmacological therapy and possible referral to a specialized center.

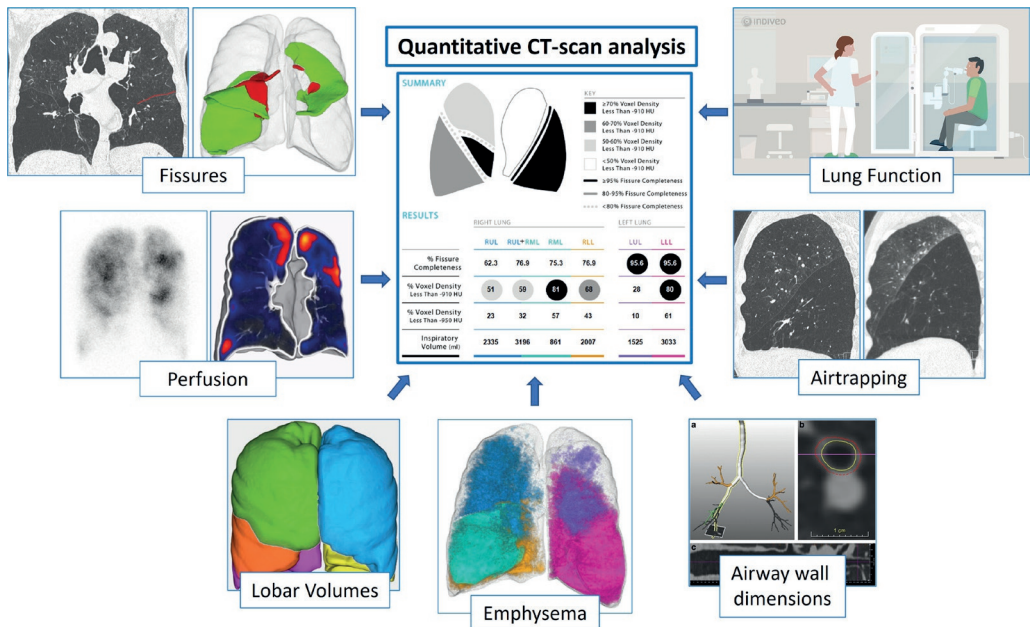
Preferably, in case third-line treatment options are being considered, patients should be discussed in multidisciplinary team meetings, involving physicians with expertise in non-invasive ventilation, bronchoscopic interventions, pulmonary rehabilitation and lung transplantation. In contrast to the situation in COPD care, multidisciplinary team meetings are already incorporated and well appreciated in our other lung diseases (lung cancer, interstitial lung disease, asthma). Multidisciplinary team meetings are essential to determine the best treatment options. For example, in some patients, there are multiple treatment options including lung transplantation and lung volume reduction therapy. In this case, it is important to discuss these patients, to determine the best treatment regime and timing of treatment. The importance, added value and implementation of multidisciplinary team meetings have been described in several papers already.<sup>3-5</sup> Relevant questions are whether bronchoscopic lung volume reduction can be used as 'bridge to transplant', if lung volume reduction surgery is a contraindication for future lung transplantation, or if pulmonary rehabilitation should be initiated before or combined with other treatment options. It is also important to involve patients in these important decisions.

## **IMPROVING DIAGNOSTICS AND PATIENT SELECTION**

Of the above third-line treatment options, this thesis mainly focuses on lung volume reduction therapy with endobronchial valves, especially aiming to improve patient selection and optimize the use of quantitative CT-scan analysis and other diagnostic tools. For treatment with valves, optimal patient selection is crucial. If based on the pulmonary function test a patient seems eligible for treatment with endobronchial valves, the CT-scan is the most important tool to check for emphysematous destruction, a suitable treatment target lobe, fissure completeness, lobar volumes and lobar perfusion. However, visual interpretation of the CT-scan can be challenging and the interobserver variability is rather high, for which the QCT provides better and more accurate data.<sup>6</sup>

Quantitative CT-scan analysis is essential in optimal patient selection, both to improve patient selection and target lobe selection, and to be able to predict response. Hence an important goal of this thesis was to improve the use of quantitative CT-scan analysis in patient selection for treatment with valves.

The most used QCT platform in valve treatment is the StratX lung report (PulmonX Inc., CA, USA). Currently, the StratX lung report provides the fissure completeness, emphysema density and inspiratory volumes and the number of measured and analyzed parameters is increasing (**Figure 1**).



**Figure 1** - Several outcome measures that are or can be incorporated into the Quantitative CT-scan analysis or StratX report (adapted from the StratX platform, PulmonX Inc., CA, USA).

Currently, the StratX report provides information regarding the fissure completeness, emphysema density at -910 and -950 HU and lobar volumes. For the future we aim to include the perfusion into this report (Chapter 8). There are several other possible parameters that can be incorporated (e.g. lung function, airtrapping, airway wall dimensions).

Ideally, the treatment target lobe is the lobe with most destruction as assessed by emphysema density. Treatment of this lobe with valves will only be successful if there is no collateral ventilation between this lobe and the adjacent lobe(s). The presence or absence of collateral ventilation can be evaluated with a Chartis measurement during bronchoscopy but can be predicted based on the fissure completeness score on the HRCT. In **chapter 3** we explained the concept of collateral ventilation and the importance of the fissure for this treatment. In **chapter 4** and **chapter 5**, we evaluated the predictive value for the fissure completeness score and how to combine this with the Chartis measurement during the bronchoscopy and these results have been incorporated into the StratX platform. By using the fissure completeness score as predictor for the presence or absence of collateral ventilation, we aim to minimize the number of patients that receive unnecessary bronchoscopies and general anaesthesia, but cannot be treated with valves due to collateral ventilation.

For the future, the use of quantitative CT-scan analyses can be expanded. As addition to the fissure completeness score, emphysema density and volumes, additional parameters could be integrated to help to select the optimal treatment target lobe, to prevent additional diagnostic tests and to predict and evaluate response (**Figure 1**).

An important feature is the integration of the perfusion on a lobar level. Currently, perfusion is measured frequently as an additional test by using nuclear perfusion scintigraphy, nuclear SPECT/CT or contrast enhanced dual energy CT, to help select the treatment target lobe. In **chapter 8**, we describe that perfusion on a lobar level can also be extracted from the HRCT and this perfusion report can be incorporated in the StratX platform and safe additional investigations, provided that future research shows that there is no difference in target lobe selection with either use of SPECT or QCT.

Furthermore, we hope to incorporate other outcomes of the CT-scan to the QCT report. This includes the expiration scan to be able to measure the air trapping in individual lobes and to estimate the lung function (especially body plethysmography-derived volumes, including residual volume).<sup>7</sup> This will hopefully reduce the use of body plethysmography and associated patient effort and costs in the future. Additionally, airway wall dimensions (e.g. airway wall thickness and airway lumen) may be used to estimate the severity of airway disease and probably as a predictor for response or side effects (such as coughing, mucus production or exacerbations).

Hopefully, improving the quantitative CT-scan analysis with incorporation of all these factors will result in better patient selection, prediction of outcome and management of expectations for the patient. Furthermore, this can lead to more efficient diagnostics and accommodate screening for treatment options, with less additional investigations and less radiation exposure.

After a patient has been selected for treatment, in most the presence or absence of collateral ventilation is confirmed using the Chartis assessment. However, this measurement can be challenging and therefore, the number of false negative and false positive measurements should be minimized. A false CV-negative measurement will lead to treatment with probably no effect and a treatment with possible side effects could have been avoided. A false CV-positive measurement will lead to no treatment in a patient that could have beneficial effect. In **chapter 6** and **chapter 7** we described new methods to optimize the Chartis measurement. Based on **chapter 6**, the use of the VT20 tool is already incorporated into the Chartis console used worldwide.

## HANDLING OF COMPLICATIONS OF VALVE TREATMENT

As shown in **chapter 10**, the treatment with valves is not without side effects. Currently, approximately 40% of the treated patients need a revision bronchoscopy during their follow-up, mainly due to the fact that they have loss of initial achieved lung volume reduction.<sup>8</sup>

One of the main problems during follow up is the formation of granulation tissue. This can lead to valve dysfunction and loss of the initial effect. Furthermore, granulation tissue formation can lead to cough and hemoptysis. Formation of granulation tissue is a well-known problem in devices that are implanted in lungs, but the exact pathophysiology is not yet clear.<sup>9</sup> For the future, it is important to try to understand and prevent the formation of granulation tissue. This is relevant for all devices that are used in the lungs (e.g. valves and other devices for lung volume reduction, airway stents for patients with airway stenosis or severe airway collapse). Currently, the Biological Investigation of Explanted Endobronchial Lung Valves Study (Bio-EXCEL) is investigating the biological principles of granulation and fibrotic responses after treatment with valves (NCT04214587).

For patients who need airway stents, the use of biodegradable stents (described in **chapter 10**) seems promising compared to regular metallic stents, because our experience is that there are less complications like granulation tissue formation or infections, for which additional bronchoscopies are needed. Therefore, the use of biodegradable stents might even lead to less bronchoscopies, even though the biodegradable stents need to be replaced every 3-4 months. This is also subject of further research.

## SEARCH FOR ALTERNATIVE TREATMENTS

For the specific COPD patient group with severe hyperinflation and severe emphysema, an important treatment option is lung volume reduction. In many patients, improving hyperinflation, independent of the type of intervention, will result in better lung function, exercise tolerance and quality of life.<sup>10</sup> Unfortunately, current treatment options are limited and may not be suitable for most patients.

Currently, the most important treatment option is treatment with one-way valves. However, this treatment is not suitable for most patients (e.g. due to collateral ventilation or phenotype of emphysema).

Therefore, it is important to find and improve alternative treatment options that are effective and suitable for more patients. We know that there are many patients who would benefit from reducing hyperinflation but cannot yet be treated. Our goal is to expand the number of treatments, so that several phenotypes of emphysema can be treated (**Figure 2**). For the (near) future, there are three main objectives that could make treatment possible in more patients: 1) conversion of collateral ventilation status by closing the collateral air flow and make patients eligible for valves; 2) development of a new device to treat patients with collateral ventilation; 3) improvement of surgical treatment options.

### **1. Conversion of collateral ventilation status**

In patients with collateral ventilation, who cannot be treated with valves, several options are being explored to make them eligible for treatment with valves. One option currently under investigation is the endobronchial administration of AeriSeal foam in the region of the fissure defect. As we describe in **chapter 11**, the administration of AeriSeal is a treatment option for lung volume reduction, but for significant lung volume reduction, a larger volume is needed, with subsequent side-effects. A smaller dose does not impact the overall safety profile in terms of type and frequency of respiratory adverse events, but the inflammatory reaction is evidently less compared to the high dose. Although a smaller dose gave no clinically relevant effect, this smaller dose can be enough to cover the full region of a small fissure defect. The goal of administration of this foam and the subsequent inflammatory reaction is to occlude the collateral channels in the region of the fissure defect, thereby blocking the collateral ventilation between the lobes and make subsequent treatment with valves possible. This combined treatment modality has been shown successful in a study where 14 patients with a small fissure defect of the left major fissure were treated and there was conversion of collateral ventilation status in 9 patients (64%).<sup>11</sup> Currently, this is also under investigation in a large multicenter study (CONVERT trial, NCT04559464).

### **2. Alternative, non-blocking treatments**

If patients are not eligible for treatment with valves due to the distribution of emphysema or incomplete fissures and collateral ventilation, there are several other bronchoscopic treatment options that can be considered.

An alternative treatment, also part of the international COPD GOLD Guidelines, is the treatment with endobronchial coils, as described in **chapter 2**. Treatment with coils has been shown to improve lung function, quality of life and exercise tolerance in patients with severe COPD.<sup>12</sup> However, the production of the PneumRX endobronchial coils has been terminated due to a business decision. Therefore, other types of coils are currently being investigated (NCT04520152, NCT03685526).

Another option for reducing hyperinflation is to create alternative airways or support existing airways. The goal of this therapy is to allow air to escape through a device that prevents the airway from collapsing, or by making an actual airway bypass in the airways. This concept has been previously investigated in the EASE trial.<sup>13</sup> In this randomized, double-blind, sham controlled trial, multiple passages were created and up to six stents were placed in the airways. This procedure was tolerated well in the severe COPD population, and in the short term this resulted in an important improvement of lung function. However, due to stent occlusion and dysfunction during follow up, there was no sustained effect. Nevertheless, the concept is really strong and this treatment could be effective in a large patient group. The main challenge for this kind of treatment is to improve the durability of the device patencies. Currently, the Pulmair Implantable Artificial Bronchus (IAB, Pulmair Medical, CA, USA) is under

investigation (NCT05087641). This is a device that is implanted in the airways to prevent airway collapse. For the future we hope to investigate this concept with several devices and also to improve the actual airway bypass option.

Another possible option to reduce hyperinflation is the use of sclerosing and blocking agents. The goal of this treatment is to create lung volume reduction due to a localized inflammatory response and blocking the collateral airway channels of the treated, most emphysematous areas. Currently, use of vapour (steam)<sup>14</sup> and AeriSea<sup>15,16</sup> are possible options. Although these treatment options have the potential to improve clinical outcomes, the outcome is relatively unpredictable and severe side effects have been reported (e.g. pneumonitis, acute inflammatory response, and in the longer term recurrent infections or bronchiectasis) which prevent these treatments from being performed routinely. For this treatment, the use of a biocompatible adhesives that block the collateral channels resulting in resorption atelectasis, but without the acute inflammatory response and infectious side effects, would be interesting to investigate further. The development of biocompatible adhesives will be challenging. Important aspects for the development of biocompatible adhesives include that it should be non-degradable because this can lead to diminishing lung volume reduction over time, have no systemic side effects and be without an important immune response.<sup>17</sup>

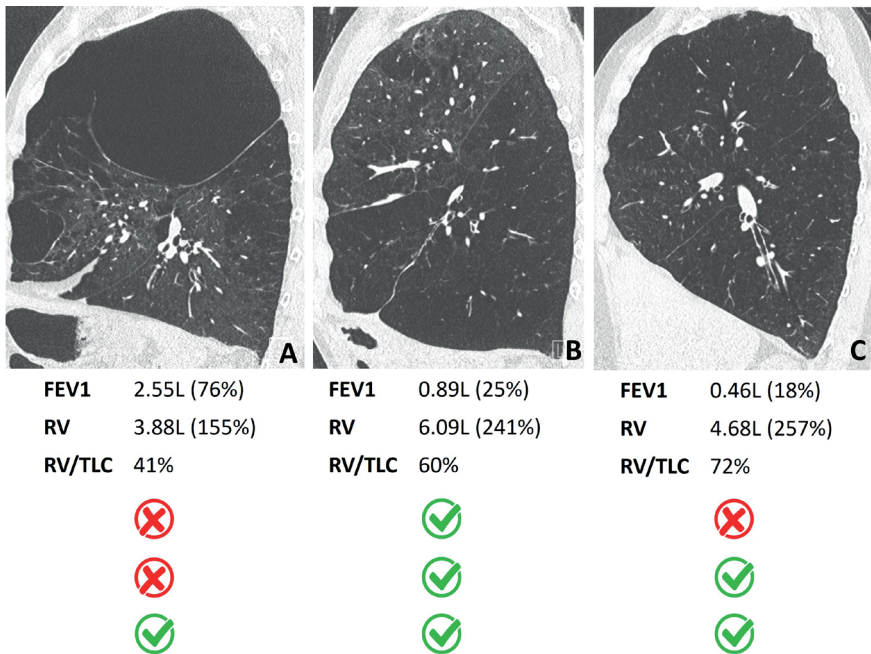
Biocompatible adhesives can be used for primary lung volume reduction, but another application is to use this to close fissure defects instead of AeriSeal as described before. Currently, after treatment with AeriSeal, the bronchoscopy has to be repeated after approximately 6 weeks when the inflammatory reaction is extinguished. If during the follow-up bronchoscopy there is still collateral ventilation, the treatment can be repeated, but then yet another bronchoscopy is needed after six weeks to see if there is conversion and if a patient can be treated. An advantage of using biocompatible adhesive is that the conversion of the collateral ventilation can be measured directly and if necessary, an extra dose can be administered or patients can be treated with valves directly. This would save potentially severe inflammatory reactions and subsequent bronchoscopies with uncertain outcome whether the collateral ventilation has been blocked.

Finally, lung volume reduction surgery (LVRS) can be very effective in patients with severe emphysema. The multicenter National Emphysema Treatment Trial (NETT) compared lung volume reduction surgery to standard medical care and demonstrated improvement of lung function and exercise in specific patients.<sup>18</sup> Due to perceived high risk of LVRS (prolonged air leak, pneumonia and reoperations), this treatment is not performed often and it requires a highly specialized team and equipment. However, surgery can be very effective. Currently this treatment is being compared to treatment with valves in the SINCERE-trial (ClinicalTrials.gov Identifier: NCT04537182). The recently published CELEB trial showed in an RCT that bronchoscopic lung volume reduction and LVRS were comparable in patients that were suitable for both treatments, indicating that LVRS is also effective in patients who technically cannot be treated with valves.<sup>19</sup>



The indication for lung volume reduction surgery is partly comparable to the treatment with valves, but an even stronger indication is the paraseptal emphysema type (Figure 2), that is ineligible for valve treatment and other bronchoscopic treatments.

For the future we should focus on further development of lung volume reduction surgery, as the capacity and knowledge for lung volume reduction surgery in patients with severe COPD in the Netherlands (and worldwide) is relatively scarce. If there is focus from a dedicated multidisciplinary team experienced in severe COPD (surgeon, anesthesiologist and pulmonologist) for adequate patient selection, this should result in a larger group of patients that can be treated with a significant and clinically relevant treatment effect.



**Figure 2** - Several phenotypes of emphysema with sagittal view of the CT-scan and lung function parameters. A. Patient with severe paraseptal emphysema of the left upper lobe and moderate hyperinflation. The most suitable treatment option for this paraseptal emphysema phenotype is lung volume reduction surgery. In this case, the fissure completeness score is not important. B. Severe hyperinflation with emphysema mainly in the left lower lobe (destruction of 56% compared to 23% of the left upper lobe) and a complete left major fissure (FCS=100%). This is a phenotype that can be treated with valves, but can also be suitable for surgery or other non-blocking techniques (e.g. airway bypass) in the future. C. Patient with severe hyperinflation and relatively homogeneous emphysema (destruction of 38% in the left upper lobe and 36% in the left lower lobe) with an incomplete fissure (FCS=80%). This patient cannot be treated with valves, but might be eligible for treatment with surgery or non-blocking techniques. However, currently the treatment options are limited for this phenotype.

**Abbreviations:** FEV<sub>1</sub>: Forced Expiratory Volume in one second. RV: Residual Volume. TLC: Total Lung Capacity. FCS: fissure completeness score.

## CONCLUSION

We have been able to optimize the use of quantitative CT-scan analysis in severe COPD patients, especially the use of the fissure completeness score, to help select the optimal patients and the possible treatment target lobes for bronchoscopic lung volume reduction with valves, with additional use of the approximated perfusion from the CT-scan.

If patients can be treated with valves, the most important side effect is the formation of granulation tissue, which we hope to understand better in the future.

There is an urgent need for additional treatments in patients with severe emphysema and hyperinflation, hopefully we will be able to contribute to new treatment modalities in the (near) future. The most promising treatment options include bronchoscopic treatment for patients with collateral ventilation (biocompatible adhesive, airway bypass) and improvement of the lung volume reduction surgery program.

**REFERENCES**

- 1 Butler, S.J., et al., Comparison of end-of-life care in people with chronic obstructive pulmonary disease or lung cancer: A systematic review. *Palliat Med*, 2020. 34(8): p. 1030-1043.
- 2 Bloom, C.I., et al., Low uptake of palliative care for COPD patients within primary care in the UK. *Eur Respir J*, 2018. 51(2).
- 3 Oey, I. and D. Waller, The role of the multidisciplinary emphysema team meeting in the provision of lung volume reduction. *J Thorac Dis*, 2018. 10(Suppl 23): p. S2824-S2829.
- 4 Dooms, C., et al., Lung volume reduction in emphysema: a pragmatic prospective cohort study. *ERJ Open Res*, 2021. 7(2).
- 5 Kouritas, V., et al., The Impact of a Newly Established Multidisciplinary Team on the Interventional Treatment of Patients With Emphysema. *Clin Med Insights Circ Respir Pulm Med*, 2019. 13: p. 1179548419852063.
- 6 Koster, T.D. and D.J. Slebos, The fissure: interlobar collateral ventilation and implications for endoscopic therapy in emphysema. *Int J Chron Obstruct Pulmon Dis*, 2016. 11: p. 765-73.
- 7 Bakker, J.T., et al., Evaluation of spirometry-gated computed tomography to measure lung volumes in emphysema patients. *ERJ Open Res*, 2022. 8(1).
- 8 Roodenburg, S.A., et al., Revision Bronchoscopy After Endobronchial Valve Treatment for Emphysema: Indications, Findings and Outcomes. *Int J Chron Obstruct Pulmon Dis*, 2021. 16: p. 1127-1136.
- 9 Roodenburg, S.A., S.D. Pouwels, and D.J. Slebos, Airway granulation response to lung-implantable medical devices: a concise overview. *Eur Respir Rev*, 2021. 30(161).
- 10 van Geffen, W.H., et al., Surgical and endoscopic interventions that reduce lung volume for emphysema: a systemic review and meta-analysis. *Lancet Respir Med*, 2019. 7(4): p. 313-324.
- 11 Ing, A.J., et al., Reversal of collateral ventilation using endoscopic polymer foam in COPD patients undergoing endoscopic lung volume reduction with endobronchial valves: A controlled parallel group trial. *Respirology*, 2022. 27(12): p. 1064-1072.
- 12 Roodenburg, S.A., et al., Bronchoscopic Lung Volume Reduction Coil Treatment for Severe Emphysema: A Systematic Review and Meta-Analysis of Individual Participant Data. *Respiration*, 2022. 101(7): p. 697-705.
- 13 Shah, P.L., et al., Bronchoscopic lung-volume reduction with Exhale airway stents for emphysema (EASE trial): randomised, sham-controlled, multicentre trial. *Lancet*, 2011. 378(9795): p. 997-1005.
- 14 Snell, G., et al., Bronchoscopic thermal vapour ablation therapy in the management of heterogeneous emphysema. *Eur Respir J*, 2012. 39(6): p. 1326-33.
- 15 Come, C.E., et al., A randomised trial of lung sealant versus medical therapy for advanced emphysema. *Eur Respir J*, 2015. 46(3): p. 651-62.
- 16 Koster, T.D., et al., A multicenter, prospective, single-arm clinical investigation of a modified staged treatment algorithm using the AeriSeal system - The STAGE trial. *Respir Med*, 2022. 203: p. 106989.
- 17 Joglekar, M.M., et al., Crosslink bio-adhesives for bronchoscopic lung volume reduction: current status and future direction. *Eur Respir Rev*, 2021. 30(162).
- 18 Fishman, A., et al., A randomized trial comparing lung-volume-reduction surgery with medical therapy for severe emphysema. *N Engl J Med*, 2003. 348(21): p. 2059-73.
- 19 Buttery, S.C., et al., Lung volume reduction surgery versus endobronchial valves: a randomised controlled trial. *Eur Respir J*, 2023.



A





# **Appendices**

**Nederlandse samenvatting**

**Dankwoord**

**Curriculum vitae**

**Publications**



## NEDERLANDSE SAMENVATTING

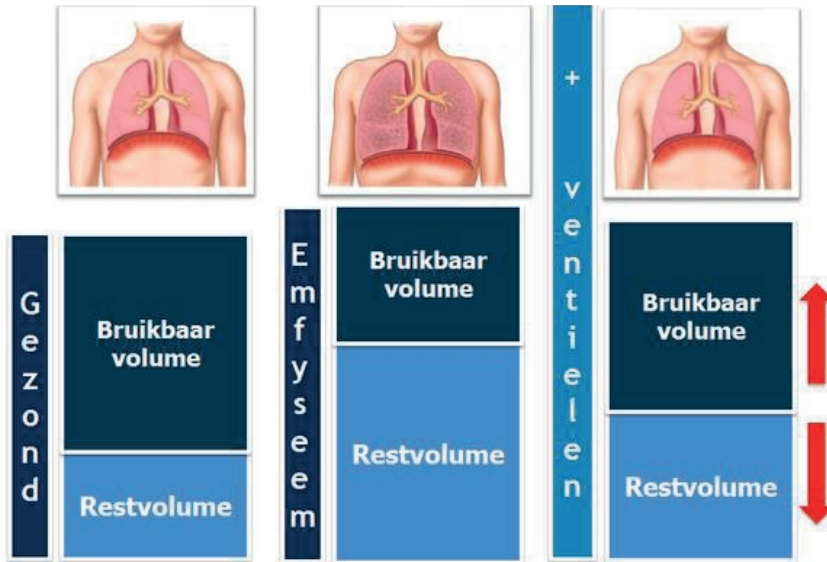
COPD (“chronic obstructive pulmonary disease”, oftewel “chronische obstructieve longziekte”) is een ziekte waarbij de longen beschadigd zijn. Hoewel de ziekte eigenlijk grotendeels te voorkomen is, is het wereldwijd de op twee na belangrijkste doodsoorzaak. Roken is de belangrijkste oorzaak van COPD, maar langdurige blootstelling aan andere schadelijke stoffen kunnen ook bijdragen aan de ontwikkeling van de ziekte, ook zijn er erfelijke factoren waardoor mensen meer aanleg hebben om COPD te ontwikkelen.

Bij COPD kan er sprake zijn van chronische bronchitis (o.a. luchtwegvernauwing en slijmproductie) en emfyseem (verlies van longblaasjes). Dit zorgt ervoor dat de longen hun elasticiteit verliezen en de luchtwegweerstand toe neemt. Daardoor wordt de ademhaling bemoeilijkt. Patiënten met COPD kunnen daardoor last hebben van kortademigheid (met name tijdens inspanning), hoesten en slijm opgeven, luchtweginfecties en vermoeidheid. Deze symptomen kunnen geleidelijk toenemen naarmate de ziekte erger wordt en ze kunnen uiteindelijk aanzienlijke beperkingen geven in het dagelijks leven van een patiënt.

COPD is een ongeneeslijke ziekte, de behandeling is erop gericht om de progressie te vertragen en de symptomen zoveel mogelijk te verlichten. Het meest belangrijk is om te stoppen met roken, daarnaast zijn er diverse medicamenteuze (o.a. inhalatiemedicatie) en niet-medicamenteuze opties (o.a. fysiotherapie) om patiënten zo goed mogelijk te begeleiden. COPD is een heel heterogene ziekte en het is eigenlijk een overkoepelende term voor verschillende klachten. Bij sommige patiënten staan veel hoestklachten met slijmproductie op de voorgrond, sommige patiënten hebben met name benauwdheid bij inspanning door emfyseem en andere patiënten hebben een chronisch zuurstoftekort waarvoor ze extra zuurstoftherapie nodig hebben. Omdat er zoveel verschil tussen patiënten zit, is de behandeling van COPD ook deels verschillend.

Bij een deel van de patiënten, met name bij meer ernstig COPD, is het totale longvolume toegenomen en is er sprake van hyperinflatie. Daarnaast kan er te veel lucht achter blijven in de long na uitademen. De lucht die achterblijft wordt het restvolume (of residuaal volume) genoemd. Bij patiënten met ernstig COPD en met name bij de patiënten die veel emfyseem hebben, kan dit restvolume heel erg hoog zijn, waardoor er nog maar weinig lucht over is om te gebruiken (zie **figuur 1**).





**Figuur 1** - Effect van ventielen op het restvolume. Ten opzichte van gezonde longen, geeft emfyseem een toename van het totale longvolume en het restvolume, waardoor er minder bruikbaar volume is. De behandeling met ventielen zorgt ervoor dat het restvolume kleiner wordt en er meer bruikbaar longvolume is.

Als er sprake is van een ernstig verhoogd restvolume en patiënten hierdoor beperkt worden, kan gekeken worden of er opties zijn om dit restvolume te verminderen. Dit kan middels longvolumereductiechirurgie, waarbij de meest zieke gedeeltes van de longen operatief verwijderd worden en de gezondere delen van de longen beter kunnen functioneren. Echter, dit is voor veel patiënten geen geschikte optie en daarnaast een belastende ingreep.

Daarom zijn er diverse bronchoscopische longvolumereductiebehandelingen ontwikkeld in de afgelopen twee decennia, die minder belastend zijn. Bij een bronchoscope wordt een bronchoscoop, een dunne en makkelijk buigzame slang met aan het uiteinde een camera, via de mond of neus in de luchtpijp ingebracht. Daarnaast is er een werkkanaal in de bronchoscoop, waardoor er een behandeling uitgevoerd kan worden. De belangrijkste bronchoscopische longvolumereductiebehandeling is een behandeling met eenrichtingsventielen. Deze behandeling is in verschillende studies onderzocht en is sinds 2017 ook een behandeling die vergoed wordt door de zorgverzekeraar.

Deze behandeling gebeurt onder narcose, waarbij de bronchoscoop via een beademingsbuisje naar binnen wordt gebracht. Bij deze behandeling wordt de ingang van één longkwab afgesloten met een aantal eenrichtingsventielen. Deze ventielen zorgen ervoor dat er geen lucht meer in de longkwab kan komen en de lucht er wel uit kan. Daardoor zal de volledige

longkwab leegstromen en samenvallen. Dit geeft de longvolumereductie, waarbij de overgebleven longkwabben beter kunnen functioneren. Het is bewezen dat behandeling met ventielen kan leiden tot een verbetering van de longfunctie en een betere kwaliteit van leven en beter inspanningsvermogen kan geven.

Helaas is niet elke patiënt met ernstig COPD geschikt voor een behandeling met ventielen. De behandeling is alleen effectief als er sprake is van ernstig emfyseem en veel hyperinflatie. De longkwab met het meeste emfyseem is de kwab die als behandeltarget wordt gekozen. Een longkwab kan verder alleen effectief behandeld worden met ventielen als er geen luchtstroom is tussen de kwab die behandeld wordt met ventielen en de aanliggende kwab. Dit wordt ook wel **collaterale ventilatie** genoemd. Als er sprake is van collaterale ventilatie, dan komt dit meestal omdat de scheiding tussen de longkwabben (de **fissuur**) niet volledig is aangelegd. Collaterale ventilatie kan gemeten worden tijdens een bronchoscopie, door een **Chartis-meting** te verrichten. Tijdens deze meting wordt de te behandelen longkwab afgesloten met een ballonkatheter en hierna kan gemeten worden hoeveel lucht er door de katheter uit de longkwab stroomt. Als er geen collaterale ventilatie is, neemt deze luchtstroom over de tijd af. Als er wel collaterale ventilatie is, zal de luchtstroom niet volledig afnemen, omdat er constant nieuwe lucht via de aanliggende longkwab wordt aangevoerd.

Op dit moment is de CT-scan van de longen het meest belangrijke middel om te kijken of een patiënt potentieel geschikt is voor een behandeling met eenrichtingsventielen. Op de CT-scan kan onder andere worden gekeken of er sprake is van ernstig emfyseem en of er een specifieke longkwab is die het best kan worden behandeld. Daarnaast kunnen de fissen op de CT-scan beoordeeld worden. Als de fissuur niet intact is, zal er waarschijnlijk collaterale ventilatie zijn en bij een intacte fissuur is er waarschijnlijk geen collaterale ventilatie. In dat geval kan een behandeling met ventielen effectief zijn.

In de afgelopen jaren is er veel ontwikkeling in computerprogramma's die medici kunnen helpen bij het beoordelen van deze CT-scans. Deze programma's kunnen diverse parameters automatisch analyseren, zoals de luchtwegen, bloedvaten in de longen, de ernst van het emfyseem en de compleetheid van de fissen. Het gebruik van deze kwantitatieve CT-scan analyse is voor de beoordeling of een patiënt geschikt kan zijn voor behandeling met ventielen erg belangrijk geworden.

In dit proefschrift onderzoeken wij of het gebruik van de kwantitatieve CT-scan analyse voor deze patiëntengroep geoptimaliseerd kan worden, om zo beter in staat te zijn om de juiste patiënten te selecteren en de juiste behandelkwab te kunnen kiezen. Daarnaast bespreken we enkele manieren om het daadwerkelijk meten van de collaterale ventilatie te kunnen optimaliseren (de Chartis-meting) en gaan we in op de belangrijkste complicaties na behandeling met ventielen.

De studies die onderdeel uitmaken van het proefschrift zijn hieronder samengevat.

In **hoofdstuk 2** geven we een samenvatting van de literatuur over de huidige bronchoscopische longvolumereductiebehandelingen voor patiënten met ernstig emfyseem en de meest belangrijke kenmerken die van belang zijn om de juiste patiënten te kunnen selecteren. De behandeling met eenrichtingsventielen is het meest effectief en uit studies blijkt dat dit ook effectief kan zijn bij mensen die voor eerdere gerandomiseerde studies niet in aanmerking kwamen, bijvoorbeeld vanwege een verhoogd koolzuur in het bloed.

Het doel van de behandeling met ventielen is om de behandelde longkwab volledig samen te laten vallen. In het merendeel van de patiënten is dit niet mogelijk, omdat er sprake is van collaterale ventilatie tussen de behandelkwab en de aanliggende kwab(ben). Zoals besproken speelt de fissuur hierin een centrale rol. In **hoofdstuk 3** gaan we dieper in op de fissuren en de aanwezigheid van collaterale ventilatie binnen een longkwab en tussen verschillende longkwabben en de relevantie hiervan voor behandelingen bij patiënten met ernstig COPD.

In **hoofdstuk 4** en **5** onderzoeken we de voorspellende waarde van de mate van compleet zijn van de fissuur op de aanwezigheid van collaterale ventilatie. In **hoofdstuk 4** gebruiken we de data van de 4 grote studies die de effectiviteit van de ventielen onderzochten en werden alle scans uit deze studies geanalyseerd middels kwantitatieve CT-scan analyse. De compleetheid van de fissuur werd hierbij vergeleken met de uitkomst van de behandeling met ventielen. Hierbij werden drie groepen geïdentificeerd: 1) patiënten met complete fissuren (>95%), die effect hadden van de behandeling; 2) patiënten met incomplete fissuren (<80%), die geen effect hadden van de behandeling; en 3) patiënten met deels intacte fissuren (>80%, maar <95%). Op basis van deze studie zouden patiënten met incomplete fissuren uitgesloten kunnen worden van Chartis-meting en behandeling, patiënten met complete fissuren zouden behandeld kunnen worden, eventueel zonder Chartis-meting. In de derde, tussenliggende groep is de fissuurscore minder voorspellend en hierbij kan met de Chartis-meting gemeten worden of er sprake is van collaterale ventilatie en of een patiënt behandeld kan worden. Als aanvulling op **hoofdstuk 4** hebben we in **hoofdstuk 5** een studie uitgevoerd waarin we de voorspellende waarde van de compleetheid van de fissuur berekenden voor de aanwezigheid van collaterale ventilatie. De compleetheid van de fissuur werd berekend met kwantitatieve CT-scan analyse en vergeleken met de aan- of afwezigheid van interlobaire collaterale ventilatie, gemeten met het Chartis-systeem. Hierbij bleek dat er een verschil is tussen de linker- en de rechterlong, waarschijnlijk omdat deze fissuren anders zijn aangelegd. De linkerlong bestaat uit twee longkwabben en hier is slechts één fissuur; rechts zijn er drie longkwabben en twee fissuren. Uit deze studie bleek dat bij patiënten met niet-intacte fissuren (linker grote fissuur <80% en rechter grote fissuur <90%) kunnen worden uitgesloten van aanvullende Chartis-meting en behandeling. Bij patiënten met meer complete fissuren is de fissuurscore niet specifiek genoeg om te kunnen beslissen of een behandeling mogelijk is. In dat geval wordt de Chartis-meting altijd aanbevolen in de rechterlong en voor de linkerlong kan eventueel worden behandeld zonder aanvullende Chartis-meting, als de fissuur >95% compleet is.

De Chartis-meting is erg belangrijk om de aanwezigheid van collaterale ventilatie te kunnen bepalen en de behandeling met ventielen wordt dus grotendeels bepaald op basis van deze uitkomst. In **hoofdstuk 6** evalueren we een nieuwe tool om te kunnen beoordelen of een heel lage flow tijdens de Chartis-meting ook voorspellend is voor de afwezigheid van collaterale ventilatie en of hierdoor de Chartis-meting ook verkort kan worden. Dit wordt gemeten met de “volume trend in de afgelopen 20 seconden” (VT20), waarbij het volume wordt weergegeven dat de afgelopen 20 seconden uit de longkwab is gestroomd via de ballonkatheter. Hiervoor analyseerden we 249 Chartis-metingen die verricht waren bij patiënten die ingepland waren voor een bronchoscopische longvolumereductiebehandeling. De VT20 werd hierbij berekend en we vonden dat bij alle metingen waarbij er geen collaterale ventilatie was, de VT20 6 mL of lager was, terwijl bij aanwezigheid van collaterale ventilatie bij alle metingen de VT20 boven de 7 mL bleef. We concludeerden dat het gebruik van de drempel van een VT20 van 6 mL of lager een betrouwbare methode is om de aanwezigheid van collaterale ventilatie te kunnen bepalen als er sprake is van een lage flow. Tevens kan een meting makkelijker geïnterpreteerd worden en kan er ook eerder gestopt worden. Op dit moment is deze tool geïmplementeerd in de Chartis-software en wordt deze nieuwe tool wereldwijd gebruikt.

De Chartis-meting kan erg uitdagend zijn en een goede meting is wel essentieel voor het besluit om wel of niet te behandelen. Echter, met name in metingen van de onderkwabben, kan de Chartis-meting lastig zijn door het “no-flow fenomeen”, wat betekent dat er geen flow is van de afgesloten longkwab naar de Chartis-console direct na start van de meting, of dat deze flow plotseling stopt tijdens de meting. Hierdoor is de meting niet betrouwbaar. De oorzaak is waarschijnlijk dat de luchtwegen in de onderkwabben makkelijker samenvallen tijdens de meting. Als dit fenomeen optreedt in de linkeronderkwab, kan dit makkelijk opgelost worden door de linkerbovenkwab te meten, omdat er maar één fissuur aanwezig is links. Als dit in de rechteronderkwab plaats vindt, moet zowel de rechterbovenkwab als -middenkwab gemeten worden. Dit kan door de ingang van de middenkwab tijdelijk af te sluiten met een ballon of een Watanabe spigot en vervolgens de meting in de rechterbovenkwab te verrichten. In **hoofdstuk 7** beschrijven we de resultaten waarin we bij 15 patiënten met ernstig COPD op deze manier een goede en betrouwbare Chartis meting hebben kunnen doen.

Voor het selecteren van de optimale behandelkwab is het vaak ook nog van belang om op de hoogte te zijn van de doorbloeding (perfusie) van de longen en longkwabben. Dit kan worden gemeten met een nucleaire perfusiescintigrafie of single-photon emission computed tomography (SPECT-CT). Momenteel worden deze testen uitgevoerd als aanvullende test naast de CT-scan die standaard wordt verricht. Voor **hoofdstuk 8** hebben we deze perfusie berekend met behulp van kwantitatieve CT-analyse (PXT) op basis van de CT-scan. Deze uitkomst werd vergeleken met de uitkomsten van nucleaire perfusiescintigrafie en SPECT-CT. In deze studie hebben we de PXT vergeleken met perfusiescintigrafie voor perfusie van de linker- en rechterlong bij 207 patiënten, en met SPECT-CT voor vergelijking van perfusie per kwab bij 85 patiënten. We vonden een zeer hoge correlatie tussen deze testen met slechts kleine verschillen. We concludeerden dat de perfusie in de longen nauwkeurig kan worden geschat met behulp van de kwantitatieve CT-scan analyse. Door hiervan gebruik te maken is

de CT-scan nog waardevoller in de patiëntselectie en het selecteren van de te behandelen longkwab. Tevens kunnen hiermee extra aanvullende onderzoeken en kosten vermeden worden.

Na behandeling met ventielen is zorgvuldige monitoring en follow-up belangrijk om het effect van de behandeling te evalueren en mogelijke complicaties of bijwerkingen te kunnen behandelen. In **hoofdstuk 9** hebben we de belangrijkste complicaties na behandeling met ventielen en de behandeling hiervan samengevat. De belangrijkste complicaties zijn een klaplong (4-26%), longontsteking (1-4%) en bloed ophoesten (1-6%). In een deel van de patiënten is er geen effect na de behandeling, dit kan komen door bijvoorbeeld de aanwezigheid van collaterale ventilatie of als de ventielen niet goed gepositioneerd zijn. Daarnaast kan een aanvankelijk gunstig effect verdwijnen, bijvoorbeeld als gevolg van de vorming van granulatieweefsel, waardoor de positie van de ventielen verandert. Aanvullend onderzoek middels een CT-scan en/of bronchoscopie is nodig als er geen verbetering optreedt na de behandeling, als er verlies is van initieel goed effect of als er belangrijke bijwerkingen zijn.

In **hoofdstuk 10** beschrijven we een specifieke complicatie na behandeling met eenrichtingsventielen. Doordat de longkwab die behandeld is met ventielen volledig samenvalt, verandert de positie van de luchtwegen van de andere longkwab. Als deze luchtweg te veel af knikt, kan dit leiden tot toename van benauwdheid omdat er dan geen lucht meer in de longkwab komt die juist beter moest gaan functioneren. In dit hoofdstuk beschrijven we een casus van een patiënt die hierdoor klachten kreeg, na behandeling met eenrichtingsventielen in de linkerbovenkwab. Deze patiënt werd succesvol behandeld door het plaatsen van een biologisch afbreekbare stent in de luchtweg van de linkeronderkwab.

In **Hoofdstuk 11** beschrijven we een alternatieve behandeling voor patiënten die niet in aanmerking komen voor behandeling met eenrichtingsventielen. Behandeling met een scleroserend middel (AeriSeal) is momenteel al een optie om longvolumereductie te bereiken. In deze studie hebben we verder gekeken naar de veiligheid en werkzaamheid van deze behandeling, maar dan verdeeld over twee procedures, met lagere dosering dan gebruikelijk. AeriSeal werd toegediend tijdens twee opeenvolgende bronchoscopieën: eerst werden 2 subsegmenten van een longkwab behandeld met twee doses van 5 mL, zes weken later gevolgd door twee doses van 10 mL in de longkwab aan de andere zijde. In totaal werden 14 patiënten behandeld. AeriSeal-behandeling resulteerde in een significante vermindering van het volume van de behandelde longkwab na 3 maanden follow-up, maar er waren geen significante veranderingen na 12 maanden op het gebied van longfunctie, inspanningscapaciteit en kwaliteit van leven. Verder gaf deze gefaseerde behandeling met lagere dosering geen duidelijk verschil in het aantal bijwerkingen in vergelijking met een enkelvoudige behandeling in hogere dosering.

Concluderend heeft dit proefschrift ertoe bijgedragen dat voor patiënten met ernstig COPD het gebruik van kwantitatieve CT-scan analyse is verbeterd, met name in het beoordelen van de fissuren en de doorbloeding van de longen, om hiermee de meest geschikte patiënten en behandelkwalen te kunnen selecteren voor behandeling met ventielen.

Omdat de behandeling met ventielen voor de meeste patiënten met ernstig emfyseem en hyperinflatie helaas niet geschikt is, is er veel behoefte aan alternatieve behandelingen. Voor de toekomst hopen we meer effectieve alternatieve bronchoscopische behandelingen te kunnen ontwikkelen (bijvoorbeeld de ontwikkeling van 'airway bypass' of biogel).



## DANKWOORD

Mijn promotietraject is onlosmakelijk verbonden met mijn opleiding tot en mijn werk als longarts. Ik heb het geluk dat ik mijn werk kan combineren met (promotie)onderzoek, in het gebied wat ik leuk en interessant vind. Onderzoek doe je uiteraard niet alleen en graag wil ik iedereen bedanken met wie ik de afgelopen jaren heb samengewerkt. Maar een aantal mensen wil ik graag in het bijzonder bedanken.

Beste Dirk Jan, ik ben blij dat je mijn opleider was en enorm hebt bijgedragen aan mijn opleiding tot longarts. Dat ik de kans heb gekregen om me tijdens mijn opleiding verder te verdiepen in de zorg bij ernstig COPD en bronchoscopische interventies en we dit promotietraject hebben kunnen opstarten. Ook nu als longarts en collega leer ik nog erg veel bij, zowel op gebied van onderzoek, organisatie en klinische zorg (o.a. de interventies). Het is inspirerend om te zien hoe jij je werk als (interventie-)longarts, afdelingshoofd en onderzoeker combineert. Ik heb van dichtbij meegemaakt hoe jullie de behandeling met eenrichtingsventielen in Nederland (en eigenlijk wereldwijd) als compleet nieuwe behandeling op de kaart hebben kunnen zetten en ik hoop dat we in de toekomst nog veel mooie dingen kunnen onderzoeken en ontwikkelen.

Beste Huib, heel erg bedankt voor de vele manieren waarop je betrokken bent bij mijn huidige carrière: natuurlijk nu als promotor tijdens mijn promotieonderzoek, maar ook als mentor tijdens mijn opleiding en als afdelingshoofd heb je me een vaste plek geboden als longarts. Ik heb veel bewondering voor jouw scherpe blik en analyses, zowel op onderzoeksgebied, maar ook als arts en manager.

Beste Karin, toen jij promoveerde, begon ik zo ongeveer met mijn promotietraject en ben jij mijn co-promotor geworden. Ik heb heel veel van je geleerd op het gebied van onderzoek doen en hoe je lastige praktische zaken toch schijnbaar makkelijk op weet te lossen. Daarnaast ben je een voorbeeld voor mij met de manier waarop je je inzet voor de patiënten, de persoonlijke aandacht die je ze geeft en de manier waarop je de beste zorg voor ze probeert te krijgen.

Het team van het bronchoscopisch interventie centrum (het BIC-team): Dirk-Jan, Karin, Jorine, Marlies, Sonja, Gea, Marieke, Sharyn, Jens en Else (en Jorrit). Het is leuk om te zien dat er vanuit veel verschillende kanten wordt gewerkt aan het optimaliseren van de behandeling en diagnostiek van ernstig COPD met eenrichtingsventielen en alternatieve behandelingen. Bedankt voor de leuke samenwerking!

Beste Gea, bedankt voor al het inplanwerk, opvragen van gegevens en last-minute CT-scans regelen.



Beste Sonja, bedankt voor het uitvoeren van alle functieonderzoeken, een betrouwbare longfunctie is goud waard om te gebruiken bij alle analyses!

Beste Jorine, dank voor je regelmatige hulp en adviezen bij statistische en methodische vraagstukken.

Beste Marlies, je loopt telkens precies een jaartje voor me uit (longarts, promotie), maar ondertussen zijn we al heel wat jaren kamergenoten en collega's. Ik snap dat je regelmatig even je noise cancelling headphones nodig hebt om mij te kunnen negeren, maar het is altijd fijn om even met je te kunnen sparren over patiënten, onderzoek en andere dingen.

I would like to thank the reading committee, Prof. Dr. P.L. Shah, Prof. Dr. P.J. Wijkstra and Prof. Dr. L.E.G.W. Vanfleteren, for reviewing this thesis.

I would like to thank all the co-authors for their contribution to the manuscripts in this thesis.

Dear team of PulmonX, several publications from my thesis were result of our nice collaboration. I look forward to our future projects to improve the treatment of patients with severe COPD.

Beste Eva en Jean Paul, heel erg bedankt voor de leuke samenwerking met Thirona op het gebied van kwantitatieve CT-scan analyse waarmee ik in samenwerking met jullie een aantal heel leuke en belangrijke publicaties heb kunnen doen. Volgens mij zijn er nog genoeg projecten voor de nabije toekomst.

Beste Jan Pruijm, Hester Gietema, Lowie Vanfleteren en Rein Posthuma, dank voor de samenwerking voor het perfusie manuscript. Dit is een heel mooie en belangrijke publicatie geworden en een goed voorbeeld van samenwerking tussen verschillende disciplines en ziekenhuizen.

Voor optimale zorg rondom de bronchoscopische interventies bij patiënten met ernstig COPD, is een goede samenwerking essentieel. Dank aan alle betrokken collega's van het Endoscopiecentrum, Functiecentrum, verpleegafdelingen D3VA en E4VA, polikliniek Longziekten en de afdelingen Radiologie, Anesthesiologie en de Thoraxchirurgie!

Beste collega longartsen en (oud) arts-assistenten, het is best een voorrecht om als longarts in het UMC Groningen te mogen werken. Alle aspecten van de longziekten komen hier aan bod, er is een heel goede sfeer op de afdeling en een heel goede samenwerking tussen alle verschillende subspecialismen. Dit maakt dat we heel leuke en goede klinische zorg kunnen geven en belangrijk wetenschappelijk onderzoek kunnen doen.

Allerliefste Martin en Jelmer: een blonde schuine streep, Xanthus, misselijk na squash, bevroren terug van de Amerongse berg, "pas op, doorn!", spiegelei, doorweekt op WK baan. Mijn promotie staat niet los van mijn opleiding als longarts, maar zeker ook niet van onze studententijd en de jaren erna. Ik ben blij dat jullie als ondertussen vermaard schrijver en huisarts getuige zijn van mijn promotie als paranimfen.

Lieve Joris, Else en Suze, het is fantastisch om jullie te zien opgroeien. Het is goed te beseffen dat er belangrijker dingen op de wereld zijn dan werk en onderzoek.

Lieve Renske, vanaf basisschoolleeftijd was het eigenlijk al rond, maar nog officieus. Ondertussen zijn we al ruim 22 jaar echt samen en in deze tijd hebben we al veel bijzondere dingen meegemaakt. Bedankt voor je liefde, steun en support, jij bent wel het beste wat ik me kan wensen.



## CURRICULUM VITAE

Theodoor David Koster werd in 1984 geboren in Echten (Drenthe). In 2003 rondde hij het gymnasium af aan het Roelof van Echten college in Hoogeveen. Na twee jaar biomedische wetenschappen te hebben gestudeerd, startte hij in 2005 de opleiding geneeskunde aan de Universiteit Utrecht. Na de opleiding heeft hij een jaar als arts-assistent in het St. Antonius Ziekenhuis in Nieuwegein gewerkt op de afdeling longziekten. In 2012 is hij aan zijn opleiding tot longarts begonnen in het UMC Groningen en richting het einde van de opleiding is hij ook met zijn promotietraject gestart.

In 2018 rondde hij zijn opleiding tot longarts af en startte hij een fellowship 'ernstig COPD en bronchoscopische interventies', waarbij hij zijn promotieonderzoek en klinische zorg kon combineren. In 2020 werd het fellowship omgezet in een vaste stafaanstelling. Momenteel werkt hij als longarts in het UMC Groningen met als aandachtsgebieden de behandeling van ernstig COPD en bronchoscopische interventies.



**PUBLICATIONS**

- 1 Welling JBA, **Koster TD**, Slebos DJ. From plugging air leaks to reducing lung volume: a review of the many uses of endobronchial valves. *Expert Rev Med Devices*. 2023 Jul 7. Online ahead of print.
- 2 **Koster TD**, Charbonnier JP, Pruijm J, Gietema HA, Posthuma R, Vanfleteren LEGW, van Dijk M, Klooster K, Slebos DJ. HRCT-Approximated Perfusion is Comparable to Nuclear Perfusion Imaging in Severe COPD. *Am J Respir Crit Care Med*. 2023 May 16. Online ahead of print.
- 3 Roodenburg SA, Slebos DJ, van Dijk M, **Koster TD**, Klooster K, Hartman JE. Improved exercise capacity results in a survival benefit after endobronchial valve treatment. *Respir Med*. 2023 Apr-May;210:107175.
- 4 Klooster K, van Dijk M, **Koster TD**, Hartman JE, Slebos DJ. Bronchoscopic Lung Volume Reduction With Endobronchial Valves Exclusively of the Middle Lobe in Patients With Emphysema. *J Bronchology Interv Pulmonol*. 2023 Apr 1;30(2):192-195.
- 5 Everaerts S, Hartman JE, Van Dijk M, **Koster TD**, Slebos DJ, Klooster K. Bronchoscopic Lung Volume Reduction in Patients with Emphysema due to Alpha-1 Antitrypsin Deficiency. *Respiration*. 2023;102(2):134-142.
- 6 Klooster K, Hartman JE, **Koster TD**, Slebos DJ, van Dijk M. Prevalence and Impact of COVID-19 among Severe COPD Patients post Bronchoscopic Lung Volume Reduction Treatment with Endobronchial Valves. *Respiration*. 2023;102(3):203-206.
- 7 Hartman JE, Klooster K, **Koster TD**, Ten Hacken NHT, van Dijk M, Slebos DJ. Long-term follow-up after bronchoscopic lung volume reduction valve treatment for emphysema. *ERJ Open Res*. 2022 Nov 21;8(4):00235-2022.
- 8 **Koster TD**, Eberhardt R, Huebner RH, Valipour A, Herth F, Klooster K, Shargill NS, Radhakrishnan S, Slebos DJ. A multicenter, prospective, single-arm clinical investigation of a modified staged treatment algorithm using the AeriSeal system - The STAGE trial. *Respir Med*. 2022 Nov;203:106989.
- 9 **Koster TD**, van Dijk M, Slebos DJ. Bronchoscopic Lung Volume Reduction for Emphysema: Review and Update. *Semin Respir Crit Care Med*. 2022 Aug;43(4):541-551.
- 10 **Koster TD**, Klooster K, van Dijk M, Slebos DJ. Biodegradable Stent Placement for Airway Kinking After Bronchoscopic Lung Volume Reduction Treatment. *Ann Thorac Surg*. 2022 May;113(5):e375-e377.

- 11 **Koster TD**, Klooster K, McNamara H, Shargill NS, Radhakrishnan S, Olivera R, Slebos DJ. An adjusted and time-saving method to measure collateral ventilation with Chartis. *ERJ Open Res.* 2021 Jul 26;7(3):00191-2021.
- 12 Roodenburg SA, Klooster K, Hartman JE, **Koster TD**, van Dijk M, Slebos DJ. Revision Bronchoscopy After Endobronchial Valve Treatment for Emphysema: Indications, Findings and Outcomes. *Int J Chron Obstruct Pulmon Dis.* 2021 Apr 21;16:1127-1136.
- 13 Klooster K, Hartman JE, van Dijk M, **Koster TD**, Slebos DJ. Response to Endobronchial Valve Treatment in Emphysema Patients With Moderate Hyperinflation. *J Bronchology Interv Pulmonol.* 2021 Jan 1;28(1):e14-e17.
- 14 **Koster TD**, Klooster K, Ten Hacken NHT, van Dijk M, Slebos DJ. Endobronchial valve therapy for severe emphysema: an overview of valve-related complications and its management. *Expert Rev Respir Med.* 2020 Dec;14(12):1235-1247.
- 15 Hartman JE, Klooster K, **Koster TD**, van Dijk M, Slebos DJ. Minimal important difference of change in patient-specific goals in severe emphysema patients. *ERJ Open Res.* 2020 Oct 19;6(4):00459-2020.
- 16 van Dijk M, Gan CT, **Koster TD**, Wijkstra PJ, Slebos DJ, Kerstjens HAM, van der Vaart H, Duiverman ML. Treatment of severe stable COPD: the multidimensional approach of treatable traits. *ERJ Open Res.* 2020 Sep 21;6(3):00322-2019.
- 17 Klooster K, **Koster TD**, Ruwwe-Glösenkamp C, Theilig D, Doellinger F, Saccomanno J, Kerstjens HAM, Slebos DJ, Hübner RH. An Integrative Approach of the Fissure Completeness Score and Chartis Assessment in Endobronchial Valve Treatment for Emphysema. *Int J Chron Obstruct Pulmon Dis.* 2020 Jun 9;15:1325-1334.
- 18 Welling JBA, **Koster TD**, Hartman JE, van Dijk M, Kerstjens HAM, Klooster K, Slebos DJ. Temporary Right Middle Lobe Occlusion with a Blocking Device to Enable Collateral Ventilation Measurement of the Right Major Fissure. *Respiration.* 2020;99(6):516-520.
- 19 Klooster K, van Dijk M, **Koster TD**, Slebos DJ. First in Human Experience of the Performance of the New 5.5-LP Size Zephyr Endobronchial Valve. *Respiration.* 2020;99(1):50-55.
- 20 **Koster TD**, van Dijk M, Slebos DJ. Een man met hypoxemie na een femurfractuur [A man with hypoxaemia after a femoral fracture]. *Ned Tijdschr Geneesk.* 2017;161:D987. Dutch.

- 21 **Koster TD**, van Rikxoort EM, Huebner RH, Doellinger F, Klooster K, Charbonnier JP, Radhakrishnan S, Herth FJ, Slebos DJ. Predicting Lung Volume Reduction after Endobronchial Valve Therapy Is Maximized Using a Combination of Diagnostic Tools. *Respiration*. 2016;92(3):150-7.
- 22 **Koster TD**, Slebos DJ. The fissure: interlobar collateral ventilation and implications for endoscopic therapy in emphysema. *Int J Chron Obstruct Pulmon Dis*. 2016 Apr 13;11:765-73.
- 23 **Koster TD**, Kooistra WE, Tuinman AG. Near miss with succinylcholine for electroconvulsive therapy: a case report. *Eur J Anaesthesiol*. 2014 Aug;31(8):441-3.
- 24 **Koster TD**, Ramjankhan FZ, Kwakkel-van Erp JM. Reply to the editor. *J Thorac Cardiovasc Surg*. 2014 Mar;147(3):1111-2.
- 25 **Koster TD**, Ramjankhan FZ, van de Graaf EA, Luijk B, van Kessel DA, Meijer RC, Kwakkel-van Erp JM. Crossed wiring closure technique for bilateral transverse thoracosternotomy is associated with less sternal dehiscence after bilateral sequential lung transplantation. *J Thorac Cardiovasc Surg*. 2013 Oct;146(4):901-5.
- 26 Bins S, **Koster TD**, de Heij AH, de Vries AC, van Pelt AB, Aarts MC, Rovers MM, van der Heijden GJ. No evidence for diagnostic value of Mallampati score in patients suspected of having obstructive sleep apnea syndrome. *Otolaryngol Head Neck Surg*. 2011 Aug;145(2):199-203.











