

University of Groningen

## Novel aspects in the pathophysiology and diagnosis of glomerular diseases

Kronbichler, Andreas; Bajema, Ingeborg; Geetha, Duvuru; Säemann, Marcus

*Published in:*  
Annals of the Rheumatic Diseases

*DOI:*  
[10.1136/ard-2022-222495](https://doi.org/10.1136/ard-2022-222495)

**IMPORTANT NOTE: You are advised to consult the publisher's version (publisher's PDF) if you wish to cite from it. Please check the document version below.**

*Document Version*  
Publisher's PDF, also known as Version of record

*Publication date:*  
2023

[Link to publication in University of Groningen/UMCG research database](#)

*Citation for published version (APA):*

Kronbichler, A., Bajema, I., Geetha, D., & Säemann, M. (2023). Novel aspects in the pathophysiology and diagnosis of glomerular diseases. *Annals of the Rheumatic Diseases*, 82(5), 585-593.  
<https://doi.org/10.1136/ard-2022-222495>

### Copyright

Other than for strictly personal use, it is not permitted to download or to forward/distribute the text or part of it without the consent of the author(s) and/or copyright holder(s), unless the work is under an open content license (like Creative Commons).

The publication may also be distributed here under the terms of Article 25fa of the Dutch Copyright Act, indicated by the "Taverne" license. More information can be found on the University of Groningen website: <https://www.rug.nl/library/open-access/self-archiving-pure/taverne-amendment>.

### Take-down policy

If you believe that this document breaches copyright please contact us providing details, and we will remove access to the work immediately and investigate your claim.

*Downloaded from the University of Groningen/UMCG research database (Pure): <http://www.rug.nl/research/portal>. For technical reasons the number of authors shown on this cover page is limited to 10 maximum.*

# Novel aspects in the pathophysiology and diagnosis of glomerular diseases

Andreas Kronbichler <sup>1,2</sup>, Ingeborg Bajema,<sup>3</sup> Duvuru Geetha,<sup>4</sup> Marcus Säemann <sup>5,6</sup>

**Handling editor** David S Pisetsky

<sup>1</sup>Department of Medicine, University of Cambridge, Cambridge, UK

<sup>2</sup>Vasculitis and Lupus Service, Addenbrooke's Hospital, Cambridge, UK

<sup>3</sup>Department of Pathology, Leiden University Medical Center, Leiden and Department of Pathology and Medical Biology, University of Groningen, University Medical Center, Groningen, The Netherlands

<sup>4</sup>Department of Medicine, Johns Hopkins University School of Medicine, Baltimore, Maryland, USA

<sup>5</sup>6th Medical Department, Nephrology and Dialysis, Clinic Ottakring, Vienna, Austria

<sup>6</sup>Medical Faculty, Sigmund Freud University, Vienna, Austria

## Correspondence to

Dr Andreas Kronbichler, Department of Medicine, University of Cambridge, Cambridge, UK; ak2283@cam.ac.uk

AK and IB contributed equally.

Received 16 March 2022

Accepted 9 December 2022

Published Online First

19 December 2022

## ABSTRACT

Immune deposits/complexes are detected in a multitude of tissues in autoimmune disorders, but no organ has attracted as much attention as the kidney. Several kidney diseases are characterised by the presence of specific configurations of such deposits, and many of them are under a 'shared care' between rheumatologists and nephrologists. This review focuses on five different diseases commonly encountered in rheumatological and nephrological practice, namely IgA vasculitis, lupus nephritis, cryoglobulinaemia, anti-glomerular basement membrane disease and anti-neutrophil cytoplasm-antibody glomerulonephritis. They differ in disease aetiopathogenesis, but also the potential speed of kidney function decline, the responsiveness to immunosuppression/immunomodulation and the deposition of immune deposits/complexes. To date, it remains unclear if deposits are causing a specific disease or aim to abrogate inflammatory cascades responsible for tissue damage, such as neutrophil extracellular traps or the complement system. In principle, immunosuppressive therapies have not been developed to tackle immune deposits/complexes, and repeated kidney biopsy studies found persistence of deposits despite reduction of active inflammation, again highlighting the uncertainty about their involvement in tissue damage. In these studies, a progression of active lesions to chronic changes such as glomerulosclerosis was frequently reported. Novel therapeutic approaches aim to mitigate these changes more efficiently and rapidly. Several new agents, such as avacopan, an oral C5aR1 inhibitor, or imlifidase, that dissolves IgG within minutes, are more specifically reducing inflammatory cascades in the kidney and repeat tissue sampling might help to understand their impact on immune cell deposition and finally kidney function recovery and potential impact of immune complexes/deposits.

## INTRODUCTION

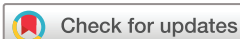The term immune-complex glomerulonephritis (ICGN) is used in connection with specific disease entities and denotes a pattern of disease in which an immune-mediated process resulting in glomerular deposits has led to kidney injury. The huge complexity behind the term could easily be underestimated: there are numerous kidney diseases that are characterised by the presence of deposits; but not all deposits are immune deposits, and not all immune deposits are immune complexes.<sup>1</sup> However, regardless of the nature of the deposits, they are considered to initiate and perpetuate an inflammatory response and further abrogate tolerance mechanisms of both B and T cells,<sup>2</sup> critical in the pathogenesis of autoimmunity.

Renal pathologists mostly use combinations of findings by immunofluorescence (IF) staining and electron microscopy (EM) to determine the nature and location of all kinds of deposits in a kidney biopsy. This enables the distinction between an enormous variety of deposits sharing characteristics by either one technique but are different by mutual exclusion. For example, in C3 glomerulonephritis, C3 is the dominant staining by IF, but the variant dense deposit disease can only be recognised by EM.<sup>3</sup>

For this review, we have chosen to focus on five kidney diseases that are commonly encountered by the rheumatologists: IgA vasculitis (IgAV), lupus nephritis (LN), cryoglobulinaemia, anti-glomerular basement membrane (GBM) disease and anti-neutrophil cytoplasm-antibody glomerulonephritis (ANCA-GN). For the latter, its denotation as an ICGN may be questioned as indicated already by its other name 'pauci-immune glomerulonephritis'. However, recent evidence highlights the importance of deposition of especially complement fragments in kidney biopsy specimens of patients with ANCA-GN. We also include it in this review because of its relevance for the rheumatologist. Most importantly, whereas pathogenesis of the five diseases that are the focus of our review may differ, they share the important clinical threat of turning into chronic kidney disease (CKD) and frequently require a shared care by rheumatologists and nephrologists.

## CLINICAL PHENOTYPES

The discussed diseases not only differ among each other in terms of organ manifestations (table 1), also within their own spectrum marked differences are apparent, for instance in their clinical presentation, treatment response and outcomes. Kidney disease clinically presents as nephritic syndrome in IgAV, cryoglobulinaemia, anti-GBM disease and ANCA-GN, while patients with LN present with different degrees of nephrosis (although often as non-nephrotic proteinuria, and might also present with a degree of haematuria and thus nephritis). The differences in symptoms between nephritic syndrome and nephrosis are highlighted in table 2. Assessment of kidney function (serum creatinine, estimated glomerular filtration rate (eGFR)) and urinalysis, both at diagnosis and follow-up visits, is needed to detect overt kidney involvement in cases with a mainly extra-renal initial manifestation. Early referral to nephrology to verify kidney involvement and establish a therapeutic concept directed to limit the extent of kidney damage (ie, sclerosis) is needed as part of a shared care between specialties.



© Author(s) (or their employer(s)) 2023. No commercial re-use. See rights and permissions. Published by BMJ.

**To cite:** Kronbichler A, Bajema I, Geetha D, et al. *Ann Rheum Dis* 2023;**82**:585–593.

**Table 1** Organ involvement in IgA vasculitis, systemic lupus erythematosus, cryoglobulinaemic disease, anti-GBM disease and ANCA-associated vasculitis. In general, frequencies of reported organ involvement depend on recruiting physician profession (rheumatologist, nephrologist, ENT surgeon and so on) and age of the patients (ie, kidney disease in younger IgA vasculitis less frequent than in adults, and vice versa in SLE).

	IgA vasculitis <sup>72</sup> (%)	Cryoglobulinaemic disease <sup>77</sup>					ANCA-associated vasculitis <sup>50</sup>			
		SLE <sup>73–76</sup> (%)	Type 1 Cryo (%)	HCV-related mixed Cryo (%)	HCV-related life-threatening Cryo (%)	Non-infectious mixed Cryo (%)	Anti-GBM disease <sup>19</sup> (%)	GPA (%)	MPA (%)	EGPA (%)
Kidney	38.8	49	30	30	73	35	99	58.6	82.2	26.4
Lung	–	33	–	2	18	2	30–60	63.1	62.8	88.7
Skin	100	83	69	98	66	75	–	34.7	29.5	47.2
ENT	–	42.9*	–	–	–	–	–	82.3	25.8	70.6
Neurology	–	24	44	80	45	52	–	31.2	36.6	66.2
Gastrointestinal	27.1	8–10	0	0	16	5	–	18.7	22.2	29.9

\*Nasal symptoms only, but a particular focus on nasal investigation.

ANCA, anti-neutrophil cytoplasm-antibody; Cryo, cryoglobulinaemia; EGPA, eosinophilic granulomatosis with polyangiitis; ENT, ear, nose and throat; GBM, glomerular basement membrane; GPA, granulomatosis with polyangiitis; HCV, hepatitis C virus; MPA, microscopic polyangiitis; SLE, systemic lupus erythematosus.

Presenting symptoms together with pathogenetic insights of the five diseases which we focus on in this review are summarised below.

### IgA vasculitis

IgAV is more common in childhood and presents less frequently with kidney involvement in comparison to adulthood.<sup>4</sup> The presence of a skin rash is a prerequisite of the disease, and often self-limiting.<sup>5</sup> Renal involvement is considered an entity with IgA-dominant glomerulonephritis, very much similar to the more frequently occurring IgA nephropathy (IgAN). In the skin, IgA deposits typically occur in foci with small vessel vasculitis. In particular in children, the presenting symptoms of skin involvement on the legs are most commonly known as Henoch-Schönlein purpura, but there are many manifestations for which the term IgA vasculitis is used that are less well defined. Clinical symptoms indicative of renal involvement may not always lead to performance of a renal biopsy—but if they do, the findings in the biopsy may be similar in various aspects to IgAN: both entities share the presence of IgA1 subclass in circulating immune complexes resulting in a pattern of IgA deposition in mesangial areas (figure 1A), accompanied by characteristic mesangial hypercellularity by light microscopy (figure 2A).<sup>6</sup> In combination with IgA1 deposition, complement C3 is frequently detected in glomeruli, reflecting the involvement of the lectin and alternative pathway in IgAV pathogenesis.<sup>5</sup> It is generally considered

that endocapillary hypercellularity and crescent formation are more common than its counterpart IgAN, perhaps in relation to the occurrence of deposits along capillary loops in addition to those in mesangial areas. In IgAN, extracapillary proliferation is regarded as an independent variable associated with a faster decline of kidney function.<sup>7</sup>

### LN in systemic lupus erythematosus

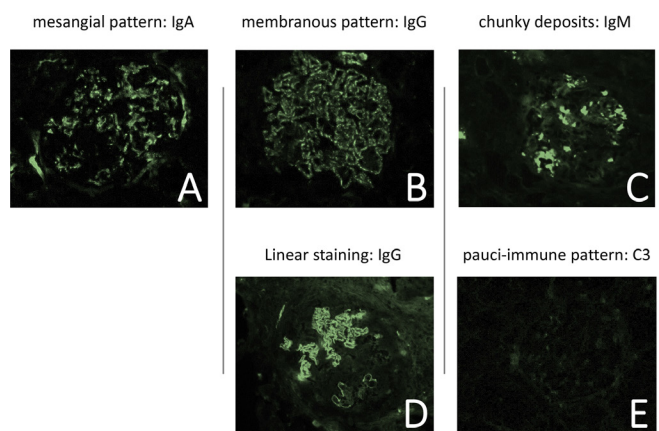
LN will ultimately be present in at least 50% of systemic lupus erythematosus (SLE) cases, and proteinuria, in some subjects presenting with severe nephrosis (including respiratory compromise, pitting oedema, severe hypertension), is the presenting feature in most patients. In the absence of other pathologies, LN classes III, IV and V require immunosuppressive therapy.<sup>8</sup>

LN is characterised by the most extensive pattern of deposition known in renal histology where all a so-called full house staining pattern (referring to simultaneous positivity for IgA, IgG, IgM, C3, C1q and light chains, depicted in figure 3A–G) in glomeruli present in various deposition patterns (mesangial (figure 2B), endocapillary (figure 2D) and membranous) are encountered, which together, form the basis for the distinction in LN classes, and moreover, they are closely associated with clinical symptoms (figure 4).<sup>9</sup> A multitude of antibodies and immune complexes are involved in LN, and although the inflammatory process may be destroying the glomerular structure, the deposits that have triggered this process in the first place, remain visible in the midst

**Table 2** Differences between nephritic and nephrotic diseases. Variations in presentation need to be expected in patients presenting with the underlying diseases. This refers to the 'standard' presentation of a patient, but note that there are exceptional cases (ie, patients with severe lupus nephritis and acute kidney failure).

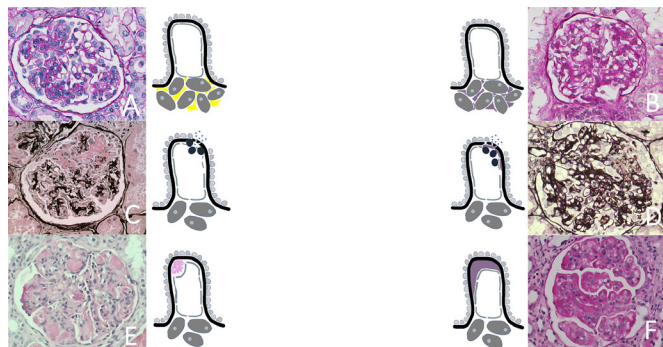
	Nephritic syndrome	Nephrotic syndrome
Onset	Mainly abrupt	Insidious-abrupt
Kidney function	Variable, from no/slow progression (many cases with IgA nephropathy) to RPGN	Mainly no significant kidney function impairment at baseline
Proteinuria	Variable, absent in some patients	'Nephrotic-range' (>3–3.5 g/day, depending on definitions) proteinuria seen in most cases
Haematuria	Feature of 'nephritis'; gross haematuria (visible blood) only in a minority of cases	Variable, absent in most patients
Blood pressure	Raised (most cases), patients often remain hypertensive (even after achieving remission)	Normal/raised (hypertensive often because of fluid overload)
Serum albumin	Normal/low	Low (in 'idiopathic' cases), <2.5 g/dL
Hypercoagulability	Present in some forms (ie, AAV)	Present in nephrotic stages (up to 40% with thrombosis)
Lipid levels	No change/reduced during active stages	Hyperlipidaemia

AAV, ANCA-associated vasculitis; RPGN, rapidly progressive glomerulonephritis.

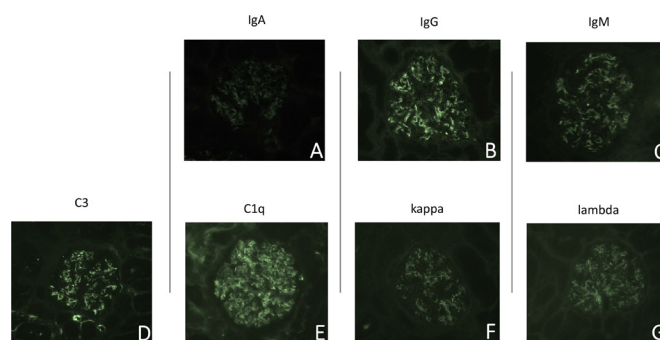


**Figure 1** Combination of localisation patterns in immunohistochemical stainings for immunoglobulins and complement is characteristic for certain ICGN. From left to right: IgAN/IgA glomerulonephritis with mesangial staining for IgA (A); membranous nephropathy (as seen in lupus class V) with granular staining along the GBM for IgG (B); chunky deposits of IgM signifying cryoglobulins in cryoglobulinaemic glomerulonephritis (C); linear staining for IgG in anti-GBM disease (D); virtually negative staining for C3 in pauci-immune GN (E). GBM, glomerular basement membrane; GN, glomerulonephritis; ICGN, immune-complex glomerulonephritis.

of the glomerular damage. It is perhaps also because LN involves so many different autoantibodies and immune complexes acting together that a huge variety of glomerular lesions are encountered.<sup>10 11</sup> Some of these have a very close relation to light

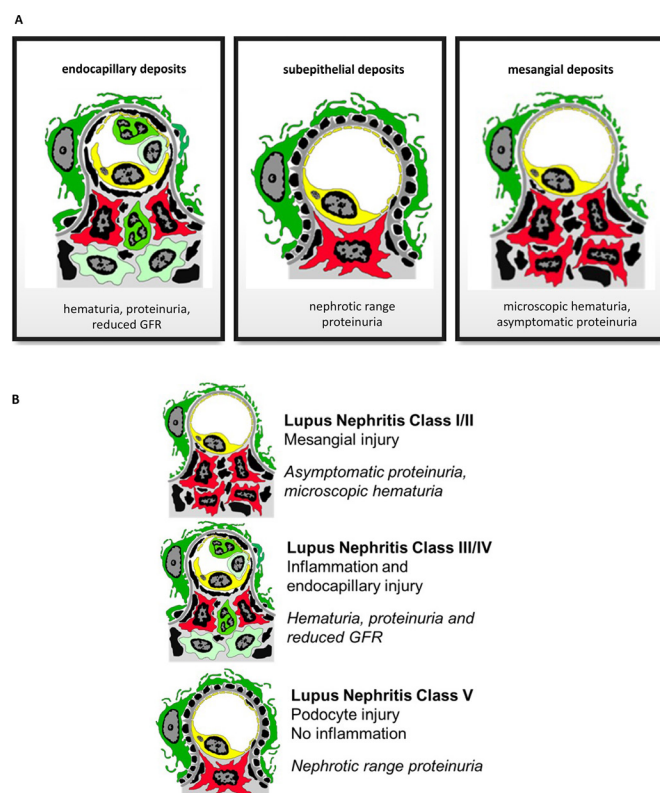


**Figure 2** Light microscopic lesions may look fairly identical in different renal diseases. Knowledge on the true nature of the deposits in combination with their role in pathogenetic mechanisms that is partly dependent on their location helps to diagnose the diseases that we focus on in this review. Mesangial hypercellularity in IgA nephropathy (A) and lupus nephritis class II (B): lesions are similar by light microscopy and caused by deposits in mesangial areas. The true nature of the deposits is, however, different in the two diseases. Necrotising glomerulonephritis with crescent formation in AAGN (C) and lupus nephritis class III (D): lesions are similar by light microscopy, but are caused by subendothelial deposits in lupus nephritis whereas in AAGN, a class II hypersensitivity reaction driven by ANCA is initiating the inflammatory response leading to disruption of the glomerular basement membrane and release of cytokines into Bowman's space giving rise to crescent formation. Wire loops in lupus nephritis class IV (E) are formed by massive subendothelial deposits. Cryoglobulins deposit at the same site, although they more often organise in nodular formations that are known as pseudothrombi (F). Only by EM, their true nature is further identified. AAGN, ANCA-associated glomerulonephritis; ANCA, anti-neutrophil cytoplasmic antibody; EM, electron microscopy.



**Figure 3** Full house IF-pattern in a renal biopsy with lupus nephritis class II. There is full house positivity for IgA (A), IgG (B), IgM (C), C3 (D), C1q (E) and light chains (kappa (F); lambda (G)). All stainings show mesangial pattern but in varying intensities. IF, immunofluorescence.

microscopic lesions, for instance, wire loops (figure 2F) and pseudothrombi that are almost synonymous with the subendothelial deposits themselves. A recent histopathologic subclassification indicated that the majority of global class IV LN present with a membranoproliferative glomerulonephritis (MPGN)-like pattern reflected by presence of global endocapillary hypercellularity, wire loops and double contours, while class III LN is characterised by segmental endocapillary hypercellularity and thus resembles a vasculitis-like pattern.<sup>12</sup> Membranous LN (class V, IF pattern shown in figure 1B) is characterised by subepithelial



**Figure 4** Location of deposits in capillary loop correlates strongly with clinical symptoms. Red cells: mesangium; dark green cells: podocytes; yellow cells: endothelium; deposits in black. Drawings of figures by Professor Charles Jennette. Presenting features (haematuria, proteinuria and reduced kidney function) depend on the location of deposits (A). All three features, endocapillary deposits, subepithelial deposits and mesangial deposits, are encountered in lupus nephritis (B).

deposits which involve more than half of capillary loops of more than half of glomeruli with mesangial deposits.<sup>13</sup>

Disease antigens have been identified in class V LN. Exostosin 1 and exostosin 2 are present in around a third of the patients, and these patients present at a younger age and with less severe chronic damage on kidney biopsy.<sup>14</sup> Another identified antigen is neural cell adhesion molecule 1, which is present in around 6.6% of cases with class V LN.<sup>15</sup>

### Cryoglobulinaemic glomerulonephritis

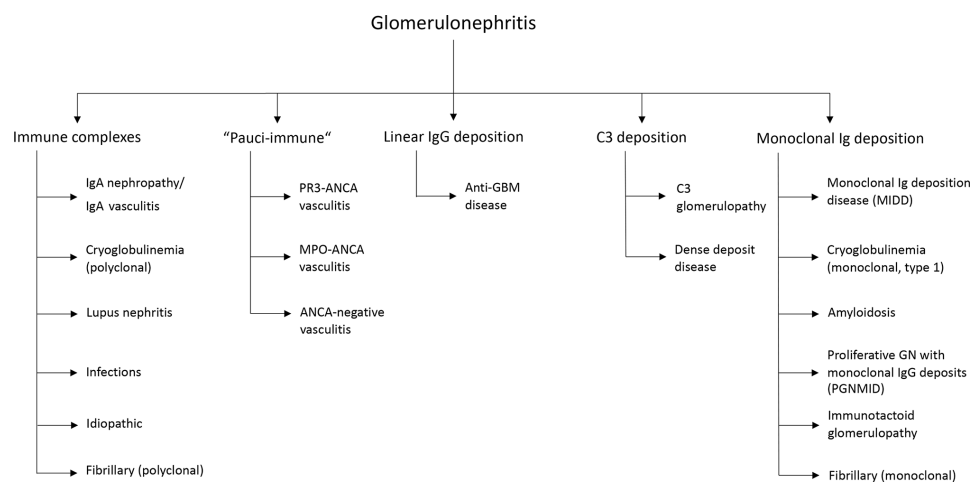
Initial presentation of cryoglobulinaemic disease differs among patients, and spans from relatively mild cases to life-threatening disease with a rapid decline in kidney function. Organ manifestations often result in significant morbidity and cumulative organ impairment.<sup>16</sup> Of the glomerular diseases that are discussed in this review, cryoglobulinaemic GN<sup>17</sup> is the only one for which EM is essential to the diagnosis. From a light microscopic perspective, cryoglobulinaemic GN shares the most similarities with LN class IV. Lupus-like lesions such as pseudothrombi, and lesions similar to wire loops (figure 2E) are revealed by EM to consist of cryoglobulins, which show a microtubular substructure, rather than the more regular deposits that are found in LN. Endocapillary and mesangial cell proliferation, thickening of the GBM and subendothelial deposits resembling a MPGN-pattern can be indicative of cryoglobulinaemic GN. A third of the biopsies also reveal vasculitis of small-sized and medium-sized arteries with fibrinoid necrosis.<sup>18</sup> From a clinical perspective, cryoglobulins have been subcategorised in types 1, 2 and 3, but all of these may contain IgG and/or IgM and lead to similar findings by EM. Types 1–3 are almost indistinguishable according to the findings in the biopsy, although characterisation by IF (figure 1C) may be helpful as type 1 characteristically should have a light chain restriction, type 2 an IgM kappa predominance, whereas type 3 has mixed immunoglobulins.

### Anti-GBM disease

Anti-GBM disease presents with kidney disease in almost all patients, and is characterised by a rapid deterioration of kidney function. Many patients present with dialysis-dependency, and the presence of oliguria and especially anuria portends a risk factor for remaining on dialysis even after immediate treatment initiation.

Presence of anti-GBM antibodies can be detected in blood of most patients, or by direct IF on a biopsy specimen. The typical finding on direct IF is a linear IgG staining along the GBM, which is often accompanied by some degree of complement deposition.<sup>19</sup> This finding by IF (as depicted in figure 1D) strikingly reveals the pathogenetic mechanism of anti-GBM disease because it represents binding of autoantibodies to the well characterised autoantigen expressed in the basement membrane.<sup>20</sup> By light microscopy, anti-GBM disease is characterised by a crescentic glomerulonephritis which develops after destruction of the GBM due to the inflammatory response that evolves from IgG binding. Because this is an acute process by which the entire GBM of all glomeruli is being targeted in a relatively short time, typically, cellular crescents are present in the majority of glomeruli in the renal biopsy. It is generally acknowledged that if 100% of glomeruli in a renal biopsy have crescents, outcome is poor. This rule of thumb is based on a series of 71 patients: in this study, no patient who required haemodialysis and had 100% crescents on kidney biopsy recovered renal function.<sup>21</sup> In a recent study of 123 patients, it was shown that there is some variability in the histological patterns of anti-GBM disease. For instance, younger patients in particular would still have a proportion of normal glomeruli in the biopsy,<sup>22</sup> and variation in the glomerular lesion also in relation to chronic lesions such as fibrous crescents and global glomerulosclerosis was encountered. In this study, dialysis independency at presentation, presence of normal glomeruli and a relatively mild interstitial infiltrate were associated with a favourable outcome. A variant of anti-GBM disease, ‘double positive’ disease marked by presence of circulating ANCA, directed predominantly to MPO is present in 10%–50% of patients with anti-GBM. While the renal presentation of these patients is similar to isolated anti-GBM disease, patients with ‘double positive’ disease often have a relapsing disease course akin to ANCA vasculitis and require maintenance immunosuppression.

Unlike other diseases presenting with detectable antibodies (dsDNA in LN, ANCA in ANCA-GN), the titres of anti-GBM antibodies have a relevance in guiding immunosuppressive therapy. The ultimate therapeutic goal is reduction of circulating anti-GBM antibodies to a normal range or a range which is considered ‘non-toxic’,<sup>23</sup> the latter depending on the specific assay used to detect antibodies.



**Figure 5** The expanding spectrum of diseases summarised under the umbrella of glomerulonephritis. A subclassification is based on predominant histologic manifestation, that is, deposition of immune complexes. A minority of these diseases are under a shared care between rheumatologists and nephrologists, but often require an interdisciplinary approach (ie, amyloidosis with haematologists and cardiologists). ANCA, anti-neutrophil cytoplasmic antibody; GBM, glomerular basement membrane; MPO, myeloperoxidase; PR3, proteinase 3.

### ANCA-associated vasculitis

In ANCA-associated vasculitis, kidney disease is most frequent in microscopic polyangiitis (>80%), while less frequent in granulomatosis with polyangiitis (around 60%) and in eosinophilic granulomatosis with polyangiitis (around 25%–30%). Kidney disease can present as slowly progressive<sup>24</sup> over time or as a rapidly progressive glomerulonephritis, characterised by a rapid deterioration of kidney function.<sup>25</sup>

ANCA bind to peripheral neutrophil epitopes, which through a complex interaction between triggered neutrophils and the endothelium ensues in what we recognise as vasculitis.<sup>26</sup> If this damage occurs in glomeruli, the inflammatory process destroys the capillary loops resulting in fibrinoid necrosis, and consequently, inflammatory mediators will leak into the Bowman's space, resulting in proliferation of parietal epithelial cells eventually forming crescents (figure 2C). In ANCA-GN, however, antibodies succumb in the inflammation and only the bystander effect of complement activation is observed in some biopsies.

ANCA-GN is characterised by the virtual absence of deposits ('pauci-immune', figure 1E). However, by EM, studies showed that immune complex deposits were found in half of the patients and a majority (87% of 126 patients) showed positive IF findings for at least one immunoglobulin or complement component, even though staining was in general subdued.<sup>27</sup> Patients with MPO-ANCA vasculitis and IgG deposits tend to have poorer kidney survival.<sup>28</sup> In-depth analysis found a variable degree of complement deposition reflecting involvement of the alternative complement pathway, with a higher frequency in MPO-ANCA vasculitis compared with PR3-ANCA vasculitis.<sup>29,30</sup> Glomerular C3d staining not only associated with severity of kidney function impairment and lower response rates to therapy,<sup>31</sup> but also formation of cellular crescents.<sup>29</sup>

Numerous other glomerulonephritides can be encountered by the nephrologist and are summarised according to the presence of immune deposits/complexes in figure 5. Many of these, however, fall outside the realm of the rheumatologist.

### CIRCULATING IMMUNE COMPLEXES AND LOCATION OF IMMUNE DEPOSITS/COMPLEXES WITHIN GLOMERULAR STRUCTURES

Once there are circulating immune complexes (CIC), it is likely that they will deposit in the kidney, and this process has been linked to disease pathogenesis in several autoimmune disorders. In SLE, the amount of CIC correlates with disease activity and kidney involvement, and changes of CIC levels predict therapy response.<sup>32</sup> In most cases with cryoglobulinaemia (especially types II and III), the cryoglobulins have rheumatoid factor activity, that in turn enables them to form immune complexes.<sup>33</sup> In IgAV, IgA1-containing CICs are usually detected, which are larger in size compared with those detected in IgAN.<sup>34</sup> ANCA-associated vasculitis is considered an antibody-mediated disorder, and it remains obscure if there is a role of CICs, which has recently been reported in a small study from Japan.<sup>35</sup> Irrespective of the nature of the deposits, their location is closely associated with clinical symptoms, as depicted in figure 4. Mesangial deposits will lead to hypercellularity of mesangial fields and broadening of the mesangial matrix. This is clinically associated with haematuria: through expansion of mesangial areas, breaks in the basement membrane will ensue leading to loss of erythrocytes in Bowman's space. Subepithelial deposits will eventually lead to spike formation: rearrangement of the basement membrane around the deposits that look similar to spikes in a silver staining. Only subendothelial deposits will

elicit an inflammatory response that co-occurs with complement activation, by which inflammatory cells such as neutrophils will be attracted that will try to get rid of the deposits, but in the process, will destroy parts of the basement membrane through release of inflammatory enzymes. Because subepithelial deposits, and to some extent mesangial deposits are further removed from the immune system they will elicit a less severe inflammatory response than subendothelial deposits.

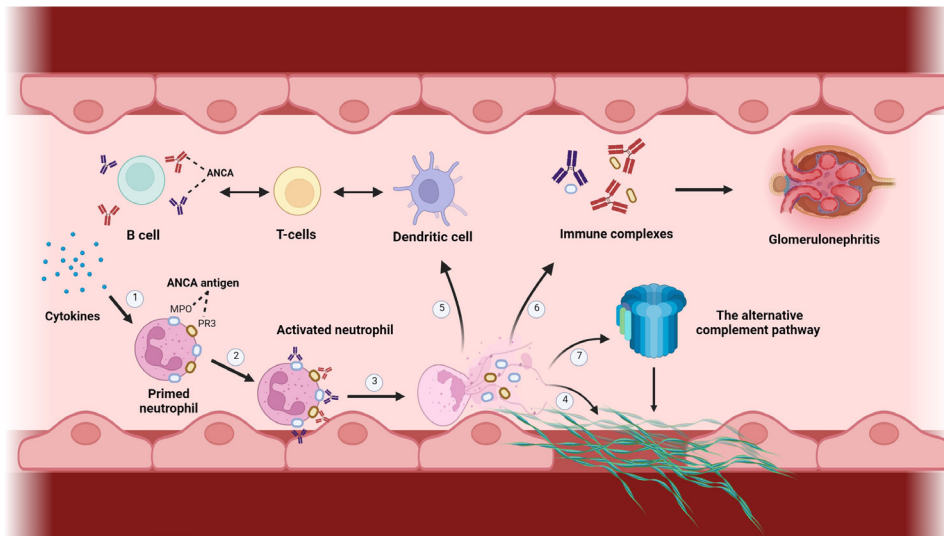
For this review, we have focused on five renal diseases which are under the 'shared care' of rheumatologists and nephrologists to show the many facets of ICGN and how they relate to our insights into the pathogenesis of disease, diagnosis and treatment. A selection of different glomerular lesions is given in figure 2A–F.

### HOW DO IMMUNE COMPLEXES/CELLS DAMAGE THE KIDNEY?

The filtration barrier comprised of endothelium, GBM and podocytes which are the main target of inflammatory and non-inflammatory injury in glomerular disease. Most exogenous non-renal antigens collect in the subendothelial space and mesangial areas that are close to the circulation allowing antibody binding, production of anaphylatoxins and recruitment of inflammatory cells.<sup>36</sup> The complement system, neutrophil/macrophage stimulation and the induction of several cytokines/chemokines lead to tissue inflammation, and thus damage of kidney structures.<sup>37</sup> Additionally, mesangial cells and endothelial cells are activated by complement and deposition of membrane attack complex results in mesangial expansion, endothelial cell detachment and apoptosis.<sup>38</sup> ICGNs are histologically characterised by distinct patterns of deposition of immune deposits mostly accompanied by complement deposits, especially C3 and C1q. Immune deposits usually precede the appearance of histological evidence for glomerular lesions.<sup>6</sup>

Among the many factors contributing to autoimmunity, neutrophil extracellular traps (NETs) have a prominent role in ICGN. NETs contain neutrophilic granules, histones and decondensed chromatin which also contain autoantigens. NETosis, a process by which chromatin is released, uncovers enzymes and autoantigens to the extracellular circulation in an inflammatory context (figure 6). Blood of patients with LN and AAV demonstrate increased numbers of unique low-density granulocytes which have high NET-generating capacity and also display impaired NET degradation due to the presence of DNase1 inhibitors or anti-NET antibodies. NETs colocalise with immune deposits and a failure to degrade NETs, either due to presence of DNase1 inhibitors or anti-NET antibodies, promotes development of LN.<sup>7</sup> At present, it is unclear if NETosis directly contributes to disease pathogenesis or if it is a 'bystander' reaction of the inflammatory response.<sup>39</sup> Therapeutic trials with agents such as CIT-013<sup>40</sup> to inhibit NET formation and promote NET clearance will help to clarify the role of NETs in autoimmunity.

Further important steps take place during the natural course of ICGN, leading to progression of kidney lesions. A decrease in *Dnase1* gene transcription and an accumulation of activated caspase 3-positive cells in kidney coincides with transition from a mesangial to a membranoproliferative pattern of LN indicative of disease progression.<sup>41,42</sup> Among other factors, megin, a serine protease inhibitor, is involved in mesangial matrix expansion. The increase of mesangial cells was also linked to an augmented deposition of immune complexes, immunoglobulins and complement components, as highlighted by the presence of electron-dense deposits in transgenic mice as early as at



**Figure 6** The role of neutrophil extracellular traps in immune mediated kidney disease. NETosis plays a critical role in most autoimmune kidney diseases and are involved in many processes perpetuating inflammation, eventually leading to a humoral immune response, further the deposition of immune deposits and complexes, which then leads to the onset of glomerulonephritis.

20 weeks. A potential explanation for this role of megsin is the inhibitory effect of megsin on plasmin activity. The plasminogen activator/plasmin cascade plays an important role in degrading matrix components, and this might be disturbed by the presence of megsin–plasmin complexes.<sup>45</sup>

The evolution of crescent formation in the context of MPGN requires alterations of the complement system, as only double-knockout factor H mice developed crescents.<sup>44</sup> Complement alternative pathway anaphylatoxin C5a plays an essential role in neutrophil influx in a cryoglobulin-induced glomerulonephritis model and has shown a crucial involvement in the pathogenesis of several autoimmune diseases including AAV.<sup>45 46</sup> The absence of C5 in an ICGN model resulted in reduced crescent formation and deposition of immune complexes.<sup>47</sup> The complement system plays a pivotal role in perpetuating inflammatory responses. In C3-deficient mice a pronounced accumulation of immune complexes and a progressive decline in kidney function was reported after injection of anti-GBM antibodies.<sup>48</sup> Lower C3 levels in circulation of patients with AAV are associated not only with reduced patient and kidney survival, but also indicates a proportion of patients at risk to develop CKD.<sup>49 50</sup> Additionally, C3 deposits in the kidney are associated with worse renal and patient survival.<sup>51</sup>

Importantly, the presence of immune complexes in glomeruli alone is not sufficient to induce severe nephritis in a LN mouse model.<sup>52</sup> Rather, there is a delicate interplay between inflammatory immune responses and inhibitory pathways, but once an imbalance in favour of inflammation occurs, kidney injury evolves. In addition, tissue damage caused by immune complexes is dependent on the biochemical and biologic properties of the antigen and antibody and the relative concentration of the antigen and antibody in the circulation and tissues. Thus, the sole presence of immune deposits/complexes might not be capable to induce related tissue lesions, but rather the concomitant induction of inflammatory pathways involving the innate and adaptive immune system leads to tissue injury.

#### PRESENCE OF IMMUNE DEPOSITS/COMPLEXES AND PROGNOSTICATION/THERAPEUTIC RESPONSE

The presence, location and type of immune deposits in the kidney is directly associated with the pattern and severity of

glomerular injury and with clinical features and outcome. In LN, membranous or class V LN has better prognosis compared with the class III and IV despite more severe proteinuria,<sup>53</sup> while in IgAV, the deposition of the terminal complement complex colocalised with IgA is associated with decreased kidney function and nephrotic syndrome,<sup>54</sup> which resulted in a significant increase in prescription of immunosuppression in this cohort.

Nephritogenicity in anti-GBM disease is characterised by production of pathogenic antibodies against constituents of the basement membrane, comprising the non-collagenous domain of  $\alpha 3$  chain of type IV collagen. Alongside linear IgG deposition on GBM, patients with anti-GBM typically present with cellular crescents present in most glomeruli, which directly predicts overall renal survival.<sup>23</sup> Our understanding of kidney histology change over time is limited to ‘atypical’ anti-GBM disease, but a transition from acute lesions to chronic damage (presence of global glomerulosclerosis) needs to be expected in cases with severe kidney disease.

The inflammatory response seen in many diseases with immune deposits will eventually lead to chronic lesions with global glomerulosclerosis and interstitial fibrosis (IF) as characteristic features of common final pathways of kidney damage, if the respective processes are not terminated early.<sup>26 55</sup> Repeat kidney biopsy (either protocol biopsies or as per indication) indicated that the number of globally sclerosed glomeruli and the proportion of patients with severe IF/tubular atrophy (IF/TA) increased in ANCA-GN with evidence of active disease despite immunosuppressive treatment.<sup>56</sup> This indicates that despite treatment and clinical remission, sub-clinical inflammation and disease progression may still progress unnoticed. In line, protocol biopsies in LN indicate an increase of the Chronicity Index (CI), IF/TA and glomerulosclerosis over time. Higher percentage of glomerulosclerosis and IF/TA, and higher CI are associated with CKD progression.<sup>57</sup> A possible explanation, especially in patients that lack response to therapy, is that persistent glomerular overexpression of interferon and JAK/STAT signalling is found in transcriptome analyses in non-responding patients in comparison to those achieving remission.<sup>58</sup> Single cell RNA sequencing revealed local activation of B cells, an interferon response of most cells, and a crucial role of chemokine receptors in LN. More importantly, these transcripts in urine and kidney

correlated with each other and reflect immunological activity contributing to kidney involvement.<sup>59</sup> This would allow to reduce the number of kidney biopsies, which is not well accepted by most patients. A further step towards prediction of kidney disease and specific lesions is a machine learning approach. Combination of RNA sequencing with demographic and laboratory parameters had an accuracy of 81.7% to predict active LN as compared with patients without LN, and this model was influenced by dsDNA titers, age, male sex and the expression of the *PTPRO* and *IL10RA* genes.<sup>60</sup> Disease flares of LN could be predicted by six variables, including partial remission, presence of endocapillary hypercellularity (at baseline biopsy), age, serum albumin, dsDNA and serum complement C3,<sup>61</sup> thus machine learning approaches might also displace the need for repeated kidney biopsies in LN.

Treatment approaches of immune-mediated diseases should aim to immediately abrogate the transition to irreversible damage. Uncertainty, however, exists if resolution of immune deposits on initiation of immunosuppression plays a role in this context. In repeated kidney biopsies of patients with membranous LN, the resorption of immune deposits was seen more frequently in patients treated with rituximab compared with conventional immunosuppression, and this was associated with a favourable treatment response.<sup>62</sup> The utility of repeat kidney biopsies to evaluate the role of persistent immune deposits together with the histological alterations in particular in relation to chronicity, clearly warrants further study. Novel methods may allow prediction of progression of specific lesions, and will incorporate multiple 'omics' approaches and machine learning algorithms.

## NEW THERAPEUTIC AVENUES

Newer substances specifically tackling inflammatory pathways are needed to mitigate the transition of acute changes to chronic damage seen on repeat kidney biopsies.

Imlifidase (IdeS, IgG-degrading enzyme of *Streptococcus pyogenes*) is capable to cleave IgG from circulation within minutes<sup>63</sup> and thus is a therapeutic option for IgG antibody-mediated diseases, such as anti-GBM disease, renal transplantation, but also Guillain-Barre syndrome. Imlifidase was tested in a mouse model of anti-GBM disease. Kidney-bound IgG was cleaved by IdeS by approximately 93.4%, and this also reduced the glomerular influx of leukocytes by 62% and the staining of C3 and C1q.<sup>64</sup> A phase IIa trial in anti-GBM disease recruiting 15 patients with severely impaired kidney function found that 10 patients at 6 months were free of dialysis with a median GFR of 27 mL/min/1.73 m<sup>2</sup>.<sup>23</sup> A phase III trial in anti-GBM disease is in the set-up phase. Some of the patients in the phase IIa trial were double-positive (anti-GBM and ANCA), and imlifidase led to a similar complete disappearance of ANCA after therapy. A single case report of a patient with severe respiratory compromise due to AAV was treated with imlifidase and weaned off venovenous extracorporeal membrane oxygenation after therapy.<sup>66</sup> Further developments in antibody-mediated diseases might be expected.

Avacopan, which blocks the C5aR1, ameliorated the formation of crescents in a mouse model of MPO-ANCA vasculitis in a dose-dependent fashion. In addition, significant reductions of haematuria and proteinuria were reported.<sup>67</sup> In the phase II trial CLEAR both avacopan groups had a more rapid decline in albuminuria and overall disease activity.<sup>68</sup> The phase III trial ADVOCATE randomised 331 patients to either avacopan plus standard of care or prednisone plus standard of care. The composite

primary endpoint of remission at week 26 and sustained remission at week 52 were reached by 72.3% versus 70.1% and 65.7% versus 54.9% participants in the avacopan and prednisone groups, respectively. Patients in the avacopan group had higher albuminuria values at baseline and a significant decrease of albuminuria by week 4, but there was no difference of albuminuria change between groups at week 52. A significant difference in change of eGFR between groups was observed at week 26 and week 52, with an increase of 7.3 mL/min/1.73 m<sup>2</sup> in the avacopan and 4.1 mL/min/1.73 m<sup>2</sup> in the prednisone arm at week 52, respectively.<sup>69</sup> The C5aR1 not only primes neutrophils for activation by ANCA, it further perpetuates the generation of ANCA, but also leads to neutrophil retention and reactive oxygen species bursts within glomerular capillaries.<sup>70</sup> The C5aR1 is expressed by other inflammatory cells with relevance in ANCA-GN, such as monocytes and macrophages.<sup>71</sup> Information about histology and especially repeat biopsies, which was optional in the ADVOCATE trial, are not published thus far. Other complement inhibitors, such as iptacopan, an oral factor B inhibitor, are under investigation in several glomerular diseases, and it seems that targeting complement pathways will revolutionise management strategies in kidney diseases. However, it is unclear so far if these therapies also reduce immune deposits in kidney tissue.

## CONCLUSION

In summary, immune deposits in the kidney are a key feature of manifestations of autoimmune kidney diseases. There is, however, still limited data to support their pathogenetic evidence, but in general the location, the density and the property of deposits predict clinical presentation and disease severity. Experimental therapies have not specifically been developed to tackle immune deposits. Ultimately, future research will need to involve protocol kidney biopsies, multi-omics approaches and artificial intelligence to assess time-dependent changes of immune deposits potentially indicating response to therapy.

**Correction notice** This article has been corrected since it published Online First. The third author affiliation has been updated.

**Contributors** All four authors have contributed to the manuscript.

**Funding** The authors have not declared a specific grant for this research from any funding agency in the public, commercial or not-for-profit sectors.

**Competing interests** AK received consulting fees from Vifor Pharma, Otsuka, Alexion, UriSalt, Delta4 and Catalyst Biosciences. IB received consulting fees from Boehringer-Ingelheim, Novartis, Catalyst Biosciences and Toleranzia. DG received consulting fees from ChemoCentryx. MS received consulting fees from Astra Zeneca, Boehringer-Ingelheim, Novartis and Otsuka.

**Patient consent for publication** Not applicable.

**Ethics approval** Not applicable.

**Provenance and peer review** Not commissioned; externally peer reviewed.

## ORCID iDs

Andreas Kronbichler <http://orcid.org/0000-0002-2945-2946>

Marcus Säemann <http://orcid.org/0000-0003-2316-449X>

## REFERENCES

- 1 Mayadas TN, Tsokos GC, Tsuboi N. Mechanisms of immune complex-mediated neutrophil recruitment and tissue injury. *Circulation* 2009;120:2012–24.
- 2 Suurmond J, Diamond B. Autoantibodies in systemic autoimmune diseases: specificity and pathogenicity. *J Clin Invest* 2015;125:2194–202.
- 3 Pickering MC, D'Agati VD, Nester CM, et al. C3 glomerulopathy: consensus report. *Kidney Int* 2013;84:1079–89.
- 4 Peruzzi L, Coppo R. Iga vasculitis nephritis in children and adults: one or different entities? *Pediatr Nephrol* 2021;36:2615–25.
- 5 Pillebout E, Sunderkötter C. Iga vasculitis. *Semin Immunopathol* 2021;43:729–38.



- 6 Ge Y, Jiang C, Sung S-SJ, *et al.* Cgnz1 allele confers kidney resistance to damage preventing progression of immune complex-mediated acute lupus glomerulonephritis. *J Exp Med* 2013;210:2387–401.
- 7 Hakkim A, Fürnrohr BG, Amann K, *et al.* Impairment of neutrophil extracellular trap degradation is associated with lupus nephritis. *Proc Natl Acad Sci U S A* 2010;107:9813–8.
- 8 Fanouriakis A, Tziolos N, Bertsias G, *et al.* Update on the diagnosis and management of systemic lupus erythematosus. *Ann Rheum Dis* 2021;80:14–25.
- 9 Bajema IM, Wilhelmus S, Alpers CE, *et al.* Revision of the International Society of Nephrology/Renal pathology Society classification for lupus nephritis: clarification of definitions, and modified National Institutes of health activity and chronicity indices. *Kidney Int* 2018;93:789–96.
- 10 Kudose S, Santoriello D, Bomback AS, *et al.* Sensitivity and specificity of pathologic findings to diagnose lupus nephritis. *Clin J Am Soc Nephrol* 2019;14:1605–15.
- 11 Rijink EC, Teng YKO, Wilhelmus S, *et al.* Clinical and histopathologic characteristics associated with renal outcomes in lupus nephritis. *Clin J Am Soc Nephrol* 2017;12:734–43.
- 12 Bolognesi MM, Capitoli G, Galimberti S, *et al.* Dissecting the histological features of lupus nephritis highlights new common patterns of injury in class III/IV. *Ann Rheum Dis* 2022;81:1704–11.
- 13 Lusco MA, Fogo AB, Najafian B, *et al.* AJKD atlas of renal pathology: membranous lupus nephritis, ISN/RPS class V. *Am J Kidney Dis* 2017;70:e13–15.
- 14 Ravindran A, Casal Moura M, Ferverza FC, *et al.* In patients with membranous lupus nephritis, Exostosin-Positivity and Exostosin-Negativity represent two different phenotypes. *J Am Soc Nephrol* 2021;32:695–706.
- 15 Caza TN, Hassen SI, Kuperman M, *et al.* Neural cell adhesion molecule 1 is a novel autoantigen in membranous lupus nephritis. *Kidney Int* 2021;100:171–81.
- 16 Muchtar E, Magen H, Gertz MA. How I treat cryoglobulinemia. *Blood* 2017;129:289–98.
- 17 Chen Y-P, Cheng H, Rui H-L, *et al.* Cryoglobulinemic vasculitis and glomerulonephritis: concerns in clinical practice. *Chin Med J* 2019;132:1723–32.
- 18 Kiremitci S, Calayoglu R, Ensari A, *et al.* Pathologist's puzzle: membranoproliferative glomerulonephritis-like features in cryoglobulinemic glomerulonephritis. *Pathol Res Pract* 2012;208:254–8.
- 19 Hellmark T, Segelmark M. Diagnosis and classification of Goodpasture's disease (anti-GBM). *J Autoimmun* 2014;48–49:108–12.
- 20 McAdoo SP, Pusey CD. Anti-Glomerular basement membrane disease. *Clin J Am Soc Nephrol* 2017;12:1162–72.
- 21 Levy JB, Turner AN, Rees AJ, *et al.* Long-Term outcome of anti-glomerular basement membrane antibody disease treated with plasma exchange and immunosuppression. *Ann Intern Med* 2001;134:1033–42.
- 22 van Daalen EE, Jennette JC, McAdoo SP, *et al.* Predicting outcome in patients with anti-GBM glomerulonephritis. *Clin J Am Soc Nephrol* 2018;13:63–72.
- 23 Shin JI, Geetha D, Szpirt WM, *et al.* Anti-Glomerular basement membrane disease (Goodpasture disease): from pathogenesis to plasma exchange to ides. *Ther Apher Dial* 2022;26:24–31.
- 24 Trivioli G, Gopaluni S, Urban ML, *et al.* Slowly progressive anti-neutrophil cytoplasmic antibody-associated renal vasculitis: clinico-pathological characterization and outcome. *Clin Kidney J* 2021;14:332–40.
- 25 Geetha D, Jefferson JA. Anca-Associated vasculitis: core curriculum 2020. *Am J Kidney Dis* 2020;75:124–37.
- 26 Lindquist JA, Hildebrandt J, Philipsen L, *et al.* Immune complexes and complexity: investigating mechanisms of renal disease. *Int Urol Nephrol* 2017;49:735–9.
- 27 Haas M, Eustace JA. Immune complex deposits in ANCA-associated crescentic glomerulonephritis: a study of 126 cases. *Kidney Int* 2004;65:2145–52.
- 28 Lin W, Shen C, Zhong Y, *et al.* Glomerular immune deposition in MPO-ANCA associated glomerulonephritis is associated with poor renal survival. *Front Immunol* 2021;12:625672.
- 29 Hillhorst M, van Paassen P, van Rie H, *et al.* Complement in ANCA-associated glomerulonephritis. *Nephrol Dial Transplant* 2017;32:1302–13.
- 30 Gou S-J, Yuan J, Wang C, *et al.* Alternative complement pathway activation products in urine and kidneys of patients with ANCA-associated GN. *Clin J Am Soc Nephrol* 2013;8:1884–91.
- 31 Villacorta J, Diaz-Crespo F, Acevedo M, *et al.* Glomerular C3d as a novel prognostic marker for renal vasculitis. *Hum Pathol* 2016;56:31–9.
- 32 Abrass CK, Nies KM, Louie JS, *et al.* Correlation and predictive accuracy of circulating immune complexes with disease activity in patients with systemic lupus erythematosus. *Arthritis Rheum* 1980;23:273–82.
- 33 Roccatello D, Saadoun D, Ramos-Casals M, *et al.* Cryoglobulinaemia. *Nat Rev Dis Primers* 2018;4:11.
- 34 Hillhorst M, van Paassen P, van Breda Vriesman P, *et al.* Immune complexes in acute adult-onset Henoch-Schönlein nephritis. *Nephrol Dial Transplant* 2011;26:3960–7.
- 35 Kojima T, Inoue D, Wajima T, *et al.* Circulating immune-complexes and complement activation through the classical pathway in myeloperoxidase-ANCA-associated glomerulonephritis. *Ren Fail* 2022;44:714–23.
- 36 Quigg RJ. Complement and autoimmune glomerular diseases. *Curr Dir Autoimmun* 2004;7:165–80.
- 37 Noronha IL, Fujihara CK, Zatz R. The inflammatory component in progressive renal disease—are interventions possible? *Nephrol Dial Transplant* 2002;17:363–8.
- 38 Belmont HM, Buyon J, Giorno R, *et al.* Up-regulation of endothelial cell adhesion molecules characterizes disease activity in systemic lupus erythematosus. The Schwartzman phenomenon revisited. *Arthritis Rheum* 1994;37:376–83.
- 39 Jorch SK, Kubers P. An emerging role for neutrophil extracellular traps in noninfectious disease. *Nat Med* 2017;23:279–87.
- 40 Chirivi RGS, van Rosmalen JWG, van der Linden M, *et al.* Therapeutic AcP inhibits net formation: a potential therapy for neutrophil-mediated inflammatory diseases. *Cell Mol Immunol* 2021;18:1528–44.
- 41 Sereidkina N, Zykova SN, Rekvig OP. Progression of murine lupus nephritis is linked to acquired renal Dnase1 deficiency and not to up-regulated apoptosis. *Am J Pathol* 2009;175:97–106.
- 42 Zykova SN, Tveita AA, Rekvig OP. Renal Dnase1 enzyme activity and protein expression is selectively shut down in murine and human membranoproliferative lupus nephritis. *PLoS One* 2010;5:e12096.
- 43 Miyata T, Inagi R, Nangaku M, *et al.* Overexpression of the serpin meginin induces progressive mesangial cell proliferation and expansion. *J Clin Invest* 2002;109:585–93.
- 44 Alexander JJ, Pickering MC, Haas M, *et al.* Complement factor H limits immune complex deposition and prevents inflammation and scarring in glomeruli of mice with chronic serum sickness. *J Am Soc Nephrol* 2005;16:52–7.
- 45 Trendelenburg M, Fossati-Jimack L, Cortes-Hernandez J, *et al.* The role of complement in cryoglobulin-induced immune complex glomerulonephritis. *J Immunol* 2005;175:6909–14.
- 46 Moiseev S, Lee JM, Zykova A, *et al.* The alternative complement pathway in ANCA-associated vasculitis: further evidence and a meta-analysis. *Clin Exp Immunol* 2020;202:394–402.
- 47 Falk RJ, Jennette JC. Immune complex induced glomerular lesions in C5 sufficient and deficient mice. *Kidney Int* 1986;30:678–86.
- 48 Sheerin NS, Abe K, Risley P, *et al.* Accumulation of immune complexes in glomerular disease is independent of locally synthesized C3. *J Am Soc Nephrol* 2006;17:686–96.
- 49 Crnogorac M, Horvatic I, Kacinari P, *et al.* Serum C3 complement levels in ANCA associated vasculitis at diagnosis is a predictor of patient and renal outcome. *J Nephrol* 2018;31:257–62.
- 50 Kronbichler A, Shin JI, Lee KH, *et al.* Clinical associations of renal involvement in ANCA-associated vasculitis. *Autoimmun Rev* 2020;19:102495.
- 51 Oba R, Kanzaki G, Sasaki T, *et al.* Long-Term renal survival in antineutrophil cytoplasmic antibody-associated glomerulonephritis with complement C3 deposition. *Kidney Int Rep* 2021;6:2661–70.
- 52 Clynes R, Dumitru C, Ravetch JV. Uncoupling of immune complex formation and kidney damage in autoimmune glomerulonephritis. *Science* 1998;279:1052–4.
- 53 Parodis I, Tamirou F, Houssiau FA. Prediction of prognosis and renal outcome in lupus nephritis. *Lupus Sci Med* 2020;7:e000389.
- 54 Dumont C, Mèrouani A, Ducruet T, *et al.* Clinical relevance of membrane attack complex deposition in children with IgA nephropathy and Henoch-Schönlein purpura. *Pediatr Nephrol* 2020;35:843–50.
- 55 LeBleu VS, Teng Y, O'Connell JT, *et al.* Identification of human epididymis protein-4 as a fibroblast-derived mediator of fibrosis. *Nat Med* 2013;19:227–31.
- 56 Chapman GB, Farrah TE, Chapman FA, *et al.* Utility of interval kidney biopsy in ANCA-associated vasculitis. *Rheumatology* 2022;61:1966–74.
- 57 Morales E, Trujillo H, Bada T, *et al.* What is the value of repeat kidney biopsies in patients with lupus nephritis? *Lupus* 2021;30:25–34.
- 58 Parikh SV, Malvar A, Song H, *et al.* Molecular profiling of kidney compartments from serial biopsies differentiate treatment responders from non-responders in lupus nephritis. *Kidney Int* 2022;102:845–65.
- 59 Arazi A, Rao DA, Berthier CC, *et al.* The immune cell landscape in kidneys of patients with lupus nephritis. *Nat Immunol* 2019;20:902–14.
- 60 Frangou E, Garantzios P, Grigoriou M, *et al.* Cross-species transcriptome analysis for early detection and specific therapeutic targeting of human lupus nephritis. *Ann Rheum Dis* 2022;81:1409–19.
- 61 Chen Y, Huang S, Chen T, *et al.* Machine learning for prediction and risk stratification of lupus nephritis renal flare. *Am J Nephrol* 2021;52:152–60.
- 62 Zickert A, Lannfelt K, Schmidt Mende J, *et al.* Resorption of immune deposits in membranous lupus nephritis following rituximab vs conventional immunosuppressive treatment. *Rheumatology* 2021;60:3443–50.
- 63 Vindebro R, Spoerry C, von Pawel-Rammingsen U. Rapid IgG heavy chain cleavage by the streptococcal IgG endopeptidase ides is mediated by ides monomers and is not due to enzyme dimerization. *FEBS Lett* 2013;587:1818–22.
- 64 Yang R, Otten MA, Hellmark T, *et al.* Successful treatment of experimental glomerulonephritis with ides and EndoS, IgG-degrading streptococcal enzymes. *Nephrol Dial Transplant* 2010;25:2479–86.
- 65 Uhlin F, Szpirt W, Kronbichler A, *et al.* Endopeptidase Cleavage of Anti-Glomerular Basement Membrane Antibodies *in vivo* in Severe Kidney Disease: An Open-Label Phase 2a Study. *J Am Soc Nephrol* 2022;33:829–38.

- 66 Enghard P, Zickler D, Sonnemann J, *et al*. Imlifidase as novel treatment strategy in anti-neutrophil cytoplasmic antibody-induced pulmonary-renal syndrome. *Kidney Int* 2021;100:1344–5.
- 67 Xiao H, Dairaghi DJ, Powers JP, *et al*. C5A receptor (CD88) blockade protects against MPO-ANCA GN. *J Am Soc Nephrol* 2014;25:225–31.
- 68 Jayne DRW, Bruchfeld AN, Harper L, *et al*. Randomized trial of C5a receptor inhibitor Avacopan in ANCA-associated vasculitis. *J Am Soc Nephrol* 2017;28:2756–67.
- 69 Jayne DRW, Merkel PA, Schall TJ, *et al*. Avacopan for the treatment of ANCA-associated vasculitis. *N Engl J Med* 2021;384:599–609.
- 70 Dick J, Gan P-Y, Ford SL, *et al*. C5A receptor 1 promotes autoimmunity, neutrophil dysfunction and injury in experimental anti-myeloperoxidase glomerulonephritis. *Kidney Int* 2018;93:615–25.
- 71 Stewart BJ, Ferdinand JR, Young MD, *et al*. Spatiotemporal immune zonation of the human kidney. *Science* 2019;365:1461–6.
- 72 Hočevár A, Tomšič M, Jurčić V, *et al*. Predicting gastrointestinal and renal involvement in adult IgA vasculitis. *Arthritis Res Ther* 2019;21:302.
- 73 Gomes RC, Silva MF, Kozu K, *et al*. Features of 847 childhood-onset systemic lupus erythematosus patients in three age groups at diagnosis: a Brazilian multicenter study. *Arthritis Care Res* 2016;68:1736–41.
- 74 Alamoudi OSB, Attar SM. Pulmonary manifestations in systemic lupus erythematosus: association with disease activity. *Respirology* 2015;20:474–80.
- 75 Kusyairi KA, Gendeh BS, Sakthiswary R, *et al*. The spectrum of nasal involvement in systemic lupus erythematosus and its association with the disease activity. *Lupus* 2016;25:520–4.
- 76 Frittoli RB, Vivaldo JF, Costallat LTL, *et al*. Gastrointestinal involvement in systemic lupus erythematosus: a systematic review. *J Transl Autoimmun* 2021;4:100106.
- 77 Retamozo S, Brito-Zerón P, Bosch X, *et al*. Cryoglobulinemic disease. *Oncology* 2013;27:1098–105.