

Evaluation of abdominal gas by plain abdominal radiographs

Elizabeth Barba^{1,2}  | Dan M. Livovsky¹  | Lucia Relea³  | Luis G. Alcalá-Gonzalez¹  | Sergio Quiroga⁴  | Anna Accarino¹  | Fernando Azpiroz¹ 

¹Digestive System Research Unit, University Hospital Vall d'Hebron; Centro de Investigación Biomédica en Red de Enfermedades Hepáticas y Digestivas (Ciberehd); Universitat Autònoma de Barcelona, Bellaterra, Spain

²Gastroenterology Department, Hospital Clínic de Barcelona, Bellaterra, Spain

³Gastroenterology Department, Hospital Universitario Puerta de Hierro, Madrid, Spain

⁴Radiology Department, University Hospital Vall d'Hebron, Barcelona, Spain

Correspondence

Dan M. Livovsky, Digestive Diseases Institute, Shaare Zedek Medical Center, and Faculty of Medicine, Hebrew University of Jerusalem, Shmu'el Bait St 12, Jerusalem 9103102, Israel.
Email: danlivo@szmc.org.il

Present address

Dan M. Livovsky, Digestive Diseases Institute, Shaare Zedek Medical Center, and Faculty of Medicine, Hebrew University of Jerusalem, Jerusalem, Israel

Funding information

This work was supported in part by the Spanish Ministry of Economy and Competitiveness (Dirección General de Investigación Científica y Técnica, SAF 2016-76648-R); Ciberehd is funded by the Instituto de Salud Carlos III. Dan M. Livovsky received support from the Israeli Medical Association and from Israel Gastroenterological Association 2020 fellowship grants.

Abstract

Background: Our aim was to determine the reliability of plain abdominal radiographs for the evaluation of abdominal gas content in patients with functional digestive symptoms.

Methods: Abdominal CT scan scout views, mimicking a conventional plain abdominal radiograph, were obtained from 30 patients both during episodes of abdominal distension and basal conditions. Physicians ($n = 50$) were instructed to rate the estimated volume of gas in the 60 images presented in random sequence using a scale graded from 0 to ≥ 600 ml.

Key Results: The gas volumes estimated in the scout views differed from those measured by CT by a median of 90 (95% CI 70–102) ml, and the misestimation was not related to the absolute volume in the image. The accuracy of the observers, measured by their mean misestimation, was not related to their specialty or the training status (misestimation by 96 (95% CI 85–104) ml in staff vs 78 (70–106) ml in residents; $p = 0.297$). The accuracy was independent of the order of presentation of the images. Gas volume measured by CT in the images obtained during episodes of abdominal distension differed by a median of 39 (95% CI 29–66) ml from those during basal conditions, and this difference was misestimated by a median of 107 (95% CI 94–119) ml. The accuracy of these estimations was not related to the absolute gas volumes ($R = -0.352$; $p < 0.001$) or the magnitude of the differences.

Conclusions & Inferences: Plain abdominal radiographs have limited value for the evaluation of abdominal gas volume in patients with functional gut disorders.

KEYWORDS

abdominal CT imaging, abdominal distension, abdominal radiographs, intestinal gas

Elizabeth Barba, Dan M. Livovsky Shared first authorship

The work was conducted while at: Digestive System Research Unit Hospital General Vall d'Hebron 08035-Barcelona, Spain

This is an open access article under the terms of the [Creative Commons Attribution-NonCommercial-NoDerivs](https://creativecommons.org/licenses/by-nc-nd/4.0/) License, which permits use and distribution in any medium, provided the original work is properly cited, the use is non-commercial and no modifications or adaptations are made.

© 2022 The Authors. *Neurogastroenterology & Motility* published by John Wiley & Sons Ltd.

1 | INTRODUCTION

Patients with functional digestive symptoms, that is, without detectable organic disorders, frequently attribute their symptoms to excess abdominal gas. Indeed, gas-related symptoms, such as abdominal distension, bloating, flatulence, and borborygmi, affect a large proportion of patients with functional gut disorders and constitute their most bothersome complaint¹⁻³.

The clinical value of plain abdominal radiographs for the investigation of abdominal symptoms has been studied in the setting of the emergency department, and despite that its clinical value is not clear, plain abdominal radiographs remain one of the most common radiological examinations performed in this setting⁴⁻⁸; indeed, a study from Switzerland reported that only 12% of plain abdominal radiographs performed in 1997 patients (2.2% of all patients admitted to the ER) were actually indicated⁹. Correspondingly, an Italian study showed that plain abdominal radiographs were used in 38% of patients presenting with acute abdominal pain; the sensitivity for detecting acute disease was 28%⁵. Likewise, plain abdominal radiographs were performed in 42% of patients presenting to the ER with constipation, and the findings had no significant effect on management⁷.

In particular, the evaluation of patients with severe episodes of abdominal bloating and distension frequently includes plain abdominal radiographs; based on the subjective interpretation of the images, the symptoms in some patients are categorically attributed to excess of gas in the gut and are followed by sometimes drastic recommendations to reduce intestinal gas production. However, some studies objectively measuring intestinal gas content by means of abdominal CT in patients with functional gut disorders consistently found gas volumes within the normal range¹⁰⁻¹⁴. To address this discrepancy, our aim was to determine the reliability of plain abdominal radiographs for the evaluation of abdominal gas content in patients with functional gas-related symptoms. To this aim, we analyzed CT images obtained in previous studies in patients with functional gut disorders complaining of abdominal distension and compared the objective values of abdominal gas measured by CT to the subjective estimation of gas volumes from a plain AP projection of the same CT images by a cohort of physicians.

2 | MATERIAL & METHODS

2.1 | Study design

Prospective analysis of images obtained in previous studies ([ClinicalTrials.gov](https://clinicaltrials.gov/ct2/show/study/NCT01205100): NCT01205100).

2.2 | Database: collection and analysis of CT images

In previous studies, patients with disorders of gastrointestinal function (by Rome III criteria) complaining of episodes of visible

PRACTITIONER POINTS

- The evaluation of patients with functional gut disorders presenting with severe episodes of abdominal bloating and distension frequently includes plain abdominal radiographs.
- To determine the reliability of this practice, we compared the objective values of abdominal gas, measured by a validated CT technique in patients with functional gut disorders, to the subjective estimation of gas volumes on plain AP projection of the same CT images (scout views) by a cohort of physicians.
- The volumes of abdominal gas were grossly misestimated in the scout views, indicating that plain abdominal radiographs have no value for the evaluation of intestinal gas volume in patients with functional gut disorders.

abdominal distension were evaluated. After obtaining written informed consent, patients were instructed to come to the laboratory under two different conditions: when they felt minimal or no abdominal distension (basal conditions) and during an episode of visible distension. On each occasion, abdominal CT scans were obtained with a helical multi-slice CT scanner (exposure 120kV and 50mA), using the available dose reduction options (tube current modulation). Images were obtained in the supine position during a single breath hold. No oral or intravenous contrast medium was administered. Measurement of the volume of abdominal gas in the CT images was performed by means of an original software program specifically developed in our laboratory and previously described in detail^{15,16}. A database of 104 patients was collected. The results from the original studies have been published elsewhere^{17,18}.

2.3 | Current analysis: estimation of gas volumes on CT scouts

2.3.1 | Material

For the present study, CT scout views, that is, antero-posterior projections mimicking a conventional plain abdominal radiograph ([Figure 1](#)), were obtained from a representative selection of 30 patients in the database¹⁹; 16 fulfilled Rome III criteria for constipation-predominant irritable bowel syndrome (IBS-C) and 14 for functional bloating/distension. A sequence of 60 images in random order (30 corresponding to distension episodes and 30 to basal conditions in the same patients) was prepared, and another sequence was obtained by reversing the order of the first sequence. All images contained between 20ml y 600ml gas: 51 images in the 20-200ml range represented the most common values observed in patients with functional gut disorders; 7 images in the 250-450ml

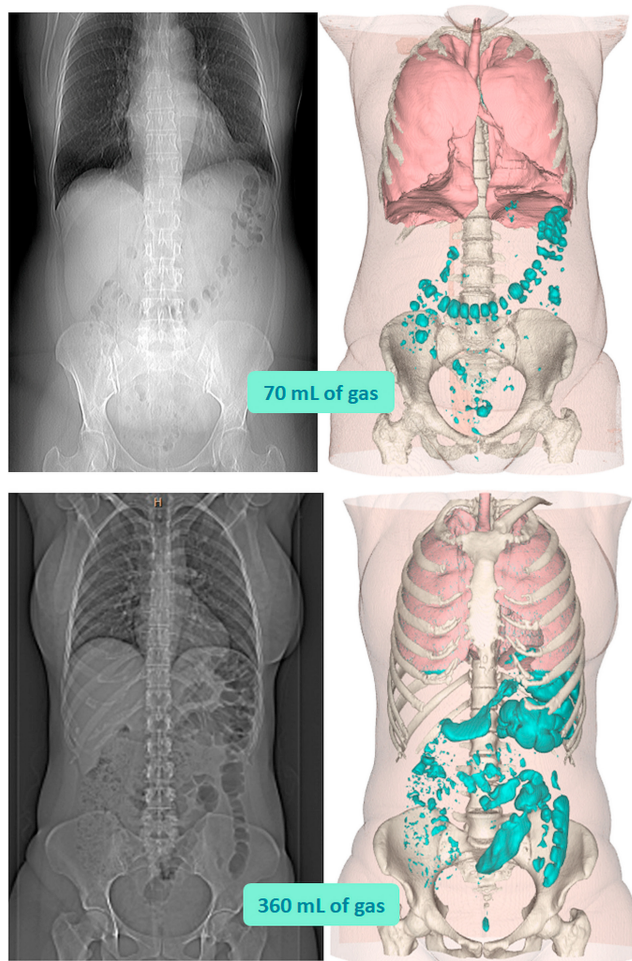


FIGURE 1 Examples of abdominal CT scans and scout views as plain AP projections in two patients. Images contain 70 ml (A) and, (360 ml gas measured by volumetric analysis, respectively

range represented the very top values seen in these patients^{17,18}; 2 images in the 600 ml range were included in search for the detection threshold.

2.3.2 | Participants

Fifty physicians from 3 academic institutions in Spain (University Hospital Vall d'Hebron, Barcelona; Hospital Clinic, Barcelona; Hospital de la Princesa, Madrid) accepted to participate in the study. Participants were recruited among four specialties: Gastroenterology ($n = 20$), Internal Medicine ($n = 12$), Radiology ($n = 12$), and General Surgery ($n = 6$), including staff physicians ($n = 34$) and residents ($n = 14$).

2.3.3 | Procedure

Each participant was randomly allocated to evaluate one of the sequences containing the 60 images. Participants were instructed to rate the estimated volume of gas in each image using a scale graded from 0 ml to ≥ 600 ml with 50 ml divisions. Before the evaluation

TABLE 1 Demographics of participants

Specialty (n)	GE (20)	IM (11)	RX (11)	GS (6)
Sex, F/M	11/9	5/6	4/7	2/4
Staff/residents	15/5	7/4	8/3	4/2
*Experience, years	6 (3–34)	6(2–9)	8 (3–34)	7 (3–11)
Institution, VH/HC/HP	7/4/9	3/4/4	4/4/3	2/4/0

Abbreviations: GE, Gastroenterology; GS, General Surgery; HC, Hospital Clinic, Barcelona, Spain; HP, Hospital de la Princesa, Madrid, Spain; IM, Internal Medicine; RX, Radiology; VH, Vall d'Hebron University Hospital, Barcelona, Spain.

*Years from MD degree, median (range).

procedure, each participant underwent a brief standardized training, being exposed to a training set of images labeled with their real volume of gas: 3 images in the lower 50 ml range (containing 29 ml, 33 ml, and 34 ml gas, respectively) and another 3 images in the upper 500 ml range (containing 583 ml, 531 ml, and 492 ml gas, respectively).

2.4 | Statistical analysis

Volumes of gas estimated by the participants were compared to the volumes measured by the CT analysis program, taken as reference, and the differences (misestimation) were calculated, as an index of the accuracy of the observations. The median or grand median (95% CI) of the variables measured was calculated. The Kolmogorov-Smirnov test was used to check the normality of the data distribution. Parametric normally distributed data were compared by Student's *t*-test for unpaired data or ANOVA (for more than 2 variables); otherwise, the Mann-Whitney *U* test or the Kruskal-Wallis test (for more than 2 variables) was used. In order to evaluate the role of experience, the absolute misestimation value per participant (mean value of the 60 images) was correlated with the years in practice. Pearson's correlation coefficient (Pearson's *r*) was used to examine correlations between parametric normally distributed data and Spearman's *r*' for non-parametric data.

3 | RESULTS

3.1 | Demographics

Two participants (1 internist and 1 radiologist) did not complete the study, and data from 48 participants, representing Gastroenterology ($n = 20$), Internal Medicine ($n = 11$), Radiology ($n = 11$) and General Surgery ($n = 6$), were included for analysis (Table 1).

3.2 | Estimation of gas volumes

The estimated values of gas volumes on plain AP projections showed a great dispersion as compared to the real values measured by CT

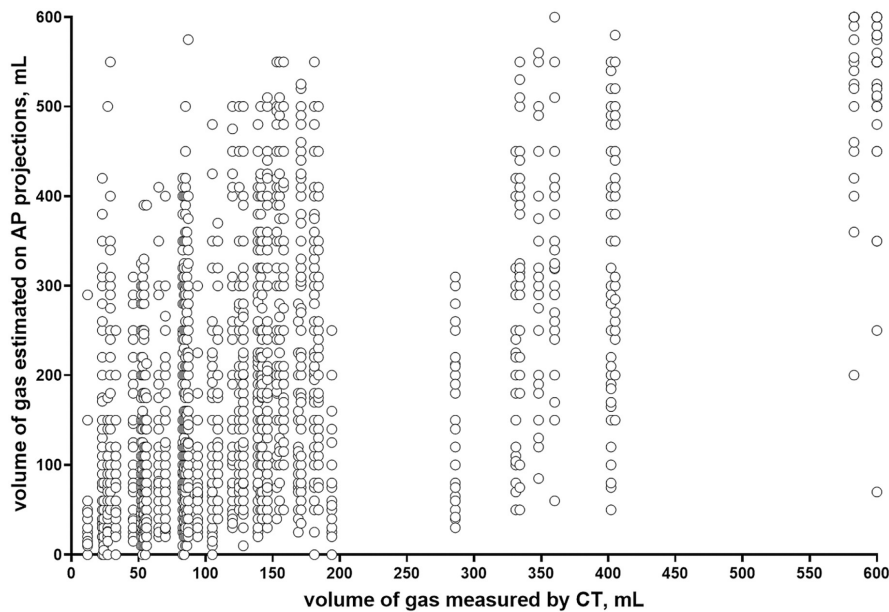


FIGURE 2 Abdominal gas volume. Relation between objective gas volumes measured by CT and estimated volumes on plain AP projections. Individual data of 48 observers for 60 images are shown. Note, great overlap of estimated values, even with largest gas volumes

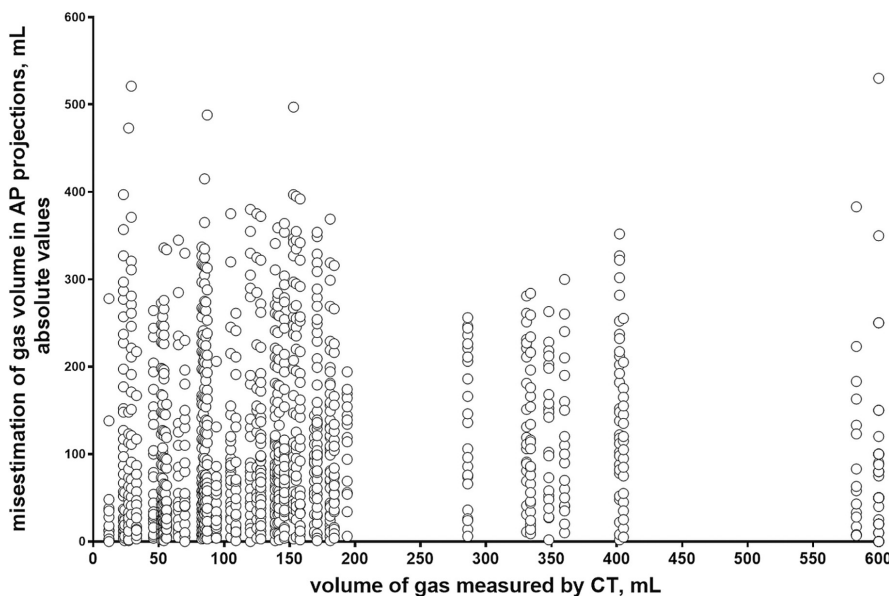


FIGURE 3 Accuracy of estimated volumes on plain AP projections. Relation between absolute values of misestimation (absolute difference from volume measured by CT) and volumes measured by CT. Individual data of 48 observers for 60 images are shown. Note, similar error regardless of the real gas volume

(Figure 2). The misestimation, measured as difference between estimated and real values, was not related to the absolute gas volume in the image ($R = -0.245$; $p < 0.001$); that is, the error was similar with small and large volumes (Figure 3). However, small volumes tended to be overestimated and large volumes underestimated, partly because of the saturation effect of the lower and upper limits of the scale (Figure 4).

3.3 | Role of training, experience, and previous exposure

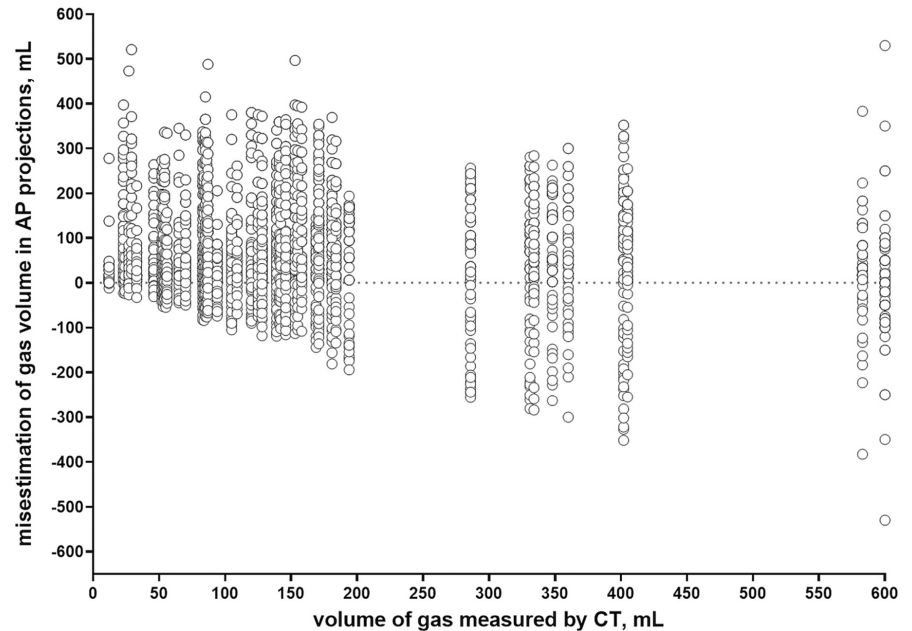
The accuracy of individual participants, determined by averaging the values of the misestimation in all his/her observations, was not related to the specialty (misestimation by 106 (79–133) ml in surgeons, 92 (67–111) ml in gastroenterologists, 86 (64–126) ml in internists

and 87 (55–102) ml by radiologists; $p = 0.322$), training status (misestimation by 96 (85–104) ml in staff versus 78 (70–106) ml in residents; $p = 0.297$) (Figure 5), or years of experience ($R = 0.073$; $p = 0.618$). The accuracy of the observations was independent of the order of presentation of the images ($R = -0.111$; $p < 0.001$; Figure S1). No differences in accuracy were observed between the two randomization sequences presented (misestimation by 75 (62–87) ml and 62 (52–73) ml, respectively; $p = 0.107$).

3.4 | Differences between paired observations (basal versus distension)

Gas volume measured by CT in the images obtained in the same patients during episodes of abdominal distension differed by 39 (29–66) ml from those during basal conditions, and this difference

FIGURE 4 Over and underestimations on plain AP projections. Relation between misestimations (difference from volume measured by CT) and volumes measured by CT. Individual data of 48 observers for 60 images are shown. Note, overestimation of smaller volumes and underestimation of larger volumes



was misestimated by 107 (94–119) ml in the plain AP projections; in 38% of the cases with an increase detected by CT during distension episodes, the estimated volume was smaller; in 40% of the cases with a decrease detected by CT, the estimated volume was greater (Figure 6). The accuracy of these estimations was neither related to the absolute gas volumes ($R = -0.352$; $p < 0.001$) nor to the magnitude of the differences (Figure 6).

4 | DISCUSSION

Our data indicate that plain abdominal radiographs have limited value for the evaluation of abdominal gas volume, specifically in patients with functional digestive symptoms and gas volumes within the 600ml range. The estimations in different subjects were poor, but also when comparing images taken in the same subjects on different occasions, the estimations failed to recognize whether the volume was larger or not. The limitation of the technique cannot be overcome by training, and the same accuracy, measured as misestimation, was observed regardless of specialty (specialized radiologists versus gastroenterologists, internists or general surgeons), and training status (specialized staff physicians versus residents). Furthermore, the accuracy did not improve or deteriorate with repeat estimations, showing neither learning nor fatigue trends.

The accuracy of the estimated volumes was tested against objective measurements of gas by CT analysis. A standard technique was used in the acquisition for abdominal CT imaging, and gas volumes were measured using a software program previously developed in our laboratory. The program has been previously validated by a thorough series of studies comparing gas volumes before and after infusion of known gas loads into the intestine. Detailed description and validation of the program has been published¹⁵.

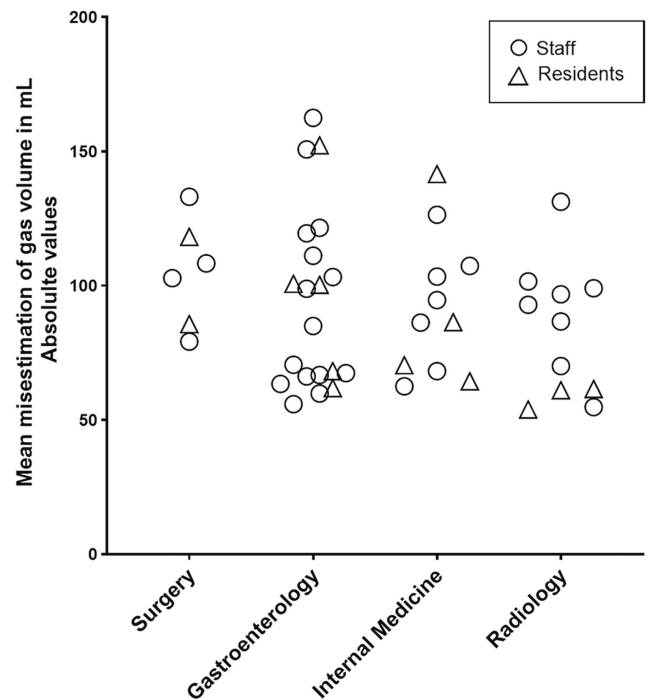


FIGURE 5 Individual accuracy in gas content estimations. For each observer ($n = 48$; x-axis) figure shows absolute misestimation value (mean value of the 60 images; y-axis)

Gas in the gut by-and-large derives from the fermentation by colonic microbiota of food residues that are not absorbed in the small bowel. Intraluminal gas content is kept within 100–200ml by a tight homeostatic control: the volume produced is disposed of by 3 routes: (a) gas-consuming microorganisms, (b) absorption and clearance by breath, and (c) anal evacuation^{20,21}. Despite that gas-related symptoms are commonly attributed to excess intestinal gas, gas volumes measured by CT have been consistently found within the normal range, even during episodes of visible abdominal distension^{10–14}. Some data

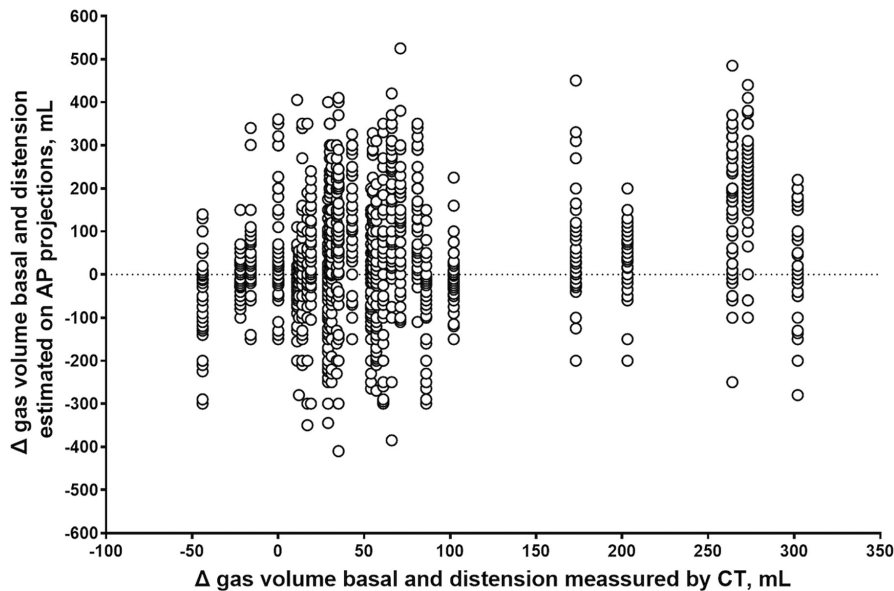


FIGURE 6 Differences in gas volumes between images obtained during basal conditions and distension. Relation between objective gas differences measured by CT (x-axis) and estimated differences on plain AP projections (y-axis). Individual data of 48 observers for 30 paired images are shown

indicate that the symptoms in these patients are due to a sensitive gut with poor tolerance of contents, and visible abdominal distension is due to abdomino-phrenic dyssynergia (diaphragmatic push and downwards displacement of contents). In a recent study, we reviewed the whole pool of 104 consecutive patients with paired abdominal CT images obtained during basal conditions and episodes of distension in our laboratory: in most patients, the difference in gas between both conditions was within the ± 300 ml range, as in the images evaluated in the present study; in only a minority (5 out of 104 patients), distention was associated with an increase in gas above that range, and even these patients exhibited a clear pattern of abdomino-phrenic dyssynergia²².

In a previous study, we specifically measured the volume of rectal gas in patients with functional digestive disorders and found no significant differences compared to healthy subjects, either during basal conditions or during a distension episode²³. By contrast, an interesting study measured gas volumes in the rectum by CT imaging in a large pool of patients presenting with constipation ($n = 141$); the volume of rectal gas was found significantly higher in patients with functional outlet obstruction compared to patients with slow transit or normal transit constipation²⁴.

Limitations of plain abdominal radiographs for the evaluation of intestinal gas content were also encountered by previous studies. Some differences between patients and healthy controls or between patients with and without distension were reported, but no correlations between gas content and symptoms were found. Furthermore, it was also reported that changes in body position introduced a large variability in the estimations (67% increase from upright to supine)²⁵⁻²⁷. Other studies also failed to detect associations between estimated gas contents and gas-related symptoms during provocative tests^{11,28}.

Our data in relation to gas detection apply specifically to patients with functional digestive disorders with gas volumes below 600 ml, but we wish to acknowledge that in patients with organic disorders, such as intestinal dysmotility and pseudo-obstruction, massive gas retention may be reliably identified in plain abdominal radiographs²⁹.

Our data may have inference in clinical practice, suggesting that plain abdominal radiographs to evaluate intestinal gas could be spared, because the technique is not reliable for that purpose; moreover, the possibility of excess gas is very unlikely in patients with reliable diagnosis of a functional gut disorder, and doubtful cases may rather undergo more precise imaging techniques, that provide quantitative measures of gas, and a more precise exam of abdominal structures.

AUTHOR CONTRIBUTIONS

EB. Study design, conduction of studies, data analysis. DL. Conduction of studies, data analysis. LR. Study design, conduction of studies, data analysis. SQ. Analysis of CT images. LA. Conduction of studies. AA. Study design. FA. Study design, data interpretation, manuscript preparation. All authors approved the final draft of the manuscript.

ACKNOWLEDGMENTS

The authors thank Gloria Santaliestra for secretarial assistance.

FUNDING INFORMATION

This work was supported in part by the Spanish Ministry of Economy and Competitiveness (Dirección General de Investigación Científica y Técnica, grant SAF 2016-76,648-R to F Azpiroz); Ciberehd is funded by the Instituto de Salud Carlos III. Dan M. Livovsky received support from the Israeli Medical Association and from Israeli Gastroenterological Association 2020 fellowship grants.

CONFLICT OF INTERESTS

the authors declare no conflict of interest.

ORCID

Elizabeth Barba  <https://orcid.org/0000-0002-5986-6592>

Dan M. Livovsky  <https://orcid.org/0000-0002-8212-9638>

Lucia Relea  <https://orcid.org/0000-0002-3673-5346>

Luis G. Alcalá-Gonzalez  <https://orcid.org/0000-0003-3247-1539>

Sergio Quiroga  <https://orcid.org/0000-0001-8671-7616>
 Anna Accarino  <https://orcid.org/0000-0002-5829-1811>
 Fernando Azpiroz  <https://orcid.org/0000-0002-7327-960X>

REFERENCES

- Sperber AD, Dumitrascu D, Fukudo S, et al. The global prevalence of IBS in adults remains elusive due to the heterogeneity of studies: a Rome Foundation working team literature review. *Gut*. 2017;66(6):1075-1082. doi:10.1136/gutjnl-2015-311240
- Lovell RM, Ford AC. Global prevalence of and risk factors for irritable bowel syndrome: a meta-analysis. *Clin Gastroenterol Hepatol*. 2012;10(7):712-721. doi:10.1016/j.cgh.2012.02.029
- Oka P, Parr H, Barberio B, Black CJ, Savarino EV, Ford AC. Global prevalence of irritable bowel syndrome according to Rome III or IV criteria: a systematic review and meta-analysis. *Lancet Gastroenterol Hepatol*. 2020;5(10):908-917. doi:10.1016/S2468-1253(20)30217-X
- Smith JE, Hall EJ. The use of plain abdominal x rays in the emergency department. *Emerg Med J*. 2009;26(3):160-163. doi:10.1136/emj.2008.059113
- Marasco G, Verardi FM, Eusebi LH, et al. Diagnostic imaging for acute abdominal pain in an Emergency Department in Italy. *Intern Emerg Med*. 2019;14(7):1147-1153. doi:10.1007/s11739-019-02189-y
- Zeina AR, Shapira-Rootman M, Mahamid A, Ashkar J, Abu-Mouch S, Nachtigal A. Role of plain abdominal radiographs in the evaluation of patients with non-traumatic abdominal pain. *Isr Med Assoc J*. 2015;17(11):678-681.
- Driver BE, Chittineni C, Kartha G, Cole JB, Klein LR, Rischall M. Utility of plain abdominal radiography in adult ED patients with suspected constipation. *Am J Emerg Med*. 2020;38(6):1092-1096. doi:10.1016/j.ajem.2019.158377
- Loo JT, Duddalwar V, Chen FK, Tejura T, Lekht I, Gulati M. Abdominal radiograph pearls and pitfalls for the emergency department radiologist: a pictorial review. *Abdom Radiol (NY)*. 2017;42(4):987-1019. doi:10.1007/s00261-016-0859-8
- Bertin CL, Ponthus S, Vivekanantham H, Poletti PA, Kherad O, Rutschmann OT. Overuse of plain abdominal radiography in emergency departments: a retrospective cohort study. *BMC Health Serv Res*. 2019;19(1):36. doi:10.1186/s12913-019-3870-2
- Liu Y, Luo HS. Quantitative analysis of intestinal gas in patients with acute pancreatitis. *Hepatobiliary Pancreat Dis Int*. 2012;11(3):314-318. doi:10.1016/s1499-3872(12)60166-0
- Youn YH, Park JS, Jahng JH, et al. Relationships among the lactulose breath test, intestinal gas volume, and gastrointestinal symptoms in patients with irritable bowel syndrome. *Dig Dis Sci*. 2011;56(7):2059-2066. doi:10.1007/s10620-011-1569-2
- Maxton DG, Martin DF, Whorwell PJ, Godfrey M. Abdominal distension in female patients with irritable bowel syndrome: exploration of possible mechanisms. *Gut*. 1991;32(6):662-664. doi:10.1136/gut.32.6.662
- Mc Williams SR, Mc Laughlin PD, O'Connor OJ, et al. Computed tomography assessment of intestinal gas volumes in functional gastrointestinal disorders. *J Neurogastroenterol Motil*. 2012;18(4):419-425. doi:10.5056/jnm.2012.18.4.419
- Mc SR, Williams PDML, Maher MM. Computed tomography assessment of intestinal gas volumes in functional gastrointestinal disorders. *J Neurogastroenterol Motil*. 2012;18(4):419-425. doi:10.5056/jnm.2012.18.4.419
- Perez F, Accarino A, Azpiroz F, Malagelada J. Gas distribution within the human gut: effect of meals. *Am J Gastroenterol*. 2007;102:842-849.
- Accarino A, Perez F, Azpiroz F, Quiroga S, Malagelada J. Abdominal distension results from caudo-ventral redistribution of contents. *Gastroenterology*. 2009;136:1544-1551.
- Barba E, Accarino A, Azpiroz F. Correction of abdominal distention by biofeedback-guided control of abdominothoracic muscular activity in a randomized, placebo-controlled trial. *Clin Gastroenterol Hepatol*. 2017;15(12):1922-1929.
- Barba E, Burri E, Accarino A, Cisternas D, Quiroga S, Monclus E. Abdomino-thoracic mechanisms of functional abdominal distension and correction by biofeedback. *Gastroenterology*. 2015;148(4):732-738.
- Barba Orozco E, Burri E, Quiroga S, Accarino Garaventa A, Azpiroz F. Visible abdominal distension in functional gut disorders: objective evaluation. *Neurogastroenterol Motil*. 2022;e14466. doi:10.1111/nmo.14466
- Mego M, Bendezú A, Accarino A, Malagelada JR, Azpiroz F. Intestinal gas homeostasis: disposal pathways. *Neurogastroenterol Motil*. 2015;27(3):363-369. doi:10.1111/nmo.12498
- Azpiroz F. Intestinal Gas. *Slisenger and Fordtran's Gastrointestinal and Liver Disease: Pathophysiology, Diagnosis, Management*. 11th ed. Saunders; 2020:224-231.
- Barba Orozco E, Burri E, Quiroga S, Accarino Garaventa A, Azpiroz F. Mechanism of abdominal distension in patients with functional gut disorders. *UEG Journal*. 2021;9(S8):A 244.
- Bendezú RA, Barba E, Burri E, et al. Intestinal gas content and distribution in health and in patients with functional gut symptoms. *Neurogastroenterol Motil*. 2015;27(9):1249-1257. doi:10.1111/nmo.12618
- Park SY, Khemani D, Nelson AD, Eckert D, Camilleri M. rectal gas volume measured by computerized tomography identifies evacuation disorders in patients with constipation. *Clin Gastroenterol Hepatol*. 2017;15(4):543-552. doi:10.1016/j.cgh.2016.11.013
- Chami TN, Schuster MM, Bohlman ME, Pulliam TJ, Kamal N, Whitehead WE. A simple radiologic method to estimate the quantity of bowel gas. *Am J Gastroenterol*. 1991;86(5):599-602.
- Koide A, Yamaguchi T, Odaka T, et al. Quantitative analysis of bowel gas using plain abdominal radiograph in patients with irritable bowel syndrome. *Am J Gastroenterol*. 2000;95:1735-1741.
- Poynard T, Hernandez M, Xu P, Couturier D, Frexinos J, Bommelaer G. Visible abdominal distension and gas surface: description of an automatic method of evaluation and application to patients with irritable bowel syndrome and dyspepsia. *EurJGastroenterolHepatol*. 1992;4:831-836.
- Morken MH, Berstad AE, Nysaeter G, Berstad A. Intestinal gas in plain abdominal radiographs does not correlate with symptoms after lactulose challenge. *Eur J Gastroenterol Hepatol*. 2007;19(7):589-593. doi:10.1097/MEG.0b013e328133f2e7
- Barba E, Quiroga S, Accarino A, et al. Mechanisms of abdominal distension in severe intestinal dysmotility: abdomino-thoracic response to gut retention. *Neurogastroenterol Motil*. 2013;25(6):e389-e394. doi:10.1111/nmo.12128

SUPPORTING INFORMATION

Additional supporting information can be found online in the Supporting Information section at the end of this article.

How to cite this article: Barba E, Livovsky DM, Relea L, et al. Evaluation of abdominal gas by plain abdominal radiographs. *Neurogastroenterology & Motility*. 2023;35:e14485. doi: [10.1111/nmo.14485](https://doi.org/10.1111/nmo.14485)