

## Unexpected *Loa loa* Finding in an Asymptomatic Patient From The Gambia: A Case Report

Begoña Treviño,<sup>1,2</sup> Francesc Zarzuela,<sup>3</sup> Inés Oliveira-Souto,<sup>1,2,⊗</sup> Carlos Rubio Maturana,<sup>3,⊗</sup> Núria Serre-Delcor,<sup>1,2</sup> Maria L. Aznar,<sup>1,2</sup> Diana Pou,<sup>1,2</sup> Lidia Goterris,<sup>3</sup> Fernando Salvador,<sup>1,2</sup> Pau Bosch-Nicolau,<sup>1,2</sup> José M. Rubio,<sup>2,4</sup> Ederne Ruiz,<sup>3</sup> Israel Molina,<sup>1,2</sup> and Elena Sulleiro,<sup>2,3,⊗</sup>

<sup>1</sup>Vall d'Hebron-Drassanes International Health Unit, Infectious Diseases Department, Vall d'Hebron University Hospital, International Health Programme of Catalan Health Institute (PROSICS) Barcelona, Centres, Services and Reference Units (CSUR) Imported Tropical Diseases, Barcelona, Spain, <sup>2</sup>Centre for Biomedical Research Network on Infectious Diseases, Madrid, Spain, <sup>3</sup>Vall d'Hebron-Drassanes International Health Unit, Microbiology Department, Vall d'Hebron University Hospital, International Health Programme of Catalan Health Institute (PROSICS) Barcelona, Centres, Services and Reference Units (CSUR) Imported Tropical Diseases, Barcelona, Spain, and <sup>4</sup>Microbiology National Centre, Carlos III Health Institute, Madrid, Spain

A 17-year-old asymptomatic male from The Gambia presented for a routine health examination after migration to Spain. Laboratory diagnosis confirmed the presence of *Loa loa* microfilariae. This unusual finding emphasizes the importance of screening in newly arrived migrants and the need of an extended anamnesis including migratory route and previous travels.

**Keywords.** *Chrysops*; epidemiology; *Loa loa*; loiasis; The Gambia.

Loiasis is a parasitic disease caused by the filarial nematode *Loa loa*. It is transmitted to humans mainly through the bite of adult female *Chrysops silacea* and *Chrysops dimidiata* gadflies [1]. It is geographically distributed in the west and central region of the African continent, where >10 million people are estimated to be infected [2]. Pathognomonic manifestations of the disease are Calabar swelling and the presence of the adult worm on the surface of the eye, although most people infected with *L loa* are asymptomatic [1]. Thus, *L loa* findings are occasional in immigrant infection screening programs unless routine examination of blood for microfilariae detection is performed.

Received 29 March 2023; editorial decision 21 June 2023; accepted 29 June 2023; published online 3 July 2023

Correspondence: Inés Oliveira-Souto, MD, PhD, Unidad de Salud Internacional Vall d'Hebron-Drassanes, Servicio de Enfermedades Infecciosas, Hospital Universitario Vall d'Hebron, Passeig de la Vall d'Hebron 119-129, 08035 Barcelona, Spain (ines.oliveira@vallhebron.cat).

### Open Forum Infectious Diseases<sup>®</sup>

© The Author(s) 2023. Published by Oxford University Press on behalf of Infectious Diseases Society of America. This is an Open Access article distributed under the terms of the Creative Commons Attribution-NonCommercial-NoDerivs licence (<https://creativecommons.org/licenses/by-nc-nd/4.0/>), which permits non-commercial reproduction and distribution of the work, in any medium, provided the original work is not altered or transformed in any way, and that the work is properly cited. For commercial re-use, please contact journals.permissions@oup.com  
<https://doi.org/10.1093/ofid/ofad338>

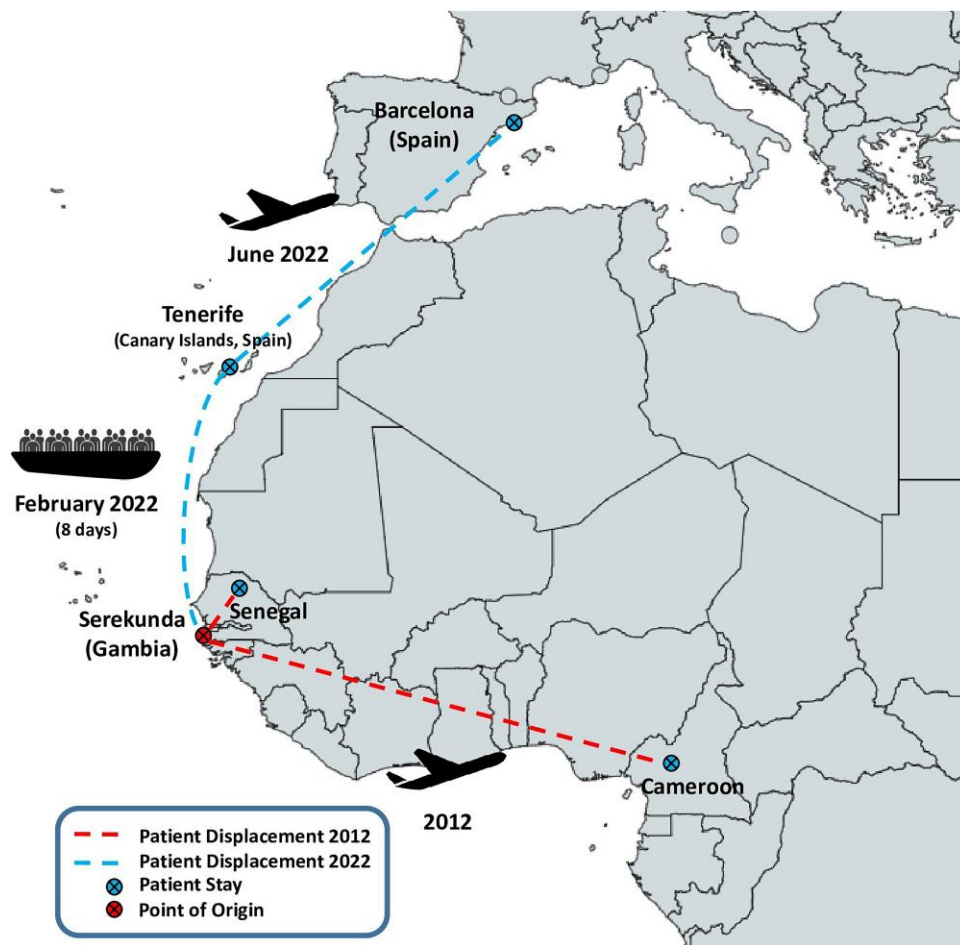
### CASE REPORT

An unaccompanied 17-year-old male minor from The Gambia (Serekunda), living in a shelter center, presented for a routine health examination in July 2022 at the International Health Unit in Barcelona. He left The Gambia in February 2022 and followed the migration route from his country to Spain by sea (small boat) to the island of Tenerife (Canary Islands). Afterward, he flew to Barcelona in June 2022. The patient's travel history is represented in Figure 1. He provided documentation from The Gambia and spoke Fula and Wolof local languages. Furthermore, he stated that he had not traveled to any other country except Senegal once for a few days, and 3 months in Cameroon when he was 7 years old. He was asymptomatic and had an unremarkable physical examination.

Our initial screening protocol for infectious diseases in asylum seekers was composed of hemogram with leukocyte count and immunoglobulin E; creatinine, cholesterol, glycemia, and hepatic function panel in serum; hepatitis B surface antigen, antibodies to hepatitis B core antigen, antibodies to hepatitis B surface antigen, and hepatitis A, hepatitis C, syphilis, human immunodeficiency virus, *Strongyloides stercoralis*, and *Schistosoma mansoni* serology; latent tuberculosis infection screening by tuberculin test and Quantiferon-TB Gold Test; microscopic examination of helminths and intestinal protozoa in 1 sample of feces; urinary sediment for discarding schistosomiasis and microfilariae microscopic examination; and malaria polymerase chain reaction (PCR) [3]. In this patient, the health assessment for newly arrived migrants showed eosinophilia; immunity to hepatitis A, varicella zoster virus, measles, mumps, and rubella; and active hepatitis B. Detailed screening results are shown in Table 1. Microfilariae were detected by the Ho-Thi Sang technique based on a leuko-concentration with saponin to visualize the hemoparasites, revealing microfilariae compatible with *L loa* (110 microfilariae/mL). In vivo, microfilariae with a characteristic sheath and movement were observed. Hematoxylin-modified Gill staining was performed to observe the morphology of microfilariae, being 250–300 µm in length and 6–7 µm in width, with dispersed somatic nuclei. Giemsa staining 10% without sheath coloration confirmed an *L loa* infection (Figure 2).

Real-time PCR was performed with a positive result for *L loa* infection, confirming microscopy diagnosis [4]. The patient initiated treatment with diethylcarbamazine and completed the 21-day regimen with no adverse effects.

The patient's origin renders the finding unexpected. However, his 3-month stay in Cameroon is enough time to have been infected with *L loa*, as it is also the epicenter of the disease [5]. We cannot discard an endemic infection of the disease in The Gambia, despite the fact that no cases have been previously reported in this region.

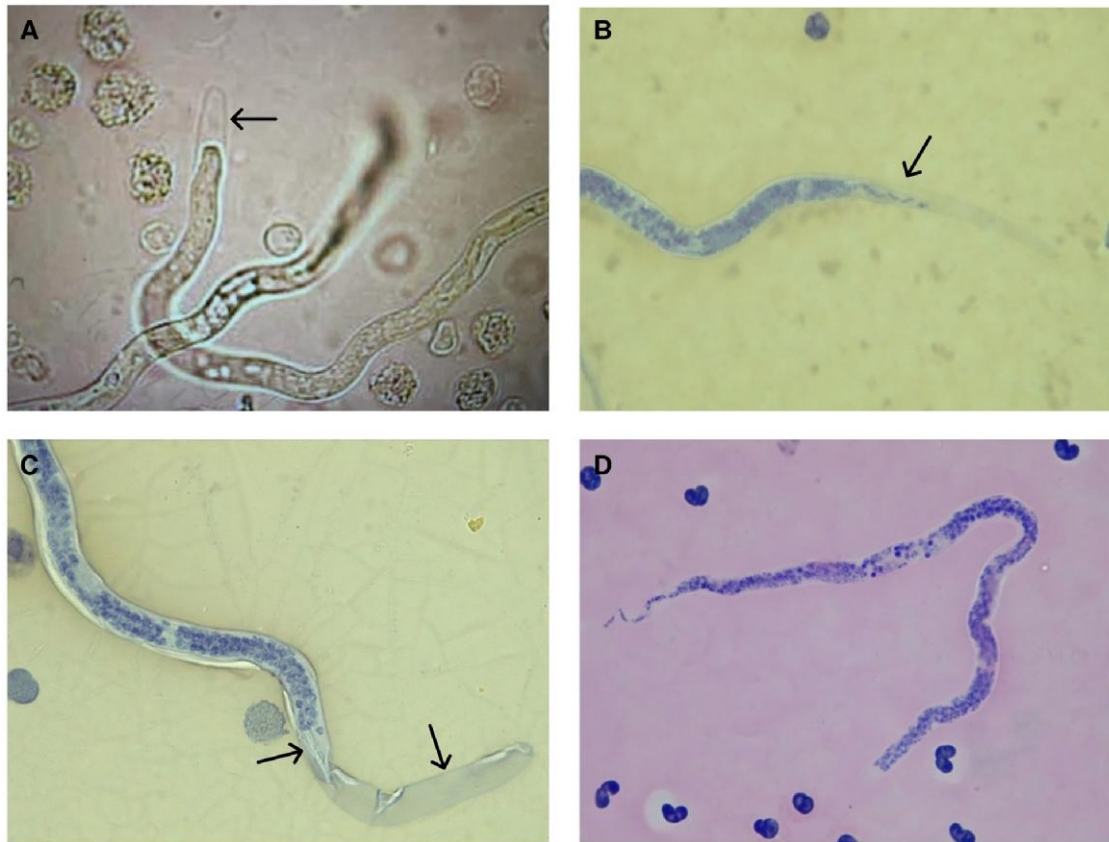


**Figure 1.** Patient's travel history. Patient displacement in year 2012 (Cameroon and Senegal) and patient displacement in year 2022 (Spain / Barcelona and Tenerife) were represented. Ship and plane illustrations represent the transport vehicle of the displacement.

**Table 1. Clinical and Laboratory Diagnosis Results**

Observations	Results
Clinical findings	Asymptomatic Unremarkable physical examination
Hematology	Total eosinophil count: 400/ $\mu$ L (n.v. <500 cells/ $\mu$ L) Relative eosinophil percentage: 9.5% Total IgE: 1098 kU/L (n.v. 0.00–117.00) Blood count, biochemical and urine tests: n.v.
Serology	Serological markers showed immunity to HAV, VZV, measles, mumps, and rubella virus HBsAg: positive, DNA HBV viral load of 5.66E8 IU/mL (8.75 log) HIV, HCV, and syphilis, and <i>Strongyloides stercoralis</i> Ac IgG: negative <i>Schistosoma mansoni</i> Ac IgG: 5.78 (positive >1.1)
Microscopic examination	Microscopic examination of stool concentration: protozoan cysts, helminth ova, and larvae not observed <i>Schistosoma haematobium</i> eggs in urine by concentration: not observed Ho-Thi Sang technique in peripheral blood: <i>Loa loa</i> microfilariae (110 microfilariae/mL)
Tuberculosis and malaria	Quantiferon-TB Gold Test: negative CXR: normal Real-time PCR for <i>Plasmodium</i> spp: negative
<i>Loa loa</i> diagnosis confirmation	Real-time PCR for <i>Loa loa</i> [4]: positive

Abbreviations: Ac, antibody; CXR, chest radiograph; HAV, hepatitis A virus; HBsAg, hepatitis B surface antigen; HBV, hepatitis B virus; HCV, hepatitis C virus; HIV, human immunodeficiency virus; IgG, immunoglobulin G; IgE, immunoglobulin E; n.v., normal value; PCR, polymerase chain reaction; TB, tuberculosis; VZV, varicella zoster virus.



**Figure 2.** A, *Loa loa* microfilarial morphology by the Ho-Thi Sang leuko-concentration technique. The microfilarial sheath is visible (arrow). B, Modified hematoxylin Gill stain. Visualization of *L loa* microfilarial morphology: presence of terminal, irregular, and overlapped somatic nuclei (arrow). Tapered posterior extremity with terminal nuclei. C, Cephalic space and sheath (arrows) of *L loa* microfilariae with modified hematoxylin Gill staining. D, Uncolored *L loa* sheath observed by Giemsa staining (10%).

The limits of loiasis geographical distribution area are Benin to the west, Uganda to the east, latitude 10° to the north, and Zambia to the south. Therefore, in 2018 an *L loa* endemicity map that reached southern Guinea Conakry was published [5]. In addition, *L loa* infections were reported in a migrant from Guinea Conakry in 2021 [6], and in a traveler returning from Bioko Island (Equatorial Guinea) in 2016 [7], a location formerly unknown for *L loa* transmission.

*Chrysops* redistribution may also be responsible for the new cases in nonclassic endemic countries. *Chrysops silacea* and *C dimidiata* are found in areas of western and central Africa, and their presence is associated with disease transmission. Environmental studies postulate that changes in ecosystems, temperature, and rainfall may vary the presence of these species in potentially endemic areas. In addition, some species of the genus *Chrysops* had been found in Senegal, an area where no such findings had been reported before and which is adjacent to The Gambia [8]. However, the spread of the disease in areas outside the African continent is highly improbable due to the present absence of the vectors *C silacea* and *C dimidiata* in areas of southern Europe.

Furthermore, loiasis is not currently on the list of priority of neglected tropical diseases by the World Health Organization [9], and there are no control programs. Mass drug administration (MDA) with ivermectin is employed for some elimination strategies and has been recently implemented in The Gambia for malaria control purposes [10]. Although this treatment is generally safe, ivermectin has been associated with potentially fatal encephalopathy in individuals with high *L loa* microfilariae densities [11]. Possible autochthonous *L loa* infections could represent a risk for MDA ivermectin programs.

We cannot rule out a previous infection, due to the patient's former travel history, nor a Gambian autochthonous infection. However, if the vector is potentially established in the neighboring countries of The Gambia, and there is high mobility of people between endemic and nonclassic endemic countries, it might be only a matter of time until new cases will be reported. To rule out this hypothesis, it is essential to carry out vector and parasitological studies in the field in order to determine the real prevalence of this infection in the country.

Finally, we must emphasize the importance of screening programs in recently arrived migrants. The finding of unusual

pathologies can be studied on the basis of the screening tests and the previous anamnesis, focused on the migratory route and the country of origin. The prompt treatment of asymptomatic infections would decrease morbidity and the potential public health issues in countries hosting immigrant populations.

### Notes

**Author contributions.** B. T., F. Z., I. O.-S., C. R. M., and E. S. prepared and wrote the manuscript. J. M. R. performed the polymerase chain reaction technique to confirm the microscopic diagnosis. F. Z. and E. S. participated in the microbiological diagnosis of the patient. N. S.-D., M. L. A., D. P., L. G., F. S., P. B.-N., J. M. R., E. R., and I. M. revised the manuscript.

**Acknowledgments.** Written informed consent was obtained from the patient for publication of this case report. The authors thank Helena Kruyer for her assistance with the English editing.

**Potential conflicts of interest.** All authors: the authors declare that there is no conflict of interest.

### References

- Centers for Disease and Prevention, Division of Parasitic Diseases and Malaria. Loiasis. 2019. Available at: <https://www.cdc.gov/dpdx/loiasis/index.html>. Accessed 12 December 2022.
- Metzger WG, Mordmüller B. *Loa loa*—does it deserve to be neglected? *Lancet Infect Dis* 2014; 14:353–7.
- Serre-Delcor N, Ascaso C, Soriano-Arandes A, et al. Health status of asylum seekers, Spain. *Am J Trop Med Hyg* 2018; 98:300–7.
- Tang TH, López-Vélez R, Lanza M, Shelley AJ, Rubio JM, Luz SL. Nested PCR to detect and distinguish the sympatric filarial species *Onchocerca volvulus*, *Mansonella ozzardi* and *Mansonella perstans* in the Amazon region. *Mem Inst Oswaldo Cruz* 2010; 105:823–8.
- Akue JP, Eyang-Assengone ER, Dieki R. *Loa loa* infection detection using biomarkers: current perspectives. *Res Rep Trop Med* 2018; 9:43–8.
- Nicolini AL, Tamarozzi F, Pomari E, et al. Loiasis from where you don't expect it: an illustrative case of misled diagnosis. *J Travel Med* 2022; 29:taac060.
- Priest DH, Nutman TB. Loiasis in US traveler returning from Bioko Island, Equatorial Guinea, 2016. *Emerg Infect Dis* 2017; 23:160–2.
- Keita ML, Medkour H, Sambou M, Dahmana H, Mediannikov O. Tabanids as possible pathogen vectors in Senegal (West Africa). *Parasit Vectors* 2020; 13:500.
- Jacobsen KH, Andress BC, Bhagwat EA, et al. A call for loiasis to be added to the WHO list of neglected tropical diseases. *Lancet Infect Dis* 2022; 22:e299–302.
- Dabira ED, Soumare HM, Conteh B, et al. Mass drug administration of ivermectin and dihydroartemisinin–piperaquine against malaria in settings with high coverage of standard control interventions: a cluster-randomised controlled trial in the Gambia. *Lancet Infect Dis* 2022; 22:519–28.
- Blok DJ, Kamgno J, Pion SD, et al. Feasibility of onchocerciasis elimination using a 'test-and-not-treat' strategy in *Loa loa* co-endemic areas. *Clin Infect Dis* 2021; 72:E1047–55.